

## INTRACRANIAL SPACE OCCUPYING LESION WITH HYDATID CYST: A RARE INFESTATION OF HYDATID ISOLATE FROM INTRACRANIAL CYSTIC LESION

### Abstract

Human echinococcus is caused by a tapeworm, *Echinococcus granulosus*, which forms larval cysts in the human tissue. The definite hosts of echinococcus are various carnivores, the common one being the dog [1]. It is a widespread zoonotic disease, where most cysts develop in the liver and some disseminate to other sites; such as the lungs and rarely, the brain [2, 3]. The incidence of hydatid cyst in the liver is 60%, while that of the cerebral and spinal forms is only 1–2% [4]. In our country, *E. granulosus* is relatively common in southeast Rajasthan [5]. The larval stage involves the brain via the choroid plexus [2, 6, 7]. Localization of hydatid disease in brain can be associated with involvement of other organs such as liver or lung or may be an isolated infestation of the brain or spinal column. Fifty to seventy-five percent of cerebral cases appear in childhood with supratentorial location whereas infratentorial lesions are quite rare [8]. Treatment of cerebral hydatid cysts is primarily surgical [9]. The cysts must be removed intact as spillage of the contents will cause anaphylactic reaction or disseminated recurrence of hydatid disease [10]. Preoperative and postoperative albendazole may be considered to sterilize the cyst, decrease the chance of anaphylaxis, decrease tension in the cyst wall, and hence reduce risk of spillage during surgery and the recurrence rate [11]. In this case report we highlight a case of intracranial hydatid cyst and its diagnosis which was confused with a diagnosis of intracranial neurocysticercosis.

### Aims

The aim of our case report is to bring into light a rare infestation of hydatid isolate from intracranial cystic lesion which was misdiagnosed as intracranial neurocysticercosis infestation at a tertiary care center in northern India.

### Presentation of case

A 16 year old female, resident of Uttar Pradesh presented to the Neurosurgery outpatient department (OPD) with a 3 months history of holocranial headache and generalised tonic clonic seizures for the past 1 year. On general examination, all her vitals were within normal limits, no facial asymmetry or hypoesthesia was observed and her lower cranial nerves were also within normal limits. On motor examination, tone was normal in all four limbs and power 5/5 in all the four limbs. Plantar sign showed flexion, sensory system, posterior column, and cerebellar signs were intact. Her tandem gait and lobar sign were impaired. She was advised for a Contrast enhanced Magnetic resonance imaging (CEMRI) and the results showed evidence of a large

cystic space occupying lesion in left frontal region of size 4x4 cm intra-axial T1 hypointense and T2 hyperintense with contrast enhancement without any diffusion restriction (Fig 1). The lesion had a mass effect with ipsilateral effacement of lateral ventricle with subfalcine herniation. To diagnose involvement of other organs, ultrasound and computed tomography of the abdomen and high resolution computed tomography (HRCT) chest were performed on which no cystic lesions were found. The clinicians considered it as a case of Left frontal intraparenchymal single neurocysticercosis with mass effect. She was scheduled for a precoronal keyhole craniotomy and total excision of cyst on 4<sup>th</sup> July 2019. Cyst was thick translucent containing clear content. Cyst decompressed and cyst wall excised from wall of parenchyma. Postoperatively patient had improvement in headache. Rest of the post operative recovery was uneventful. Sutures were removed on 14<sup>th</sup> postoperative day and the patient was discharged on Albendazole 400 mg BD for two weeks. Patient was discharged with advice to follow up in Neurosurgery OPD.

After one month of surgery, she was suggested for a repeat Contrast enhanced computed tomography which suggested of craniotomy defect with a cystic mass lesion with contrast enhancing ring like lesion with central necrotic material and perilesional edema with mass effect (Fig 2). She was reoperated on 28<sup>th</sup> August 2019 due to repeated cystic lesion and mass effect with midline shift. Abscess cavity was decompressed and abscess was aspirated, which was thick and yellowish, there were few cysts in the cavity. Fluid was yellowish and thick. The cyst fluid and abscess pus were aspirated and sent to the Parasitology section of Department of Microbiology, Sanjay Gandhi Postgraduate Institute of Medical Sciences, Lucknow. A wet mount of the pus was prepared and observed under the 10x followed by 40x objective lens of the microscope shows few pus cells and plenty of hooklets and scolices of *Echinococcus granulosus* (Hydatid cyst) (Fig 3). No cystic lesions were found on repeat ultrasound and computed tomography of the abdomen and high resolution computed tomography (HRCT) chest, deeming it as a case of primary neurohydatosis. On histopathology of the frozen section, brain parenchyma was observed with few scolices and hooklets, the parenchyma shows mixed inflammatory cell infiltrates comprising of sheets of foamy histiocytes, lymphocytes, eosinophils with no evidence of malignancy. Follow up examinations showed no motor or sensory weakness. Repeat ultrasound of the abdomen and pelvis and chest X-ray were all within normal limits. Repeat MRI of the brain and spinal cord after 3 months showed craniotomy defect with no new lesion

The patient underwent a left precoronal keyhole craniotomy and total excision of cyst with drainage of thick and yellow coloured pus. The surgical cavity was then irrigated with hypertonic saline 3%. The patient had an uneventful postoperative period and was discharged on Albendazole 400 mg BD for the next three months.

## Discussion

In hydatid disease, the only pathogenic species for humans is *E. granulosus*. Humans become infected by ingesting tapeworm eggs passed from an infected carnivore, especially dogs, which

most frequently happens when individuals handle or have contact with infected carnivores or inadvertently ingest food or drink contaminated with fecal material containing tapeworm eggs [1]. However, because India is an endemic region, all the children in our series may have been infected by **eating contaminated food**. Intracranial hydatid disease is considered a childhood disease. Fifty to seventy-five percent of intracranial hydatid cysts are seen in children. Izci *et al.*[10] reported a series of 17 patients with intracranial hydatid cysts and 13 (65%) of these patients were children. Cerebral hydatid cysts are often supratentorially localized in the distribution of the terminal branches of the middle cerebral artery, usually temporo-parieto-occipitally.[11] In our case, patients also had cysts in the supratentorial location and in the left frontal lobe of the brain.

Cerebral hydatid cysts may not show any symptom until they reach a considerably large size. They usually present with focal neurological deficit and feature of raised intracranial pressure; the latter results from the large size or interference in the flow of cerebrospinal fluid. Most patients present **with headache and vomiting**, followed by motor weakness and seizures [12]. In our case the patient presented with generalised tonic clonic seizure and her tandem gait and lobar sign were impaired.

The differential diagnosis of intracranial cystic lesions consists of cystic and necrotic malignancies and benign lesions like abscess or calcified neurocysticercosis. There was immense diagnostic dilemma among the clinicians on the first contrast enhanced magnetic resonance imaging film before the first keyhole craniotomy, due to large ring enhancing space occupying lesion in the left frontal lobe. It was proved to be *E. granulosus* on wet mount prepared from the pus aspirate of the abscess cavity. Therefore microscopic examination of the cystic fluid or abscess aspirate holds almost equal importance as the radiologic imaging techniques. The primary treatment of intracranial hydatid cysts is surgery and should be as radical as possible. Injection of formalin and evacuation of the cyst was the technique used until 1967 [12]. Thereafter, the Dowling technique has been used to remove the cyst as the most common and the gold standard method. In the case of intraoperative rupture, the operative site should be systematically and repeatedly cleaned with a solution of 3% NaCl or 10% formaldehyde. Albendazole is recommended in cases of intraoperative rupture of the cysts and in case of recurrence. It is also recommended in inoperable cases of multifocal disease or involving vital brain structures [13]. In our case, a precoronal keyhole craniotomy and total excision of cyst followed by repeated cleaning with 3% hypertonic saline. Indications for preoperative or postoperative therapy with albendazole or mebendazole include rupture, multiple organ involvement, multiple brain lesions, recurrence and preoperative volume reduction [14, 15].

## Conclusion

Intracranial hydatid cyst is a rare disease in non-endemic parts of India and should be included as a rare cause of cystic lesions in the brain. The diagnosis of cystic echinococcosis in brain is very difficult due to misleading appearance on CT scan which presents as an image similar to the

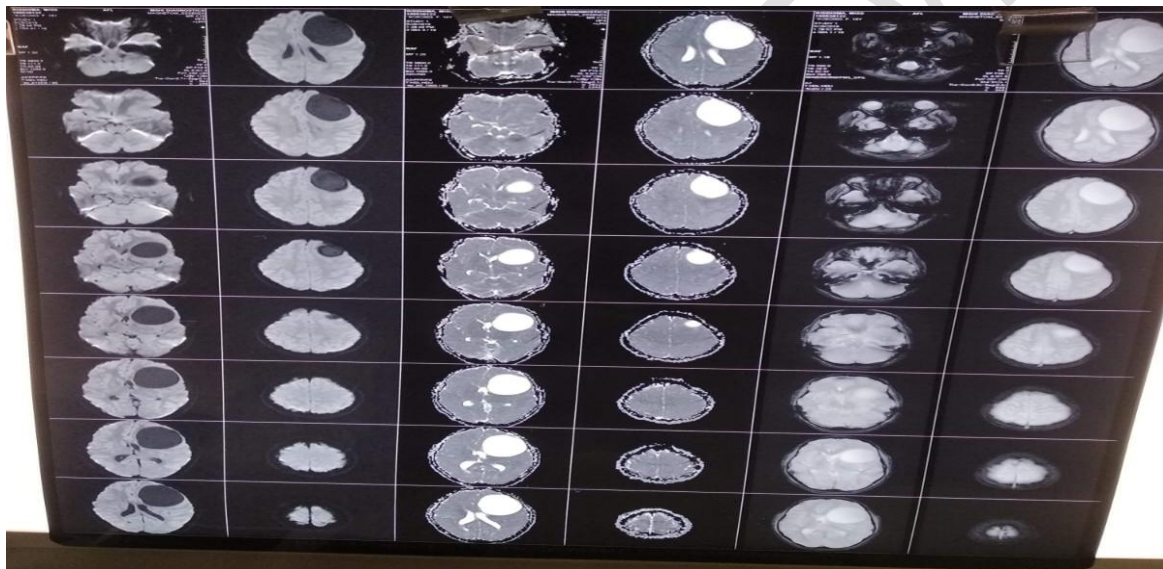
single cystic neurocysticercosis lesion with ring enhancement and thus the role of wet mount preparation and microbiological tests is equally important in early diagnosis of the disease.

## Reference

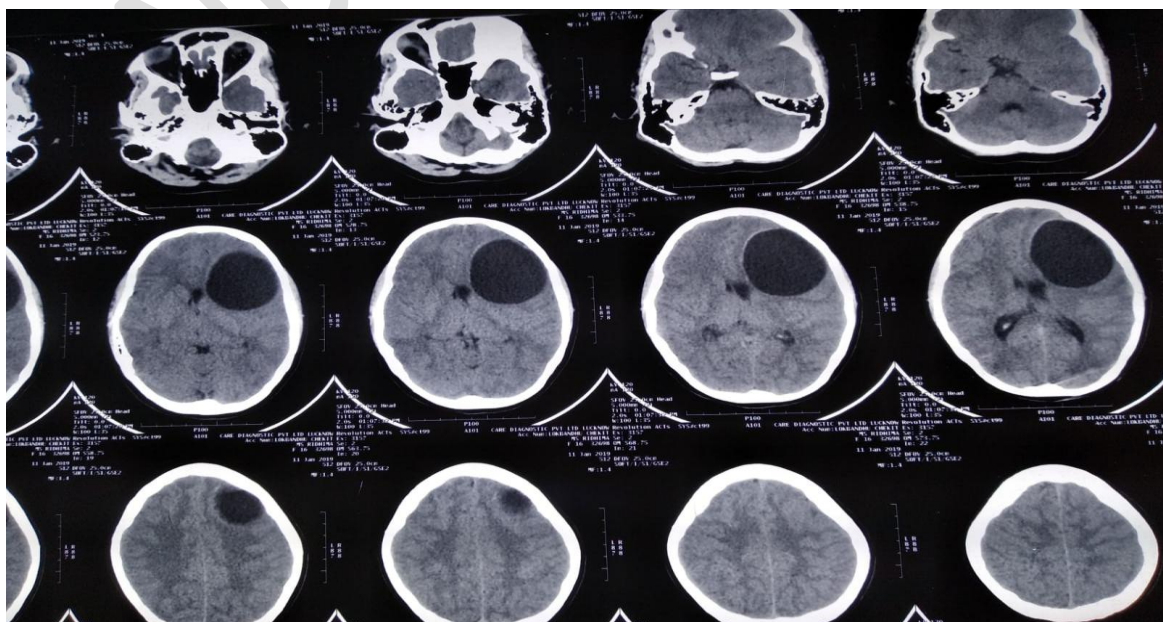
1. Tuzun Y, Kadioglu HH, Izci Y, Suma S, Keles M, Aydin IH. The clinical, radiological and surgical aspects of cerebral hydatid cysts in children. *PaediatrNeurosurg*. 2004; 40:155-60.
2. Binesh F, Mehrabanian M, Navabii H. Primary brain hydatosis. *BMJ Case Rep* 2011; 2011:bcr0620103099.
3. Bükte Y, Kemaloglu S, Nazaroglu H et al. Cerebral hydatid disease. CT and MR imaging findings. *Swiss Med Wkly* 2004; 134:459-67.
4. Abbassioun K, Rahmat H, Ameli NO, Tafazoli M. CT in hydatid cyst of the brain. *J Neurosurgery*. 1985;62:781-2.
5. Gautam S, Sharma A. Intracranial Hydatid Cyst; A report of three cases in North-west India. *J PediatrNeurosci*. 2018; 13 (1): 91-95.
6. Polat P, Kantaci M, Alper F et al. Hydatid disease from head to toe. *Radiographics* 2003; 23:475-94.
7. Gupta S, Desai K, Goel A. Intracranial hydatid cyst: a report of five cases and review of literature. *Neurol India* 1999;47:214-17.
8. Ayres CM, Davey LM, German WJ. Cerebral hydatidosis. Clinical case report with a review of pathogenesis. *J Neurosurg*. 1963;20:371-7.
9. Izci Y, Tüzün Y, Seçer HI, Gönül E. Cerebral hydatid cysts: Technique and pitfalls of surgical management. *Neurosurg Focus*. 2008;24:E15.
10. Boop FA, Jacobs RF, Young RL (1999) Brain abscess and encephalitis in children. In: Albright AL, Pollack IF, Adelson PD (eds) *Principles and practice of pediatric neurosurgery*. Thieme, New York, pp 1203-1226
11. Horton RJ. Albendazole in treatment of human cystic echinococcosis: 12 years of experience. *Acta Trop*. 1997;64:79-93.
12. Ciurea AV, Fountas KN, Coman TC, Machinis TG, Kapsalaki EZ, Fezoulidis NI, et al. Long-term surgical outcome in patients with intracranial hydatid cyst. *Acta Neurochir (Wien)* 2006;148:421-6.



13. Esgin M, Aktas M, Coskun S. The investigation of antibody presence in the sera of patients with a suspicion of cystic echinococcosis by using indirect hemagglutination test (IHA). *TurkiyeParazitolojisi Dergisi* 2007;31:283-7.
14. Najjar MW, Rajab Y, El-Beheiri Y. Intracranial hydatid cyst. Dilemma in diagnosis and management. *Neurosciences (Riyadh)* 2007;12:249–52.
15. Bartosch C, Reis C, Castro L. Large solitary cerebral hydatid cyst. *Arch Neurol* 2011;68:946–7. 30
16. Nourbakhsh A, Vannemreddy P, Minagar A, et al. Hydatid disease of the central nervous system: a review of literature with an emphasis on Latin American countries. *Neurol Res* 2010;32:245–51.



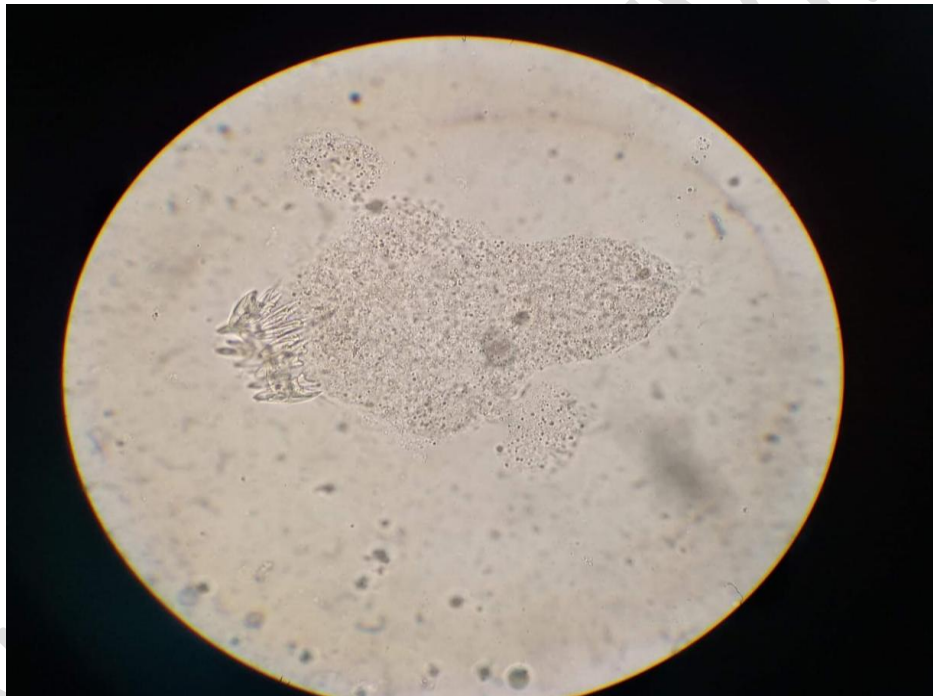**Figure 1. Preoperative Contrast enhanced magnetic resonance imaging of the space**



occupying lesion in the frontal lobe

**Figure 2. Postoperative Contrast enhanced computed tomography image of space occupying lesion in the frontal lobe**

**Figure 1 and 2 show a thick walled cystic lesion measuring 4x4 cm in the left frontal lobe which is subcalverial in location. The lesion is causing buckling of the underlying parenchyma. Mild perilesional edema is noted causing mass effect in the form of effacement of left frontal horn of lateral ventricle, left basal ganglia along with midline shift suggestive of Hydatid cyst.**



**Figure 3. Wet mount of the pus was prepared and observed under the 10x followed by 40x objective lens of the microscope shows few pus cells and plenty of hooklets and scolices of *Echinococcus granulosus***