

Original Article

Analysis of 74 Open Globe Injuries Requiring Vitreo-Retinal Intervention and Its Correlation with Ocular Trauma Score

Abstract:

Aim: Retrospective study of 74 eyes with open globe injuries requiring V-R Intervention & its correlation with ocular trauma score.

Results: Commonest cause of injury: Hammer-chisel/stone in 32.43%(24) & Thorn/wooden stick 27%(20). Average age-30.5yrs. Average interval between trauma & intervention was - 10.04days (4hrs – 52days).

Discussion: Delay of presentation to ophthalmologist has lot of significance, high incidence of endophthalmitis & retinal detachment compared to other studies. Surgical outcome shows lower incidence of NO Light Perception & Significant reduction in number of cases with \leq HM. Patients had better prognosis & visual outcome, higher incidence of 1/200- 20/50; 35.14% cases with $>20/200$. 60% of our cases had traumatic cataract, visual acuity may be underestimated in traumatic cataract. Faulty Projection of rays probably would be better criteria than RAPD. Extension of wound beyond pars plana, and aniridia(6.7%) are important risk factor.

Conclusion: Modification of raw points is recommended in OTS criteria in Indian scenario.

Keywords: Ocular trauma score (OTS), Retinal Detachment (RD), *Penetrating trauma (PT)*, *Retained IOFB (IOFB)*, *Perforating injury (PF)*, *Globe rupture (RPT)*

Introduction:

Ocular trauma is the major cause of preventable monocular blindness and visual impairment

in the world and leads to psychological, economical and professional crippling of the patient. Fifty yrs ago, there was very little to offer patients with severe injury involving posterior segment. In open globe injuries enucleation was often recommended due to perceived risk of sympathetic ophthalmia. Since last decade scenario has changed with better vitreoretinal surgical techniques. Now in almost all cases, we can salvage the eye and in many we can even give ambulatory vision

Aim & Objectives:

1. It is very critically important for patient as well as ophthalmologist to have reliable information regarding outcome and prognosis of injured eye.
2. Ferenc Kuhn et al. ^[8] developed a method by which we can predict functional outcome with reasonable certainty by Ocular trauma score (OTS).
3. We correlated our cases of open globe injuries requiring vitreo-retinal intervention with Ocular Trauma Score (OTS).

Materials & Methods: Retrospective samples of 74 eyes with open globe injuries which required vitreo-retinal intervention, from May 2017 to September 2018 was taken for study. Patients with no posterior segment intervention were excluded. The detailed history of trauma and primary intervention was considered for study. After that general ophthalmic examination was done, USG B-scan/CT scan/ X-ray done in appropriate cases. Standard 3

port pars plana vitrectomy with wide angle EIBOS system with 20 G cutter was used. Cataract extraction done by pars plana lensectomy or SICS. An appropriate intravitreal antibiotics was given in cases >24 hrs post trauma - suspected with endophthalmitis. Endolaser & appropriate tamponade given as required. Post operative follow-up was minimum 6 months. Secondary interventions like – re-surgery for RD, secondary IOL, repeat Intravitreal as per need. No case had optical keratoplasty done. Each case was given raw points as per OTS criteria that was divided based on Birmingham Eye Trauma Terminology (BETT) into 4 groups and compared with OTS criteria for calculating likelihood of final visual acuity.(Table 1)

Results: The average age among the cases under study was 30.5 years. The Male to Female ratio was 58:16 and young males were mostly affected. Also, average time of intervention after trauma was 10.4 days (4hrs to 52days). Amongst 74 cases 35.13%(n=26) had endophthalmitis, 37.83%(n=27) had retinal detachment, 6.7%(n=5) had traumatic aniridia and 62.16%(n=46) had traumatic cataract at initial presentation.(Table 2) Most common cause of injury was hammer-chisel (32.43%) and thorn/wooden stick(27%).(Table 3) In our study 54% had penetrating trauma, 29.7% had Intraocular foreign body, 9.5% had perforating injury and 6.75% had globe rupture.(Table 4) In our study 87.83% had visual acuity \leq Hm, 9.47% had visual acuity of 1/60-6/60 and 2.7% had visual acuity of >6/60 at presentation. Overall visual outcome post vitreoretinal intervention showed 35.14% had > 6/60, 50% had 1/60-6/60 and only 14.86% cases had \leq Hm or worse.(Graph 1). Traumatic cataract was the cause of initial poor visual acuity.

Table 1: Distribution of Raw Points.

<i>Variables</i>	<i>Raw points</i>
Initial vision	
NLP	60
PL/HM	70
1/200-19/200	80
20/200-20/50	90
\geq 20/40	100
Rupture	-23
Endophthalmitis	-17
Perforating injury	-14
RD	-11
Aff. pupillary defect	-10

Table 2: Presentations

Endophthalmitis	26 (35.13%)
Retinal detachment	27 (37.83%)
Traumatic aniridia	5 (6.7%)
Traumatic cataract	46(62.16%)

Table 3: Commonest causes of injury among the different cases under study.

Hammer-chisel/stone	24(32.43%)
Thorn/wooden stick	20 (27%)

Table 4: Different study parameters under study.

Parameters	PT (n=40) 54%	IOFB (n=22) 29.7%	PF (n=7) 9.5%	RPT (n=5) 6.75%
Age (yrs)	22.7	32.7	31.6	38.2
M:F ratio	28:12	21:1	7:0	3:2
Commonest Injury type	Thorn/wooden stick 42.5%	Hammer-chisel/stone 68.2%	Iron wire/needle 71.4%	Sugarcane stick 60%

Table 5: Different study variables under study.

Study Variables	PT	IOFB	PF	RPT
Avg OTS	54.92	55.09	41.97	38.42
Endophthal	12 (30%)	11 (50%)	2 (28.5%)	1 (20%)
RD	14 (35%)	9 (40%)	4 (57%)	1 (20%)
Preop Va <=HM	34 (85%)	19 (86.3%)	7 (100%)	5 (100%)
Preop Va>6/60	0	2	0	0
Final Va <=HM	5 (12.5%)	4 (18.1%)	1 (14%)	1 (20%)
Final Va>6/60	13 (32.5%)	8 (36.3%)	3 (42.8%)	2 (40%)

Graph 1:- Comparison between Initial Visual acuity and Final Visual acuity post vitreo retinal intervention.

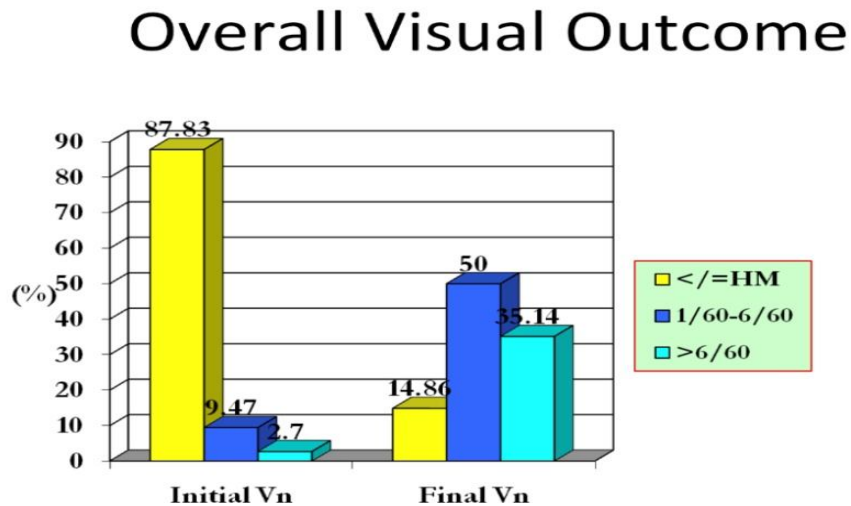


Table 6: Comparison between outcome of our results & F. Kuhn et al as per OTS criteria.

Raw points	OTS	No PL		PL/HM		1/200-19/200		20/200-20/5		>=20/40	
		Kuhn et al (%)	Our result (%)	Kuhn et al (%)	Our result (%)	Kuhn et al (%)	Our result (%)	Kuhn et al (%)	Our result (%)	Kuhn et al (%)	Our result (%)
0-44	1	74	10.5	15	21.5	7	52.6	3	10.5	1	5.2
45-65	2	27	0	26	27.3	18	38.6	15	30	15	4.5
66-80	3	2	0	11	0	15	27.3	31	36.4	41	36.4
81-91	4	1	-	2	-	3	-	22	-	73	-
92-100	5	-	-	1	-	1	-	5	-	94	-

- Statistically significant $p < 0.05$ by test of difference between two proportions
- F.Kuhn et al included all trauma cases including closed globe injuries

Discussion: In our study we compared our final visual acuity with OTS criteria for calculating visual prognosis. OTS aims to estimate a patient's visual acuity 6 months after

injury. Average OTS in study variable 54.92 in penetrating injury, 55.09 in intraocular foreign body, 41.97% in perforating injury and 38.42 in globe rupture cases. The score ranges from 1 (most severe injury and worst prognosis at 6 months follow-up) to 5 (least severe injury and best prognosis at 6 months). None of our cases were in OTS category 4 and 5. F Kuhn et al^[8] reported that patients with an OTS score of 1 have 74% probability of No PL visual acuity. In our study only 10.5% patients had No PL visual acuity and 52.6% patients had better vision between 1/200-19/200 range. Similar discrepancies were also found in two other groups. F Kuhn et al^[8] observed that with an OTS score 2 27% cases would have No PL vision whereas our study found no case with No PL vision instead 38.6% cases with vision between 1/200-19/200 and 30% cases with vision between 20/200-20/50. According to Kuhn OTS 3 category 13% cases had poor visual outcome (\leq PL/HM) and only 46% patients had visual outcome of 1/200-20/50 whereas our study documented no patient with \leq PL/HM vision and 63.7% patients with vision between 1/200-20/50. These differences are statistically significant (Table 6). Our patients had better visual outcome and prognosis. So the predictive accuracy of the conventional OTS system is poor.

Data from our study showed higher incidence of endophthalmitis and retinal detachment at presentation. 60% of our cases had traumatic cataract which accounts for poor visual acuity. Hammer-chisel injury was the most common (68.2%) cause of IOFB, comparable to other studies by Kuhn F et al., Witherspoon C and Jackson Coleman et al.^[8-10] This study revealed that the majority of the cases were young males with the average age being 30 years. So the potential earning group was more commonly affected leading to economic burden to the family. The male preponderance is explained on the basis that men are more commonly involved in agricultural and industrial work. This study found that the average interval between trauma & intervention was 10 days. Delay in seeking medical attention increases the severity of the ocular injury and affects the visual outcome. The causes of delay are illiteracy, ignorance, rural status and poverty. Taking into consideration the ocular morbidity because of trauma in the young wage earner age group, the need for its prevention cannot be over emphasized. In rural area ocular trauma mainly affects agricultural workers and labourers in small scale industries. Mass education regarding measures of prevention of trauma, importance of obtaining immediate treatment and consequences of ocular injuries is necessary.

Conclusion: The conventional OTS scoring system is a useful classification designed to predict visual outcomes in open globe injuries. Our study compared the visual outcome post injury with the OTS predictive value. Our patients had better prognosis and final visual outcome. Even though, the cases included in our study were open globe injuries with posterior segment involvement which makes the situation more complex. We need to modify the raw points recommended in OTS criteria for the Indian scenario on the following basis. The initial visual acuity is underestimated in cases of traumatic cataract (62.16%) which affected the predictive outcome. The existing classification also does not include the delay in seeking medical help or the extension of wound beyond the pars plana and aniridia which has lot of significance in open globe injuries. These need to be added as negative raw points in the scoring system. RAPD cannot be calculated in most cases of open globe injuries, so faulty projection of rays probably would be a better criteria. There is also an inequitable distribution & approachability of health facilities and a lack of awareness in people & referring practitioner about the importance of early intervention. Effective mass education is needed for prevention of ocular injuries and seeking early medical help. Eye care programmes need to consider ocular trauma as a priority in the rural population.

Limitations: There is a need to have a prospective study to avoid shortcomings and limitations inherent to retrospective studies. The proposed changes can be adopted for a further multicenter study as it represents the current scenario of visual prognosis in the Indian population.

Ethical Approval:

As per international standard or university standard written ethical approval has been collected and preserved by the author(s).

References:

1. Kuhn F, Morris R, Witherspoon CD, Heimann K, Jeffers JB, Treister G. A standardized classification of ocular trauma. *Ophthalmology* 1996;103:240-3.
2. Pieramici DJ, Sternberg P Jr., Aaberg TM Sr., Bridges WZ Jr., Capone A Jr., Cardillo JA, et al. A system for classifying mechanical injuries of the eye (globe). The Ocular Trauma Classification Group. *Am J Ophthalmol* 1997;123:820-31.
3. Shukla B, Shukla D. New classification of ocular trauma. In: Garg A, editor. *Clinical Diagnosis and Management of Ocular Trauma*. 1st ed. New Delhi: Jaypee Brothers; 2009. p. 7-9.
4. Xiao JH, Zhang MN, Li SY, Jiang CH, Jiang H, Zhang Y, et al. A new classification for epidemiological study of mechanical eye injuries. *Chin J Traumatol* 2014;17:35-7.
5. Schmidt GW, Broman AT, Hindman HB, Grant MP. Vision survival after open globe injury predicted by classification and regression tree analysis. *Ophthalmology* 2008;115:202-9.
6. Kuhn F, Morris R, Witherspoon CD, Mester V. The Birmingham Eye Trauma Terminology system (BETT). *J Fr Ophtalmol* 2004;27:206-10.
7. Kuhn F, Maisiak R, Mann L, Morris R, Witherspoon C. OTS: Prognosticating the final vision of the seriously injured eye. In: Kuhn F, Pieramici D, editors. *Ocular trauma: principles and practice*. New York: Thieme; 2002. p. 9 – 13.
8. Witherspoon C, Morris R, Phillips R, Kuhn F, Nelson S, Witherspoon R. Severe combined anterior and posterior segment trauma. In: Kuhn F, Pieramici D, editors. *Ocular trauma: principles and practice*. New York: Thieme; 2002. p. 264 – 72.
9. Jackson Coleman et al. Management of Intraocular Foreign Bodies; *Ophthalmology* December 1987. Vol-94 No. 12:1647-1653