

Comparison of complication regarding modified Duhamel procedure for Hirschsprung's disease in male to female children

ABSTRACT

Aim: To compare the complications regarding modified Duhamel procedure in male to female children for Hirschsprung's disease (HSCR). **Methodology:** This comparative retrospective study was done at pediatric surgery department PUMHSW Nawabshah during Jun 2019-Aug 2020. Sample size was selected as 70 patients and divided it into two groups. Group A contain 45 male children while group B also consists of 25 female children. The children between the age of 2-15 year, both sexes and confirm Hirschsprung's disease was included in this study while the children below 2 years. The study was approved by ethical review board PUMHSW Nawabshah. Written informed consent was obtained from parents or guardians of the participants. **Results:** There were 64.28% (n=45) male and 35.72% (25) female patients (Fig 1). The mean weight of patients in male was 17.8 ± 7.6 kg while in female was 15.6 ± 6.27 kg (Fig 2). In the distribution of patients by complications, anorectal stenosis was present in 13.33% (n=6) in male while 12% (n=3) in female children. Wound infection was present in 8.88% (n=4) in male and 8% (n=2) in female children. Intestinal obstruction was present in 11.11% (n=5) and 12% (n=3) in male and female children respectively. **Conclusion:** It was concluded that modified Duhamel Procedure for Hirschsprung's disease has less postoperative complications in both male and females moreover there is no significant difference of postoperative complications in both sexes.

Keywords: Duhamel procedure, Hirschsprung's Disease, Constipation, Enterocolitis

1. INTRODUCTION

Constipation is one of the most common gastrointestinal problems in children. Constipation occurs when the colon absorbs too much of water or if the contraction of colonic muscle are slow or sluggish, causing the stool to move through the colonic too slowly, as a result stool become hard and dry^{1,2}. Hirschsprung's Disease (HD) is a congenital condition, which is characterized by the absence of Ganglion cells in submucosal (Meissner's) plexus and the intermuscular (Auerbach's) plexus^{3,4}. Hirschsprung's Disease is actually caused by the failure of vagal neural crest cells to migrate distally from upper and of alimentary tract or due to failure of maturation or degeneration of neural cells in altered micro environment⁵. Hirschsprung's Disease the incidence is 1: 5000 births. It is 4 times more common in boys than in girls.⁶ Older children typically present with chronic constipation, abdominal distention, emesis and failure to thrive. Some of them patient present with Enterocolitis.⁷ Initial diagnosis for workup of HD is constrict enema, the classic finding is transition zone.⁸ After diagnosis surgery is normally the treatment option in the form of different pull through procedures, most of them being two stage procedures. The complication rate generally range from 4-16%.⁹ In 1956 Bernard Duhamel first described retrorectal dissection with pull through of ganglionic colon and anastomosis of both ganglionic and aganglionic parts¹⁰. This procedure is further modified using gastrointestinal stapler (GIA) to create anastomosis. The long term outcome of this procedure depends on level of retrorectal incision and length of blind rectal pouch¹¹. The aim of this study is to know the early post operative complications of this procedure in male and female child.

2. MATERIAL AND METHODS

This study was done at pediatric surgery department PUMHSW Nawabshah during Jun 2019-Aug 2020. Sample size was selected as 70 patients and divided it into two group. Group A contain 45 male children while group B consists of 25 female children. The children between the age of 2-15 year, both sexes and confirm Hirschsprung's disease was included in this study while the children below 2 years and with comorbidity were excluded from the study. Anastomosis was done with the help of 75mm GIA linear cutting stapler. A drain was placed through the anastomosis in the pulled through segment. Follow up was done till ninety days postoperatively.

3. RESULTS

The mean age of the patients was 6.2 ± 3.1 years and 5.9 ± 2.6 years in male and female children respectively. There were 64.28% (n=45) male and 35.72% (25) female patients (Fig 1). The mean weight of patients in male was 17.8 ± 7.6 kg while in female was 15.6 ± 6.27 kg (Fig 2). In the distribution of patients by complications, anorectal stenosis was present in 13.33% (n=6) in male while 12% (n=3) in female children. Wound infection was present in 8.88% (n=4) in male and 8% (n=2) in female children. Intestinal obstruction was present in 11.11% (n=5) and 12% (n=3) in male and female children respectively. Constipation was present in 15.55% in male while 16% (n=4) in female children. Enterocolitis was found in 51.11% (n=23) in male and 52% (n=13) in female children (Table 1).

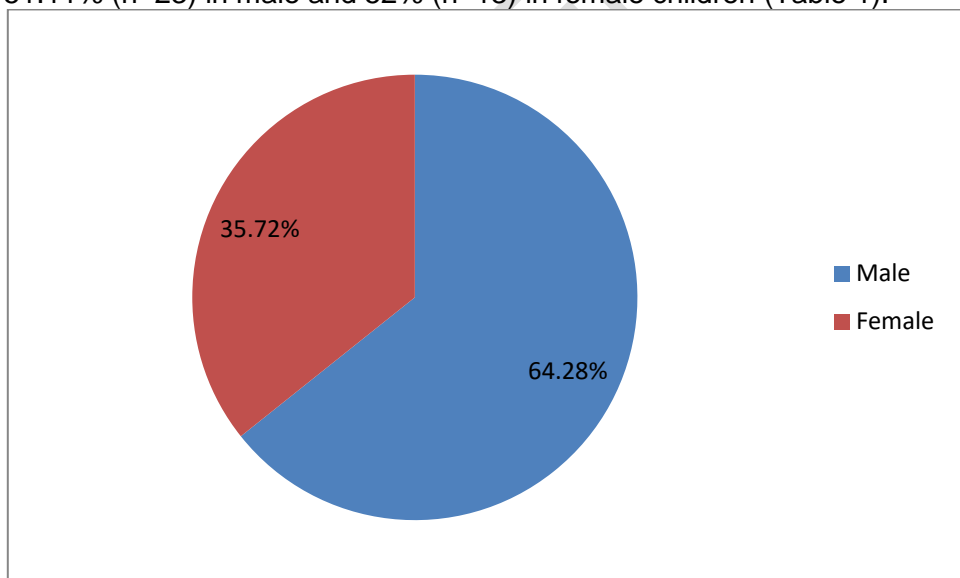


Figure 1 Distribution of patients by sex

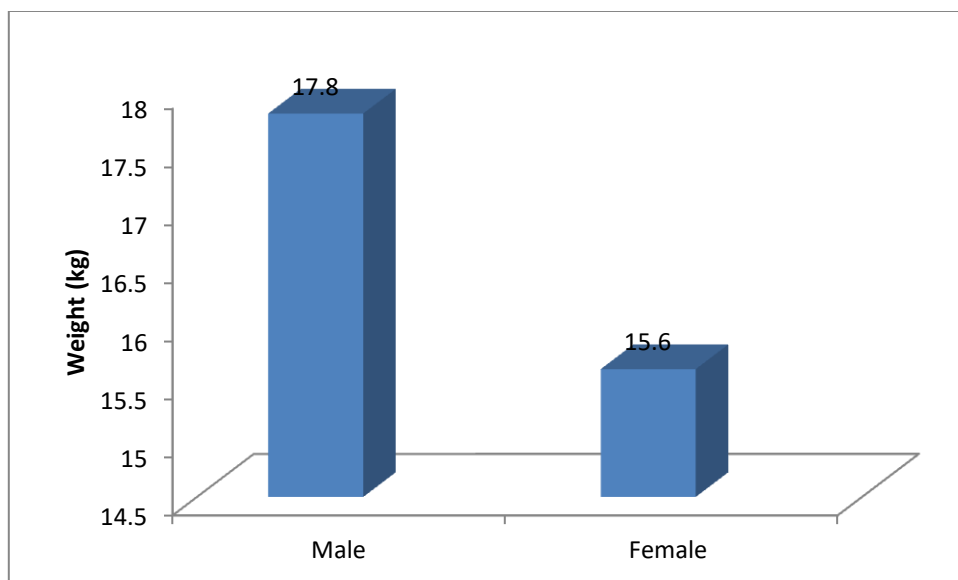


Figure 2 Weight of Male and female children

Table 1: Distribution of patients by Complications (n=70)

Complications	Male (n=45)		Female (n=25)		P value
	No.	%age	No.	%age	
Anorectal stenosis	6	13.33	3	12	0.43
Wound infection	4	8.88	2	8	0.51
Intestinal obstruction	5	11.11	3	12	0.49
Constipation	7	15.55	4	16	0.53
Enterocolitis	23	51.11	13	52	0.49

4. DISCUSSION

The Duhamel Procedure is widely used for definitive treatment of Hirschsprungs disease. Hirschsprungs disease is a congenital disorder characterized by the absence of ganglion cells in the distal bowel, which results in functional obstruction, most commonly in the newborn period. Although many types of pull through procedures have been described, the most commonly performed operations in North America have been the Swenson, Duhamel, and soave (or endorectal) pullthrough) procedures. Clinical presentation is variable, newborns present with failure to pass meconium with distended abdomen and bilious vomiting. About 98% of full term newborn pass meconium within 48 hours but these children has history of delayed passage. The features like fecal incontinence, fecal urgency and stool withholding behavior are usually not present in HD while it is common in functional constipation.^{12,13}

In our study there were 64.28% male and 35.72% female patients. As compared with the study of Mirza et al there were 70.6% male and 29.4% female patients¹². The results of our study are comparable with other national and international studies. In our study Modified Duhamel Procedure was performed in 70 patients. Out of them 25 Patients (35.72%) were females. According to Saadai 128 male to female ratio in classic Hirschsprung Disease is 4:1 in favor of males. So in both studies males are affected more than females⁶.

Handaya et al, performed modified Duhamel procedure and his result were very similar to our series. 16.6% of their patients developed enterocolitis while in our study it was observed 51.5% and 52% in male and female children respectively, which is in contrast with the above study¹⁴. In our study wound infection was found in 8.88 and 8% in male and female children respectively. As compared with another study wound infection was found in 17.60% patients¹⁵. In our study intestinal obstruction was found in 11.11% in male while 12% in female children. As compared with another study Intestinal obstruction was found in 5.8% patients¹⁶. In our study enterocolitis was found in 50.7% Patients. As compared with other study enterocolitis was found in 11.6% patients⁸.

4. CONCLUSION

It was concluded that modified Duhamel Procedure for Hirschsprung's disease has less postoperative complications in both male and females moreover there is no significant difference of postoperative complications in both sexes.

ETHICAL APPROVAL AND CONSENT

The study was approved by ethical review board PUMHSW Nawabshah. Written informed consent was obtained from parents or guardians of the participants.

COMPETING INTERESTS

Authors have declared that no competing interests exist.”.

AUTHORS' CONTRIBUTIONS

All work has been done by MAS”

REFERENCES

1. Sakurai T, Tanaka H, Endo N. Predictive factors for the development of postoperative Hirschsprung-associated enterocolitis in children operated during infancy. *Pediatric Surgery International*. 2021 Feb;37(2):275-80.
2. Pruitt LC, Skarda DE, Rollins MD, Bucher BT. Hirschsprung-associated enterocolitis in children treated at US children's hospitals. *Journal of pediatric surgery*. 2020 Mar 1;55(3):535-40.
3. Blackman AC, Anvari S, Davis CM, Anagnostou A. Emerging triggers of food protein-induced enterocolitis syndrome: lessons from a pediatric cohort of 74 children in the United States. *Annals of Allergy, Asthma & Immunology*. 2019 Apr 1;122(4):407-11.

4. Ambartsumyan L, Smith C, Kapur RP. Diagnosis of Hirschsprung disease. *Pediatric and Developmental Pathology*. 2020 Jan;23(1):8-22.
5. Heuckeroth RO. Hirschsprung disease—integrating basic science and clinical medicine to improve outcomes. *Nature Reviews Gastroenterology & Hepatology*. 2018 Mar;15(3):152-67.
6. Saadai P, Trappey AF, Goldstein AM, Cowles RA, De La Torre L, Durham MM, Huang EY, Levitt MA, Rialon K, Rollins M, Rothstein DH. Guidelines for the management of postoperative soiling in children with Hirschsprung disease. *Pediatric Surgery International*. 2019 Aug;35(8):829-34.
7. Dai Y, Deng Y, Lin Y, Ouyang R, Li L. Long-term outcomes and quality of life of patients with Hirschsprung disease: a systematic review and meta-analysis. *BMC gastroenterology*. 2020 Dec;20(1):1-3.
8. Youn JK, Yang HB, Ko D, Park KW, Jung SE, Kim HY. Comparison of long-term outcome according to involved aganglionic segments of total colonic aganglionosis. *Medicine*. 2021 Oct 10;100(40).
9. Davidson JR, Mutanen A, Salli M, Kyrklund K, De Coppi P, Curry J, Eaton S, Pakarinen MP. Comparative cohort study of Duhamel and endorectal pull-through for Hirschsprung's disease. *BJS open*. 2022 Feb;6(1):zrab143.
10. Fahmy MA, Abd El Hamid SA, Elsamahy OM, Mohammed HM. Comparative study between transanal endorectal pull-through and modified Duhamel's procedure in management of Hirschsprung's disease. *The Egyptian Journal of Hospital Medicine*. 2019 Jan 1;74(3):679-83.
11. Hosseinpour M, Ahmadi B, Etezazian S. Mechanical Bowel Preparation versus No Preparation in Duhamel Procedure in Children with Hirschsprung's Disease. *European Journal of Pediatric Surgery*. 2020 Apr;30(02):201-4.
12. Mirza MA, Askari MR, Maqbool S, Ahmad S. Modified duhamel procedure;: our experience for early complication at the children hospital & the institute of child health, Faisalabad. *The professional medical journal*. 2018 aug 4;25(08):1147-50.
13. Hasan Z, Kumar V, Yadav R, Thakur VK, Chaubey D, Rahul SK, Prasad R, Kumar D, Pallavi K. Loop Colostomy Versus End Colostomy for Initial Stage Surgery in Children With Hirschsprung's Disease. *Journal of Indira Gandhi Institute Of Medical Sciences*. 2019 Jan 1;5(1):39.
14. Handaya AY, Fauzi AR, Andrew J, Hanif AS. Modified Duhamel with lateral anal sphincterotomy and coloanal stump for adult Hirschsprung's disease: A case series. *International Journal of Surgery Case Reports*. 2020 Jan 1;77:174-7.
15. Yokota K, Uchida H, Tainaka T, Tanaka Y, Shiota C, Hinoki A, Kato T, Sumida W, Oshima K, Chiba K, Ishimaru T. Single-stage laparoscopic transanal pull-through modified Swenson procedure without leaving a muscular cuff for short-and long-type Hirschsprung disease: a comparative study. *Pediatric Surgery International*. 2018 Oct;34(10):1105-10.
16. Aravind KL, Nisha N, Sushmitha R, Madiwal C. Duhamel's procedure for Hirschsprung's disease and the functional outcome in a tertiary care center. *Indian Journal of Child Health*. 2021 Feb 19;8(1):51-5.
- 17.