

Frequency Of Multiple Canals In Mandibular Premolars And Its Correlation With Other Anatomical Variants (C Shaped Canals In Mandibular Second Molars): A Retrospective and cross-sectional study

Abstract

Introduction

Recognition of variations in molar root morphology is critically important for dental procedures such as root canal treatment and apical surgery. Usage of CBCT enables systemic evaluation of teeth including the number of roots and canals, location of roots, etc. The aim of this study was to determine the frequency of multiple canals in mandibular first and second premolars and to evaluate correlations between other anatomical variants using Cone beam computed tomography (CBCT).

Methodology

The protocol of this retrospective, cross-sectional study was approved by the Ethics Committee of Saveetha Dental Hospital, Chennai, India. Images of mandibular premolars were obtained from patients who had undergone CBCT scanning at the hospital between January 2018 and November 2020. Cross-sectional images in the axial, coronal, and sagittal planes were reconstructed using GALILEOS Comfort^{PLUS} (Sirona 3D) is an advanced CBCT that provides seamless workflow integration. Serial axial, coronal and sagittal-plane CBCT images were closely examined at 1.0-mm intervals from the canal orifice to the apex.

Results

Using SPSS software (ver. 21; SPSS, Inc., Chicago, IL, USA), chi-squared test was performed for analyses of different parameters involved. Various anatomical variants such as

distolingual roots of first molars, C shaped canals of second molars are highly correlated with different canal configurations of mandibular premolars.

Conclusion

This retrospective study showed that different configurations of mandibular premolars canals was significantly correlated with the presence of Distolingual root (DLRs) in first molars, and C shaped canals in second molars. Understanding and identifying anatomical variants is important in comprehensive success of endodontic treatment.

Keywords: Canal variations, CBCT, Anatomic variants, C shaped roots, Distolingual roots, Multiple canal configuration.

Introduction

Recognition of variations in molar root morphology is crucial for dental procedures such as root canal treatment and apical surgery. Adequate knowledge regarding anatomical variants of canal helps in achieving success in root canal treatment. [1,2] Mandibular premolars are known as enigma to endodontists as it exhibits enormous variations in canal morphology.[3,4] "Previous studies have shown high frequencies of multiple canal systems in mandibular premolars (12.9–34.8% and 2–9.9% in mandibular first and second premolars, respectively). These variations are caused by differences in methodology, ethnicity, and characteristics of participants, such as age and gender." [5,6]

“Permanent mandibular first molars usually have 2 roots, mesial and distal. Later, a third root, distolingual (DL) root, develops in a number of individuals. Literature reviews have shown the high prevalence of 3-rooted mandibular first molar from 5% to more than 40% in Asian populations” [7-10]. Therefore, it would be advantageous for CBCT usage in many treatments.

“In the routine diagnostic periapical radiograph, the X ray cone tube is placed perpendicular to the mandibular first molar and the film. Therefore, the image of the DL root is easily super-imposed by the distobuccal (DB) root, and it is unclear.” [1,11]

“Recently introduced Cone- beam computed tomography (CBCT) is designed for dental use and serves as noninvasive and 3-dimensional reconstruction imaging. CBCT images can be used to evaluate morphologic analysis of the DL root of the permanent mandibular first molars” [12,13]. “In apical surgery, the use of CBCT enables systematic evaluation of teeth in all manners. Previously, our team had a rich experience in working on various research projects across multiple disciplines” [14–28] Now the growing trend in this area motivated us to pursue this project.

The goal of this research was to determine the frequency and morphologic characteristics of multiple canals of mandibular first and second premolars using Cone beam computed tomography (CBCT).

Methodology

Study design

The protocol of this retrospective, cross-sectional study was approved by the Ethics Committee of Saveetha Dental Hospital, Chennai, India. Images of mandibular premolars were obtained from patients who had undergone CBCT scanning at the hospital between January 2018 and November 2020. CBCT images were acquired with the following parameters: 80 kVp, 9.0 mA, 10 × 10-cm field of view, 0.167-mm³ voxel size, and the slice thickness was 1.0 mm.

Sample size

100 patients were examined **in vivo by CBCT. The inclusion criteria applied were the patients aged between 18 and 70 years; presence of mandibular premolars with fully matured apices and without apical** periodontitis; presence of mandibular premolars without root canal fillings, posts, and crown restorations, patients undergoing orthodontic treatment and patients with calcified canals. The Vertucci classification and the Fan classification will be used to define root canal configurations and C-shaped canals, respectively. In a logistic regression study, the connection between non-single canals in PM1s and DLRs in M1s was employed.

Image Assessment

Cross-sectional images in the axial, coronal, and sagittal planes were reconstructed using GALILEOS Comfort^{PLUS} (Sirona 3D). Implant surgery or surgical removal of impacted molars were the most common reasons for CBCT scans. As a result, no subjects in this study were subjected to excessive radiation in order to gather information about root canal anatomy; also, the "as low as reasonably achievable" principle was applied to radiation dose. To

avoid any possible bias, data were anonymised by numbering the participants from 1 to 300 before examining the images.

Axial-plane images were used to determine the number of roots in premolars. Single-rooted teeth, such as teeth with two canals and a fused root, had conical-shaped roots. Teeth with two canals in a single fused root and a third canal in a separate root showed bifurcation at a particular root level, as did teeth with two canals in a single fused root and a third canal in a separate root. Teeth with three independent roots were known as triple-rooted teeth. C-shaped canal configurations were determined in accordance with the Fan classification as follows: C1 (continuous C-shaped canal: an uninterrupted “C” without separation or division); C2 (semicolon-shaped canal: caused by discontinuation of the “C” outline); C3 (separated canals: two or three separate canals); C4 (a single canal subdivided into round (C4a), oval (C4b), or flat canals (C4c)); C5 (≥ 3 separate canals); or C6 (no visible canal lumen).[29]

Statistical analysis

Statistical analyses were performed using SPSS software (ver. 21; SPSS, Inc., Chicago, IL, USA). The chi-squared test was performed for analyses of differences based on sex, and premolar canal configurations. The chi-squared test was also used to compare the frequencies of disto lingual roots in first molars and C- shaped canals in second molars according to premolar root canal configuration and to compare unilateral and bilateral molar DLRs and C-shaped canal configurations.

Results

Among 100 patients (52 women and 48 men; mean age, 25.61 ± 10.02 years), a total of 460 premolars were examined (232 first premolars and 228 second premolars). The majority of premolars had one root (95.9%) and one canal (76.78%).

The respective frequencies of DLRs in first molars and C-shaped canals in second molars were 28.4% and 32.8%. Chi-squared analysis revealed that the frequency of molar DLRs varied significantly according to premolar root canal configuration ($p < 0.05$).

Discussion

“The primary goal of endodontic treatment often got vulnerable because of the complexity of the root canal anatomy and lack of its knowledge and clinical challenges raised because of it. Thus, for any endodontic therapy, one must precede with a thorough knowledge of pulp chamber and root canal configuration and number of canals as the success of the therapy is directly related to the elimination, prevention of microbial contamination, and complete disinfection by the proper endodontic procedure.”[30,31]

“The mandibular first molar is the first posterior tooth that erupts in the oral cavity and frequently requires root canal treatment. This tooth has two roots, but occasionally, it has three roots with two or three canals in the mesial root and one, two, or three canals in the distal root. Over the years, there have been numerous reports that described the morphology of teeth including mandibular first molar.” [32,33] The major variant in this

group is the mandibular molar with five, six, and seven canals. According to Martinez-Berna and Badanellis, who reported a mandibular molar with six canals, three in the mesial root that were independent throughout the root and three canals in distal root with independent orifices in the pulpal floor but join immediately to form two canals. Ghoddusi et al. also reported “a mandibular molar with four distal canals. The intracanal communication frequency is higher in the mesial root of mandibular molars which make the variant morphology and so the disinfection more difficult to achieve. Cohen and Burns described maxillary first molar as “The most treated, but least understood posterior tooth with the highest endodontic failure rate.” It reported that many treatment failures in the maxillary permanent first molar were related to the inability to locate and clean the MB canal.” [34,35]

“The significance of advanced diagnostic tools such as dental operating microscope (DOM) and cone-beam computed tomography (CBCT) over the traditional diagnostic tools has been proven by various researchers till now. CBCT assists the practitioner to identify canal morphology, numbers of canals, and relative positioning even in the presence of calcific metamorphosis and dystrophic calcifications. Identification and treatment of lateral canals are supported by viewing their specific location with the use of narrow field of view CBCT before or during endodontic therapy.” [36,37]

“The C-shaped canal configuration presents with variations in both the number and location of the canal(s), as the canal(s) courses from the coronal to the apical third. The complexity of this canal configuration proves to be a challenge with respect to debridement

and obturation, and possibly the prognosis during root canal therapy. Recognition of a C-shaped canal configuration before treatment can facilitate effective management, which will prevent irreparable damage that may put the tooth in severe jeopardy.” [38,39] “The C-shaped canal configuration shows an ethnic predilection. It has frequently been reported in countries belonging to the Asian continent. East Asian population groups like the Chinese (0.6%-41.27%) and Koreans (31.3%-45.5%) display a high prevalence of this variant. Among the South Asian countries, Burmese population showed a prevalence of 22.4%, which was much higher than the Indian, Thai or Sri Lankan population. Higher incidence of C-shaped anatomy was documented in Lebanese population (19.1%) as compared to the other West Asian population groups (Iranian, Jordanian, Saudi Arabian).” [39,40]

“The frequency of first premolars with a single canal (760 of 971, 78.27%) was comparable to those reported in two systematic reviews (75.8 and 73.55%) as well those reported in East Asian populations (e.g., Chinese and Taiwanese [65.2– 87.1%]). Regarding the root canal morphology of second premolars, a recent review reported a markedly lower incidence of a second canal (2%) in East Asian populations compared with other populations. Our institution is passionate about high quality evidence based research and has excelled in various fields” [18,41–50]

The thorough knowledge of root canal space anatomy is a basic prerequisite for the successful completion of endodontic treatment, especially in cases where extra root canals are suspected. Proper care and attention must be given in identifying extra roots and canals.

Clinical significance

A thorough knowledge regarding anatomical variants may result in treating all canals space, potentially paving to higher endodontic treatment success rate .Thus, understanding the canal variations and morphology is crucial in success of endodontic treatment in clinical practice

Conclusion

This retrospective study showed that different configurations of mandibular premolars canals were significantly correlated with the presence of DLRs in first molars, and C shaped canals in second molars. Understanding and identifying anatomical variants is important in comprehensive success of endodontic treatment.

Ethical Approval:

As per international standard or university standard written ethical approval has been collected and preserved by the author(s).

Consent

As per international standard or university standard, patients' written consent has been collected and preserved by the author(s).

COMPETING INTERESTS DISCLAIMER:

Authors have declared that no competing interests exist. The products used for this research are commonly and predominantly use products in our area of research and country. There is absolutely no conflict of interest between the authors and producers of the products because we do not intend to use these products as an avenue for any litigation but for the advancement of knowledge. Also, the research was not funded by the producing company rather it was funded by personal efforts of the authors.

References

- [1] Song JS, Choi H-J, Jung I-Y, Jung H-S, Kim S-O. The prevalence and morphologic classification of distolingual roots in the mandibular molars in a Korean population. *J Endod* 2010;36:653–7.
- [2] Kim Y, Roh B-D, Shin Y, Kim BS, Choi Y-L, Ha A. Morphological Characteristics and Classification of Mandibular First Molars Having 2 Distal Roots or Canals: 3-Dimensional Biometric Analysis Using Cone-beam Computed Tomography in a Korean Population. *Journal of Endodontics* 2018;44:46–50. <https://doi.org/10.1016/j.joen.2017.08.005>.
- [3] Kim S-Y, Yang S-E. Cone-Beam Computed Tomography Study of Incidence of Distolingual Root and Distance from Distolingual Canal to Buccal Cortical Bone of Mandibular First Molars in a Korean Population. *Journal of Endodontics* 2012;38:301–4. <https://doi.org/10.1016/j.joen.2011.10.023>.
- [4] Kim H-S, Jung D, Lee H, Han Y-S, Oh S, Sim H-Y. C-shaped root canals of mandibular second molars in a Korean population: a CBCT analysis. *Restorative Dentistry & Endodontics* 2018;43. <https://doi.org/10.5395/rde.2018.43.e42>.
- [5] Wang Y, Zheng Q-H, Zhou X-D, Tang L, Wang Q, Zheng G-N, et al. Evaluation of the root and canal morphology of mandibular first permanent molars in a western Chinese population by cone-beam computed tomography. *J Endod* 2010;36:1786–9.
- [6] Zheng Q-H, Wang Y, Zhou X-D, Wang Q, Zheng G-N, Huang D-M. A Cone-Beam Computed Tomography Study of Maxillary First Permanent Molar Root and Canal Morphology in a Chinese Population. *Journal of Endodontics* 2010;36:1480–4. <https://doi.org/10.1016/j.joen.2010.06.018>.

- [7] Zheng Q, Zhang L, Zhou X, Wang Q, Wang Y, Tang L, et al. C-shaped root canal system in mandibular second molars in a Chinese population evaluated by cone-beam computed tomography. *International Endodontic Journal* 2011;44:857–62. <https://doi.org/10.1111/j.1365-2591.2011.01896.x>.
- [8] Zhou Z, Yang Z, Lu K, Wang F, Li Y. Cone-beam computed tomography study of the root and canal morphology of mandibular permanent anterior teeth in a Chongqing population. *Therapeutics and Clinical Risk Management* 2015;19. <https://doi.org/10.2147/tcrm.s95657>.
- [9] Nur BG, Ok E, Altunsoy M, Aglarci OS, Colak M, Gungor E. Evaluation of the root and canal morphology of mandibular permanent molars in a south-eastern Turkish population using cone-beam computed tomography. *European Journal of Dentistry* 2014;08:154–9. <https://doi.org/10.4103/1305-7456.130584>.
- [10] Tu M-G, Tsai C-C, Jou M-J, Chen W-L, Chang Y-F, Chen S-Y, et al. Prevalence of three-rooted mandibular first molars among Taiwanese individuals. *J Endod* 2007;33:1163–6.
- [11] Chen Y-C, Lee Y-Y, Pai S-F, Yang S-F. The morphologic characteristics of the distolingual roots of mandibular first molars in a Taiwanese population. *J Endod* 2009;35:643–5.
- [12] Moor RJGD, De Moor RJG, Deroose CAJ, Calberson FLG. The radix entomolaris in mandibular first molars: an endodontic challenge. *International Endodontic Journal* 2004;37:789–99. <https://doi.org/10.1111/j.1365-2591.2004.00870.x>.
- [13] Calberson FL, De Moor RJ, Deroose CA. The Radix Entomolaris and Paramolaris: Clinical Approach in Endodontics. *Journal of Endodontics* 2007;33:58–63.

<https://doi.org/10.1016/j.joen.2006.05.007>.

- [14] Govindaraju L, Gurunathan D. Effectiveness of Chewable Tooth Brush in Children-A Prospective Clinical Study. *J Clin Diagn Res* 2017;11:ZC31-4.
- [15] Christabel A, Anantanarayanan P, Subash P, Soh CL, Ramanathan M, Muthusekhar MR, et al. Comparison of pterygomaxillary dysjunction with tuberosity separation in isolated Le Fort I osteotomies: a prospective, multi-centre, triple-blind, randomized controlled trial. *Int J Oral Maxillofac Surg* 2016;45:180-5.
- [16] Soh CL, Narayanan V. Quality of life assessment in patients with dentofacial deformity undergoing orthognathic surgery--a systematic review. *Int J Oral Maxillofac Surg* 2013;42:974-80.
- [17] Mehta M, Deeksha, Tewari D, Gupta G, Awasthi R, Singh H, et al. Oligonucleotide therapy: An emerging focus area for drug delivery in chronic inflammatory respiratory diseases. *Chem Biol Interact* 2019;308:206-15.
- [18] Ezhilarasan D, Apoorva VS, Ashok Vardhan N. Syzygium cumini extract induced reactive oxygen species-mediated apoptosis in human oral squamous carcinoma cells. *J Oral Pathol Med* 2019;48:115-21.
- [19] Campeau PM, Kasperaviciute D, Lu JT, Burrage LC, Kim C, Hori M, et al. The genetic basis of DOORS syndrome: an exome-sequencing study. *Lancet Neurol* 2014;13:44-58.
- [20] Kumar S, S S. Knowledge and awareness regarding antibiotic prophylaxis for infective endocarditis among undergraduate dental students. *Asian J Pharm Clin Res* 2016:154.
- [21] Christabel SL. Prevalence of type of Frenal Attachment and morphology of frenum in children, Chennai, Tamil Nadu. *World J Dent* 2015;6:203-7.
- [22] Kumar S, Rahman R. Knowledge, awareness, and practices regarding biomedical waste

- management among undergraduate dental students. *Asian J Pharm Clin Res* 2017;10:341.
- [23] Sridharan G, Ramani P, Patankar S. Serum metabolomics in oral leukoplakia and oral squamous cell carcinoma. *J Cancer Res Ther* 2017;13:556–61.
- [24] Ramesh A, Varghese SS, Doraiswamy JN, Malaiappan S. Herbs as an antioxidant arsenal for periodontal diseases. *J Intercult Ethnopharmacol* 2016;5:92–6.
- [25] Thamaraiselvan M, Elavarasu S, Thangakumaran S, Gadagi JS, Arthie T. Comparative clinical evaluation of coronally advanced flap with or without platelet rich fibrin membrane in the treatment of isolated gingival recession. *J Indian Soc Periodontol* 2015;19:66–71.
- [26] Thangaraj SV, Shyamsundar V, Krishnamurthy A, Ramani P, Ganesan K, Muthuswami M, et al. Molecular Portrait of Oral Tongue Squamous Cell Carcinoma Shown by Integrative Meta-Analysis of Expression Profiles with Validations. *PLoS One* 2016;11:e0156582.
- [27] Ponnulakshmi R, Shyamaladevi B, Vijayalakshmi P, Selvaraj J. In silico and in vivo analysis to identify the antidiabetic activity of beta sitosterol in adipose tissue of high fat diet and sucrose induced type-2 diabetic experimental rats. *Toxicol Mech Methods* 2019;29:276–90.
- [28] Fluoride, fluoridated toothpaste efficacy and its safety in children - review. *Int J Pharm Res* 2018;10. <https://doi.org/10.31838/ijpr/2018.10.04.017>.
- [29] C-shaped canals. *Dent Abstr* 2008;53:15–7.
- [30] Cotton TP, Geisler TM, Holden DT, Schwartz SA, Schindler WG. Endodontic applications of cone-beam volumetric tomography. *J Endod* 2007;33:1121–32.

- [31] Patel S, Dawood A, Pitt Ford T, Whaites E. The potential applications of cone beam computed tomography in the management of endodontic problems. *International Endodontic Journal* 2007;40:818–30. <https://doi.org/10.1111/j.1365-2591.2007.01299.x>.
- [32] Tu M-G, Huang H-L, Hsue S-S, Hsu J-T, Chen S-Y, Jou M-J, et al. Detection of permanent three-rooted mandibular first molars by cone-beam computed tomography imaging in Taiwanese individuals. *J Endod* 2009;35:503–7.
- [33] Patel S, Harvey S, Shemesh H, Durack C. *Cone Beam Computed Tomography in Endodontics*. Quintessenz Verlag; 2019.
- [34] Patel S, Dawood A, Mannocci F, Wilson R, Pitt Ford T. Detection of periapical bone defects in human jaws using cone beam computed tomography and intraoral radiography. *International Endodontic Journal* 2009;42:507–15. <https://doi.org/10.1111/j.1365-2591.2008.01538.x>.
- [35] Patel S, Dawood A, Whaites E, Pitt Ford T. New dimensions in endodontic imaging: part 1. Conventional and alternative radiographic systems. *International Endodontic Journal* 2009;42:447–62. <https://doi.org/10.1111/j.1365-2591.2008.01530.x>.
- [36] Matherne RP, Angelopoulos C, Kulild JC, Tira D. Use of cone-beam computed tomography to identify root canal systems in vitro. *J Endod* 2008;34:87–9.
- [37] Kalaitzoglou ME, Kantilieraki E, Beltes C, Angelopoulos C, Beltes P. Second Root Canal in Mandibular Incisors: an Ex Vivo Cone-Beam Computed Tomography (CBCT) Study. *Balkan Journal of Dental Medicine* 2018;22:38–42. <https://doi.org/10.2478/bjdm-2018-0007>.
- [38] Fernandes M, de Ataíde I, Wagle R. C-shaped root canal configuration: A review of

- literature. J Conserv Dent 2014;17:312–9.
- [39] Kirilova J, Topalova-Pirinska S. C-SHAPED CONFIGURATION OF THE ROOT CANAL SYSTEM – PROBLEMS AND SOLUTIONS. Journal of IMAB - Annual Proceeding (Scientific Papers) 2014;20:504–9. <https://doi.org/10.5272/jimab.2014201.504>.
- [40] Ali S, Bansal P, Nikhil V, Goyal A, Hasnain M. Incidence of C-shaped canal configuration in mandibular first premolars: A cone-beam computed tomography analysis. Endodontology 2018;30:125. https://doi.org/10.4103/endo.endo_113_17.
- [41] Vijayashree Priyadharsini J. In silico validation of the non-antibiotic drugs acetaminophen and ibuprofen as antibacterial agents against red complex pathogens. J Periodontol 2019;90:1441–8.
- [42] Pc J, Marimuthu T, Devadoss P. Prevalence and measurement of anterior loop of the mandibular canal using CBCT: A cross sectional study. Clin Implant Dent Relat Res 2018.
- [43] Ramesh A, Varghese S, Jayakumar ND, Malaiappan S. Comparative estimation of sulfiredoxin levels between chronic periodontitis and healthy patients - A case-control study. J Periodontol 2018;89:1241–8.
- [44] Ramadurai N, Gurunathan D, Samuel AV, Subramanian E, Rodrigues SJL. Effectiveness of 2% Articaine as an anesthetic agent in children: randomized controlled trial. Clin Oral Investig 2019;23:3543–50.
- [45] Sridharan G, Ramani P, Patankar S, Vijayaraghavan R. Evaluation of salivary metabolomics in oral leukoplakia and oral squamous cell carcinoma. J Oral Pathol Med 2019;48:299–306.
- [46] Mathew MG, Samuel SR, Soni AJ, Roopa KB. Evaluation of adhesion of Streptococcus

mutans, plaque accumulation on zirconia and stainless steel crowns, and surrounding gingival inflammation in primary molars: Randomized controlled trial. Clin Oral Investig 2020;1–6.

- [47] Samuel SR. Can 5-year-olds sensibly self-report the impact of developmental enamel defects on their quality of life? Int J Paediatr Dent 2021;31:285–6.
- [48] R H, Hannah R, Ramani P, Ramanathan A, R JM, Gheena S, et al. CYP2 C9 polymorphism among patients with oral squamous cell carcinoma and its role in altering the metabolism of benzo[a]pyrene. Oral Surgery, Oral Medicine, Oral Pathology and Oral Radiology 2020;130:306–12. <https://doi.org/10.1016/j.oooo.2020.06.021>.
- [49] Chandrasekar R, Chandrasekhar S, Sundari KKS, Ravi P. Development and validation of a formula for objective assessment of cervical vertebral bone age. Prog Orthod 2020;21:38.
- [50] Vijayashree Priyadharsini J, Smiline Girija AS, Paramasivam A. In silico analysis of virulence genes in an emerging dental pathogen A. baumannii and related species. Arch Oral Biol 2018;94:93–8.

Tables

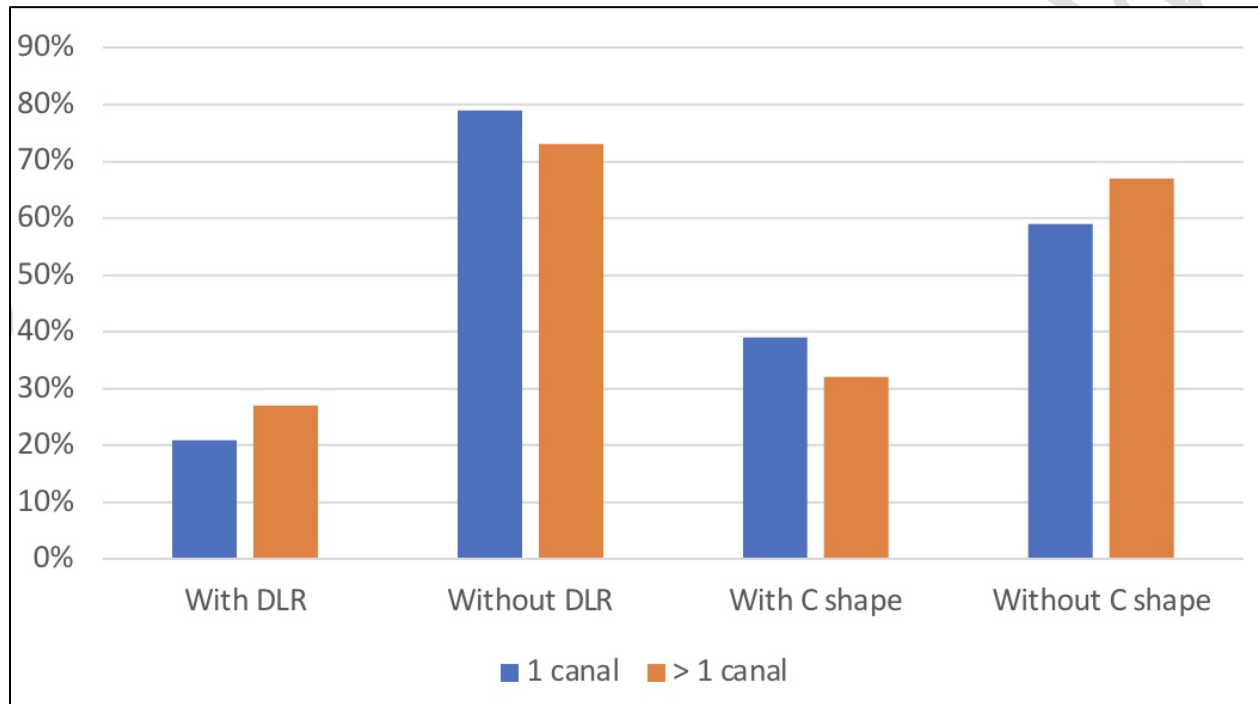
Table 1 : Frequencies of the root and root canal configurations of mandibular premolars

Number of roots	Number of canals	Mandibular first premolar	Mandibular second premolar
1 Root	1 canal	75.2%	74.3%
	2 canals	19.3%	22.3%
	3 canals	5.7%	4.9%
2 Roots	2 canals	3.1%	6.2%
	3 canals	1.7%	2.6%
Total		232	228

Table 2 :Canal configuration frequencies based on gender

Mandibular Premolars	Sex	Number of canals	Percentage	p value
First premolars	Female-52	1 canal	45.2%	>0.05
		More than 1 canal	14.2%	
	Male-48	1 canal	32.4%	
		More than 1 canal	12.7%	
Second premolars	Female-52	1 canal	42.2%	>0.05
		More than 1 canal	16.7%	
	Male-48	1 canal	30.2%	
		More than 1 canal	14.1%	

Graph 1: Canal Variations in Mandibular Premolars and Molars



The graph represents the correlation of anatomical variants such as distolingual roots of first molars, C shaped canals of second molars with canal configuration of mandibular premolars.