

Depth of Invasion as tumor indicator in cervical lymph node metastasis in OSCC

ABSTRACT

Squamous cell carcinoma of oral cavity is the 6th common cancer of the world and a major source of malignancy around the world. The best prognostic indicators for the occult lymph node metastasis are tumor depth of invasion and lymph node biopsies.

SAMPLE ABSTRACT:

Aims: This study was conducted to assess the association of tumor depth of invasion and lymph nodes metastasis in oral cancer diagnosis at its initial stage.

Study design: Cross-Sectional Study design.

Place and Duration of Study: Ziauddin Hospital, North Nazimabad campus, Karachi. January 2021 to January 2022.

Methodology: This Cross sectional study was conducted at the Ziauddin hospital, North nazimabad after Ziauddin University Ethical Review Committee approval (Reference Code: 0330618FAOM). 140 biopsied surgical resection specimen slides were included the slides were evaluated by 3 investigators.

Results: . The mean age of 140 OSCC was found to be 46.87 ± 12.25 years. 80.7% of study population comprised of males. 50% of patients had T4 stage. Moderately differentiated grade (89.3%) was the most predominant grade observed in this study. on the basis of DOI the patients were divided into 2 groups. One Group with Depth of invasion upto 4 mm and second group with Depth of invasion >4 mm. depth of invasion above 4 mm was found in 82.1% and without nodal metastasis(40.7%). The mean tumor size was found to be 4.36 ± 2.433 mm and tumor thickness was 1.95 ± 1.48 mm. and the most common anatomical site was found to be buccal mucosa (73.6%). T Stage and Nodal status , Tumour thicknes showed significant

association with depth of invasion with p values 0.001, 0.023 and 0.002 respectively.

Conclusion: The tumor depth of invasion is found to be an important variable that can be related with metastasis in Oral cancer as our study showed its significant association with lymph node metastasis.

Keywords: Depth of Invasion, ORAL SQUAMOUS CELL CARCINOMA, Lymph node metastasis, Tumor Thickness

1. INTRODUCTION

Oral squamous cell carcinoma develops from epithelial lining of the oral cavity. It is the 6th common cancer of the world and a major source of malignancy around the world (1-3). Burden of disease in oral cancer is highly increased in the less developed countries of Asia around 40% as compared to the West where overall prevalence is 2 to 5% (4).

Early oral cancer detection and diagnosis leads to a better prognosis, increases the chances of patient survival and plays a significant role in successful clinical treatment outcome. Delayed detection may lead to treatment failure and death (5). The current available treatment options for the oral cancers are not satisfactory, and the survival rate from past 5 years has not improved significantly over the past two decades (5-8).

Lymph node metastasis is the most common source of oral cancer metastasis. Surgical resection of tumour with neck dissection is the most important treatment of choice for the patient survival in oral cancer. Elective neck dissection gives information of pathological neck nodes involvement, hence remove undetectable cancerous cells in the lymphatic vessels and also helps to add additional therapy. The 5-year survival rate for patients of oral squamous cell carcinomas with lymph node metastasis is up to 50% (9-11).

According to AJCC 8th edition Depth of invasion is measured as "distance from horizon of basement membrane of adjacent squamous mucosa to deepest point of tumor in perpendicular direction through a plumbline" (12).

Now-a-days, the best prognostic indicators for the occult lymph node metastasis are Depth of Invasion and lymph node biopsies. Sentinel lymph node biopsies are highly accurate for identification of the lymph nodes metastasis. The sentinel lymph node biopsy is a delicate technique which requires accuracy. Whereas, Depth of Invasion is used as a marker for elective neck dissection (10).

The purpose of this study was to assess the association of DOI and the risk of occult lymph nodes metastasis in the early oral cancer diagnosis.

2. MATERIAL AND METHODS:

A cross-sectional study was conducted at Ziauddin Hospital, North Nazimabad after Ethical Review Committee approval (Reference Code: 0330618FAOM). The diagnostic histological slides of 140 patients with OSCC managed between January 2021 and January 2022 from the Ziauddin Hospital North Nazimabad histopathology department were collected from the hospitals' archives.

A total of 140 paraffin embedded formalin fixed OSCC tissue slides were included. Patients with any other cancer of oral cavity were excluded from study. 2 investigators (F.A. and S.F.) evaluated H&E slides by light microscopy which were

further reviewed by a senior pathologist (S.B). A pilot study of 20 cases was conducted to standardize the evaluation criteria for all 3 investigators. At the time of the evaluation all 3 investigators were blinded to the clinicopathologic data. All Patients file records were recorded, which includes age of the patient, gender, tumor site, tumor staging (TNM), the DOI, Lymph node involvement, tumour differentiation grades, perineural invasion and lymphovascular invasion. Measurement of Depth of Invasion: The hematoxylin and eosin slides were used to measure depth of invasion which was measured in accordance with AJCC 8th edition as "a plumb-line from as the distance from the inner most invasion area to the basement membrane adjacent to normal mucosa". A cut-off value of 4mm was used for depth of invasion. (10, 11).

3. RESULTS AND DISCUSSION

The present study included 140 OSCC patients with mean age of 46.87 ± 12.25 years. 80.7% of patients were males. The most common anatomical site was found to be buccal mucosa (73.6%). The mean tumor size was 4.36 ± 2.433 mm and tumor thickness was 1.95 ± 1.48 mm. The most common grade of OSCC was found to be moderately differentiated grade present in 89.3% of patients. 50% of patients had T4 stage followed by 25% of patients with T2 Stage. Lymph node metastasis was present in 59.3% of cases. On the basis of DOI the patients were divided into 2 groups. One group with depth of invasion up to 4 mm and second group with depth of invasion >4 mm. Depth of invasion up to 4mm was present in 17.9% of patients whereas above 4 mm was found in 82.1%. The association of depth of invasion with clinicopathological parameters was assessed. There is a significant association of depth of invasion with Tumor stage (P value 0.001), lymph node involvement (P value 0.023) and thickness of tumor (P value 0.002) respectively.

The association of age, gender, anatomical site, grade, lymphovascular and perineural invasion with depth of invasion were non significant with p values 0.091, 0.11, 0.075, 0.511, 0.148 and 0.422 respectively.

Presence of Lymph node metastasis, blood vessels and perineural involvement and grading are important key factors in the prognosis of OSCC patient. The clinical significance and importance of the histopathological parameters are determined by clinical TNM classification. (9, 13). However, discrepancy still exists. Significant cases with early oral cancer diagnosis with smaller tumor size have worst prognosis. Which clearly indicates that the tumor aggressiveness & tumor biological environment does not depend upon TNM Staging (14)

Literature suggested that depth of invasion of tumor is used as a tumor predictor and prognostic indicator in decision making of End node dissection in the early stages of oral squamous cell carcinoma. The optimal cut off point of depth of invasion was taken 4mm. The histomorphometric parameter of the tumor are best recognized after the surgical resection of the tumour. Therefore treatment planned of such cancer patients depend upon the surgical resected tumour specimens results (10, 15).

Numerous studies reported tumor depth of invasion and tumor thickness are not the same. "Depth of invasion" means the extent of cancerous lesion growth into the tissue beneath an epithelial surface (11, 16).

Literature suggested that the Depth of invasion of tumor as a occult lymph node metastasis predictor, In early oral cancer diagnosis END is used as a tumour predictor. For indurated tumours, The DOI is considered a better prognostic factor than Tumour Thickness. The 8th edition of AJCC guideline clearly stated the Depth of invasion definition as distance from horizon of basement membrane of adjacent squamous mucosa to deepest point of tumor in perpendicular direction through a plumbline. Our study showed with depth of invasion >4mm raised significantly the risk of nodal involvement. Some studies do not confirm cut off value of 4mm. Disparity exist in literature number of studies showed large variance. Some studies reported cut off value of <5mm DOI, Some showed cut off value of > 5mm. However, Some showed 7.25mm cut off. However, Some reported 4mm cut off. Some did not specify any cut off value for DOI, Some showed DOI value cut off varied from different subsites for tongue 2mm, floor of mouth 3mm. The reason for lower cut off value for tongue as compared to other subsite was the higher risk of lymph node metastasis due to its rich vascular and lymphatic supply and floor of the mouth. (10, 17-21).

Literature revealed there was a significant correlation between the tumor thickness and cancer metastasis at an early stage. Studies showed a strong association co-exist between the tumor depth of invasion and nodal status involvement, Which were concurrent with our study. Their study showed a depth of invasion of 4 mm to be a valuable cut-off for the occurrence of lymph node metastasis. They have recommended that oral cancers with 4 mm DOI are at higher risk of metastasis and should be selected for elective nodal dissection. (22). but no significant association were reported with pathological tumor size and tumor grade in tumor metastasis. Despite our study showed significant association of tumor

size and tumor grade. The reason for that was tumor thickness became more significantly co-related with larger tumor size (T2–T4) which were concurrent with other studies. (10, 11).

In our study, We had OSCC patients with tumor size measuring > 4 cm and upto 4mm. The strength of this study was measuring the depth of invasion for all OSCC cases by AJCC guide line. The depth of invasion was measured by AJCC guideline on H & E slides. By specialist oral pathologist. Limitation of this study was retrospective single centered study. A multi-centric prospective study with standard protocols should be carried out in future in order to correlate depth of invasion with the radiological aspects and histopathological determinants of tumor.. (18).

UNDER PEER REVIEW

Table 1: age, gender and histopathological characteristics of patients

Variables Categories	Total = N (%)
Age Mean \pm SD	46.87 \pm 12.25
Gender Male Female	113 (80.7%) 27 (19.3%)
Grade of tumor Well differentiated Moderately differentiated Poorly differentiated	9 (6.4%) 125 (89.3%) 6 (4.3%)
Perineural invasion Yes No	97(69.3%) 43 (30.7%)
Lymphovascular invasion Yes No	131 (93.6%) 9 (6.4%)
Depth of invasion (up to 4mm) (>4mm)	25 (17.9%) 115 (82.1%)
T stage	
T1 T2 T3 T4	15(10.7%) 35 (25%) 20(14.3%) 70(50%)
Nodal status	
N0 N1 N2a N2b N2c N3	57 (40.7%) 25 (17.9%) 10 (7.1%) 24 (17.9%) 2 (1.4%) 21 (15%)
Tumor size	4.36 \pm 2.433
Tumor thickness	1.95 \pm 1.48
Anatomical location Buccal mucosa Tongue Others	103(73.6%) 18(12.9%) 19 (13.57%)

GENDER INVOLVEMENT IN OSCC

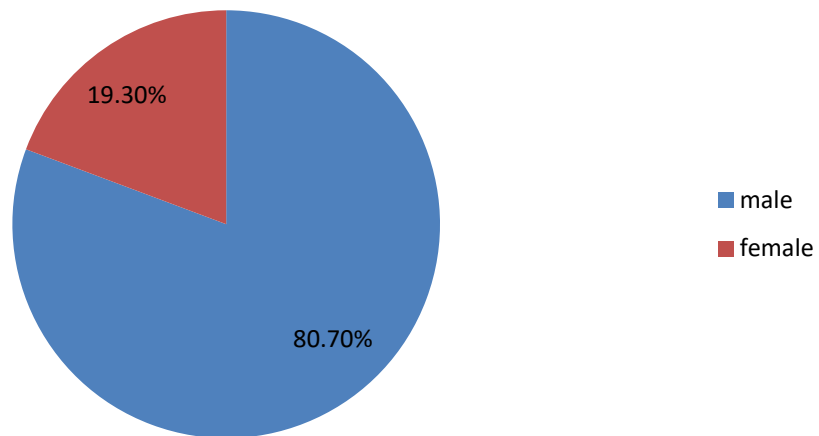


Fig. 1. Gender involvement in OSCC

OSCC Site

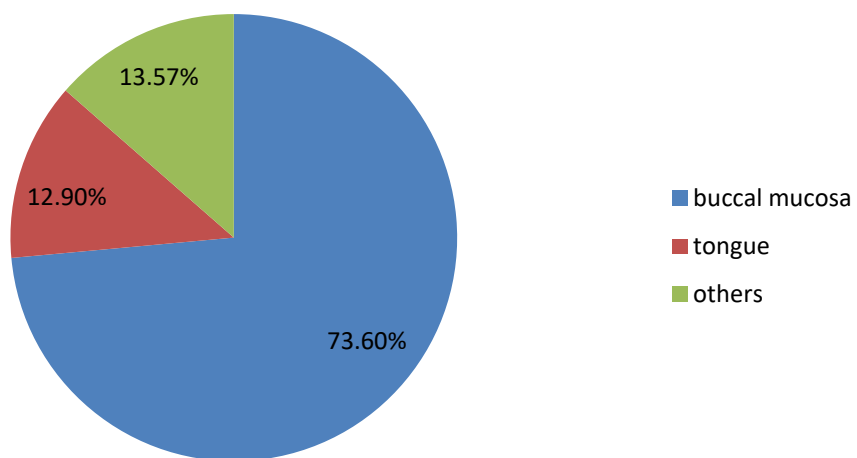


Figure 2: Frequent sites of OSCC involved

TABLE 2: Association of depth of invasion with clinico-pathological parameters

S.NO	DOI Up to 4mm	DOI >4mm	TOTAL	P value
Age Mean \pm SD 46.74 \pm 12.25	25	115	140	0.091
GENDER MALE FEMALE	23 2	90 25	113 27	0.115
T T1 T2 T3 T4	6 1 0 18	9 34 20 52	15 35 20 70	0.001*
N N0 N1 N2a N2b N2c N3	16 6 2 1 0 0	41 19 8 24 2 21	57 25 10 25 2 21	0.023*
Tumor Size in mm	25	115	140	0.217
Anatomical site Buccal mucosa Tongue Others	19 0 6	84 18 13	103 18 19	0.075
THICKNESS IN mm	25	115	140	0.002*
GRADE Well differentiated moderately differentiated poorly differentiated	3 21 1	6 104 5	9 125 6	0.511
Lymphovascular invasion Yes No	0 25	9 106	9 131	0.148
Perineural invasion YES NO	6 19	37 78	43 97	0.422

4. CONCLUSION

The DOI is an important tumor predictive factor for occult neck metastasis in Oral Cancer. Our study showed significant association of DOI with lymph node metastasis. OSCC patients with a Depth of invasion >4 mm had increased the probability of lymph node metastasis than those having depth of invasion upto 4 mm.

CONSENT :

Informed written consent was obtained from patients guardian.

ETHICAL APPROVAL:

The study was accepted by the Ziauddin University Ethics Review Committee. Ethical approval was obtained (Reference Code: 0330618FAOM)) It was carried out in line with the Helsinki Declaration, and all participants gave their informed written permission.

References:

1. Aldalwg MAH, Brestovac B. Human papillomavirus associated cancers of the head and neck: An Australian perspective. *Head and Neck Pathology*. 2017;11(3):377-84.
2. Alamgir MM, Jamal Q, Mirza T. Conventional clinical and prognostic variables in 150 oral squamous cell carcinoma cases from the indigenous population of Karachi. *Pakistan journal of medical sciences*. 2016;32(3):672.
3. Choi S, Myers J. Molecular pathogenesis of oral squamous cell carcinoma: implications for therapy. *Journal of dental research*. 2008;87(1):14-32.
4. Musani MA, Jawed I, Marfani S, Khambaty Y, Jalisi M, Khan SA. Carcinoma cheek: regional pattern and management. *Journal of Ayub Medical College Abbottabad*. 2009;21(3):87-91.
5. Yakob M, Fuentes L, Wang M, Abemayor E, Wong D. Salivary biomarkers for detection of oral squamous cell carcinoma: current state and recent advances. *Curr Oral Health Rep* 2014; 1: 133-41. 2014.
6. Ali J, Sabiha B, Jan HU, Haider SA, Khan AA, Ali SS. Genetic etiology of oral cancer. *Oral oncology*. 2017;70:23-8.
7. Faneca H, Düzgüneş N, de Lima MCP. Suicide Gene Therapy for Oral Squamous Cell Carcinoma. *Suicide Gene Therapy*: Springer; 2019. p. 43-55.
8. Markopoulos. Current aspects on oral squamous cell carcinoma. *The open dentistry journal*. 2012;6:126.
9. Abidi F, Hosein M, Butt SA, Zaidi AB, Anjum A, Fatima S. Association of clinicopathological features with lymph node metastasis: A cross sectional study of oral squamous cell carcinoma patients. *Journal of Advances in Medicine and Medical Research*. 2020;46-53.
10. Aaboubout Y, van der Toom QM, de Ridder MAJ, De Herdt MJ, van der Steen B, van Lanschot CGF, et al. Is the Depth of Invasion a Marker for Elective Neck Dissection in Early Oral Squamous Cell Carcinoma? *Frontiers in Oncology*. 2021;11(434).
11. Almangush A. For early-stage oral tongue cancer, depth of invasion and worst pattern of invasion are the strongest pathological predictors for locoregional recurrence and mortality. *Virchows Archiv*. 2015;467(1):39-46.
12. Kukreja P, Parekh D, Roy P. Practical challenges in measurement of depth of invasion in oral squamous cell carcinoma: Pictographical documentation to improve consistency of reporting per the AJCC 8th edition recommendations. *Head and Neck Pathology*. 2020;14(2):419-27.
13. Mirza S, Hadi NI, Akram S, Noor-ul-Wahab R, Akram Z. Histopathological predictors of nodal metastases in oral squamous cell carcinoma. *Pak J Med Dent*. 2016;5:12-6.
14. Siriwardena B, Rambukewela I, Pitakotuwage T, Udagama M, Kumarasiri P, Tilakaratne W. A predictive model to determine the pattern of nodal metastasis in oral squamous cell carcinoma. *BioMed research international*. 2018;2018.
15. Almangush A, Bello IO, Keski-Säntti H, Mäkinen LK, Kauppila JH, Pukkila M, et al. Depth of invasion, tumor budding, and worst pattern of invasion: prognostic indicators in early-stage oral tongue cancer. *Head & neck*. 2014;36(6):811-8.
16. Moore C, Kuhns JG, Greenberg RA. Thickness as prognostic aid in upper aerodigestive tract cancer. *Archives of Surgery*. 1986;121(12):1410-4.

17. Faisal M, Abu Bakar M, Sarwar A, Adeel M, Batool F, Malik KI, et al. Depth of invasion (DOI) as a predictor of cervical nodal metastasis and local recurrence in early stage squamous cell carcinoma of oral tongue (ESSCOT). *PLoS One*. 2018;13(8):e0202632.
18. Muhammad AY, Dhanani R, Salman S, Shaikh Z, Ghaloo SK, Ikram M. Depth of Invasion as a Predictor of Cervical Nodal Metastasis of Oral Tongue Squamous Cell Carcinoma: Findings From a Tertiary Care Center in Pakistan. *Cureus*. 2021;13(10).
19. Tam S, Amit M, Zafereo M, Bell D, Weber RS. Depth of invasion as a predictor of nodal disease and survival in patients with oral tongue squamous cell carcinoma. *Head & Neck*. 2018;41(1):177-84.
20. van Lanschot CG, Klazen YP, de Ridder MA, Mast H, Ten Hove I, Hardillo JA, et al. Depth of invasion in early stage oral cavity squamous cell carcinoma: The optimal cut-off value for elective neck dissection. *Oral Oncology*. 2020;111:104940.
21. Kumar T, Patel MD. Pattern of lymphatic metastasis in relation to the depth of tumor in oral tongue cancers: a clinico pathological correlation. *Indian Journal of Otolaryngology and Head & Neck Surgery*. 2013;65(1):59-63.
22. Sandu K, Nisa L, Monnier P, Simon C, Andrejevic-Blant S, Bron L. Clinicobiological progression and prognosis of oral squamous cell carcinoma in relation to the tumor invasive front: impact on prognosis. *Acta oto-laryngologica*. 2014;134(4):416-24.