

# **A CASE REPORT ON SPHENOIDAL SINUSITIS WITH BRAIN ABSCESS IN A 16 YEAR OLD**

## **ABSTRACT:**

A pyogenic infection-induced brain abscess is rare, and usually affects immunocompromised people. Brain imaging and bacterial culture from the infection site are used to diagnose a brain abscess. An effective treatment method is surgical resection combined with antibiotic treatment with bacteria-sensitive antibiotics for a sufficient period of time.

**PRESENTATION OF THE CASE:** A 16-year-old boy was confirmed to have Sphenoidal Sinusitis. The patient had been diagnosed with dengue fever three weeks ago and corona infection four months ago. And finally, he was diagnosed with Sphenoidal Sinusitis which manifested as severe headache, vomiting, and fever. He underwent bilateral Functional Endoscopy Sinus Surgery (FESS), sphenoidotomy and also temporal craniotomy and evacuation of abscess.

**CONCLUSION:** The treatment of a brain abscess requires early diagnosis, appropriate surgical treatment, and adequate duration of therapy with effective antibiotics.

**KEYWORDS:** Brain abscess, Sinusitis, Immunocompromised, Surgical treatment, Effective antibiotics

## **1. INTRODUCTION:**

Sinusitis is described as an inflammation of the mucosal lining of one or more paranasal sinuses that can be divided into acute (90 days) or chronic (120 days) disorders based on the length of clinical symptoms<sup>1</sup>. Viral, bacterial or fungal infections as well as environmental irritants and allergies can induce acute sinusitis<sup>2</sup>.

Sphenoidal sinus lesions are uncommon, accounting for just 2 to 3% of all paranasal sinus lesions<sup>3</sup>. Inflammatory disorders (acute, chronic bacterial and mycotic infections), mucocoeles, primary or secondary tumours (inverted papilloma, ossifying fibroma, pituitary adenoma) are examples of differential diagnosis<sup>4</sup>. The most prevalent complaint is headache, which accounts for 80-100 percent of cases<sup>5</sup>. Blurred vision, photophobia, progressive vision loss and diplopia owing to sixth nerve paralysis are all ocular symptoms that can occur in upto 22.5 percent of cases<sup>6</sup>.

## **2. PRESENTATION OF CASE:**

A 16 years old male patient approached to general medicine department. For the previous ten days, he had complaints of neck stiffness, been photophobic, and had a worsening headache and intermittent vomiting. The patient was conscious, oriented and febrile when admitted. His vital signs such as oxygen saturation (SPO2), pulse rate, and respiratory rate were all normal. He had a history of dengue fever three weeks prior and a COVID infection four months ago.

His blood group and Rheumatoid Factor (RH) type were found to be "O" positive. The patient's Serum Glutamic Pyruvic Transaminase (SGPT) level and activated partial thromboplastin time were both normal on clinical examination. His Prothrombin Time (PT), International Normalized Ratio (INR), and C-reactive Protein (CRP) was elevated. His Magnetic Resonance Imaging (MRI) brain report showed sphenoidal sinusitis with skull base osteomyelitis and meningitis with extra axial extension showing adjacent cerebritis.

S.NO	LAB PARAMTER	ESTIMATED VALUE				NORMAL VALUE
		DAY 1	DAY 6	DAY 8	DAY 16	
1.	Serum sodium	132	132	132	135	135-145mEq/L
2.	Serum Potassium	4.5	4.6	4.2	4.5	3.5-4.5mEq/L
3.	Total WBC Count	20,000	11,600	6500	4800	5000 -10,000cells/cu.mm
4.	Total RBC Count	4.62	4.17	3.98	4.36	4.7-6.1cells/cu.mm
5.	Basophils	0	0	0	0	0.5-1%
6.	Esinophils	0	0	5	8	0-6%
7.	Lymphocytes	11	11	39	25	20-40%
8.	Monocytes	1	2	3	3	2-8%
9.	Polymorphs	88	87	54	57	10-30%

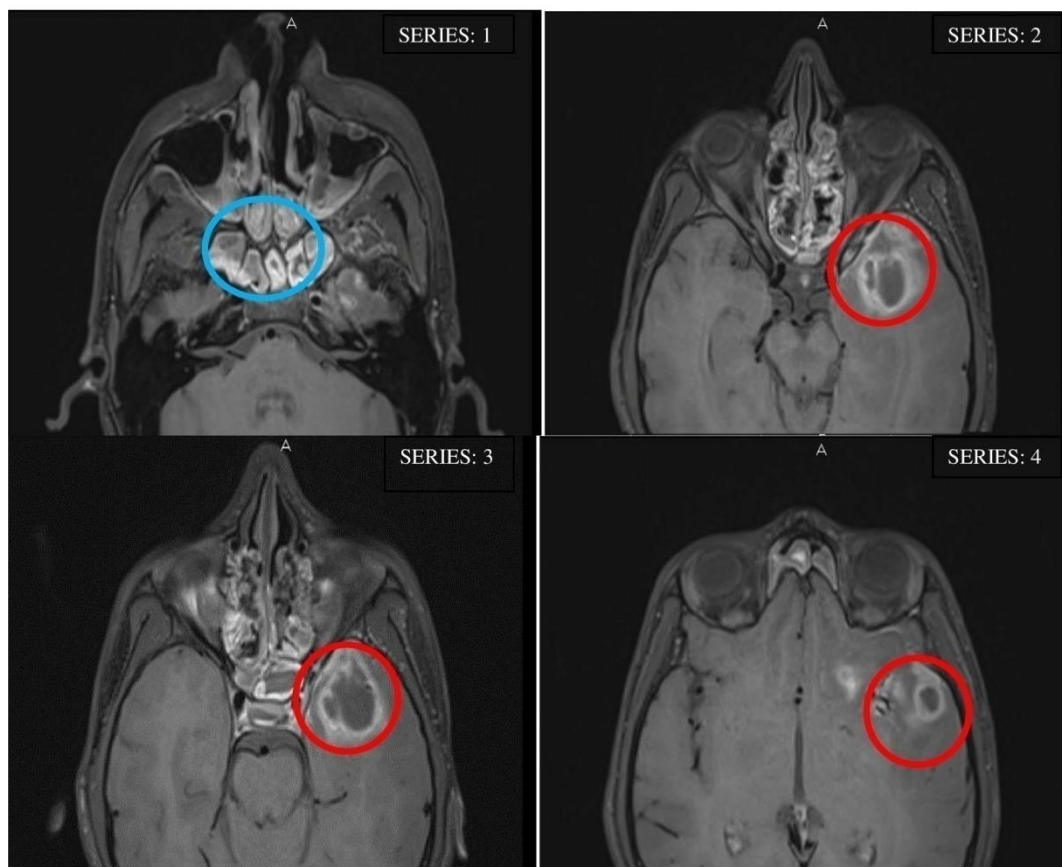
10.	PCV	36.9	33.6	32.2	39.5	36-48%
11.	MCV	79.9	80.6	80.9	91	80-100
12.	MCH	27.2	27.6	27.8	29	27.5-33.2%
13.	MCHC	34	34.2	34.4	32	33.4-35.5
14.	PLATELET	3,72,000	4,75,000	3,98,000	3,76,000	1,50,000-4,50,000cells/l
15.	HB	12.5	11.5	11.1	12.8	13.5-17g/dl
16.	RDW	13.4	12.8	13.4	11.8	11.8-14.5%

**Table 1: Lab investigations showing abnormalities in patient**

**Abbreviations: Mean Corpuscular Volume (MCV), Mean Corpuscular Hemoglobin (MCH), Mean Corpuscular Hemoglobin Concentration (MCHC), Platelet, Hemoglobin, Red Cell Distribution Width (RDW), Serum Sodium, Serum Potassium, White Blood Cells (WBC) Count, Hemoglobin (HB).**

\* - Elevated from the normal. \* - Decreased from the normal.

He was started on IV ceftriaxone, vancomycin, doxycycline, and Acyclovir, and then transferred to the High Dependency Unit (HDU) for further treatment. Acyclovir was discontinued since his cerebrospinal fluid (CSF) analysis indicated bacterial infection. Furthermore, doxycycline was stopped since his scrub typhus serology was negative. He had a sphenoidotomy and Bilateral Functional Endoscopy Sinus Surgery (FEES).



**Figure 1: Frontal axis MRI showed left temporal ring enhanced cystitic lesions with edema (marked in blue) and enhancement of Sphenoid sinus mucosa (marked in red) in the patient**

Since his MRI features were suggestive of fungal infection, voriconazole was given. He was then transferred to the ward, where his head ache got better with regular analgesics. He had persistent headache and generalized tonic clonic seizure after a couple of days, so he was started on regular antiepileptic (Tab.levitiracetam) treatment. CSF culture showed growth of Coagulase-negative staphylococci (CoNS) containment. His histopathology test reported fragments of sinus mucosa with lobules of mucous glands, edema, mild mononuclear cell infiltrate and bony spicules. A direct microscopic examination showed no evidence of fungal filaments. The MRI was repeated and it showed “features of a left temporal ring enhanced cystic lesion with edema and enhancement of sphenoid sinus mucosa suggestive of abscess”. He was treated with the following medications; T.Meropenam, T.Vancomycin, T.Voriconazole, T.levitiracetam, T.Mannitol, T.Paracetamol, T.Emeset, Fluticasone nasal spray, Polyethylene glycol 3350 and T.Fexofenadine hydrochloride.

Later he pursued treatment at another hospital. The patient underwent temporal craniotomy and evacuation of abscess and followed the current medication in hospital: analgesic, antibiotic and antiepileptics.

He was admitted to our hospital after the surgery for further treatment. His vitals were recorded and found to be normal. His computed tomography (CT) scan showed defects in the left frontotemporal craniotomy, edema with air-pockets in the left temporal region and focal contusion in the left basifrontal lobe. He was treated with IV antibiotics as well as supportive measures. The patient's condition improved, and hence he was discharged with the following medications: T.Pantoprazole 40mg, T.levitiracetam 750mg and T.Diclofenac 75mg.

### **3. DISCUSSION :**

A case of sphenoidal sinusitis in a 16-year-old boy was presented. The patient had past medical history of dengue fever three weeks prior and COVID infection four months ago. Finally, he was diagnosed with manifestations of sphenoidal sinusitis. According to the study, brain abscesses account for around 8% of intracranial masses in underdeveloped nations and 1–2% in western countries<sup>7</sup>.

A brain abscess is an intraparenchymal collection of pus<sup>8</sup>. The most common intracranial complication of sinusitis is meningitis, which is frequently caused by a sphenoid source. Direct or indirect cranial infection arising from the middle ear, paranasal sinuses, or teeth is the most prevalent source of microbial infection in children<sup>14</sup>. Inflammation of the meninges leads to the clinical syndrome of headache, neck stiffness and photophobia, often with nausea and vomiting<sup>9</sup> and unusual behavior in the early stages of the disease alike the symptoms of the patient during admission. In routine laboratory testing, a white blood cell count greater than 11,000 per cu.mm is defined as Leukocytosis<sup>10</sup>. In this cases, the reoccurrence of bacterial and viral infections weakens the immune system and increases the white blood count. The patient's imaging study revealed no sign of organism in gram stain cerebrospinal fluid (CSF). However, his CSF culture shows growth of Coagulase-negative staphylococci (CoNS) Concomitantly. The CSF cell count was clear and colourless, with a few count of CSF RBC and WBC count in the report. Normally, there are no RBCs in the cerebrospinal fluid, and there should be no more than five WBCs per cubic millimeter of CSF. If the CSF fluid contains RBCs, this may indicate bleeding or may be due to the possibility

of traumatic tap (blood leaked into the fluid sample during collection)<sup>11</sup>. FESS (sinus surgery) is most successful in patients who have recurrent acute or chronic infective sinusitis.

## **CONCLUSION:**

The pyogenic brain abscess is a collection of pustular materials presenting as a mass-like lesion. A cerebral abscess usually occurs when bacteria or fungi make their way into the brain, either through your bloodstream or from an infected area in the head, such as your ears or sinuses. In the present case, craniotomy for abscess excision was a more effective method. Complete excision of the abscess capsule was an effective precaution against recurrence. It is necessary to choose antibiotics according to drug sensitivity tests result and to ensure the adequate duration of intravenous treatment until postoperative body temperature has remained within the normal range level. It is also essential for the patient to continue oral antibiotics for at least 3 months after discharge.

## **ETHICAL APPROVAL**

As per international standard or university standard written ethical approval has been Collected and preserved by the authors.

## **CONSENT**

As per international standard or university standard, patients' written consent has been Collected and preserved by the authors.

## **CONFLICT OF INTEREST:**

The authors declare that the case study was conducted in the absence of any commercial or financial relationships that could be construed as a potential conflict of interest.

## **AUTHORS' CONTRIBUTION:**

This work was carried out in collaboration among all authors. All authors read and approved the final manuscript.

## **COMPETING INTERESTS DISCLAIMER:**

Authors have declared that no competing interests exist. The products used for this research are commonly and predominantly use products in our area of research and country. There is absolutely no conflict of interest between the authors and producers of the products because we do not intend

to use these products as an avenue for any litigation but for the advancement of knowledge. Also, the research was not funded by the producing company rather it was funded by personal efforts of the authors.

## **REFERENCE:**

1. American Academy of Pediatrics, Subcommittee on Management of Sinusitis and Committee on Quality Improvement. Clinical practice guideline: management of sinusitis. Pediatrics. 2001;108(3):798–808
2. Brook I. Acute sinusitis in children. *PediatrClin North Am*. 2013;60(2):409–424.
3. Cheung DK, Martin GF, Rees J. Surgical approach to sphenoid sinus. *J OtolLaryngol* 1992;21:1-8.
4. Elden LM, Reinders KK, Tom LWC. Management of isolated sphenoid sinus disease in children: A surgical perspective. *Int J PediatrOtorhinolaryngol* 2011;75:1594-1598.
5. Castelnovo P, Pagella F, Semino F, et al. Endoscopic treatment of isolated sphenoid sinus lesions. *Eur Arch Otorhinolaryngol* 2005;262:142-147.
6. Kim SW, Kim IG, Kong DY, et al. Isolated sphenoid sinus diseases: report of 76 cases. *ActaOtolaryngol* 2008;128:455- 459.
7. Nauta HJ, Contreras FL, Weiner RL, Crofford MJ. Brain stem abscess managed with computed tomography guided stereotactic aspiration. *Neurosurgery*. 1987 Mar 1;20(3):476-80.
8. Sharma BS, Gupta SK, Khosla VK. Current concepts in the management of pyogenic brain abscess. *Neurology India*. 2000 Apr 1;48(2):105.
9. Osenbach RK, Loftus CM. Diagnosis and management of brain abscess. *Neurosurgery clinics of North America*. 1992 Apr 1;3(2):403-20.
10. Chen M, Low DC, Low SY, Muzumdar D, Seow WT. Management of brain abscesses: where are we now?. *Child's Nervous System*. 2018 Oct;34(10):1871-80.
11. Seehusen DA, Reeves MM, Fomin DA. Cerebrospinal fluid analysis. *Am Fam Physician*. 2003 Sep 15;68(6):1103-8.