

# **Original Research Article**

## **Histomorphological trends of testicular lesions : A retrospective study**

### **ABSTRACT**

**Aims:** Testis is affected by a variety of non-neoplastic and neoplastic lesions. Our study was undertaken to analyze the spectrum of all testicular lesions and clinical correlation with age-wise distribution, laterality, and clinical presentation of all testicular lesions.

**Study design:** A retrospective descriptive study.

**Place and Duration of Study:** Saveethe Medical College and Hospitals, over three years from January 2018 to December 2020.

**Methodology:** All testicular lesions sent to the Department of Pathology during this period are taken for the study. Histopathological slides were retrieved and all testicular lesions were reviewed.

**Results:** Out of 70 cases studied, 64 cases were non-neoplastic (91.42%) and 6 cases were neoplastic (8.57%). Right testis was more commonly involved in our study. Age distribution of non-neoplastic lesions showed the highest incidence in the 2nd decade of life (18.7%) followed by the 6th decade of life (15.6%) in our study. In neoplastic lesions, the 3rd and 4th decade of life shows higher incidence (33.4% respectively). Among non-neoplastic lesions, the most common histologic type is atrophic testis (31.2%). Among neoplastic lesions, the most common lesion is seminoma (50%).

**Conclusion:** Non- neoplastic lesions are seen in all age groups, whereas testicular neoplastic lesions are more commonly seen in the younger age group.

**Keywords:** Testicular lesions, non-neoplastic, neoplastic, atrophic testis, seminoma

### **1. INTRODUCTION**

The male reproductive system comprises the testes with their respective duct systems, the prostate, and the penis. Their main function is to produce, store, and periodic emission of the male gametes, spermatozoa, as well as production of male sex hormones, principally testosterone.

The normal adult testis is a paired organ that lies suspended within the scrotum by the spermatic cord [1,3]. The testis is prone to a full range of pathological conditions. Testicular lesions are seen in all age groups ranging from pediatric to adult age group [3,4].

Undescended testes, also known as Cryptorchidism are one of the most common congenital anomalies seen approximately in 1% of one-year-old boys [2,3,4]. Cryptorchidism is a major risk factor for the development of testicular cancer [3,4].

Other non-neoplastic lesions encompass inflammatory lesions like acute and chronic Epididymo-orchitis, vascular lesions like torsion of testis, regressive changes like the atrophic testis and decreased fertility, infections of testis like tuberculosis [2,3].

Neoplastic lesions of the testis are rare and account for approximately 1% of all neoplasms in males. Testicular tumors can be classified into five major categories: germ cell tumors (90%) which arise from the germinal epithelium of the seminiferous tubules; sex cord-stromal tumors; mixed germ cell–sex cord-stromal tumors; primary tumors not specific to the testis; and metastatic tumors [1].

Scrotal swelling, pain, and mass per abdomen are the most common clinical presentations for all testicular lesions [3,4]. Hence histopathologic features play a major role in the clinical prognosis and treatment of testicular lesions [4].

This study was undertaken to study the diverse histomorphological features of both non-neoplastic and neoplastic lesions of testis and clinically correlate with the age-wise distribution, laterality of the lesions.

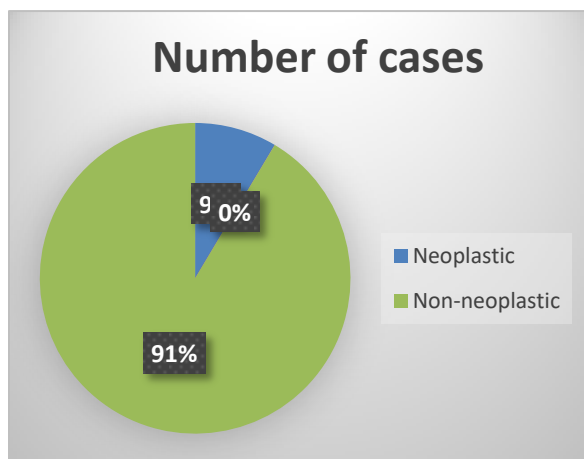
## 2. MATERIAL AND METHODS

This is a retrospective study over three years from January 2018 to December 2020. All testicular lesions sent to the Department of Pathology during the study period were taken for the study. Clinical details were obtained from the case sheets. Histopathological slides were retrieved and all testicular lesions were reviewed. The data were analyzed descriptively and compared with other studies.

## 3. RESULTS AND DISCUSSION

Among the total cases studied, 64 cases were non-neoplastic (91.42%) and 6 cases were neoplastic (8.57%) as shown in figure 1.

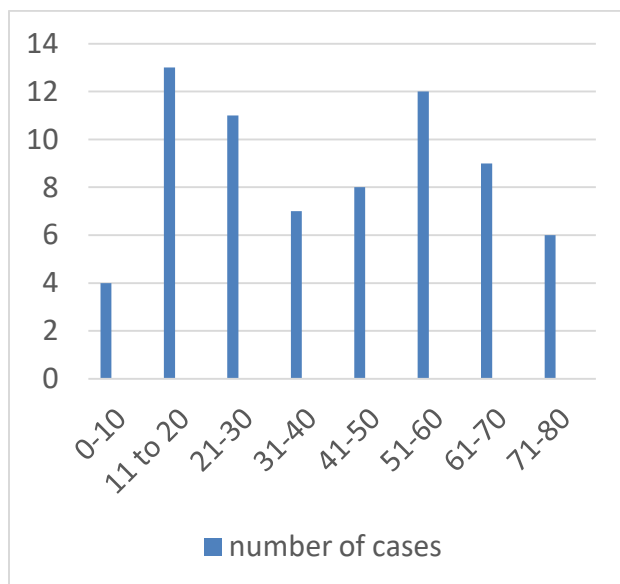
**FIGURE 1: NUMBER DISTRIBUTION**



The testis is affected by a variety of non-neoplastic and neoplastic lesions at various stages of life. A maximum number of testicular lesions are seen among 11 to 20 years (18.5%) followed by 51 to 60 years (17.1%) as shown in Table 1 and figure 2.

**TABLE 1: AGE-WISE DISTRIBUTION**

AGE	NUMBER OF CASES	PERCENTAGE
1 to 10	4	5.7%
<b>11 to 20</b>	<b>13</b>	<b>18.5%</b>
21 to 30	11	15.7%
31 to 40	7	10%
41 to 50	8	11.4%
51 to 60	12	17.1%
61 to 70	9	12.8%
71 to 80	6	8.5%
TOTAL:	70	100%

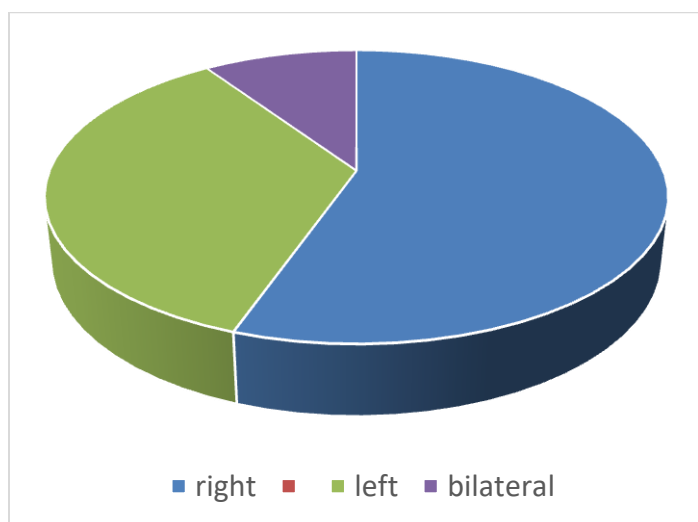
**FIGURE 2: AGE-WISE DISTRIBUTION**

Majority of the cases present with unilateral involvement of testis. Most of the cases presented with **right-sided** involvement, 41 out of 70 cases (58.5%). Whereas **left-sided** involvement is seen in 26 out of 70 cases (37.1%). **The remaining** 3 of 70 cases (4.2%) showed bilateral involvement as shown in Table 2 and figure 3.

**TABLE 2: LATERALITY OF SPECIMEN**

LATERALITY	NUMBER OF CASES	PERCENTAGE
RIGHT	41	58.5%
LEFT	26	37.1%
BILATERAL	3	4.2%
TOTAL	70	

**FIGURE 3: LATERALITY OF SPECIMEN**



Age-wise distribution of non-neoplastic lesions showed the highest incidence in the 2nd decade of life, 12 of 64 cases (18.7%) followed by 5th decade of life, 11 of 64 cases (17.1%) as shown in table 3.

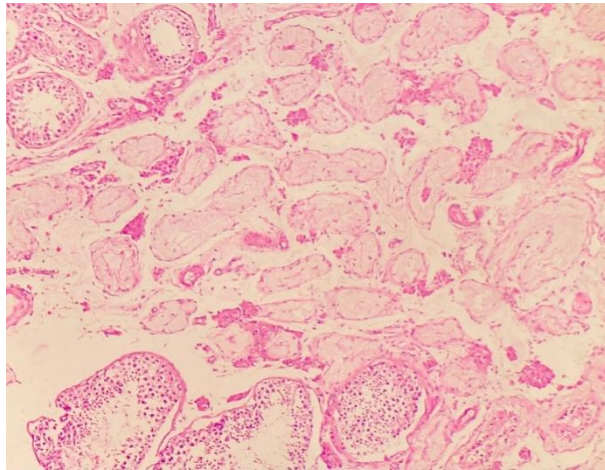
Among non-neoplastic lesions, the most common histologic type is atrophic testis, 20 of 64 cases (31.2%) followed by torsion testis, 13 of 64 cases (20.3%). The atrophic testis has a wide range of age distribution from 5 to 80 years, more incidence in 2nd decade of life, 5 of 20 cases as shown in table 3. Microscopically atrophic testis showed small tubes with thickened basement membrane with few or no germ cells and increased Leydig cells as shown in figure 4.

Inflammations are more commonly seen in epididymis than in testis. Various etiology leads to inflammation in testis and epididymis out of which Tuberculosis and gonorrhea are the most common etiology [2]. Microscopically the architecture is preserved but there can be patchy lymphoplasmacytic infiltrates in between and with the seminiferous tubules, hemorrhage, edema as shown in Figure 5.

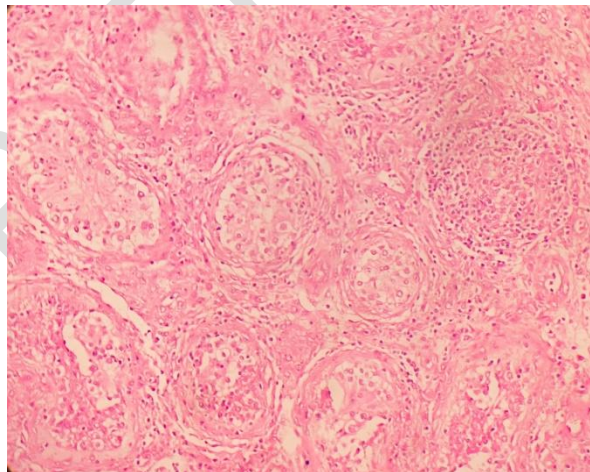
Torsion testis is more commonly seen among 11 to 20 years, 7 of 13 cases. Hydrocele 3 cases were studied (4.6%), usually associated with trauma and epididymitis. Clear serous fluid accumulates between visceral and

peritoneal layers of tunica vaginalis. Haematocele is **an accumulation** of blood in tunica vaginalis, 2 cases were studied. Pyocele, 8 cases studied is collection of pus in the tunica vaginalis.

8 cases of maturation arrest were studied. Maturation arrest can be complete or incomplete. Microscopically mature spermatozoa are absent and Sertoli cells appear prominent due to reduced germ cells.



**Figure 4** (H&E 10x): Section shows atrophic tubules with thickened basement membrane and Leydig cell hyperplasia



**Figure 5** (H&E 10X)" Section shows lymphoplasmacytic infiltrates in between and within seminiferous tubules.

**TABLE 3: HISTOPATHOLOGICAL TYPES OF NON-NEOPLASTIC TESTICULAR LESIONS ALONG WITH AGE DISTRIBUTION**

<b>A SPECTRUM OF NON-NEOPLASTIC:</b>	<b>0-10</b>	<b>11-20</b>	<b>21-30</b>	<b>31-40</b>	<b>41-50</b>	<b>51-60</b>	<b>61-70</b>	<b>71-80</b>	<b>TOTAL</b>	<b>PERCENTAGE</b>
<b>EPIDIDYMOORCHITIS</b>			2	1	2	3	2		10	15%
<b>ATROPHIC TESTIS</b>	2	4	5	2	3	2	2	1	20	31.2%
<b>TORSION TESTIS</b>	2	7	1	1		2			13	20.3%
<b>HYDROCELE</b>							1	2	3	4.6%
<b>HAEMATOCELE</b>						2			2	3.1%
<b>PYOCLE</b>		1		1	1		4	1	8	12.5%
<b>MATURATION ARREST</b>			1		1	3	1	2	8	12.5%
<b>TOTAL</b>	4	12	9	5	7	11	10	6	64	100%
<b>PERCENTAGE</b>	6.2%	18.7%	14%	7.8%	10.9%	17.1%	15.6%	9.3%	100%	

In neoplastic lesions, the 3rd and 4th decades of life show higher incidence (33.4% respectively). Among neoplastic lesions, the most common lesion is seminoma constituting 3 of 6 cases (50%) followed by non-seminomatous mixed germ cell tumor, 2 of 6 cases (33.4%), and seminomatous mixed germ cell tumor, 1 of 6 cases (16.6%) as shown in table 4. Microscopically seminoma shows tumor cells have abundant clear cytoplasm with centrally placed nucleoli as shown in Figure 6.

**TABLE 4: HISTOPATHOLOGICAL TYPES OF NEOPLASTIC TESTICULAR LESIONS ALONG WITH AGE DISTRIBUTION**

THE SPECTRUM OF NEOPLASTIC LESIONS	0-10	11-20	21-30	31-40	41-50	51-60	61-70	71-80	TOTAL	PERCENTAGE
SEMINOMA		1		2					3	50%
MIXED GCT (SEMINOMATOUS)					1				1	16.6%
MIXED GCT (NON-SEMINOMATOUS)			2						2	33.4%
TOTAL		1	2	2	1				6	100%
PERCENTAGE		16.6%	33.4%	33.4%	16.6%				100%	

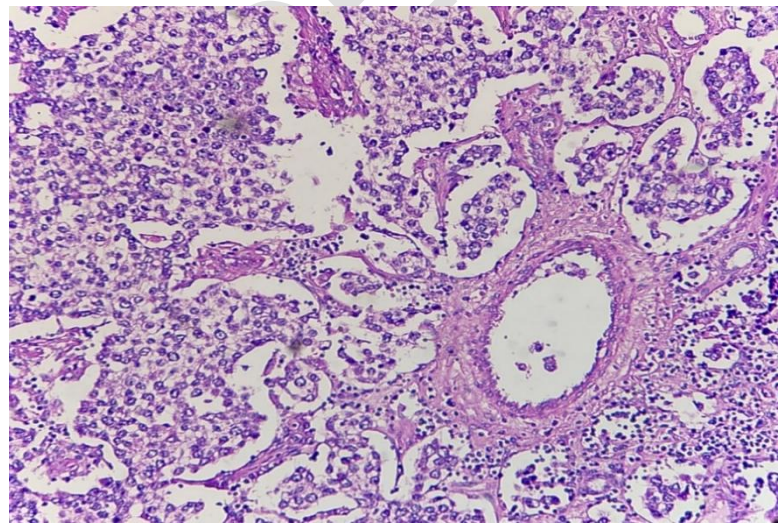




Figure 6 (H&E 20x) Section shows tumour cells with clear cytoplasm with centrally placed nucleus.

### 3.1 DISCUSSION

In this study total of 70 cases were studied. Among these cases, 11 to 20 years is the most common age group affected by testicular lesions (18.5%). Similar to the study done by Reddy H Et al (22%) [7]. Right testis is more commonly affected than left side testis in this study (58.5% VS 37.1%) similar to the study done by Tekumalla A Et al (51.25% vs 31.25%) [3].

Non-neoplastic testicular lesions were more common than neoplastic ones (91.4 vs 8.5%). This is in concordance with Sharma m et al (93 vs 7%) [4].

Age non-neoplastic lesions showed the highest incidence in 11 to 20 years (18.7%) in this study which is similar to the study done by Qazi sm Et al (30.62%) [9]. Whereas a study done by Tekumalla A Et al showed the highest incidence in the 7th decade, corresponding to 32% [3].

Among non-neoplastic lesions, the most common histologic type is atrophic testis (31.2%). Torsion testis is the most common benign lesion in the study done by Oranusi ckt al corresponding to 42.9% [6] and Baidya r et al (54.9%) [5]. Torsion testis is the second most common non-neoplastic lesion (20.3%) and it is more commonly seen among the younger age group of 5 to 55 years in this study.

Neoplastic lesions were more commonly seen among 20 to 40 years (33.4%) in this study. Similar to a study done by Mushtaq S Et al which also showed a higher incidence among the 20 to 39 years of age group (47%) [8].

Among neoplastic lesions, the most common lesion is seminoma constituting 50% in this study. Also, seminoma is the most common neoplastic lesion of testis in studies done by Tekumalla A Et al (40%) [3], Baidya r et al (44.44%) [5] and Gill ms E al (36.5%) [14]. Seminoma is the most common neoplasm of all testicular tumors.



#### 4. CONCLUSION

Non- neoplastic lesions are seen in all age groups, whereas testicular neoplastic lesions are more commonly seen in the younger age group. Knowledge about histomorphology and age distribution of neoplastic and non-neoplastic lesions of the testis is important as it determines the clinical prognosis and treatment of the patient.

#### ETHICAL APPROVAL

As per international standard or university standard written ethical approval has been collected and preserved by the author(s).

#### REFERENCES

1. Rosai j, male reproductive system in rosai and ackermans surgical pathology. Elsevier, 10th ed, vol-1 2011;1335-1336.
2. Kumar v, abbas ak ,fausto n (eds).epstein ji. The lower urinary tract and male genital system in robbins and cotran pathological basis of diseases.7thed saunders 2004; 1039-1047.
3. Tekumalla a, ragi s, thota r. Histopathological analysis of testicular lesions-a three year experience in a tertiary care center, telangana. Trop j path micro. 2019;5(5):260.
4. Sharma m, mahajan v, suri j, kaul kk. Histopathological spectrum of testicular lesions-a retrospective study. Indian j pathol oncol. 2017 jul 15;4(3):437-1.
5. Baidya r, sigdel b, baidya nl. Histopathological pattern of testicular lesion. Journal of pathology of nepal. 2017 mar 30;7(1):1087-90.
6. Oranusi ck, onyiaorah iv, ukah co. Pattern of testicular biopies as seen in a tertiary institution in nnewi, southeast nigeria. Nigerian journal of surgery. 2014 aug 22;20(2):55-8.
7. Reddy h. Histomorphological analysis of testicular lesions. International journal of pharmaceutical and biological science archive. 2015;3(1).
8. Mushtaq s, jamal s, mamoon n, akbar n, khadim t. The pathological spectrum of malignant testicular tumours in northern pakistan. Jpma. 2007;57(499).
9. Qazi sm, siraj s, gul w. Histopathological outcome of testicular lesions at pims. Annals of pims-shaheed zulfiqar ali bhutto medical university. 2018 jun 21;14(2):169-72.
10. Adami ho, bergström r, möhner m, zatoôski w, storm h, ekbom a, tretli s, teppo l, ziegler h, rahu m, gurevicius r. Testicular cancer in nine northern european countries. International journal of cancer. 1994 oct 1;59(1):33-8.
11. Devi ts, nirmala bv, srivani n, kumar os. Spectrum of orchidectomy lesions: 5 years study. J evidence based med healthcare. 2015;26:3880-92.
12. Kaver i, matzkin h, braf zf. Epididymo-orchitis: a retrospective study of 121 patients. Journal of family practice. 1990 may 1;30(5):548-52.
13. Deotra a, mathur dr, vyas mc. A 18 years study of testicular tumours in jodhpur, western rajasthan. Journal of postgraduate medicine. 1994 apr 1;40(2):68.
14. Gill ms, shah sh, soomro in, kayani n, hasan sh. Morphological pattern of testicular tumors. Journal of pakistan medical association. 2000;50(4):110.

15. Chakrabarti pr, dosi s, varma a, kiyawat p, khare g, matreja s. Histopathological trends of testicular neoplasm: an experience over a decade in a tertiary care centre in the malwa belt of central india. *Journal of clinical and diagnostic research: jcdr*. 2016 jun;10(6):ec16.
16. Woodward pj, sohaey r, o'donoghue mj, green de. from the archives of the afip: tumors and tumorlike lesions of the testis: radiologic-pathologic correlation. *radiographics*. 2002 jan;22(1):189-216.
17. Balogh d, bíró e, garai g, mohay g, semjén d, vástyán a. Cystic lesions of the testis in infancy—case series of four patients. *Orvosi hetilap*. 2020 nov 29;161(48):2043-8.
18. Paluru s, ulbright tm, amin m, montironi r, epstein ji. The morphologic spectrum of sertoliform cystadenoma of the rete testis. *The american journal of surgical pathology*. 2018 feb 1;42(2):141-9.
19. Sangüesa c, veiga d, llavador m, serrano a. Testicular tumours in children: an approach to diagnosis and management with pathologic correlation. *Insights into imaging*. 2020 dec;11(1):1-4.
20. Maizlin ii, dellinger m, gow kw, goldin ab, goldfarb m, nuchtern jg, langer m, vasudevan sa, doski jj, raval mv, beierle ea. Testicular tumors in prepubescent patients. *Journal of pediatric surgery*. 2018 sep 1;53(9):1748-52.
21. Shilo y, zisman a, lindner a, raz o, strauss s, siegel yi, segal m, sandbank j, leibovici d. The predominance of benign histology in small testicular masses. *Inurologic oncology: seminars and original investigations* 2012 sep 1 (vol. 30, no. 5, pp. 719-722). Elsevier.
22. Bergmann m, kliesch s. Testicular biopsy and histology. *Inandrology* 2010 (pp. 155-167). Springer, berlin, heidelberg.
23. Cicero c, bertolotto m, hawthorn br, antonelli ct, sidhu ps, ascenti g, nikolaidis p, dudea s, toncini c, derchi le. Multiple, synchronous lesions of differing histology within the same testis: ultrasonographic and pathologic correlations. *Urology*. 2018 nov 1;121:125-31.
24. Sarici h, telli o, eroğlu m. Bilateral testicular germ cell tumors. *Turkish journal of urology*. 2013 dec;39(4):249.
25. Akiyama s, ito k, kim wj, tanaka y, yamazaki y. Prepubertal testicular tumors: a single-center experience of 44 years. *Journal of pediatric surgery*. 2016 aug 1;51(8):1351-4.
26. Zequi sd, da costa wh, santana tb, favaretto rl, sacomani ca, guimaraes gc. Bilateral testicular germ cell tumours: a systematic review. *Bju international*. 2012 oct;110(8):1102-9.
27. Loberant n, bhatt s, messing e, dogra vs. Bilateral testicular epidermoid cysts. *Journal of clinical imaging science*. 2011;1.
28. Nauman m, leslie s. Nonseminomatous testicular tumors. *Statpearls*. 2022 feb 14.