

Original Research Article

INFLUENCE OF LYCOPENE ON RENAL TISSUE INJURY IN CELEBREX INDUCED ALBINO RATS; AN EXPERIMENTAL RESEARCH STUDY.

ABSTRACT

Objective: To analyze the renal tissue injury in Celebrex induced albino rats with improvement by lycopene.

Study design: Experimental research study.

Abode of study: Animal House, Basic medical sciences institute, Karachi,

Materials and Methods:

Celebrex and antioxidant agent lycopene were used in this experimental study. Drugs were administered orally to forty male albino rats weighing of around 250gm for research. Rats were retained in isolated cages and alienated into 4 sets including control, diseased, treated groups. The drugs were administered by gastric tube once 24-hourly for four weeks. After finalization of research work, rats were sacrificed and body tissues were preserved for staining.

Results: gB Gomori's calcium phosphate stained sections showed marked deposition of dark black particles of alkaline phosphate in cellular cytoplasm of proximal convoluted tubules but gC showed scarce deposition of black particles of alkaline phosphate in the cellular cytoplasm of proximal convoluted tubules.

Conclusion: This experiment discloses that lycopene recuperate the raised level of alkaline phosphate in the cytoplasm of proximal convoluted tubules.

Key words: proximal convoluted tubules, Gomori's calcium phosphate, alkaline phosphate, PGE₂.

INTRODUCTION:

Non-Steroidal Anti-inflammatory drugs are the number one most frequently recommended medicine & COX enzyme inhibitor for various ailments like inflammation, fever, arthritis and painful illnesses. They further categorize on the basis of (COX) enzyme selectivity. One group inhibits both COX 1 & 2 whereas second group is only COX-2 inhibitor.¹ Non-selective group raise the risk of gastric ulcers and intestinal bleeding due to weakening of prostaglandin-dependent mucosal protective ability because NSAIDs inhibit prostaglandins synthesis.^{2,3} PGE₂ regulates the fluid metabolism and hemodynamic in renal tissue and its inhibition plays a significant role in inflammation, peptic ulcer ailment, renal dysfunction and impairment of intestinal mucosa.⁴ Myeloperoxidase enzyme (MPO) found in neutrophils and macrophages plays an important role in inflammation and oxidative stress.^{5,6} Organs in which Xenobiotic metabolism occurs are kidney, liver & GIT. It is the type of metabolism in which biochemical alteration of drug takes place by enzymes. Celebrex is COX-2 enzyme inhibitor & COX-2 enzyme mainly affects salt and water excretion, so it has a toxic effect on kidney. It can cause cellular injuries & degenerative changes in renal tissue such as chronic renal failure, nephropathy & interstitial nephritis.⁷ Acute renal injury is described by accumulation of urea, alkaline phosphatase & creatinine in plasma.⁸ Alkaline phosphatases are present in proximal convoluted tubules of renal tissue & altered due to nephrotoxic drugs.⁹ Celebrex a selective COX-2 (cyclooxygenase) inhibitor has GI (gastrointestinal) tolerability & has a reduced amount of bowel injury.^{10,11,12} Usage of COX-2 inhibitors causes renal tissue injury & elevates serum alkaline phosphatase in end stage renal

disease patients, which causes reduced BP, kidney calculus formation, angina pectoris, shortness of breath, deafness, Mediterranean illness cardiovascular ailments, atherosclerosis & death.^{13,14}

Lycopene is a red carotenoid phytochemical noncyclic complex present in apricots, asparagus, parsley & other vegetables. It prevents lipid peroxidation & undergo oxidative, thermal and photo degradation.^{15,16} Lycopene found in blood plasma anti-carcinogenic, anti-inflammatory and antioxidant in character. Inhibits prostaglandin synthesis & also prevents various malignancies, Alzheimer's ailment, & cardiovascular illnesses, as well as reduces ageing.¹⁷ It prevents cellular damage due to scavenging properties of reactive oxygen species, singlet oxygen-quenching capability, several conjugated double bonds & reacts with reactive oxygen species to decrease DNA mutilation.^{18,19,20} It also prevents lipid peroxidation in cellular basement membrane.^{21,22,23} It detoxifies toxins by antioxidation, anti-inflammation activity.^{24,25} The experimental research study was organized to examine the advantageous effects of lycopene in comparison with injurious effects of Celebrex.

MATERIAL AND METHODS

This is a 4 weeks experimental research study, came about in JPMC (Jinnah postgraduate medical center), Karachi along with endorsement from ethical review board No.F-1-2/BMSI-E.COMT/039/JPMC. 40 fully grown up healthy albino rats, three to four months old, around 250gm were taken from USA lab and fostered in animal house in isolated cages. Assessed for 7 days for their health condition and weighed former the beginning of research and isolated into 4 sets (control, diseased, treated) and dosage calculated according to their weight. Tablet Celebrex purchased from Getz Pharma & lycopene pigment

capsule from General Nutrition Corporation, ^(26,27) were administered by gastric tube 0.05g/kg orally once 24-hourly for four weeks. After finalization of research work, rats were sacrificed and body tissues were preserved for staining.

gA= control.

gB= Celebrex 0.05g/kg per oral. (Morbid group)

gC= Celebrex with lycopene pigment 0.05g/kg per oral.

gD= lycopene pigment 0.05g/kg per oral.

Throughout the experimental duration animals were deeply observed for variance in their conditions. They were sedated by ethanol and fixed on a dissecting panel. A vertical cut was given from sternum to pubic bone. Renal tissue was washed with saline water and fixed in 10% formalin for 24 hours, then kept for dehydration in 70% alcohol overnight. Further dehydrated by ascending concentrations of alcohol, after that cleared in xylene. Paraffin infiltration take place at 58 °C in lab oven and paraffin blocks prepared. 4 micron dense slices excised on microtome & placed in warm H₂O bath at 40 °C and fixed on albumenized glass slides at 30 – 32 °C. Gomori's calcium phosphate was used to observe alkaline phosphatase activity in proximal convoluted tubular cells (8X ocular and 40X objective lens). ²⁸

RESULTS

Microscopic observation of Renal Tissue with the help of Gomori's calcium phosphate staining

gA:

Gomori's calcium phosphate stained renal sections of gA showed less or no black particles of alkaline phosphate in the apical area of cellular cytoplasm. (Figure-1).

gB:

Gomori's calcium phosphate stained kidney sections showed marked deposition of dark black particles of alkaline phosphate in cellular cytoplasm of proximal convoluted tubules (Figure-2).

gC:

Gomori's calcium phosphate stained section of this group showed rare deposition of black particles of alkaline phosphate in the cellular cytoplasm (Figure-3).

gD:

Gomori's calcium phosphate stained section of this group showed rare or no black particles of alkaline phosphate in the apical area of cellular cytoplasm just like gA.

Figure-1

Gomori's Calcium Phosphate stained, 4 μm thick section of control albino rat kidney showing less amount of Alkaline Phosphate particles (ALP) in Proximal tubule (Photomicrograph x 400)

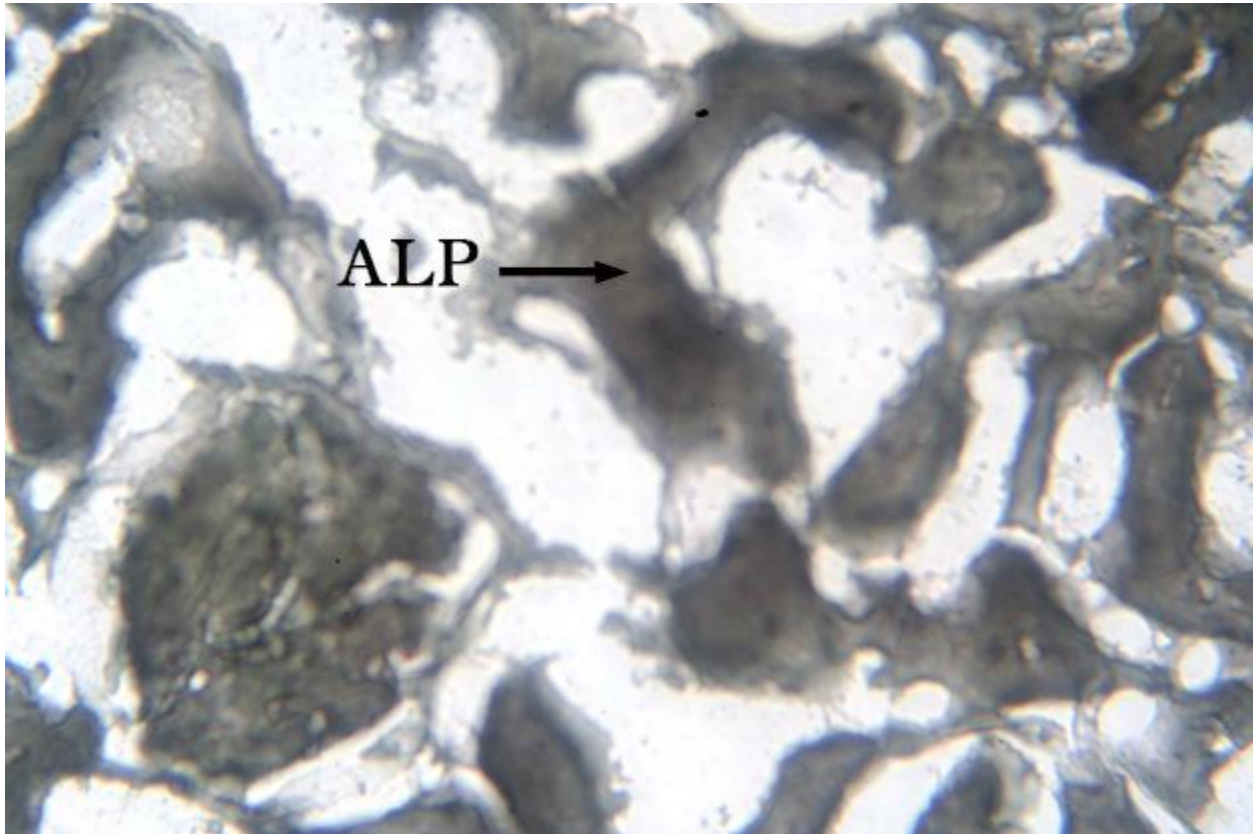


Figure-2

Gomori's Calcium Phosphate stained, 4 μm thick section of albino rat kidney showing grayish black Alkaline Phosphate particles (ALP) in Proximal tubule of Celecoxib treated group. (Photomicrograph x 400)

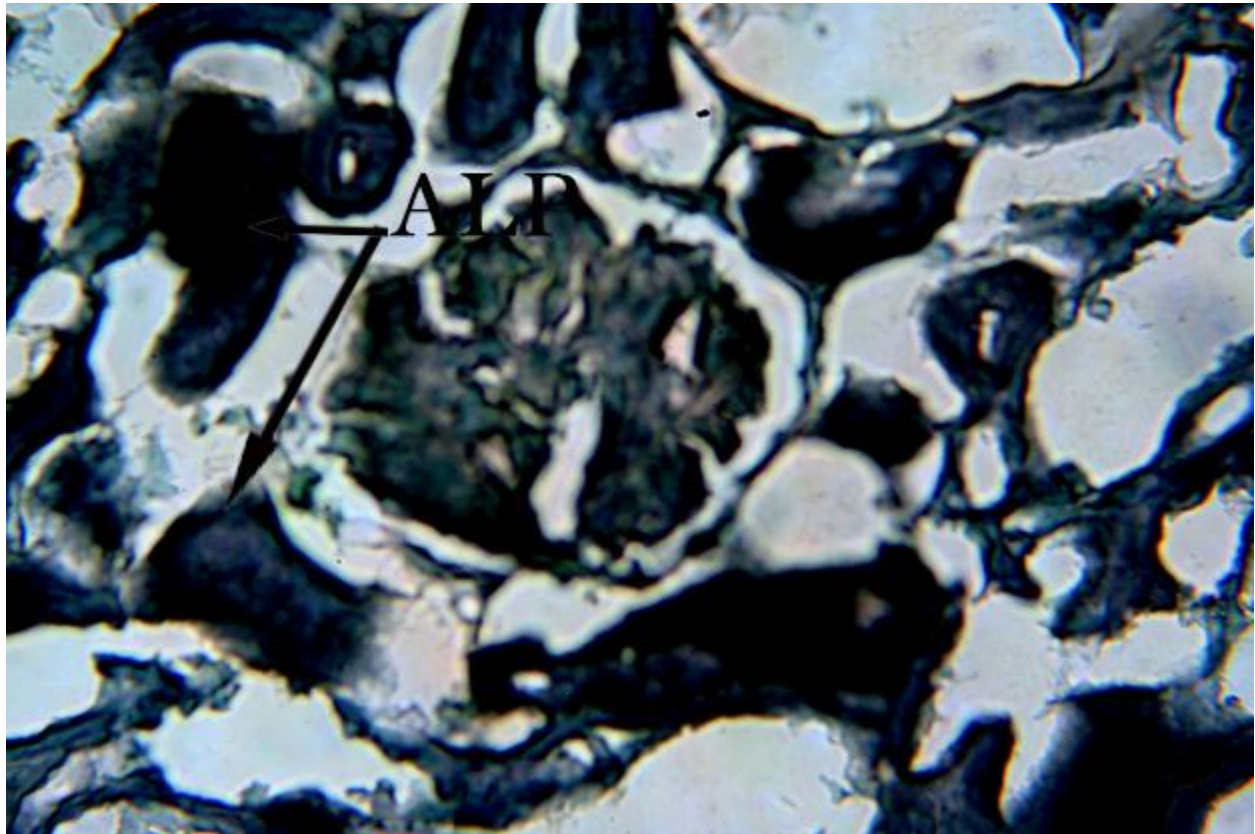
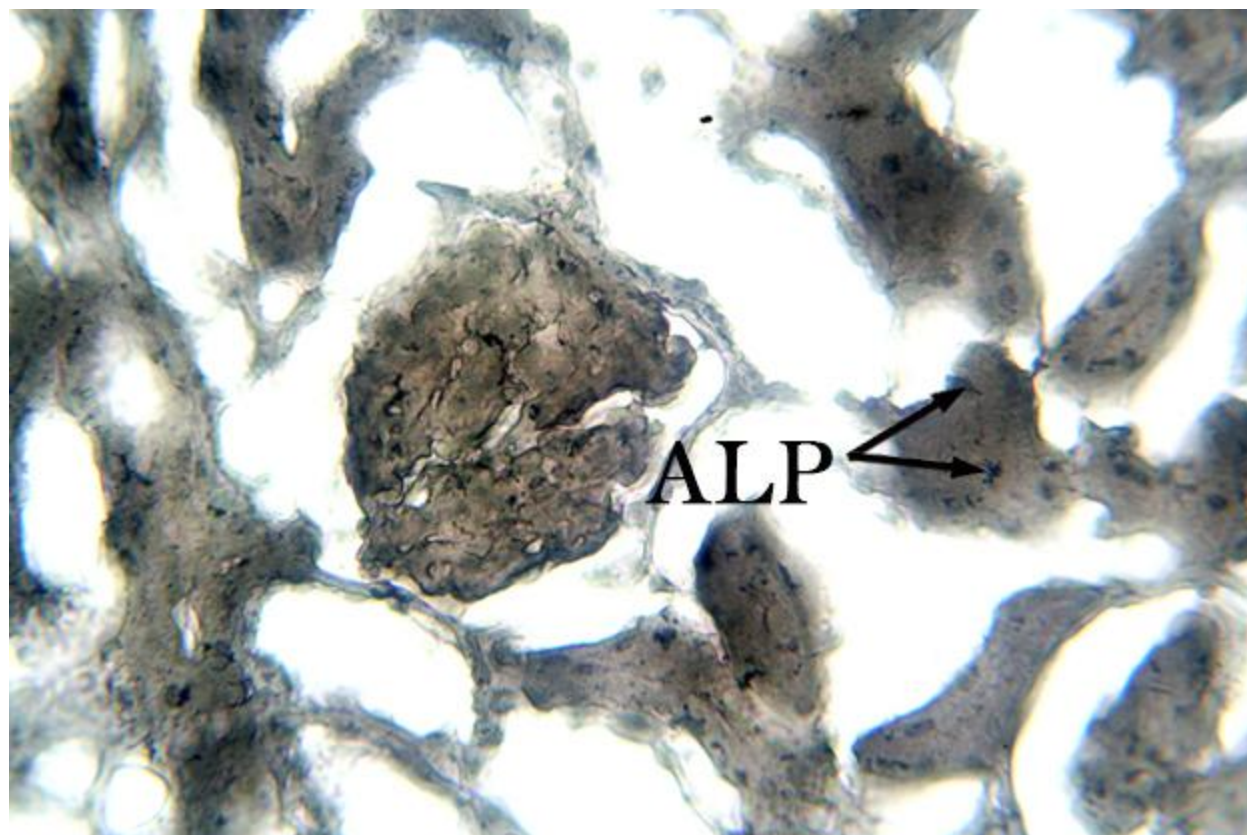


Figure-3

Gomori's Calcium Phosphate stained, 4 μ m thick section of albino rat kidney showing few Alkaline Phosphate particles (ALP) in Proximal tubule of Celecoxib + Lycopene treated group. (Photomicrograph x 400)



DISCUSSION:

NSAIDs administration is hazardous for nephropathy & causes inflammation by inhibiting COX enzyme develops renal injury. It blocks prostaglandins synthesis necessary for renal ischemia, renal perfusion & renin discharge.^{1,2} It is associated with various harmful effects like Peptic ulcers, dyspepsia, edema and retention of electrolytes.⁵

Lycopene is a red carotenoid antioxidant phytochemical noncyclic complex found in apricots, asparagus, parsley & other vegetables. Prevents lipid peroxidation & undergo oxidative, thermal and photo degradation, CNS injury, hepatic damage, renal damage, act as an anti-apoptotic mediator.^{15,16} Lycopene found in blood plasma anti-carcinogenic, anti-inflammatory and

antioxidant in character. Inhibits prostaglandin synthesis & also prevents various malignancies, Alzheimer's ailment, & cardiovascular illnesses, as well as reduces ageing.¹⁷

Gomori's calcium phosphate stained kidney sections of gB showed marked accumulation of dark black particles of alkaline phosphate in cellular cytoplasm of proximal convoluted tubules. Similar results were also explained by^{9,13} who said that numerous nephrotoxins injured proximal convoluted tubules by varying alkaline phosphatase action & raised levels are closely related with renal ailment & death of patients.

Gomori's calcium phosphate stained section of gC showed rare deposition of black particles of alkaline phosphate in the cellular cytoplasm at apical surface of proximal convoluted renal tubules. Similar results were also explained by^{15,25} who determined that amendment & reversal of harmful effects in serum levels of alkaline phosphatase occur with administration of lycopene due to its potent antioxidant properties.

CONCLUSION:

This experimental research study concluded that gB rats had marked accumulation of dark black particles of alkaline phosphate in cellular cytoplasm of proximal convoluted tubules due to renal injury on the other hand gC animals presented with rare deposition of black particles of alkaline phosphate in the cellular cytoplasm. Thus our hypothesis from this experimental work is that celebrex is injurious for kidneys & other vital organs while lycopene is advantageous for health because of its anti-oxidative properties.

LIMITATION OF STUDY

we have insufficient funds to do it in more depth.

ETHICAL APPROVAL

Anatomy department of BMSI gave us ethical approval. (Ethical review board No.F-1-2/BMSI-E.COMT/039/JPMC).

COMPETING INTERESTS DISCLAIMER:

No conflict of interests exists in this study.

REFERENCES

1. Okamoto K, Saito Y, Narumi K, Furugen A, Iseki K, Kobayashi M. Comparison of the nephroprotective effects of non-steroidal anti-inflammatory drugs on cisplatin-induced nephrotoxicity in vitro and in vivo. *European Journal of Pharmacology*. 2020 Oct 5; 884: 173339.
2. Zhigalov SA, Marasaev VV. Impact of the selectivity and half-life of nonsteroidal anti-inflammatory drugs on the development of subclinical kidney injury. *Modern Rheumatology Journal*. 2016 Dec 15;10 (4):28-34.
3. Ahmad S, Panda BP, Fahim M, Dhyani N, Dubey K. Ameliorative effect of beraprost sodium on celecoxib induced cardiotoxicity in rats. *Iranian journal of pharmaceutical research: IJPR*. 2018;17(1):155.
4. Luo B, Lin Y, Jiang S, Huang L, Yao H, Zhuang Q, Zhao R, Liu H, He C, Lin Z. Endoplasmic reticulum stress eIF2 α -ATF4 pathway-mediated cyclooxygenase-2 induction regulates cadmium-induced autophagy in kidney. *Cell death & disease*. 2016 Jun;7(6):e225.
5. Afshin Zarghi* and Sara Arfaei. Selective COX-2 Inhibitors: A Review of Their Structure-Activity Relationships. *Iranian Journal of Pharmaceutical Research*; 2011, 4, 655-683.

6. Cooper DL, Murrell DE, Conder CM, Palau VE, Campbell GE, Lynch SP, Denham JW, Hanley AV, Bullins KW, Panus PC, Singh K. Exacerbation of celecoxib-induced renal injury by concomitant administration of misoprostol in rats. *PloS one*. 2014 Feb 21;9(2):e89087.
7. Ogidi OI, Ogoun TR, Njoku CO, Charles EE, Amgbare EB, Omotehinse ET. Toxicity Studies on the Effects of Non-Steroid,2020; 55010-55014.
8. Meghji KA, Memon TF, Ahmed I, Memon SG, Noor N, Abbas A. Nephroprotective Effects of L-Arginine against Chemotherapy Induced Acute Kidney Injury in Wistar Rats. *Journal of Islamabad Medical & Dental College*. 2020 Dec 31;9(4):249-55.
9. Chouhan S, Sharma S. Diclofenac Mediated Demodulation of Alkaline Phosphatase and Renal Cortical Damage in Experimental Albino Mice. In *Proceedings of the Zoological Society* 2014 Jun (Vol. 67, No. 1, pp. 43-52). Springer India.
10. Chris Walker. Are All Oral COX-2 Selective Inhibitors the Same? A Consideration of Celecoxib, Etoricoxib, and Diclofenac. *International Journal of Rheumatology*; 2018, 2, 325-337.
11. Ruschitzka F, Borer JS, Krum H, Flammer AJ, Yeomans ND, Libby P, Lüscher TF, Solomon DH, Husni ME, Graham DY, Davey DA. Differential blood pressure effects of ibuprofen, naproxen, and celecoxib in patients with arthritis: the PRECISION-ABPM (Prospective Randomized Evaluation of Celecoxib Integrated Safety Versus Ibuprofen or Naproxen Ambulatory Blood Pressure Measurement) Trial. *European heart journal*. 2017 Nov 21;38(44):3282-92.

12. Alsaegh H, Eweis H, Kamal F, Alrafiah A. Celecoxib Decrease Seizures Susceptibility in a Rat Model of Inflammation by Inhibiting HMGB1 Translocation. *Pharmaceuticals*. 2021 Apr;14(4):380.
13. Sumida K, Molnar MZ, Potukuchi PK, Thomas F, Lu JL, Obi Y, Rhee CM, Streja E, Yamagata K, Kalantar-Zadeh K, Kovesdy CP. Prognostic significance of pre-end-stage renal disease serum alkaline phosphatase for post-end-stage renal disease mortality in late-stage chronic kidney disease patients transitioning to dialysis. *Nephrology Dialysis Transplantation*. 2018 Feb 1;33(2):264-73.
14. Zhu J, Sounthonevat C, Walker C. Celecoxib for the Treatment of Ankylosing Spondylitis. *J Rheumatol Arthritic Dis*. 2017; 2(1):1-2.
15. Hedayati N, Naeini MB, Nezami A, Hosseinzadeh H, Wallace Hayes A, Hosseini S, Imenshahidi M, Karimi G. Protective effect of lycopene against chemical and natural toxins: A review. *BioFactors*. 2019 Jan;45(1):5-23.
16. Shalaby AM, El Shaer DF. Lycopene protects against renal cortical damage induced by nandrolone decanoate in adult male rats. *Annals of Anatomy-Anatomischer Anzeiger*. 2019 Jul 1;224:142-52.
17. Kaya C, Karabulut R, Turkyilmaz Z, Sonmez K, Kulduk G, Gülbahar Ö, Köse F, Basaklar AC. Lycopene has reduced renal damage histopathologically and biochemically in experimental renal ischemia-reperfusion injury. *Renal failure*. 2015 Sep 14; 37(8):1390-5.
18. Stojiljkovic N, Ilic S, Jakovljevic V, Stojanovic N, Stojnev S, Kocic H, Stojanovic M, Kocic G. The encapsulation of lycopene in nanoliposomes enhances its protective

potential in methotrexate-induced kidney injury model. *Oxidative medicine and cellular longevity*. 2018 Jan 1.

19. Atilgan HI, Aydin A, Sadic M, Korkmaz M, Karakan T, Ogus E, Borcek P, Koca G. The protective effect of lycopene on kidney against experimentally induced unilateral ureteral obstruction. *Acta Medica Mediterranea*. 2016;32:1631-6.
20. Stojiljković N, Ilić S, Stojanović N, Stojanović S, Stojiljković M. Lycopene improves methotrexate-induced functional alterations of the Madin–Darby kidney cells in a concentration-dependent manner. *Canadian journal of physiology and pharmacology*. 2020;98(2):111-6.
21. Haghighipour S, Soltani R, Anjomshoa A. The protective effect of lycopene supplement against vancomycin-induced nephrotoxicity; a randomized double-blind placebo-controlled clinical trial. *Journal of Renal Injury Prevention*. 2020 Jul 28;9(4)32.
22. Zhao Y, Li MZ, Shen Y, Lin J, Wang HR, Talukder M, Li JL. Lycopene prevents DEHP-induced Leydig cell damage with the Nrf2 antioxidant signaling pathway in mice. *Journal of agricultural and food chemistry*. 2019 Dec 8;68(7):2031-40.
23. Patil AA, Doijad R, Koparde A. Renoprotective effect of Lycopene on Renal Functional and Histopathological changes in Gentamycin Induced Nephrotoxicity in Rats. *Research Journal of Pharmacy and Technology*. 2020;13(7):3237-40.
24. Abdel-Daim MM, Eissa IA, Abdeen A, Abdel-Latif HM, Ismail M, Dawood MA, Hassan AM. Lycopene and resveratrol ameliorate zinc oxide nanoparticles-induced oxidative stress in Nile tilapia, *Oreochromis niloticus*. *Environmental Toxicology and Pharmacology*. 2019 Jul 1;69:44-50.

25. El-Sheshtawy SM, El-Zoghby AF, Shawky NA, Samak DH. Aflatoxicosis in Pekin duckling and the effects of treatments with lycopene and silymarin. *Veterinary world*. 2021 Mar;14(3):788.
26. Kockaya EA, Selmanoglu G, Kismet K & Akay MT. Pathological and biochemical effects of therapeutic and supratherapeutic doses of Celecoxib in wistar albino rats. *Drug and chemical Toxicology*. 2010 Oct 1; 33(4): 410-414.
27. Luo C, Wu XG. Lycopene Enhances Antioxidant Enzyme Activities and Immunity Function in N-Methyl-N'-nitro-N-nitrosoguanidine-Induced Gastric Cancer Rats. *International journal of molecular sciences*. 2011 May 23; 12(5):3340-51.
28. Bancroft JD. *Histochemical techniques*. Butterworth-Heinemann; 2013 Oct 22.