

Original Research Article

INCIDENCE OF TRAUMATIC ULCER AMONG THE PATIENTS VISITING PRIVATE DENTAL HOSPITAL - RETROSPECTIVE STUDY

Running Title: Traumatic Ulcer Incidence in patients visiting dental hospital.

ABSTRACT:

INTRODUCTION: Oral mucosal ulcers are one of the most common types of ulcer of which Traumatic ulcers are common and acute in nature, caused by some form of trauma to the mucous membrane in the oral cavity. It is most commonly seen in the Buccal Mucosa, Lips, and occasionally in the Palate and Lateral border of tongue. It is caused by physical, chemical or thermal trauma resulting in damage and ulcer formation.

MATERIALS AND METHOD: The data for the present study n = 345 patients was collected by analysing case sheets of patients who visited Saveetha Dental College from June 2019-February 2021. The collected data was subjected to statistical analysis using the SPSS software by IBM of version 23.

RESULTS: From the results of the study, Traumatic Ulcer has Male predilection with incidence rate of 62.2% compared to females with incidence of 37.7%. Most of them were in the age group of 21-30 years age group (34.5%) and least in the 71-85 years age group (2.9%). Traumatic ulcer was most common in the Alveolar mucosa (32.2%)

CONCLUSION: From the present study it can be concluded that Traumatic ulcer is more common in Males. However, Gender, Age, Oral Hygiene, Usage of Tobacco products were not significantly influencing the rate of incidence of Traumatic Ulcer.

KEYWORDS: Buccal mucosa, Oral Mucosal Lesion, Squamous Cell Carcinoma of head and neck, Traumatic Ulcer.

INTRODUCTION:

Oral health is important to maintain the quality of life of all individuals. The oral mucosa serves as a protective barrier against trauma, pathogens, and carcinogenic agents [1,2]. Oral lesions can interfere with daily social activities in involved patients through impact on mastication, swallowing, and speech, and symptoms such as xerostomia, halitosis, or dysesthesia [3]. Diagnosis of the wide variety of lesions that occur in the oral cavity is an essential part of dental practice. Proper clinical management of a patient with an oral lesion starts with an accurate diagnosis. Hence, oral soft tissue examination is crucial and should be done systematically to include all parts of the oral cavity [4].

An Ulcer can be defined as a break or discontinuity in the integrity of the skin or mucous membrane with loss of surface tissue and disintegration of the epithelium [5–7]. Oral mucosal ulcers are one of the most common types of ulcers, which may or may not be associated with systemic diseases. Oral ulcers may present as a single ulcerative lesion or as multiple ulcerative lesions. Aphthous ulcer and Traumatic ulcer are the most common types of oral mucosal ulcers. Aphthous ulcer is painful and inflammatory ulceration of the oral mucosa. It usually appears as multiple pinpoint ulcers in the mucous membrane [8]. The aetiology of Aphthous ulcer is usually Idiopathic in nature but also associated with various systemic diseases like Malabsorption syndrome, inflammatory bowel disease, vitamin deficiencies, etc. The management of Aphthous Ulcer is the usage of Topical Non-Steroidal Anti-Inflammatory Drugs (NSAIDs) , Corticosteroids, Mouthwash for maintaining proper oral hygiene [9,10].

Traumatic ulcers are common and acute in nature, caused by some form of trauma to the mucous membrane in the oral cavity. The ulcer is most commonly seen in the Buccal Mucosa, Lips, and occasionally in the Palate and Lateral border of the tongue [11,12]. A traumatic ulcer can be caused by physical, chemical, or thermal trauma resulting in damage and ulcer formation in the mucous membrane [13]. Physical trauma includes harsh tooth brushing, flossing, the sharp cusp of the tooth, ill-fitting dentures, orthodontic appliances, cheek biting, lip biting [14,15]. Consumption of very hot food, accidental injury with a heated dental instrument are some Thermal causes of traumatic ulcer. thermal ulceration is most commonly seen in the palate and posterior part of the buccal mucosa. Some of the dental materials like eugenol, Sodium

Hypochlorite, Formocresol, Monomer can cause chemical ulceration, other causes include holding Aspirin tablets next to a painful tooth, Silver nitrate [16].

Traumatic ulcers can be Acute or Chronic in nature. Acute ulcers are usually self-resolving in nature within 5-7 days, whereas Chronic Traumatic ulcers are commonly found in Buccal mucosa, lateral border of Tongue, or Lips . It usually presents as a solitary ulcer with shallow or sometimes deep epithelial discontinuity and also showing peripheral keratosis of varying degrees. The ulcer heals with or without scar formation depending on the extent of the ulceration, on eliminating the causative factor for the trauma .

Epidemiologic studies provide information important to understanding the prevalence, incidence, and severity of oral disease in a specific population, but the results of such studies (including those on the established variety of changes that can occur in the oral mucosa) have rarely been published worldwide.

Our team has extensive knowledge and research experience in various aspects that has translated into high quality publications [17-35]. With this background, the present study aims to assess the incidence of Traumatic Ulcers among the patients visiting a Private Dental Hospital in Chennai.

MATERIALS AND METHODS:

The data for the present study were collected by analysing case sheets of 5,35,951 out-patients who had visited Saveetha Dental College from June 2019- February 2021, the case sheets were reviewed and analysed individually. Ethical approval was obtained from the institutional ethical committee (Ethical approval number: SDC/SIHEC/2020DIASDATA/0619-0320). The advantages of the present study are available data and similar ethnicity and geographical locations and the isolated populations could be the limitations of our study

The inclusion criteria for the study were mainly the patients having oral ulceration due to Trauma, age group of 5-80 years, and complete available data were considered. The exclusion criteria for this study were patients below the age group of 20 and patients with medical complications, incomplete and censored data. Based on the inclusion and exclusion criteria the sample size was n= 345 including the Age, Gender, Site of the Traumatic Ulcer, treatment given, and presence of any systemic problems. The case sheet verification was done using the photographic method. To minimise sampling bias simple random sampling was done. The collected data were subjected to statistical analysis using the SPSS software by IBM of version

23 in which both the descriptive and the inferential test has been done, which was the Chi-square test. The dependent variables were Traumatic Ulcer and the Independent variables were Age and Gender.

RESULTS:

Out of the n=345 patients who had Traumatic ulcer, 0.29% were in age group of 7-10 years, 6.69% in 11-20 years, 34.59% in 21-30 years, 20.35% in 31-40 years, 16.28% in 41-50 years, 10.47% in 51-60 years, 8.43% in 61-70 years, 2.9% in 71-85 years of age (Fig 1), among which 62.2% were males and 37.8% were Females (Fig 2). According to the present study, 14% had an ulcer in the upper arch buccal mucosa, 31.7% had an ulcer in the lower arch buccal mucosa, 22.1% had an ulcer in both upper and lower arch buccal mucosa and 32.2% had ulcers in the Alveolar mucosa near the specific tooth (Fig 3). Association of age and gender of traumatic ulcer revealed that there was a significant association between them, males in the age group of 21 - 30 years had increased incidence of traumatic ulcer (p-value = 0.02) (Fig 4). Association of gender with the site of traumatic ulcer revealed that there is no significant association between them, (p-value = 0.2) (Fig 5).

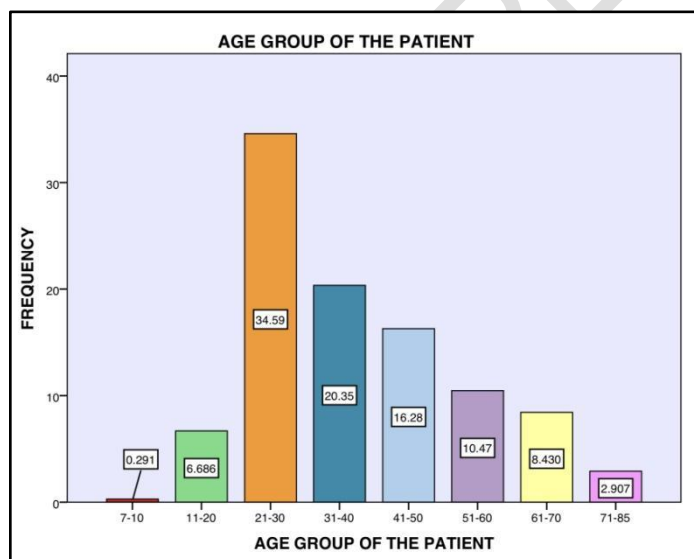


Figure 1, depicts the age group of the participants 0.29% were in the age group of 7-10 years (Red), 6.69% were in the age group of 11-20 years (Green), 34.59% were in the age group of 21-30 years (Orange), 20.35% were in the age group of 31-40 years (Dark Blue), 16.28% were in

the age group of 41-50 years (Light Blue), 10.47% were in the age group of 51-60 years (Indigo), 8.43% were in the age group of 61-70 years (Yellow), 2.9% were in the age group of 71-85 years (Pink).

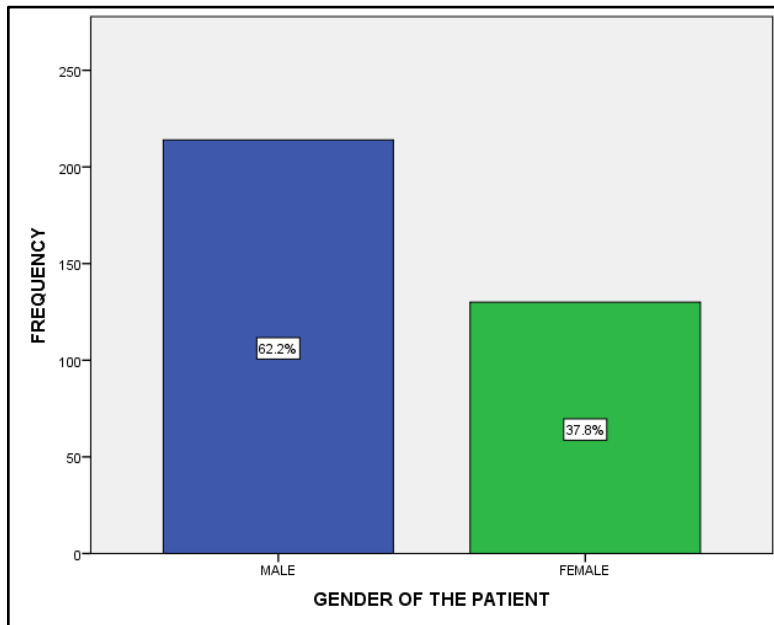


Figure 2, depicts the Gender of the Patient included in the present study. 62.2% were males represented in blue colour and 37.8% were females represented in Green colour.

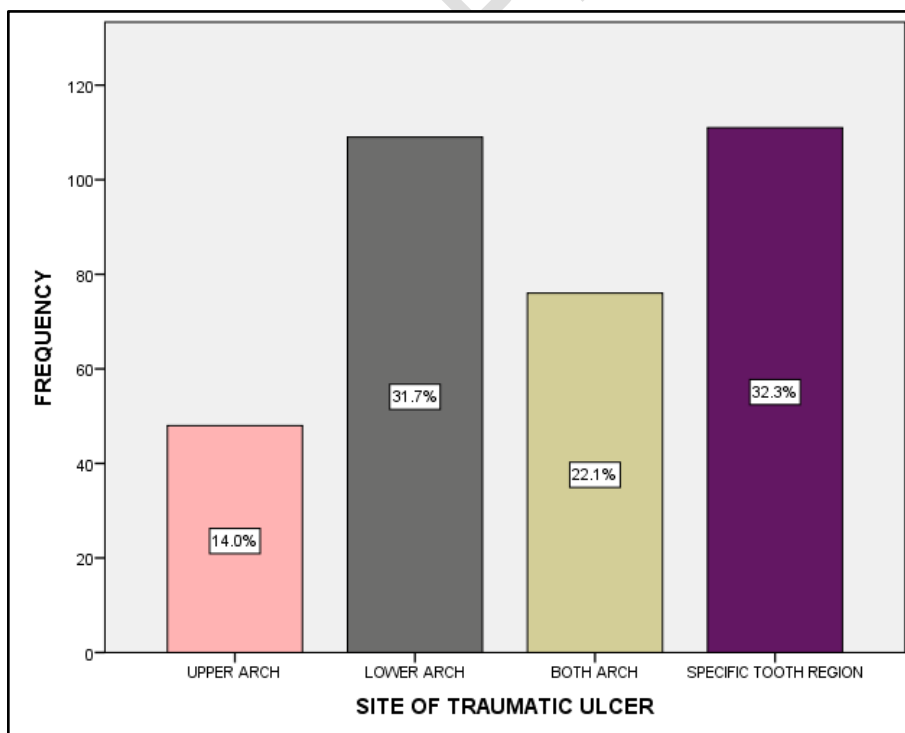


Figure 3, depicts the Site of the Ulcer in the Patients included in the present study. 14% had an ulcer in the upper arch buccal mucosa represented in peach colour, 31.7% had an ulcer in lower arch buccal mucosa represented in Grey colour, 22.1% had an ulcer in both upper and lower arch buccal mucosa represented in Brown colour and 32.2% had ulcers in the Alveolar mucosa near the specific tooth represented by violet colour.

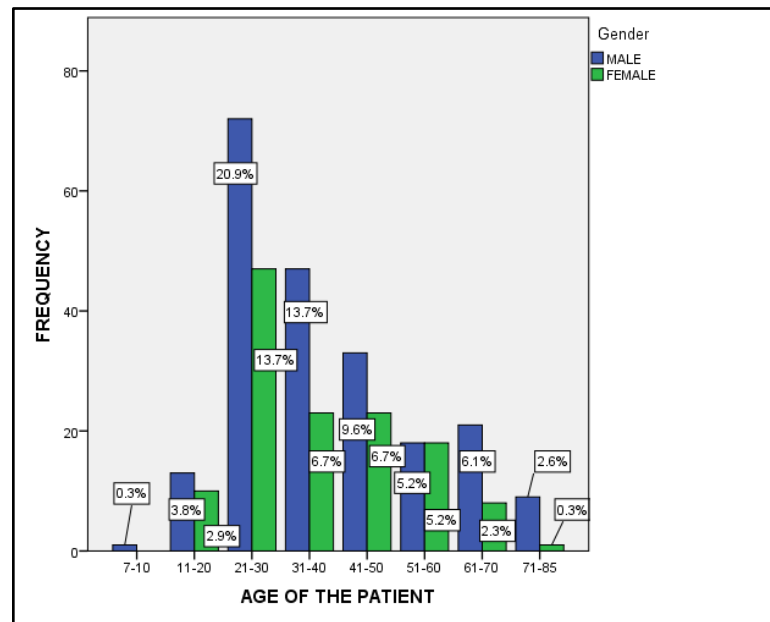


Figure 4, represents the association between Age Group and Gender of the patient included in the present study. The X-axis represents the Age group of the Patient and the Y-axis represents the Frequency Patients incident with Traumatic ulcer. Blue colour represents the Males and Green colour Females. Around 20.9% of Males were in the 21-30 years age group, whereas 13.7% of females were in the 21-30 years and 31-40 years age group. There is also Statistical Significance between Age Group and Gender of the patient included in the present study with chi-square value - 21.42 and p-value = 0.02, hence statistically significant, providing that Males of age group of 21-30 years (20.9%) had higher incidence of traumatic ulcer.

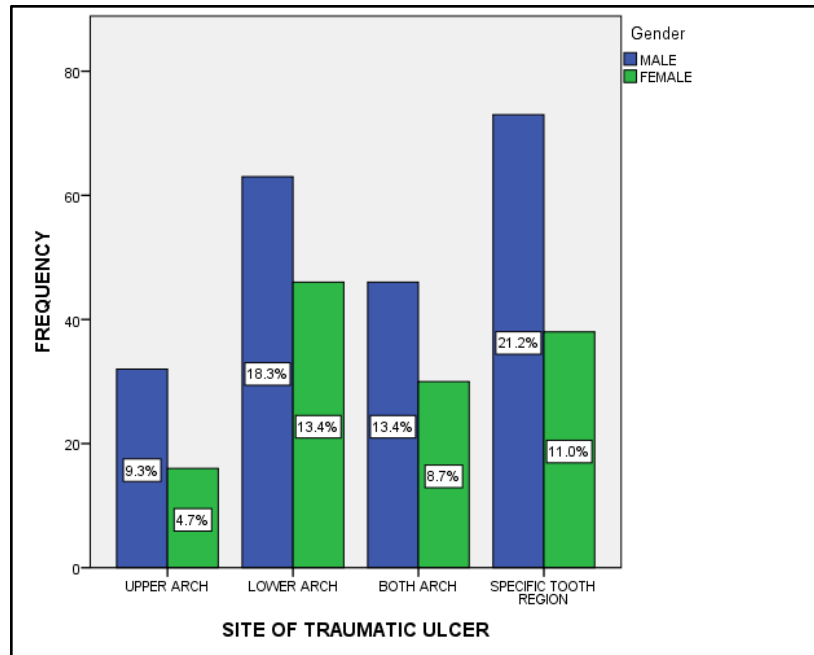


Figure 5, represents the association between the Site of the Traumatic Ulcer and the Gender of the patient included in the present study. The X-axis represents the Site of the Traumatic Ulcer and Y-axis represents the Frequency of patient incident with Traumatic ulcer. Blue colour represents the Males and Green colour Females. Around 21.2% of Males had ulceration in the alveolar mucosa near the specific tooth which induced the ulceration, whereas 13.4% of females had ulceration in the lower arch buccal mucosa. However this is statistically not significant with chi-square value - 18.42 and $p\text{-value} = 0.2$, hence statistically insignificant, even though Males had higher incidence of Traumatic ulcer in alveolar mucosa near the specific tooth (21.2%).

DISCUSSION:

Traumatic Ulcers are usually solitary lesions with an erythematous margin. Despite Traumatic ulcer being the most common ulcer the rate of incidence of Traumatic Ulcer in the present study was only 0.06%. The rate of incidence is lesser which might be attributed to misjudgment of the ulcer as Aphthous ulcer or ignorance of the ulcer. In a study by Aishwarya et al., [36] The rate of incidence of the traumatic ulcer was higher, imparting 17.5% among the other oral mucosal lesions. This increased rate is due to rough brushing, Sharp cusps of teeth in old age people.

There is no specific age group or category of persons for Traumatic Ulcer incidence. It can occur in any age group due to any kind of trauma to the oral mucosa like accidental cheek biting. Lip biting, sharp cusps, hard food substances, consumption of hot food. In the present study, it was

found in early adulthood 34.5% were in 21-30 years of age followed by 20.3% in 31-40 years of age (Fig 1). It is more common in this age group of increased Orthodontic Treatment during a Young age. In concordance with the present study, Amadori et al., [37] also demonstrated that Traumatic ulcer was more common in Teenagers, which was most likely associated with the health status and behavioural changes during the adolescence period [38]. In contrast to it Gambhir et al., reported a high incidence of mucosal lesion in the old age group of more than 50 years of age, which is due to prolonged usage of Tobacco products, usage of dental prosthesis caused traumatic lesions in the old age group compared young age [39]

Oral Traumatic Ulcers are more common in males compared to that of Females, the prevalence rate in the present study was 62.2% in males and 37.7% in females (Fig 2). It is more common in Males as comparatively, they have increased biting forces than the Females. Also, males have an increased risk because of the usage of Tobacco products [40]. Usage of Tobacco products has high chances of producing Oral Potentially Malignant Disorders (OPMD) like Leukoplakia, Erythroplakia, Oral Submucous Fibrosis, Lichen Planus which subsequently transform into an Oral Squamous Cell Carcinoma . Owing to the increased rate of Oral Squamous Cell Carcinoma, Chronic Traumatic Ulcer must be considered seriously, a persistent ulcer even after eliminating the cause and treating the ulcer should be considered for biopsy to rule out the Oral Squamous Cell Carcinoma . In congruence with the present study Sheet et al., [41] also had a high prevalence of mucosal lesions in 85% of the Males, also women are more mindful about their oral hygiene which reduced the incidence of ulcers.

Traumatic ulceration is more commonly seen in the Alveolar mucosa in 32.2% of the patients and 31.6% of them had an ulcer in the lower arch buccal mucosa (Fig 3). Ulcers in the alveolar mucosa were most likely to be contributed by the sharp cusps of the teeth . Accidental biting of the mucosa. In a study by Prithivraj et al., the most common site of the mucosal lesion was the Buccal mucosa and the least affected site was the lip and the hard palate [35]. In a study by Ghannaei et al., [42] the lateral border of the tongue was the most common site of traumatic ulcers in Iran [43].

In both Male and Females who presented with Traumatic ulcers, the majority of them were in the age group of 21-30 years, Of which 20.9% of them were Males and 13.7% were females (Fig 4). Males usually have more biting forces comparatively which is more likely to injure the mucosa and cause an ulceration. Also at a young age, patients prefer Orthodontic treatment for Cosmetic reasons. Also, 21.2% of Males had ulceration in the Alveolar mucosa and 13.4% of females had

ulceration in the Lower arch Buccal mucosa (Fig 5). Several studies had reported that Buccal mucosa is the common site for traumatic ulcers as it is more prone to accidental cheek biting, irritation of braces or appliance wires during orthodontic treatment [44]

Most often, traumatic ulcers can heal spontaneously and uneventfully without complications in a brief period [45,46]. But, in case of persistent traumatic factors, such as the presence of sharp tooth morphology, cutting edges of restorations, and puncturing appliance contours, especially inadequate surfaces of removable prosthesis, continuous trauma arising from the above-mentioned causes can lead to the formation of chronic ulcers which has high risk of transforming into an Oral Squamous Cell Carcinoma [47].

With the limitations of the small sample size and restricted region is taken into consideration, has attempted to categorise and demographic profile patients who had an incidence of Traumatic ulcer. In the future, further research can be conducted over a large sample size and wide inclusion of geographic location which helps to intervene and create awareness on the importance of maintaining oral hygiene and any ulcers had to be intervened as early as possible to prevent any malignant transformation.

CONCLUSION:

Oral cavity ulcerations are caused by any of a spectrum of etiologic factors including infection, immune dysregulation, trauma, and neoplasms. Through careful clinical and medical history and clinical evaluation may lead to a strong presumptive clinical diagnosis, a biopsy may be necessary to confirm the diagnosis or rule out neoplastic sources. From the present study, it can be concluded that Traumatic ulcer is more common in Males. However, Gender, Age, Oral Hygiene, Usage of Tobacco products were not significantly influencing the rate of incidence of Traumatic ulcers. Larger community-based studies should be conducted to estimate more representative percentages of Traumatic ulcers.

COMPETING INTERESTS DISCLAIMER:

Authors have declared that no competing interests exist. The products used for this research are commonly and predominantly used in our area of research and country. There is absolutely no conflict of interest between the authors and producers of the products because we do not intend

to use these products as an avenue for any litigation but for the advancement of knowledge. Also, the research was not funded by the producing company rather it was funded by personal efforts of the authors.

REFERENCES:

1. Verma S, Sharma H. Prevalence of Oral mucosal lesions and their association with Pattern of tobacco use among patients visiting a dental institution [Internet]. Vol. 30, Indian Journal of Dental Research. 2019. p. 652. Available from: http://dx.doi.org/10.4103/ijdr.ijdr_23_18
2. Jeevanandan G, Thomas E. Volumetric analysis of hand, reciprocating and rotary instrumentation techniques in primary molars using spiral computed tomography: An in vitro comparative study [Internet]. Vol. 12, European Journal of Dentistry. 2018. p. 021–6. Available from: http://dx.doi.org/10.4103/ejd.ejd_247_17
3. Sholapurkar A, Vengal M, Mathew A, Pai K. The prevalence of oral mucosal lesions in patients visiting a dental school in Southern India [Internet]. Vol. 19, Indian Journal of Dental Research. 2008. p. 99. Available from: <http://dx.doi.org/10.4103/0970-9290.40461>
4. Al-Mobeeriek A, AIDosari AM. Prevalence of Oral Lesions Among Saudi Dental Patients [Internet]. Vol. 29, Annals of Saudi Medicine. 2009. p. 365–8. Available from: <http://dx.doi.org/10.5144/0256-4947.2009.365>
5. Casilda S l., Priyadharsini j. V, Hannah R, Ramani P, Gheena S, Ramasubramaniam A. A study on the variability of drug responsiveness to anti inflammatory drugs - A pilot survey [Internet]. Vol. 12, International Journal of Pharmaceutical Research. 2020. Available from: <http://dx.doi.org/10.31838/ijpr/2020.12.02.0261>
6. Traumatic Ulcer [Internet]. Treatment of Oral Diseases. 2005. Available from: <http://dx.doi.org/10.1055/b-0034-55881>

7. Ponnulakshmi R, Shyamaladevi B, Vijayalakshmi P, Selvaraj J. In silico and in vivo analysis to identify the antidiabetic activity of beta sitosterol in adipose tissue of high fat diet and sucrose induced type-2 diabetic experimental rats. *Toxicol Mech Methods* [Internet]. 2019 May;29(4):276–90. Available from: <http://dx.doi.org/10.1080/15376516.2018.1545815>
8. Thompson LDR. Oral traumatic ulcer [Internet]. Vol. 90, *Ear, Nose & Throat Journal*. 2011. p. 518–34. Available from: <http://dx.doi.org/10.1177/014556131109001109>
9. Lu J, Zhang N, Qian W. The clinical efficacy and safety of traditional Chinese medicine in the treatment of recurrent aphthous stomatitis: A protocol of systematic review and meta-analysis. *Medicine* [Internet]. 2020 Oct 2;99(40):e22588. Available from: <http://dx.doi.org/10.1097/MD.00000000000022588>
10. Kwon KJ, Jeong SJ, Eun Y-G, Oh IH, Lee YC. Risk of cancer in patients with recurrent aphthous stomatitis in Korea: A nationwide population-based study. *Medicine* [Internet]. 2021 Apr 23;100(16):e25628. Available from: <http://dx.doi.org/10.1097/MD.00000000000025628>
11. Sethi A, Banga A, Raja R, Raina R. Traumatic ulcerative granuloma with stromal eosinophilia. *Indian J Dent Res* [Internet]. 2020 Jul;31(4):636–9. Available from: http://dx.doi.org/10.4103/ijdr.IJDR_330_18
12. Pizzorno JE, Murray MT, Joiner-Bey H. Aphthous stomatitis (aphthous ulcer/canker sore/ulcerative stomatitis) [Internet]. *The Clinician's Handbook of Natural Medicine*. 2016. p. 60–4. Available from: <http://dx.doi.org/10.1016/b978-0-7020-5514-0.00015-4>
13. Behera A, Hannah R, Ramasubramanian A, Ramani P. Association of the Depth of Invasion with Lymph Node Metastasis in Oral Squamous Cell Carcinoma Patients - A Retrospective Study [Internet]. *Indian Journal of Forensic Medicine & Toxicology*. 2020. Available from: <http://dx.doi.org/10.37506/ijfmt.v14i4.12542>
14. Agustina D. Oral hygiene and number of oral mucosal lesion correlate with oral health-related quality of life in elderly communities [Internet]. Vol. 47, *Dental Journal*

(Majalah Kedokteran Gigi). 2014. p. 57. Available from: <http://dx.doi.org/10.20473/j.djmk.v47.i1.p57-61>

15. Ogunrinde TJ, Olawale OF. The prevalence of denture related mucosa lesions among patients managed in a Nigerian teaching hospital. *Pan Afr Med J* [Internet]. 2020 Dec 21;37:358. Available from: <http://dx.doi.org/10.11604/pamj.2020.37.358.22194>

16. Thamilselvan S, Abilasha R, Ramani P, Gheena S, Hannah R. Evaluation of Accuracy between Habit History and Incidence of Oral Squamous Cell Carcinoma [Internet]. *International Journal of Current Research and Review*. 2020. p. 30–5. Available from: <http://dx.doi.org/10.31782/ijcrr.2020.122503>

17. Princeton B, Santhakumar P, Prathap L. Awareness on Preventive Measures taken by Health Care Professionals Attending COVID-19 Patients among Dental Students. *Eur J Dent* [Internet]. 2020 Dec;14(S 01):S105–9. Available from: <http://dx.doi.org/10.1055/s-0040-1721296>

18. Mathew MG, Samuel SR, Soni AJ, Roopa KB. Evaluation of adhesion of *Streptococcus mutans*, plaque accumulation on zirconia and stainless steel crowns, and surrounding gingival inflammation in primary molars: randomized controlled trial. *Clin Oral Investig* [Internet]. 2020 Sep;24(9):3275–80. Available from: <http://dx.doi.org/10.1007/s00784-020-03204-9>

19. Sridharan G, Ramani P, Patankar S, Vijayaraghavan R. Evaluation of salivary metabolomics in oral leukoplakia and oral squamous cell carcinoma. *J Oral Pathol Med* [Internet]. 2019 Apr;48(4):299–306. Available from: <http://dx.doi.org/10.1111/jop.12835>

20. R H, Hannah R, Ramani P, Ramanathan A, Jancy MR, Gheena S, et al. CYP2 C9 polymorphism among patients with oral squamous cell carcinoma and its role in altering the metabolism of benzo[a]pyrene [Internet]. Vol. 130, *Oral Surgery, Oral Medicine, Oral Pathology and Oral Radiology*. 2020. p. 306–12. Available from: <http://dx.doi.org/10.1016/j.oooo.2020.06.021>

21. Antony JVM, Ramani P, Ramasubramanian A, Sukumaran G. Particle size penetration rate and effects of smoke and smokeless tobacco products - An invitro analysis.

Heliyon [Internet]. 2021 Mar;7(3):e06455. Available from: <http://dx.doi.org/10.1016/j.heliyon.2021.e06455>

22. Sarode SC, Gondivkar S, Sarode GS, Gadbail A, Yuwanati M. Hybrid oral potentially malignant disorder: A neglected fact in oral submucous fibrosis. Oral Oncol [Internet]. 2021 Jun 16;105390. Available from: <http://dx.doi.org/10.1016/j.oraloncology.2021.105390>

23. Hannah R, Ramani P, WM Tilakaratne, Sukumaran G, Ramasubramanian A, Krishnan RP. Author response for “Critical appraisal of different triggering pathways for the pathobiology of pemphigus vulgaris—A review” [Internet]. Wiley; 2021. Available from: <https://publons.com/publon/47643844>

24. Chandrasekar R, Chandrasekhar S, Sundari KKS, Ravi P. Development and validation of a formula for objective assessment of cervical vertebral bone age. Prog Orthod [Internet]. 2020 Oct 12;21(1):38. Available from: <http://dx.doi.org/10.1186/s40510-020-00338-0>

25. Subramanyam D, Gurunathan D, Gaayathri R, Vishnu Priya V. Comparative evaluation of salivary malondialdehyde levels as a marker of lipid peroxidation in early childhood caries. Eur J Dent [Internet]. 2018 Jan;12(1):67–70. Available from: http://dx.doi.org/10.4103/ejd.ejd_266_17

26. Ponnulakshmi R, Shyamaladevi B, Vijayalakshmi P, Selvaraj J. In silico and in vivo analysis to identify the antidiabetic activity of beta sitosterol in adipose tissue of high fat diet and sucrose induced type-2 diabetic experimental rats. Toxicol Mech Methods [Internet]. 2019 May;29(4):276–90. Available from: <http://dx.doi.org/10.1080/15376516.2018.1545815>

27. Sundaram R, Nandhakumar E, Haseena Banu H. Hesperidin, a citrus flavonoid ameliorates hyperglycemia by regulating key enzymes of carbohydrate metabolism in streptozotocin-induced diabetic rats. Toxicol Mech Methods [Internet]. 2019 Nov;29(9):644–53. Available from: <http://dx.doi.org/10.1080/15376516.2019.1646370>

28. Alsawalha M, Rao CV, Al-Subaie AM, Haque SKM, Veeraraghavan VP,

Surapaneni KM. Novel mathematical modelling of Saudi Arabian natural diatomite clay. *Mater Res Express* [Internet]. 2019 Sep 4 [cited 2021 Aug 10];6(10):105531. Available from: <https://iopscience.iop.org/article/10.1088/2053-1591/ab2f9b/meta>

29. Yu J, Li M, Zhan D, Shi C, Fang L, Ban C, et al. Inhibitory effects of triterpenoid betulin on inflammatory mediators inducible nitric oxide synthase, cyclooxygenase-2, tumor necrosis factor- α , interleukin-6, and proliferating cell nuclear antigen in 1, 2-dimethylhydrazine-induced rat colon carcinogenesis. *Pharmacogn Mag* [Internet]. 2020;16(72):836. Available from: <https://www.phcog.com/article.asp?issn=0973-1296;year=2020;volume=16;issue=72;spage=836;epage=842;aulast=Yu>

30. Shree KH, Hema Shree K, Ramani P, Herald Sherlin, Sukumaran G, Jeyaraj G, et al. Saliva as a Diagnostic Tool in Oral Squamous Cell Carcinoma – a Systematic Review with Meta Analysis [Internet]. Vol. 25, *Pathology & Oncology Research*. 2019. p. 447–53. Available from: <http://dx.doi.org/10.1007/s12253-019-00588-2>

31. Zafar A, Sherlin HJ, Jayaraj G, Ramani P, Don KR, Santhanam A. Diagnostic utility of touch imprint cytology for intraoperative assessment of surgical margins and sentinel lymph nodes in oral squamous cell carcinoma patients using four different cytological stains. *Diagn Cytopathol* [Internet]. 2020 Feb;48(2):101–10. Available from: <http://dx.doi.org/10.1002/dc.24329>

32. Karunagaran M, Murali P, Palaniappan V, Sivapathasundharam B. Expression and distribution pattern of podoplanin in oral submucous fibrosis with varying degrees of dysplasia – an immunohistochemical study [Internet]. Vol. 42, *Journal of Histotechnology*. 2019. p. 80–6. Available from: <http://dx.doi.org/10.1080/01478885.2019.1594543>

33. Sarode SC, Gondivkar S, Gadbail A, Sarode GS, Yuwanati M. Oral submucous fibrosis and heterogeneity in outcome measures: a critical viewpoint. *Future Oncol* [Internet]. 2021 Jun;17(17):2123–6. Available from: <http://dx.doi.org/10.2217/fon-2021-0287>

34. Raj Preeth D, Saravanan S, Shairam M, Selvakumar N, Selestina Raja I, Dhanasekaran A, et al. Bioactive Zinc(II) complex incorporated PCL/gelatin electrospun

nanofiber enhanced bone tissue regeneration. Eur J Pharm Sci [Internet]. 2021 May 1;160:105768. Available from: <http://dx.doi.org/10.1016/j.ejps.2021.105768>

35. Prithiviraj N, Yang GE, Thangavelu L, Yan J. Anticancer Compounds From Starfish Regenerating Tissues and Their Antioxidant Properties on Human Oral Epidermoid Carcinoma KB Cells. In: Pancreas. Lippincott Williams & Wilkins Two Commerce Sq, 2001 Market St, Philadelphia ...; 2020. P. 155–6.

36. B AR, Aishwarya RB, Herald J. Sherlin, Nivethigaa B. Traumatic oral mucosal lesions in elderly dental patients - An institutional study [Internet]. Vol. 11, International Journal of Research in Pharmaceutical Sciences. 2020. p. 1054–9. Available from: <http://dx.doi.org/10.26452/ijrps.v11ispl3.3334>

37. Amadori F, Bardellini E, Conti G, Majorana A. Oral mucosal lesions in teenagers: a cross-sectional study [Internet]. Vol. 43, Italian Journal of Pediatrics. 2017. Available from: <http://dx.doi.org/10.1186/s13052-017-0367-7>

38. Princeton B, Santhakumar P, Prathap L. Awareness on Preventive Measures taken by Health Care Professionals Attending COVID-19 Patients among Dental Students. Eur J Dent [Internet]. 2020 Dec;14(S 01):S105–9. Available from: <http://dx.doi.org/10.1055/s-0040-1721296>

39. Gambhir RS, Veerasha KL, Sohi R, Kakkar H, Aggarwal A, Gupta D. The prevalence of oral mucosal lesions in the patients visiting a dental school in Northern India in relation to sex, site and distribution: A retrospective study [Internet]. Journal of Clinical and Experimental Dentistry. 2011. p. e10–7. Available from: <http://dx.doi.org/10.4317/jced.3.e10>

40. Sinduja P, Ramani P, Gheena S, Ramasubramanian A. Expression of metallothionein in oral squamous cell carcinoma: A systematic review. J Oral Maxillofac Pathol [Internet]. 2020 Jan;24(1):143–7. Available from: http://dx.doi.org/10.4103/jomfp.JOMFP_137_19

41. Shet RGK, Shetty SR, Kalavathi M, Naveen Kumar M, Yadav RD, Soumya S. A Study to evaluate the Frequency and Association of Various Mucosal Conditions among

Geriatric Patients [Internet]. Vol. 14, The Journal of Contemporary Dental Practice. 2013. p. 904–10. Available from: <http://dx.doi.org/10.5005/jp-journals-10024-1424>

42. Ghanaei FM, Joukar F, Rabiei M, Dadashzadeh A, Valeshabad AK. Prevalence of Oral Mucosal Lesions in an Adult Iranian Population [Internet]. Vol. 15, Iranian Red Crescent Medical Journal. 2013. p. 600–4. Available from: <http://dx.doi.org/10.5812/ircmj.4608>

43. R H, Hannah R, Ramani P, Tilakaratne WM, Sukumaran G, Ramasubramanian A, et al. Author response for “Critical appraisal of different triggering pathways for the pathobiology of pemphigus vulgaris—A review” [Internet]. 2021. Available from: <http://dx.doi.org/10.1111/odi.13937/v2/response1>

44. Krishnan R, Ramani P, Sukumaran G, Ramasubramanian A, Karunakaran M, Hannah R. Workplace violence among dental surgeons - A survey [Internet]. Vol. 0, Indian Journal of Dental Research. 2021. p. 0. Available from: http://dx.doi.org/10.4103/ijdr.ijdr_880_19

45. Alsawalha M, Rao CV, Al-Subaie AM, Haque SKM, Veeraraghavan VP, Surapaneni KM. Novel mathematical modelling of Saudi Arabian natural diatomite clay [Internet]. Vol. 6, Materials Research Express. 2019. p. 105531. Available from: <http://dx.doi.org/10.1088/2053-1591/ab2f9b>.

Tang X, Yu J, Li M, Zhan D, Shi C, Fang L, et al. Inhibitory effects of triterpenoid betulin on inflammatory mediators inducible nitric oxide synthase, cyclooxygenase-2, tumor necrosis factor-alpha, interleukin-6, and proliferating cell nuclear antigen in 1,2-dimethylhydrazine-induced rat colon carcinogenesis [Internet]. Vol. 16, Pharmacognosy Magazine. 2020. p. 841. Available from: http://dx.doi.org/10.4103/pm.pm_516_19

47. Aldossary SA. Ameliorative Effect of Cannabidiol against Gastric Ulcer Induced by Diclofenac in Rats [Internet]. Journal of Pharmaceutical Research International. 2021. p. 836–44. Available from: <http://dx.doi.org/10.9734/jpri/2021/v33i60b34686>

UNDER PEER REVIEW