

CHORIOCARCINOMA: A REVIEW

Abstract:

Here in his article, we will learn about choriocarcinoma, a highly malignant tumor arising from the chorionic epithelium. Among 3-5% of all patients with molar pregnancies develop choriocarcinoma. All the types of choriocarcinomas and their defining features are discussed below in a view to you to understand better the basic pathogenesis, histology, etiological factors involved. The patient may present with persistent ill-health, irregular vaginal bleeding, continued amenorrhea, and when it is metastasized, it forms lesions which present in the lung as cough, breathlessness, hemoptysis whereas in the vagina as irregular and at times as brisk hemorrhage. It can also have lesions in the cerebral region presenting as headache, convulsions, paralysis. Signs include pallor of varying degrees, and in all, the patient looks ill. Various investigations necessary to identify this disease are chest x-ray, pelvic sonography, diagnostic uterine curettage, etc. also, excisional biopsy, the ratio of HCG levels, CT scan, ultrasonography, chest X-ray can also be done. We also talked about staging in the forthcoming article for gestational trophoblastic tumors. Management of the same has also been discussed below to treat the disease better and cure many patients. It can be preventive as well as curative. Here we have talked about treatment modalities for low-risk and high-risk patients. Also, add treatment for those resistant to the drugs used for low-risk and high-risk patients. Finally, prophylactic chemotherapy and follow-ups are given.

Keywords: Choriocarcinoma, Malignant, Management, Chorionic Epithelium.

Introduction

CHORIOCARCINOMA

Due to its rarity, The very first human tumor to be monitored by a tumor marker and curable by chemotherapy, choriocarcinoma (CH), raises a diagnostic challenge, and malignancy trying to define requirements in other malignancies, such as vessel intrusion, pleomorphism, mitoses, and even metastatic, are natural features of the standard, trophoblast. It is necessary to have a clinicopathological relationship. Finding abundant pleomorphic trophoblast after a typical entire pregnancy usually always implies CH or a new pregnancy, whereas finding abundant

pleomorphic trophoblast after a complete mole (CM) often indicates mole resolution with no chorionic Villi in the sample.

It has a proclivity for vascular attack or metastases, however it is only treatable in most situations if it can be removed surgically. CH and PSTT have nothing in common and perform in different ways, yet they can sometimes merge into one another. The significant analytic challenges include: first, distinguishing CH and PSTT from plentiful trophoblast, which is commonly seen near the beginning of pregnancy; second, distinguishing CH and PSTT from constant trophoblast; third, distinguishing CH with a mainly cytotrophoblastic constituent from PSTT. Because of its scarcity and the fact that criteria used to describe malignancy in other neoplasms, such as vessel attack, cellular pleomorphism, mitoses, and even metastases, are essential features of standard trophoblast, the difference between CH, PSTT, and trophoblastic metaplasia in non-gestational carcinoma tumour marker and cured by chemotherapy, presents unique investigative problems. (1) Because choriocarcinoma is a type of cancer. To understand what gestational trophoblastic diseases are, we must first understand what they are. GTD are different set of pregnancy-related evolutions. There are two types of GTD: benign and malignant. Choriocarcinoma and hydatiform mole are the most common types, while ETT and PSTT are uncommon. (2)

TROPHOBLASTIC DISEASE AFTER A STANDARD PREGNANCY IS EITHER CHORIOCARCINOMA OR PSTT AND NOT A BENIGN OR INVASIVE MOLE

There can be benign TBD comprising of partial hydatiform moles and complete hydatiform moles or malignant having choriocarcinoma, hydatiform mole, ETT, PST

Angiogenic growth factors are abundant in choriocarcinomas. The most common clinical signs include cough, irregular vaginal bleeding, enlarged uterus, hemoptysis, headache, and vomiting. also, there is a link between intraperitoneal hemorrhage and elevated hCG levels in the blood

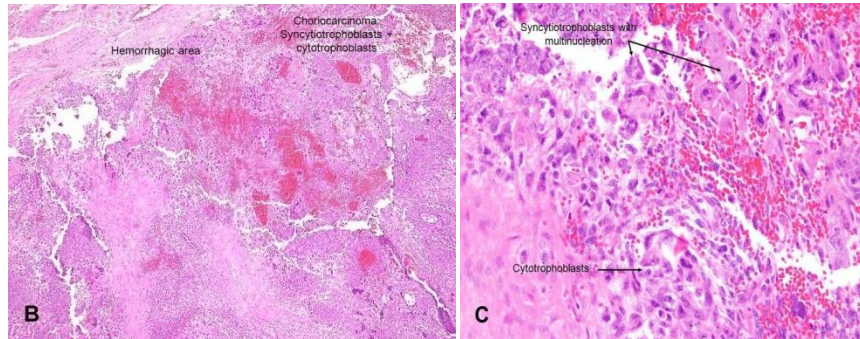
- It's uncommon
- Symptoms may be present as a result of hematogenous spread metastatic lesions
- Significant increase in hCG levels in the blood
- Gross: a hemorrhagic nodule within the testicular parenchyma; if the tumor has regressed, it may merely be a remnant scarring focus

ETIOLOGY Choriocarcinoma is a cancer that develops when an aberrant trophoblastic population undergoes hyperplasia and anaplasia. There are two types of choriocarcinoma gestational choriocarcinoma and nongestational choriocarcinoma. (3)

PATHOPHYSIOLOGY- Although the exact pathophysiology of choriocarcinoma is unknown, investigations have demonstrated that cytotrophoblast behaves like stem cells and can convert into cancerous cells. Intermediate trophoblasts and syncytiotrophoblasts develop from the neoplastic cytotrophoblast. The cell combination closely matches that of a previous blastocyst in development. In choriocarcinoma, upregulation of p53 and Transcription factors has been observed without evidence of genetic change. Hyper-methylation-induced upregulation or

downregulation has indeed been related to the genes NECC1, vascular endothelial growth factor receptors HLA-G is found in significant amounts in choriocarcinoma and is thought to alter the tumor microenvironment by inactivating the local immune system (4)

Fig 1: HISTOPATHOLOGY-



- **Choriocarcinoma (classic)**

- o Cytotrophoblasts and syncytiotrophoblasts mixed (picture B) & (image C)

Syncytiotrophoblasts develop a villous structure by wrapping or capping mononuclear cytotrophoblastic cells

- o Almost always linked to hemorrhages (search for this area)

Monophasic choriocarcinoma is a type of choriocarcinoma that has only one phase Squamous-like characteristics; very infrequent, usually in metastatic areas

- trophoblastic tumor of the placenta

Very uncommon, made up of intermediated trophoblasts

(5)

Naked eye appearance The lesion is of the nodular kind with a standard localization of the endometrium in its entirety. The nodular kind can be found deep into the myometrium, with the endometrium above it intact On uterine curettage, this frequently results in a false-negative diagnosis

Bilateral lutein cysts are found in about 30% of women with ovarian hypertrophy. An overabundance of chorionic gonadotropin causes these

Aside from the local spread, vascular degradation occurs early, allowing distant metastasis to occur quickly

CLINICAL FEATURES:-

- A) Symptoms:-: Swelling in the stomach area
- : Bleeding per vaginum
 - : Infections causing vaginal discharge, pelvic Cramps and fever
 - : Amenorrhea
 - : Hyperemesis Gravidarum
 - : Abdominal mass
 - : Features of Hypothyroidism
 - : Respiratory system

- B) Signs:-: Ill looking at patient
- : Features of Shock, Pallor
 - : Features of thyrotoxicosis, enlarged thyroid Gland
 - : Absent fetal heart sound
 - : Pelvic findings-
 - : Metastatic lesions
 - : Vesicles and bleedings seen
 - : Absent internal ballotement
 - : Palpable unilateral or bilateral enlargement of the ovary

Choriocarcinoma can metastasize to other organs, especially lungs, which can show these signs:-: Dry cough

- : Coughing blood
- : Chest pain
- : Breathing difficulties

Standardized guidelines for diagnosing postmolar GTN have been developed created on the recommendations of Braga et al

I Choriocarcinoma histology Human
chorionic gonadotropin persistence molar pregnancy even after six months

II After about 21 days, various human chorionic gonadotropin levels reached a plateau

III After 14 days, human chorionic gonadotropin levels increased by 10% or higher for at least three values

Malignant trophoblastic cancer of the choriocarcinoma is the most common GTN discovered during microscopic histological analysis, and it is most commonly caused by Term births or sudden termination Choriocarcinoma, whereas on this side, is a type of lung cancer Choriocarcinoma, on the other hand, may present with no specific symptoms or signs, making an accurate diagnosis difficult and causing a delay in detection. As a result, Gestational Trophoblastic Neoplasia should be carefully evaluated, and an HCG assessment must be undertaken by all the females during their reproductively active years, particularly those who have irregular uterine bleeding or other unexplained metastasized disease (6)

GTN risk Evaluation and Staging

Investigations: Pelvic assessment for lumps or unstandardized changes

: Test to check hCG levels

: Blood and Urine tests

: Tests to see if cancer is spreading to other body

: Imaging's as MRI, Ultrasound, or x-ray

: CXR to exclude lung diseases

: Other supportive investigation

- CBC
- Blood group and Rh typing
- PIH investigations
- TSH levels

If we discuss GTD as a whole, this is the way management would proceed

Following a molar pregnancy, the majority of neoplasia diagnoses come by continuous increase in hCG levels. While the symptoms of choriocarcinoma can be pretty variable, approximately 33% of these patients present with symptoms associated to distant tumours. However, responsible clinicians should look at malignant GTN in practically all patients with a metastatic tumour who are of reproductive age, because a modest hCG test in serum or urine could save their lives. A medical past, clinical evaluation, serum or urine hCG testing, chest X-ray, and pelvic Doppler ultrasound are all required for patients with post-molar GTN. The repetitive stimulation of the chest with CT cannot be employed for curative care of GTN patients. Ultrasonography and pelvic colour Doppler imaging are imaging procedures that can be used not only for general diagnosis but also in cases of prolonged GTN or molar pregnancy. Both the pulsatility index and the capacity of the uterus may provide self-governing medical prognostic data that can reveal methotrexate resistance mechanisms in malignancies.

MRI of the abdomen, brain, and pelvis, and also chest CT, are frequently employed in patients with drugs that are resistant or with recurrent disease. Furthermore, precise tumor localization may help determine whether therapeutic excision is an option. However, using the FDG-PET imaging to locate relapsed or residual disease would be beneficial. MRI and CT scans may be used to assess the levels of human chorionic gonadotropin in cerebrospinal fluid to detect occult illnesses in the CNS (7).

STAGING-

The following choriocarcinoma staging system was devised by the WHO and the international federation of Gynecology and Obstetrics:

- Stage I: Disease limited to the uterus
- Stage II: Disease that extends beyond the uterus but is limited to genital structures
- Stage III: Disease that extends to the lungs
- Stage IV: Cancer has spread to other metastatic locations

Criteria--

Modified WHO Prognostic Scoring System as Adapted by FIGO

Scores	0	1	2	4
Age	<40	≥40	—	—

Antecedent pregnancy	mole	abortion	Term	–
Interval months from index pregnancy	<4	4–6	7–12	>12
Pretreatment serum hCG (iu/l)	<103	103–104	104–105	>105
Largest tumor size (including the uterus)	<3	3–4 cm	≥5 cm	–
Site of metastases	lung	spleen, kidney	gastrointestinal	liver, brain
Number of metastases	–	1–4	5–8	>8
Previously chemotherapy failed	–	–	single drug	≥2 drugs

GTN FIGO staging

Stage Description

I GTDs are limited to the corpus of the uterus only

II GTDs can spread to the adnexa or vaginal region, but they are still restricted to the genital tissues

III GTDs that form in the lungs may affect the vaginal tract

IV The rest of the metastatic locations(8)

(6)Treatment-

Standard treatment options

Based on the kind and stage of the disease, conventional treatment options for GTD comprise chemotherapy, D&C, removal of the uterus or with a combo of both. In general, Dilation and curettage is used to save fertility and rule out molar pregnancy from the picture; although, to assure that the problem does not recur, rigorous post-treatment monitoring is required. When fertility retention is not a concern, and there are no distant metastases, hysterectomy is a more typical therapy for more severe and especially notable cancers. Chemotherapy, whether as a solo or combined treatment, is successful for some types of GTD; however, it is not practical for a variety of diseases.

Low-risk GTN

Low and high-risk GTN illness can be classified based on the severity of the condition. In recent years, the treatment for low-risk GTN has remained relatively unchanged. Dactinomycin and amethopterin are the most often used treatments for this group of illnesses. With or without the release of leucovorin, amethopterin is safe and has fewer negative things. When the human chorionic gonadotropin serum hormone has been standardized the amethopterin therapy would be carried out within consolidated treatment systems that might be effectively abided without causing spot baldness (9).

Other, less possible side effects include epithelial membrane irritation, and alterations in renal and liver function. Another unusual side effect is myelosuppression, which is the inhibition of marrow. Dactinomycin is best administered as a daily intravenous infusion with a dosage of 0.5 mg. Dactinomycin has a more significant short-term hazard than amethopterin. However, dactinomycin's most prevalent side effects are myelosuppression and stomach ulcers.

However, myelosuppression, nausea, hair loss, and severe mucositis are some of the more typical side effects of dactinomycin. Dactinomycin, unlike amethopterin, do not have any possible long-term side effects (10).

Low-risk persistent GTN

A rise in serum hormone of HCG in far more than three successive values is the most sensitive sign of vulnerability to amethopterin in malignancy. The level of human chorionic HCG hormone where the prolonged condition develops, on the other hand, may aid in the choosing of rescuing treatment. Patients received treatment that contained amethopterin, etopophos, and dactinomycin if dactinomycin treatments fail or if they advanced amethopterin resistance with an hCG hormone level and done 100 IU/l. While individuals who are resistant to amethopterin may be managed regardless of level of resistance in some cases, this is not always the case. While patients who are immune to amethopterin may be handled deprived of regard for their hCG levels by merging chemotherapy with etopophos, amethopterin, and dactinomycin, in some situations, patients who are resilient with amethopterin may be handled without regard for their hCG levels by merging chemotherapy with etopophos and amethopterin, and dactinomycin (11).

Despite the reality that these treatment plans may certify a faster treatment, a huge number of patients will be exposed to more harmful medications, increasing the chance of cancer recurrence. In this case, the human chorionic gonadotropin threshold values for dactinomycin therapy in amethopterin-resistant patients can be augmented from 100 to 300 IU/l. Pulsed

dactinomycin, on the other extreme, could be utilized as a last-resort treatment for GTN patients who haven't progressed to amethopterin. Combined chemotherapy, on the other hand, has the potential to heal almost all patients at a faster rate (12)

High-risk GTN

Table 1: Treatment schedule		
Week one		Week two
Day one	Day two	Day one
I: Dactinomycin 0.5 mg iv bolus injection II: Etopophos 100 mg/m ² intravenous during the half hour III: Amethopterin 300 mg/m ² intravenous during 12 h	I: Dactinomycin 0.5 mg intravenous bolus injection II: Etopophos 100 mg/m ² intravenous during the half hour III: Oral leucovorin 15 mg for 12 hours over two days and 24 hours after amethopterin start	I: Leurocristine 1.4 mg per m ² iv bolus injection II: cytophosphane 600 mg per m ² iv during half hour

The probability of healing with this kind of regimen, as per reports, is around 90%. Etopophos, amethopterin, and dactinomycin have been used in the therapy, which was combined with vincristine. Cytophosphane is much more dangerous, causing reversible hair loss, bone marrow reduction, and severe mucous membrane infection in the short term. Nerve damage disease was caused by their pristine. Moreover, the use of etopophos medicines opens up the risk of a small second tumor.

A fully functional chemotherapeutic agent. Medicines like amethopterin, etopophos, and dactinomycin can be used to provide the best possible treatment for patients with more significant GTN risks, which would have been effective in around 70% of cases. On the other side, each particular regimen is helpful with treatment of both high and low-risk GTN disorders appointment as majors (13).

Management of Resistant GTN Patients

Among the most severe problems in GTN patients who are resistive to therapy is their ability to be cured even after routine care has failed. This objective could be achieved by removing resistant disease with a mix of chemotherapy and surgery. The surgical procedure of hysterectomy is advised as a first approach when the remaining sickness site can indeed be detected using functional and anatomical imaging techniques

With the therapeutic adjuvant therapy of 2 types of etopophos, this regimen is by far the most suited, with the best recovery rate in comparison Paclitaxel, alone and in combination with cisplatin, may, on either hand, be beneficial in resistant GTN patients Moreover; although its effectiveness, the delivery of higher doses of chemotherapy to periphery blood stem cells in people has not been well investigated On the other side, there are two reported cases of individuals who experienced assisted remission after receiving higher dosages of remedies:

A:) a treatment combining etopophos tonophosphan, melphalan

B:) a mixture ofparaplatin, etopophos, and ifosfamide therapy (14)

Prophylactic chemotherapy

One element of GTD treatment which is still up for debate is either to start preventive chemotherapy in a subgroup of women who have hydatidiform mole are at high risk of tenacity but instead of tracking their HCG thresholds until they meet the criteria for declaring no evidence of disease or persistent GTD rather than tracking their hCG levels until they fulfill the requirement for announcing no evidence of disease or persistent GTD The goal is to use a more moderate chemotherapy treatment to prevent the need for further rigorous treatment in a lesser group of women, improving the chance of complete remission In several non-randomized studies, the risk of recurrent/persistent sickness was significantly reduced (15)

Prophylaxis chemotherapy was administered to 59% (19%) of the patients, while the remaining 216 people served as controls. In the 59 people who received preventative chemotherapy, no one had chronic GTD, while persistent GTD developed in 59 percent of the comparison group

Only three randomized trials were found in a recent Cochrane review, including the actinomycin mentioned above study The combined results of 7 studies showed a lower risk of GTD, but the 2 out of 3 studies were deemed low-quality by the Cochrane authors (16)

Second dilatation and curettage

2nd uterine extraction appears to limit the symptoms linked to chronic illness and lessen the requirement for chemotherapy for certain institutions with considerable experience with GTD 48 Sixty females who were diagnoses with prior GTNreceived a 2nd uterine curettage as part of the GOG 242 study, and 24 (40 percent) of them obtained complete remission without the need for chemotherapy There were no patients were cured who had hCG level larger over 100,000 mIU/mL or a FIGO/WHO score greater than 4 . (17-19).

Selective uterine surgery

Chemoresistant illness patients are frequently recommended to have a hysterectomy. However, many of these women prefer to maintain their fertility. Women with PSTT who received fertility-saving treatment are highlighted in a research review. Six of the 11 women who underwent a laparotomy with uterine retention were successful. At the same time, the other five required a complete hysterectomy. As a result, at the same time, this therapy may be effective in approximately half of the cases, close monitoring of excision margin and disease progression is required. However, hCG monitoring is useless in the case of PSTT, and human placental DNA is a better predictor of disease incidence (17).

Follow-up GTN Patients after Treatment

If the hCG levels were not identified after three weekly spliced analyses and chemotherapy, numerical hCG levels in the plasma must be obtained for one year at monthly intervals for GTN patients in stages I and III, and for two years at periodic intervals for GTN patients in stage IV, exactly even before pregnancy period begins. The systematic risk for GTN patients is generally between 4 and 10% within the first year after taking the appropriate therapy. Actual medical assessments must be performed every three months when the hCG level is measured. Furthermore, radiographic imaging techniques should only be used in particular circumstances (18).

Fertility control should be carried out primarily throughout treatment and for 1 or 2 years following completion of chemotherapy, mainly by the use combined with oral contraceptive pills. In cases where the amount of hCG is not measurable, the use of an intrauterine contraceptive device may have negative consequences. In advanced gestations beyond ten weeks, however, because of the likelihood of future GTD occurrences within the prospective subsequent pregnancy, a pelvic ultrasonography scan is recommended for fulfilling the development of normal fetal development. Furthermore, six weeks following the procedure, an inspection of the HCG hormone level must be performed. Furthermore, six weeks afterward the completion of all subsequent gestations, and also HCG hormone levels should be checked. Certain related studies were reviewed(20-24).

After the abortion or post-term disease should then be seen when a patient has a past of molar pregnancy or gestational trophic neoplasia, has fibroids bleeding, or displays evidence of metastatic sickness after a miscarriage or pregnancy. As per prior research, utilizing pharmaceutical mixtures containing etopophos has been associated with an elevated risk of hepatocellular carcinoma, including breast cancer, melanoma, CRC, blood and bone marrow cancer.

Conclusion:

The prognoses for GTN malignancies after therapeutic therapy are critical, and the majority of existing information in the area has been gained during the last half-century, primarily by seeing the natural and organic history of GTN malignancies. Patients with low and high-risk GTN illnesses have survival rates of more than 95 percent and 80 percent, respectively. One of the

most significant future difficulties in this area is the capacity to optimize treatment regimens for drug-resistant individuals. The advancement of anti-angiogenesis therapy, as well as molecular targeted cancer medications, could improve the therapeutic outlook for these patients

References:

1. F.J. Paradinas, The differential diagnosis of choriocarcinoma and placental site tumour, *Current Diagnostic Pathology*, Volume 5, Issue 2, 1998, Pages 93-101, ISSN 0968-6053, [https://doi.org/10.1016/S0968-6053\(98\)80013-6](https://doi.org/10.1016/S0968-6053(98)80013-6). (<https://www.sciencedirect.com/science/article/pii/S0968605398800136>)
2. Hemberger M, Udayashankar R, Tesar P, et al. : ELF5-enforced transcriptional networks define an epigenetically regulated trophoblast stem cell compartment in the human placenta. *Hum Mol Genet.* 2010;19(12):2456–67. 10.1093/hmg/ddq128
3. Pijnenborg R, Robertson WB, Brosens I, et al. : Review article: trophoblast invasion and the establishment of haemochorial placentation in man and laboratory animals. *Placenta.* 1981;2(1):71–91. 10.1016/S0143-4004(81)80042-2
4. Early development of the human placenta. In: Benirschke K, Kaufmann P. *Pathology of the human placenta* New York: Springer-Verlag, 1990;13–21. 10.1007/978-1-4757-4193-3_2
5. Gude NM, Roberts CT, Kalionis B, et al. : Growth and function of the normal human placenta. *Thromb Res.* 2004;114(5–6):397–407. 10.1016/j.thromres.2004.06.038
6. Pijnenborg R, Vercruysse L, Hanssens M: The uterine spiral arteries in human pregnancy: facts and controversies. *Placenta.* 2006;27(9–10):939–58. 10.1016/j.placenta.2005.12.006
7. Moser G, Huppertz B: Implantation and extravillous trophoblast invasion: From rare archival specimens to modern biobanking. *Placenta.* 2017;56:19–26. 10.1016/j.placenta.2017.02.007
8. Eysbouts YK, Ottevanger PB, Massuger LFAG, et al. : Can the FIGO 2000 scoring system for gestational trophoblastic neoplasia be simplified? A new retrospective analysis from a nationwide dataset. *Ann Oncol.* 2017;28(8):1856–61. 10.1093/annonc/mdx211
9. Bruce S, Sorosky J: *Gestational Trophoblastic Disease*. Stat Pearls Publishing. 2017.
10. Shih IM: Gestational trophoblastic neoplasia--pathogenesis and potential therapeutic targets. *Lancet Oncol.* 2007;8(7):642–50. 10.1016/S1470-2045(07)70204-8
11. Vree M, van Trommel N, Kenter G, et al. : The influence of lung metastases on the clinical course of gestational trophoblastic neoplasia: a historical cohort study. *BJOG.* 2016;123(11):1839–45. 10.1111/1471-0528.13622.
12. Vargas R, Barroilhet LM, Esselen K, et al. : Subsequent pregnancy outcomes after complete and partial molar pregnancy, recurrent molar pregnancy, and gestational trophoblastic neoplasia: an update from the New England Trophoblastic Disease Center. *J Reprod Med.* 2014;59(5–6):188–94.
13. Garrett LA, Garner EI, Feltmate CM, et al. : Subsequent pregnancy outcomes in patients with molar pregnancy and persistent gestational trophoblastic neoplasia. *Obstet Gynecol Surv.* 2008;63(11):704–5. 10.1097/01.ogx.0000335639.50781.79

14. Nadhan R, Vaman JV, C N, et al. : Insights into dovetailing GTD and Cancers. *Crit Rev Oncol Hematol*. 2017;114:77–90. 10.1016/j.critrevonc.2017.04.001.
15. Altieri A, Franceschi S, Ferlay J, et al. : Epidemiology and aetiology of gestational trophoblastic diseases. *Lancet Oncol*. 2003;4(11):670–8. 10.1016/S1470-2045(03)01245-2.
16. Seckl MJ, Sebire NJ, Berkowitz RS: Gestational trophoblastic disease. *Lancet*. 2010;376(9742):717–29. 10.1016/S0140-6736(10)60280-2.
17. Trophoblastic disease: Scoring, standardization, and salvage. *Gynecol Oncol*. 2017;144(1):200–7. 10.1016/j.ygyno.2016.08.330.
18. Mello JB, Ramos Cirilo PD, Michelin OC, et al. : Genomic profile in gestational and non-gestationalchoriocarcinomas. *Placenta*. 2017;50:8–15. 10.1016/j.placenta.2016.12.009
19. Rodabaugh KJ, Bernstein MR, Goldstein DP, et al. : Natural history of post term choriocarcinoma. *J Reprod Med*. 1998;43(1):75–80.
20. Reitsma MB, Reitsma MB, Kendrick PJ, Ababneh E, Abbafati C, Abbasi-Kangevari M, et al. Spatial, temporal, and demographic patterns in prevalence of smoking tobacco use and attributable disease burden in 204 countries and territories, 1990-2019: a systematic analysis from the Global Burden of Disease Study 2019. *LANCET*. 2021 Jun 19;397(10292):2337–60.
21. Jessani S, Saleem S, Hoffman MK, Goudar SS, Derman RJ, Moore JL, et al. Association of haemoglobin levels in the first trimester and at 26-30 weeks with fetal and neonatal outcomes: a secondary analysis of the Global Network for Women’s and Children’s Health’s ASPIRIN Trial. *BJOG-AN INTERNATIONAL JOURNAL OF OBSTETRICS AND GYNAECOLOGY*.
22. Abbafati, Cristiana, Kaja M. Abbas, Mohammad Abbasi, Mitra Abbasifard, Mohsen Abbasi-Kangevari, Hedayat Abbastabar, Foad Abd-Allah, et al. “Global Burden of 369 Diseases and Injuries in 204 Countries and Territories, 1990-2019: A Systematic Analysis for the Global Burden of Disease Study 2019.” *LANCET* 396, no. 10258 (October 17, 2020): 1204–22.
23. Sahu, Preeti Rajendra, Kishor Madhukar Hiwale, and Sunita Jayant Vagha. “Transitional-Cell Carcinoma of the Endometrium: A Rare Case Report.” *JOURNAL OF EVOLUTION OF MEDICAL AND DENTAL SCIENCES-JEMDS* 9, no. 36 (September 7, 2020): 2666–68. <https://doi.org/10.14260/jemds/2020/579>.
24. Toshniwal, Shikha M., Saunitra A. Inamdar, Himanshi D. Agarwal, and Sakshi R. Sharma. “Malignant Brenner Tumor- A Rare Case of Ovarian Carcinoma.” *MEDICAL SCIENCE* 24, no. 105 (October 2020): 3550–54.