

ANTHROPOMETRIC EVALUATION OF VOLUME OF MAXILLARY SINUS AND NASAL SEPTUM PATTERNS AS AN AID IN PERSONAL IDENTIFICATION USING CBCT-A RETROSPECTIVE STUDY

ABSTRACT

Aims: To determine the reliability and accuracy of maxillary sinus volume and nasal septum patterns in personal identification in forensics using CBCT (cone beam computed tomography).

Study design: Retrospective Study

Place and Duration of Study: Department of Oral Medicine and Radiology, Swargiya Dadasaheb Kalmegh Smruti Dental college and Hospital Nagpur, from September 2019-December 2019.

Methodology: 110 CBCT scans of bilateral maxillary sinuses and nasal septum images were retrospectively obtained from the Oral Medicine and Radiology database (68 men and 42 females). The study was divided into two groups based on age. Group -I consists of 58 CBCT scans taken between the ages of 20 and 40, while Group -II consists of 52 CBCT scans taken between the ages of 41 and 80. The height, breadth, and depth of the maxillary sinus were measured linearly. The nasal septum was classed as simple deviation to the right or left, sigmoid type, reverse sigmoid type, and straight based on the septa's deviations. Each person's combined maxillary sinus and nasal septum pattern was documented.

Results: The difference in maxillary sinus volume between two age groups was significant ($P < 0.5$). In age group I, there was a substantial change in the left deviation pattern, and there was a significant change in the reverse sigmoid pattern in males and the straight nasal septum pattern in females. With whatever nasal septum configuration, there were no volumetric alterations ($P > 0.5$).

Conclusion: In future, further research will be needed with a larger number of images to compare in order to arrive at a definitive identification.

Keywords: CBCT (Cone beam computed tomography), Maxillary Sinus, Nasal septum patterns, Forensic medicine.

INTRODUCTION

CBCT (Cone-beam computed tomography) is a new, sophisticated imaging technique in dentistry. CT (Computerized Tomography) employs a fan-shaped X-ray beam, whereas cone beam computed tomography uses a cone-shaped X-ray beam and costs less than CT. A single flat-panel detector or image intensifier radiation detector is used in CBCT, and the method comprises a rotating platform with a fixed X-ray source and detector.[1] CBCT has numerous benefits for post-mortem forensic imaging and might be highly useful in forensic situations.

The study of anthropometry plays a critical part in the medicolegal examination of death and is essential for personal identification. In forensics, the unique characteristics of each human being are universally accepted. It also aids in the identification of individuals.[2] During the process of identifying an individual, fingerprint analysis, DNA matching, and anthropological research can help speed up the process, however finger print analysis and DNA identification are useless in situations where the remains have been burned or decomposed, or when the DNA has been substantially damaged. As a result, anthropological approaches using comparative radiography have shown to be a valuable tool in these instances.[3] The nasal septum separates the nasal cavity and provides support to the external nose. It is located in the centre of the nasal cavity. By puberty, it has grown to adult size and structure.[4] The nasal septum can be categorised as straight, with a simple deviation to the right or left, sigmoid type, or reverse sigmoid type. The pattern of the nasal septum, like that of the frontal sinus, is useful in forensics. As a result, preserving antemortem accounts and comparing them to post-mortem accounts will be a crucial tool in identifying an individual.[5]

Maxillary sinuses are air spaces in the maxillary bone that come in a variety of sizes and forms. The maxillary sinuses emerge towards the end of the second embryonic month and mature at around the age of 20 years, when the permanent teeth have fully developed. After the second decade of life, they tend to stabilize, and radiographic images offer appropriate measures of maxillary sinuses for morphometric forensic investigation.[6] Previous research has used the frontal sinus and nasal septum pattern to identify people and the maxillary sinus to determine gender.[2] The present study was designed to determine the reliability and accuracy of maxillary sinus volume and nasal septum patterns in personal identification in forensics using cbct.

MATERIAL AND METHODS

Sample size formula for difference between two proportion

n=55 patients needed in each group

Study reference: David and saxena et al

Power of total:80%

Level of significance:5%

CBCT images will be selected by purpose sampling method

Statistical analysis will be done by using descriptive and inferential statistics using Chi square test, Student's t test, and software used in the analysis were SPSS 24.0 version GraphPad Prism 7.0 version and $p < 0.05$ is considered as level of significance.

This is **retrospective study**, the database of Oral Medicine and Radiology was used to retrieve 110 CBCT scans of bilateral maxillary sinuses and nasal septum images (68 males and 42 females). CBCT images were acquired with Sirona Orthophos SL, Germany CBCT Unit, with Xelis software, in the Department of Oral Medicine and Radiology. Approval from the Institutional Ethics Committee were taken. Ethical committee number-SDKS/PG/STRG/ODMR/1-2-2019.

The study comprised retrospective CBCT scans without imaging errors or distortions that showed a disease free maxillary sinus and nasal septum pattern with all maxillary permanent teeth. The study was divided into two groups based on age. Group -I consists of 58 CBCT images taken between the ages of 20 and 40, while Group -II consists of 52 CBCT images taken between the ages of 41 and 80. The height, breadth, and depth of the maxillary sinus were measured linearly. In an axial section, the breadth and depth of the maxillary sinus were measured, while the height was determined in a coronal section. The longest distance perpendicular from the medial wall of the sinus to the most lateral wall of the maxillary sinus in the axial view was used to determine the width. In an axial view, the depth was determined as the largest distance between the most anterior and most posterior points of the medial wall. The longest distance from the lowest point of the sinus floor to the highest point of the sinus roof in the coronal view was used to determine the height of the maxillary sinus, which was measured away from the inner surface of the anterior border of the sinus. **Figure 1. (A B C)**

Fig. 1A Height in coronal view

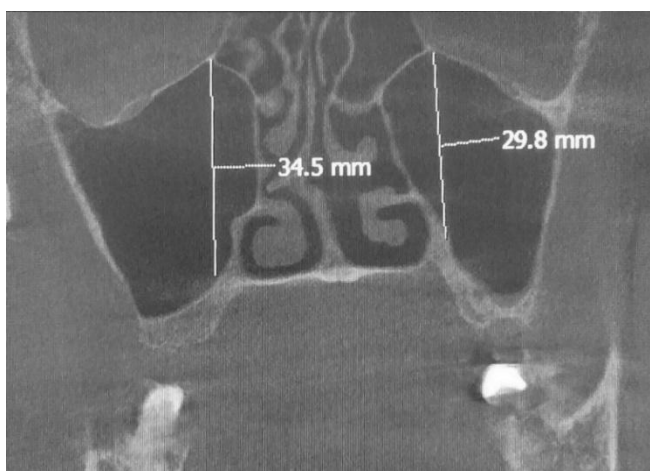


Fig. 1B Length in axial view

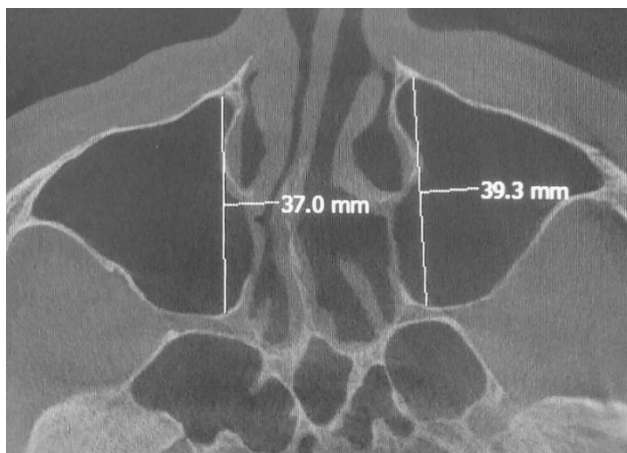
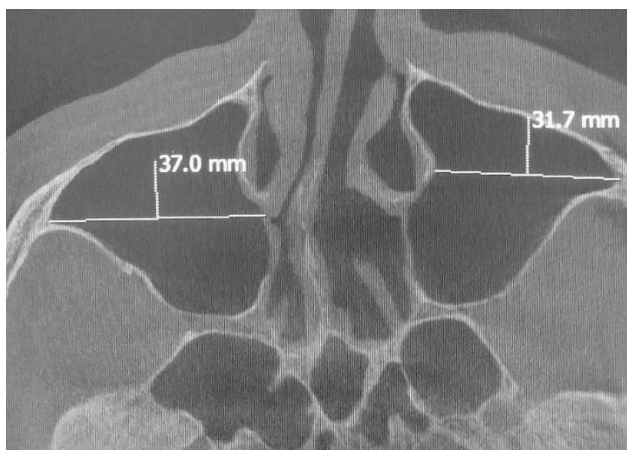


Fig. 1C width in axial view



Volume of maxillary sinus was determined by using geometric calculation method according to geometrical equation: Volume of Pyramid = Base surface area x 1/3 Height.

The nasal septum was classed as simple deviation to the right or left, sigmoid type, reverse sigmoid type, and straight based on the septa's deviations. Each person's combined maxillary sinus and nasal septum pattern was documented. **Figure 2(A, B, C, D, E)**

Fig.2A-Right deviation

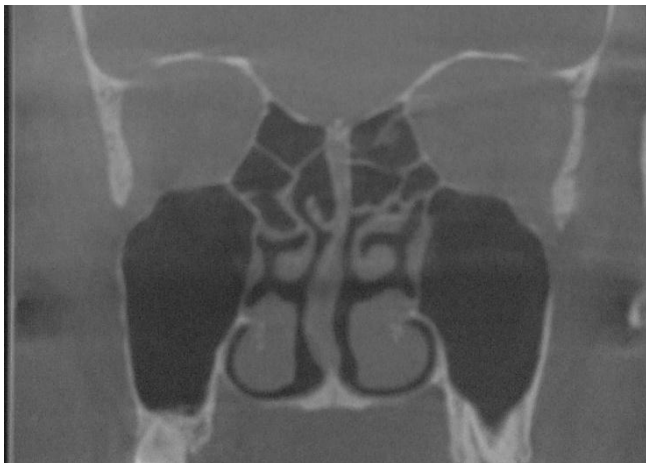

Fig.2B- Straight

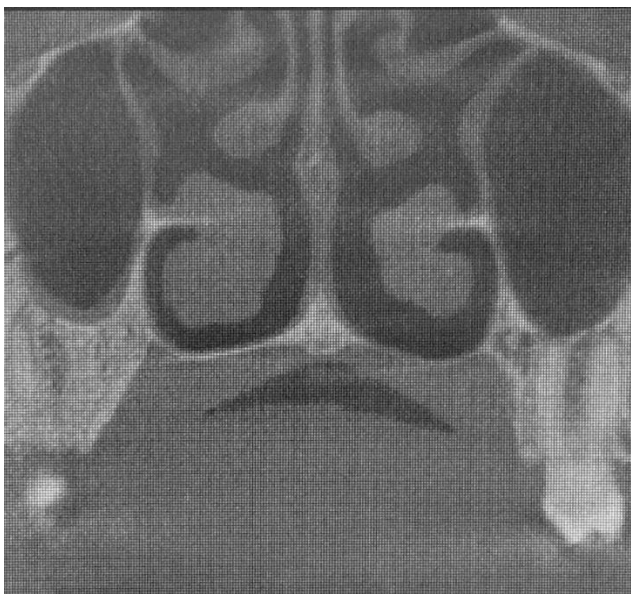


Fig.2C- Left deviation

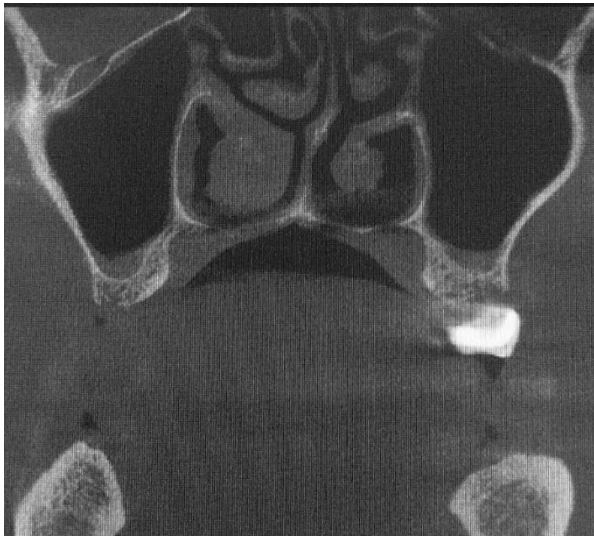

Fig.2D- Reverse Sigmoid

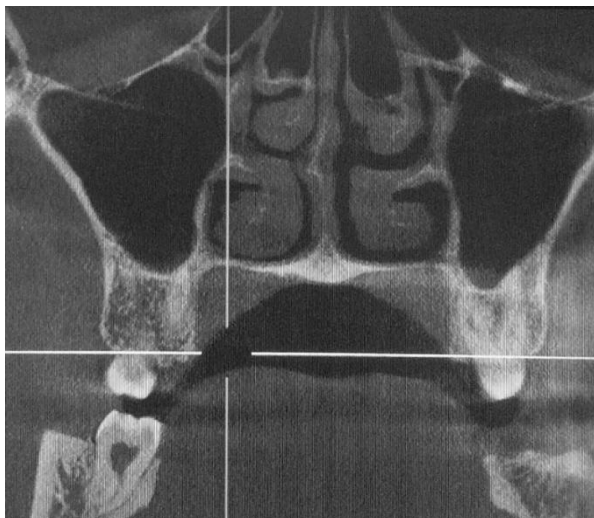
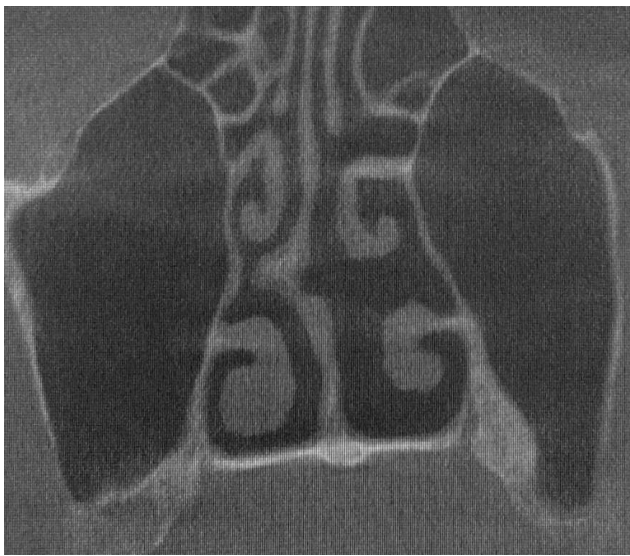


Fig.2E- Sigmoid



Results

Based on the age, 110 CBCT scans divided into Group -I consist of 58 images (30-male,28-female) obtained from age ranges from 20 to 40 years and Group -II consisted of 52 images (38-male,14-female) obtained from age ranges 41-80 years and the mean **age of participants is 40 years**. (Table-1and Graph-1), (Table-2 and Graph-2)

Table 1: Distribution of patients according to age group(yrs)

Age Group	No of images of patient	Percentage	Mean \pm SD
Group I (20-40 yrs)	58	52.7	28.12 \pm 5.89
Group II (41-80 yrs)	52	47.3	56.36 \pm 9.74

<i>Total</i>	<i>110</i>	<i>100</i>	<i>40.05±14.93</i>
--------------	------------	------------	--------------------

Graph 1: Distribution of patients according to age group(yrs)

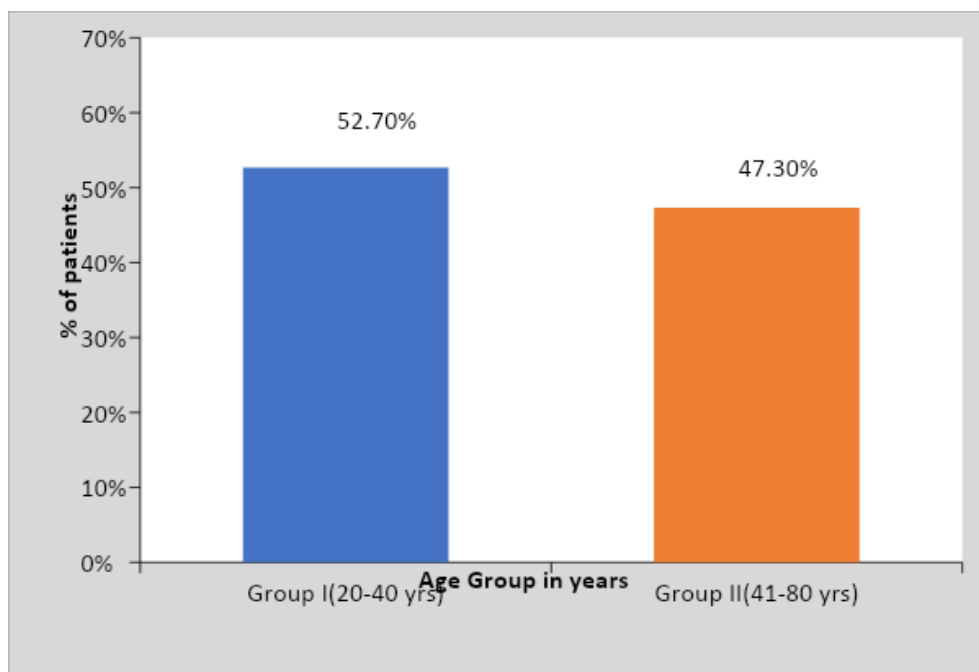
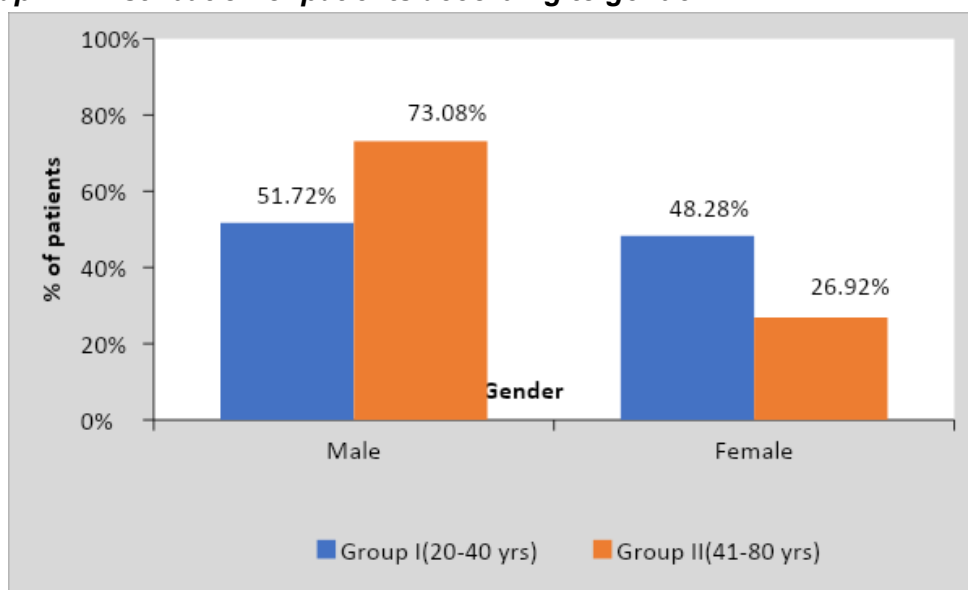


Table 2: Distribution of patients according to gender

<i>Age Group</i>	<i>Male</i>	<i>Female</i>	<i>Total</i>
<i>Group I (20-40 yrs)</i>	<i>30(51.72%)</i>	<i>28(48.28%)</i>	<i>58(100%)</i>
<i>Group II (41-80 yrs)</i>	<i>38(73.08%)</i>	<i>14(26.92%)</i>	<i>52(100%)</i>
<i>Total</i>	<i>68(61.82%)</i>	<i>42(38.18%)</i>	<i>110(100%)</i>

Graph 2: Distribution of patients according to gender



MAXILLARY SINUS

The volume of maxillary sinus is calculated by geometric calculation method according to the

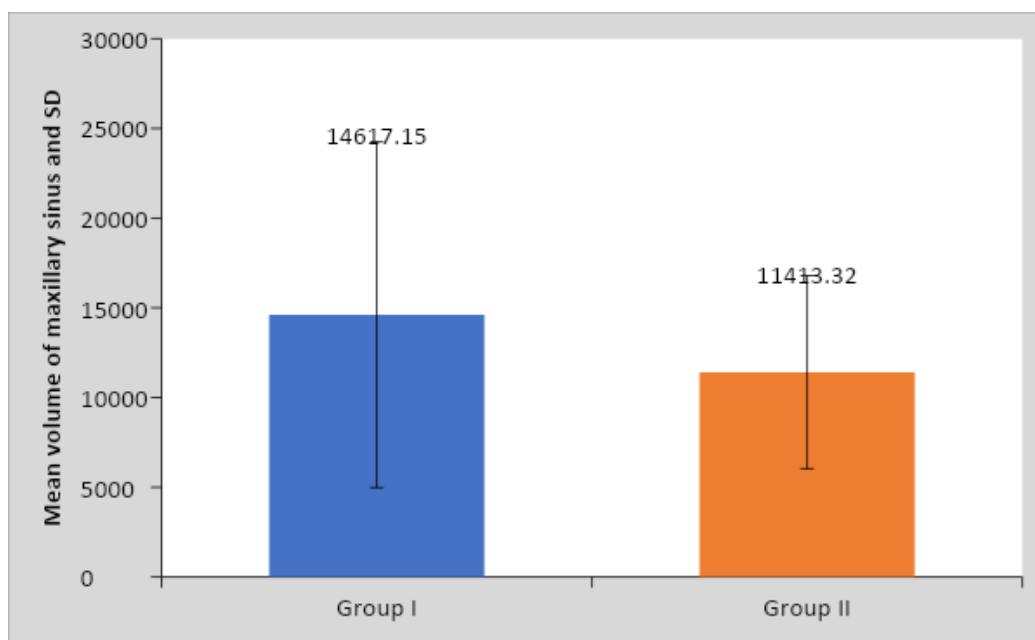
geometrical equation: Volume of Pyramid = Base Surface Area X 1/3 Height. The volume of maxillary sinus decreases with increase in the age. The volume of maxillary sinus between the Groups i.e Group I (20-40yrs) and Group II (41-80 yrs) according to age was significant $P < 0.5$ (Table-3 and Graph-3).

Table 3: Comparison of Volume of Maxillary Sinus in two groups according to age group z-test for difference between two means

Group	N	Mean	Std. Deviation	Std. Error Mean	z-value
Group I (20-40 yrs)	5	14617.15	9636.23	1265.29	2.11
Group II (41-80 yrs)	8	14617.15	9636.23	1265.29	$p=0.036^*$, S

Group II(41-8 0 yrs)	5 2	11413.32	5380.78	746.18	
----------------------------	--------	----------	---------	--------	--

Graph 3: Comparison of Volume of Maxillary Sinus in two groups according to age group



On comparing volume of maxillary sinus in between two Groups i.e Group I and Group II according to gender, there was no volumetric changes seen was hence the data was not significant. ($P>0.5$). (Table-4 and Graph-4)

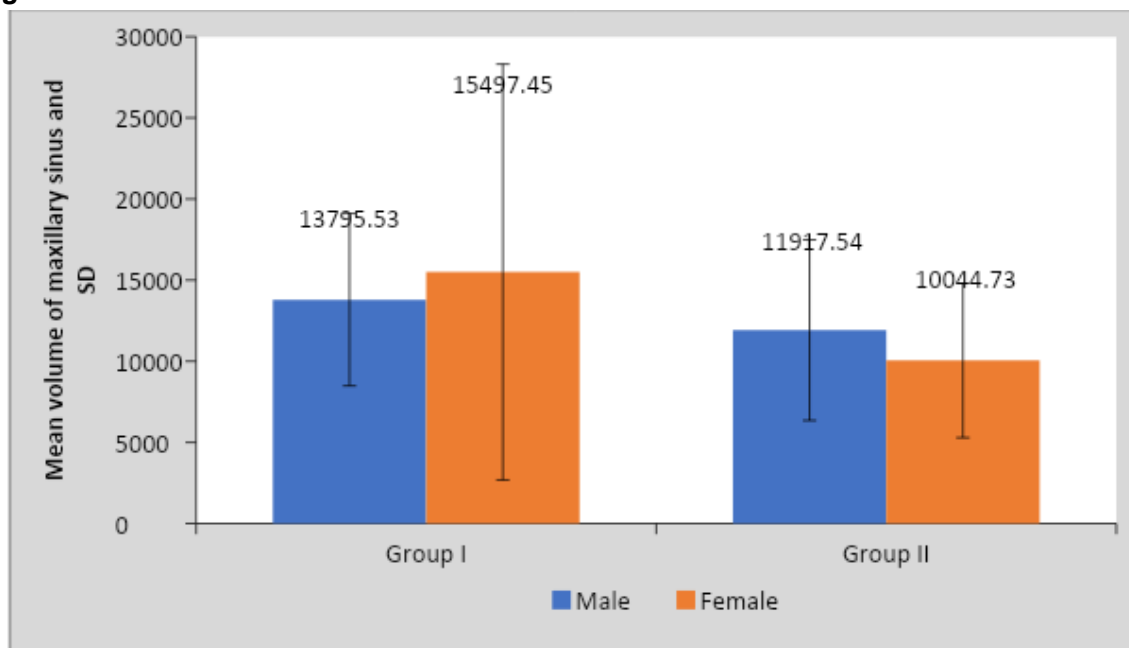
Table 4: Comparison of Volume of Maxillary Sinus in two groups according to gender

z-test for difference between two means

Group	Male		Female		z-value
	Mean	SD	Mean	SD	
Group I	13795.5 3	5309.46	15497.4 5	12814.0 2	0.66, $p=0.50$, N S

Group II	11917.54	5567.17	10044.73	4755.21	1.11, p=0.27 NS
----------	----------	---------	----------	---------	-----------------

Graph 4: Comparison of Volume of Maxillary Sinus in two groups according to gender



NASAL SEPTUM

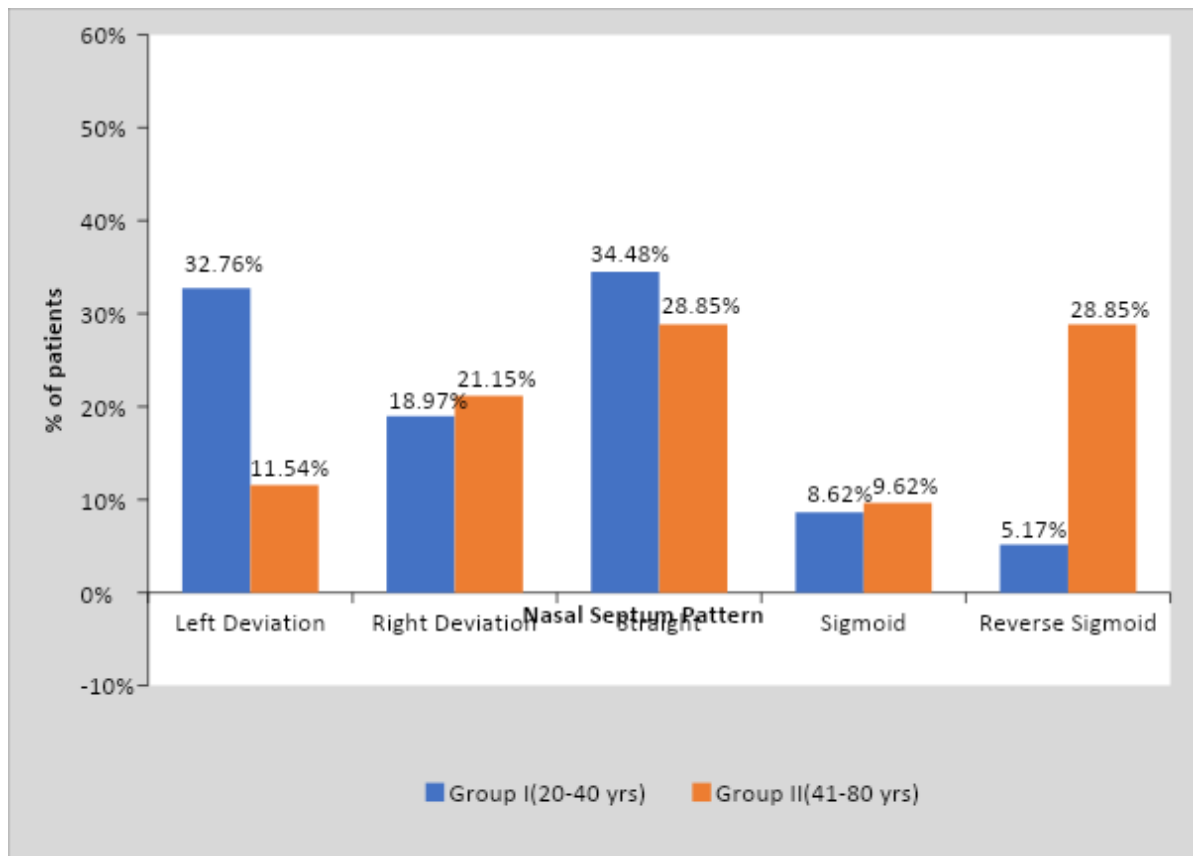
On comparing Nasal Septum Pattern according to age in two groups the maximum number of images obtained was having a straight nasal septum in Group I with age ranges from (20 to 40) years which was statistically significant $P < 0.01$. In group I (20-40 years) the maximum number of images obtained was having a straight pattern which was statistically significant $P < 0.01$

Equal number of Right deviation pattern was observed in both the groups. In group II the maximum number of images obtained was having a reverse sigmoid pattern which was statistically significant $P < 0.01$ (Table-5 and Graph-5)

Table 5: Comparison of Nasal Septum Pattern in two groups according to age group

Age Group	Left Deviation	Right Deviation	Straight	Sigmoid	Reverse Sigmoid
Group I (20-40 yrs)	19(32.76%)	11(18.97%)	20(34.48%)	5(8.62%)	3(5.17%)
Group II (41-80 yrs)	6(11.54%)	11(21.15%)	15(28.85%)	5(9.62%)	15(28.85%)
χ^2 -value	15.19, p-value=0.004*, Significant				

Graph 5: Comparison of Nasal Septum Pattern in two groups according to age group



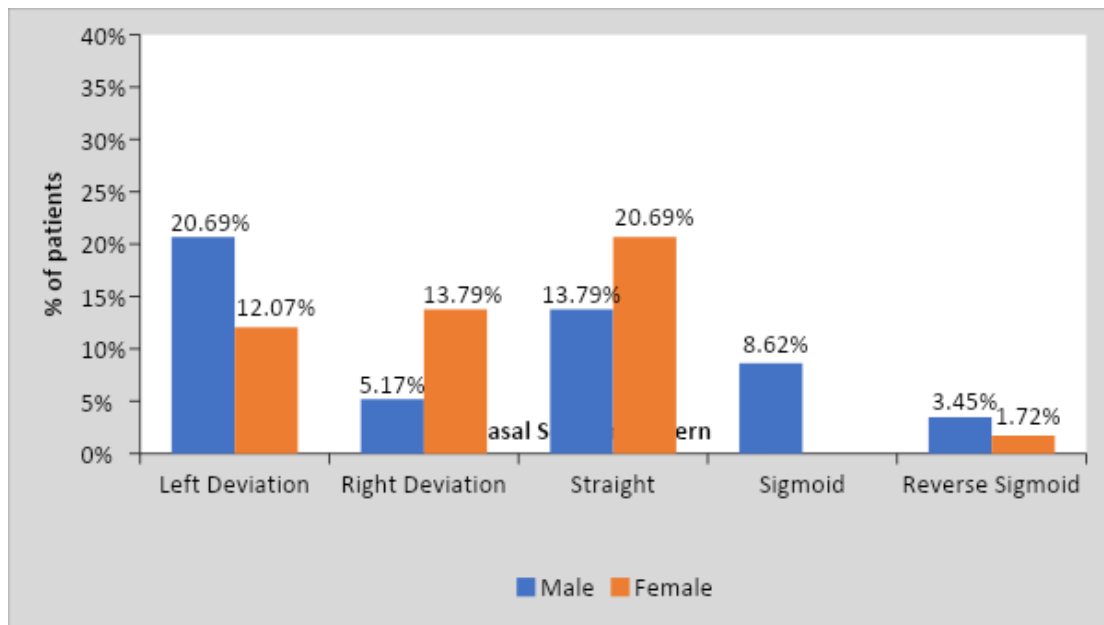
On comparing Nasal Septum Pattern in two groups according to gender there was a significant change in reverse sigmoid in male in Group II (41-80 yrs) and straight nasal septum pattern in female in group 1 (20-40 years) hence the data was found to be significant. In group I maximum number of images of left deviation was observed in males and straight nasal septum pattern in female which was statistically significant and in group II maximum number of images of reverse sigmoid was observed in males and straight nasal septum pattern in female which was statistically significant. (Table-6 and Graph-6.1/ 6.2)

Table 6: Comparison of Nasal Septum Pattern in two groups according to gender

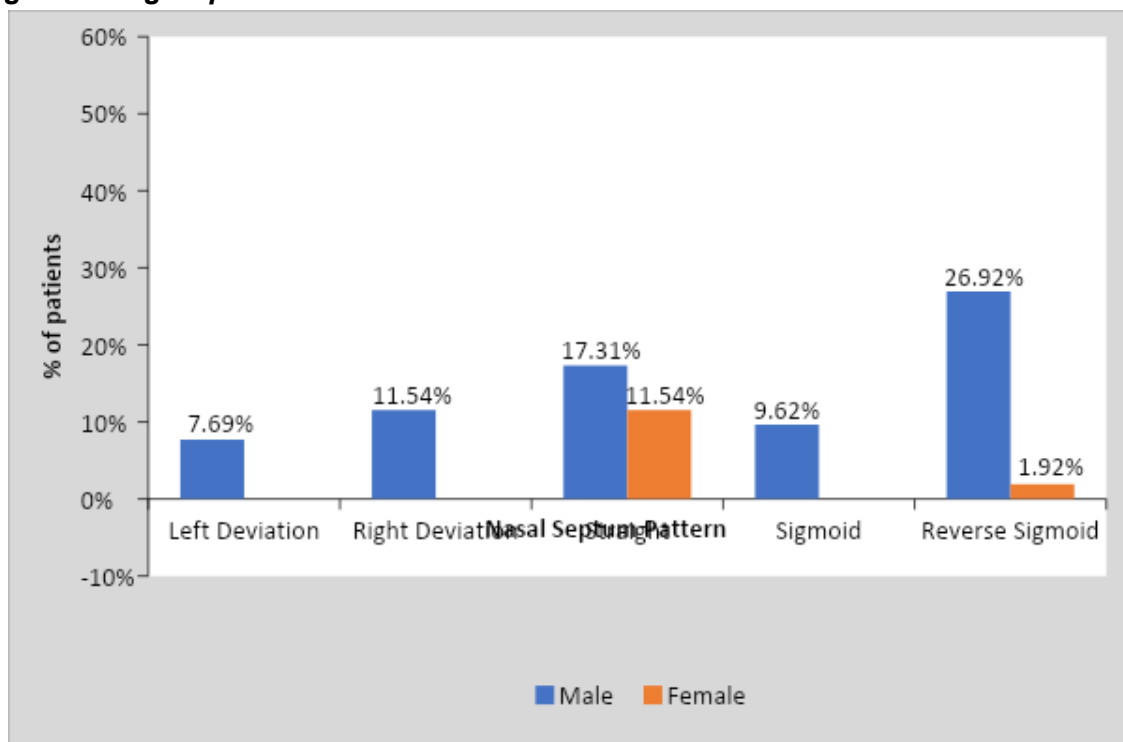
Age Group	Left Deviation	Right Deviation	Straight	Sigmoid	Reverse Sigmoid	χ^2 -value

Group I (20-40 yrs)						9.66
Male	12(20.69%)	3(5.17%)	8(13.79%)	5(8.62%)	2(3.45%)	p=0.046*, S
Female	7(12.07%)	8(13.79%)	12(20.69%)	0(0%)	1(1.72%)	
Group II (41-80 yrs)						10.24
Male	4(7.69%)	6(11.54%)	9(17.31%)	5(9.62%)	14(26.92%)	p=0.027*, S
Female	2(3.8%)	5(9.62%)	6(11.54%)	0(0%)	1(1.92%)	

Graph 6.1: Comparison of Nasal Septum Pattern in two groups according to gender in group I



Graph 6.2: Comparison of Nasal Septum Pattern in two groups according to gender in group II

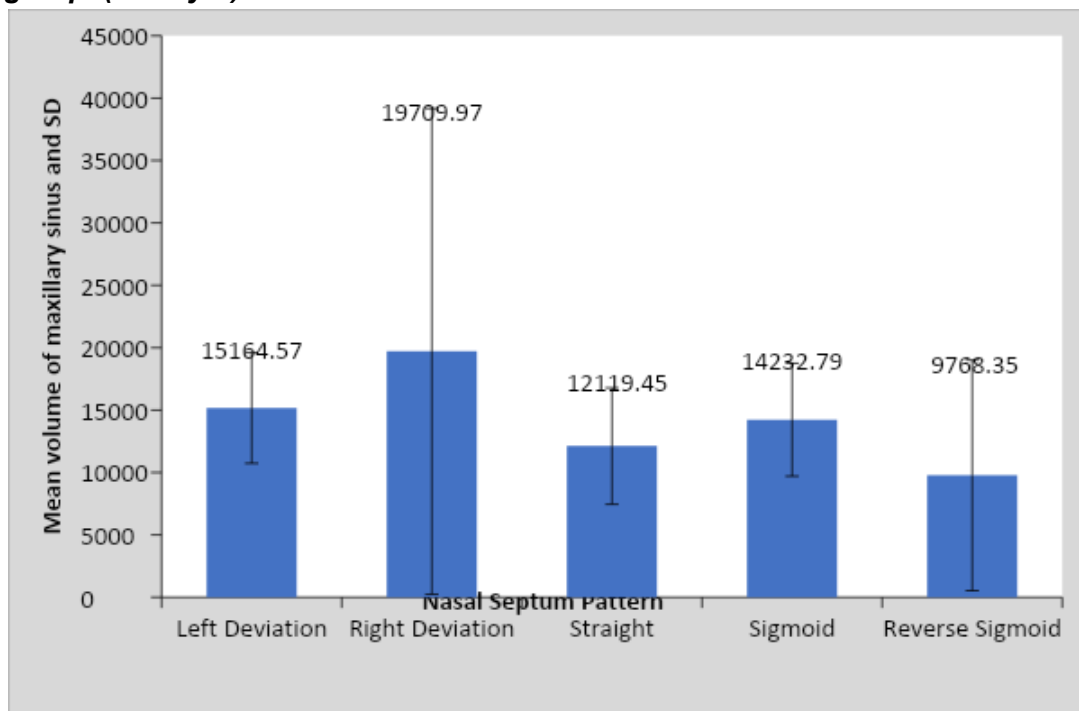


On Comparing of volume of maxillary sinus with Nasal Septum Pattern in group I (20-40) there were no volumetric changes evident with any nasal septum pattern hence the data was not significant ($P>0.5$). (Table-7 and Graph-7)

Table 7: Comparison of volume of maxillary sinus with Nasal Septum Pattern in group I(41-80yrs)

Nasal septum pattern	N	Mean	Std. Deviation	Std. Error	F-value
Left Deviation	19	15164.57	4428.62	1015.99	1.34 $p=0.26$ NS
Right Deviation	11	19709.97	19459.54	5867.27	
Straight	20	12119.45	4664.99	1043.12	
Sigmoid	5	14232.79	4525.87	2024.03	
Reverse Sigmoid	3	9768.35	9236.57	5332.73	
Total	58	14617.15	9636.23	1265.29	

Graph 7: Comparison of volume of maxillary sinus with Nasal Septum Pattern in group I(41-80yrs)

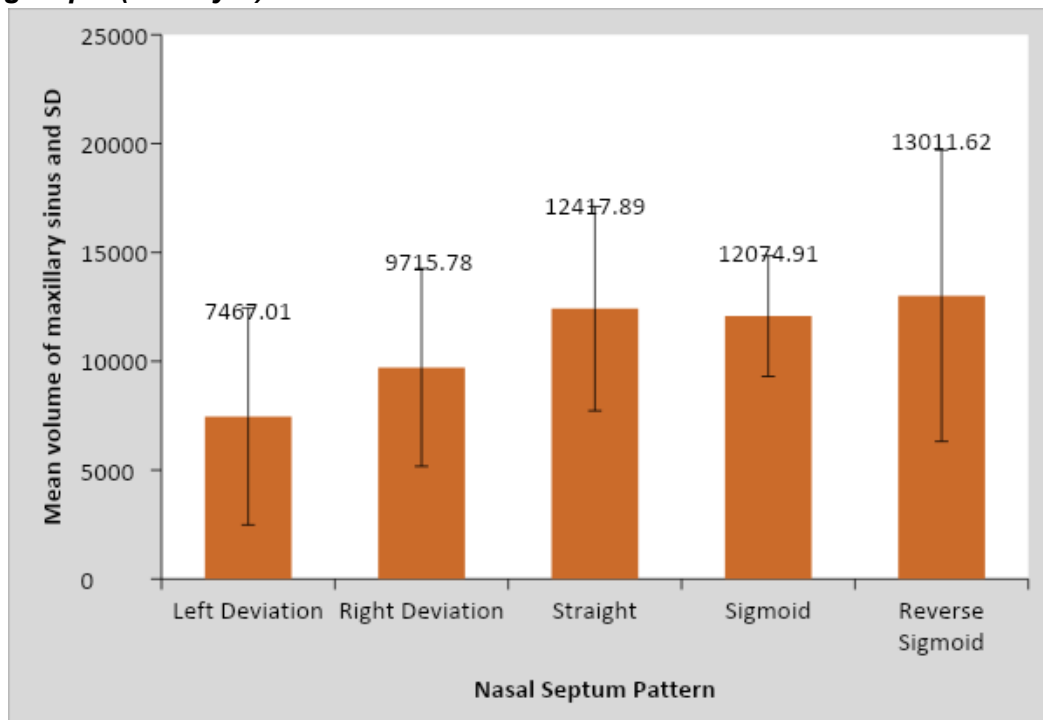


On Comparing of volume of maxillary sinus with Nasal Septum Pattern in group II there were no volumetric changes evident with any nasal septum pattern hence the data was no significant ($P>0.5$). (**Table-8 and Graph-8**)

Table 8: Comparison of volume of maxillary sinus with Nasal Septum Pattern in group II (41-80 yrs)

Nasal septum pattern	N	Mean	Std. Deviation	Std. Error	F-value
Left Deviation	6	7467.01	4982.37	2034.04	1.63 $p=0.18$ NS
Right Deviation	11	9715.78	4541.00	1369.16	
Straight	15	12417.89	4690.63	1211.11	
Sigmoid	5	12074.91	2769.40	1238.51	
Reverse Sigmoid	15	13011.62	6691.03	1727.61	
Total	52	11413.32	5380.78	746.18	

Graph 8: Comparison of volume of maxillary sinus with Nasal Septum Pattern in group II (41-80 yrs)



Discussion

“Application of dental expertise in the investigation of crime and administration of justice” is how forensic dentistry is characterised. Human identity is a deeply embodied field that binds masculinity in a variety of ways. Fingerprints, dental comparisons, and biological procedures such as DNA profiling are the most often used ways of identification, however when soft tissue of human remains decays, DNA is badly damaged, or dental comparisons are altered, identification becomes problematic.⁷ Cone-beam computed tomography is a relatively recent sophisticated imaging technique that has sparked attention in its dental applications. The advantages of CBCT for pre-mortem and post-mortem forensic imaging, such as excellent resolution for skeletal imaging, cheap cost, mobility, and simplicity, may be beneficial in various forensic trials.

It offers a non-invasive method of determining age, which is an essential element of forensic science. Estimation is a key component of forensic dentistry, and dentistry gives a non-invasive alternative.¹ Sidhu R et al in his study reported that the maxillary sinuses remain intact although the skull and other bones may be badly disfigured in victims who are incinerated and therefore, that maxillary sinuses can be used for identification.⁸

In 2019, Mohan G et al used a 96 digital posteroanterior cephalogram to combine the nasal septum and frontal sinus patterns, as well as the area and lobulations of the frontal sinus. This will be a useful tool and an easy, quick method for a tentative screening in case of mass disasters for sex determination and personal identification.⁹

In our study, we used cbct to compare the volume of the maxillary sinus with nasal septum patterns in forensic personal identification. The CBCT images of 110 patients will be obtained and examined retrospectively from the department of oral medicine and radiology in this study.

The volume of the maxillary sinus estimated by geometric computation revealed that the volume of the maxillary sinus differed significantly by age between Group 1 (20-40 yrs) and Group 2 (41-80 yrs). According to the findings, the volume of the maxillary sinus decreases with age. There were no volumetric differences between the two groups when the volume of the maxillary sinus was compared by gender.

On comparing Nasal Septum Pattern according to age in two groups there was significant changes in the left deviation pattern in age group I (20-40 yrs). According to gender there was a significant change in reverse sigmoid in male in Group II (41-80 yrs) and straight nasal septum pattern in female in group 1 (20-40 years) hence the data was found to be significant.

Similarly, a study done by Paul et al in his study most of the images of nasal septum pattern obtained in Group I (20-30 years) and Group II (30-40 years) has straight, where as in Group III (40-50years) straight and sigmoid are equal in number. Male have more straight nasal septum in Group III (40-50years), II (30-40years) and sigmoid in Group I(20-40years). Female have more straight nasal septum in Group I, II and in sigmoid in Group III.

On Comparing of volume of maxillary sinus with Nasal Septum Pattern in group I (20-40yrs) and group II (41-80 yrs) there were no volumetric changes evident with any nasal septum pattern ($P>0.5$).

Similar retrospective study was done by Dr. Paul A et al based on the age, the study consisted of 3 groups. Group -I consist of 39 CBCT images obtained from age ranges from 21 to 30years, Group -II consisted of 48 CBCT images obtained from age range of 31 to 40 years and Group III consisted of 13 CBCT images ranges from 41 to 50 years. In his study the volume of the maxillary sinus calculated by geometric calculation yielded results that

were highly significant between the groups ($p < 0.5$). This study shows that the volume of maxillary sinus to decrease with increase in the age, this same finding is seen in our study.

However, comparison of the maxillary sinus volume with the nasal septum patterns there was volumetric changes evident with reverse sigmoid pattern which is significant in all groups ($P < 0.01$).²

Cone beam computed tomography (CBCT) is a radiographic imaging method that allows accurate, three-dimensional (3D) imaging of hard tissue structures. CBCT is the most significant among the medical diagnostic imaging modalities that have emerged recently. Increasing availability of this technology is now providing the dental clinician an imaging modality, which is capable of providing a 3D representation of the maxillofacial structures with minimal distortion and reduced radiation hazards.¹⁰

Images of patient 20-80 years, clinically healthy maxillary sinuses and having permanent teeth, individuals without any developmental craniofacial malformations and systemic conditions affecting growth and individuals with no history of trauma in the maxillofacial region are included in the study. Individuals with the history of surgery of Nasal region, images with maxillary sinuses pathology such as mucosal thickening, sinusitis and odontogenic cyst or tumor, radiographic imaging errors/distortions are excluded from study.

Conclusion

In light of the findings, maxillary sinus volume measurements can be utilised as a tool in forensic anthropology to help determine sex. In age group I (20-40 years), there was a significant change in the left deviation pattern, and there was a significant change in the reverse sigmoid pattern in males and the straight nasal septum pattern in females. To make a probable identification, a comparison of ante mortem and post mortem information is

required. In order to arrive at a positive identification, more research with a larger number of images to compare will be necessary in the future.

ETHICAL APPROVAL (WHERE EVER APPLICABLE)

Approval from the Institutional Ethics Committee were taken. Ethical committee number- SDKS/PG/STRG/ODMR/1-2-2019

COMPETING INTERESTS DISCLAIMER:

Authors have declared that no competing interests exist. The products used for this research are commonly and predominantly use products in our area of research and country. There is absolutely no conflict of interest between the authors and producers of the products because we do not intend to use these products as an avenue for any litigation but for the advancement of knowledge. Also, the research was not funded by the producing company rather it was funded by personal efforts of the authors.

REFERENCES

- 1.** Gopal SK. Role of 3 D Cone Beam Computed Tomography Imaging in Forensic Dentistry: A Review of Literature. Indian Journal of Forensic Odontology. December 2018;11(5):75-82.
- 2.** Saraswathi Gopal D, Paul A. Maxillary Sinus, Frontal Sinus and Nasal Septum Patterns in Personal Identification in Forensics Using CBCT-A Retrospective Study. Sch. J. Dent. Sci., 2017; 4(4):158-167.
- 3.** Gopal KS, Vijayan BP. Significance of Frontal Sinus and Nasal Septum Patterns in Personal Identification in Forensics. Int J Oral Health Med Res. 2016;2(6):57-61.
- 4.** Kim IS, Lee MY, Lee KI, Kim HY, Chung YJ. Analysis of the development of the nasal septum according to age and gender using MRI. Clinical and experimental otorhinolaryngology. 2008 Mar;1(1):29-34.
- 5.** David MP, Saxena R. Use of frontal sinus and nasal septum patterns as an aid in personal identification: A digital radiographic pilot study. Journal of forensic dental sciences. 2010 Jul;2(2):77-80.

- 6.** Tambawala SS, Karjodkar FR, Sansare K, Prakash N. Sexual dimorphism of maxillary sinus using cone beam computed tomography. Egyptian journal of forensic sciences. 2016 Jun 1;6(2):120-5.
- 7.** Nagaraj T, Nigam H, Santosh HN, Sumana CK, Gogula S, Sahu P. Personal identification using frontal sinus and nasal septum patterns in forensic medicine: A retrospective digital radiographic study. Journal of Medicine, Radiology, Pathology and Surgery. 2017 Sep 1;4(5):5-8.
- 8.** Sidhu R, Chandra S, Devi P, Taneja N, Sah K, Kaur N. Forensic importance of maxillary sinus in gender determination: a morphometric analysis from Western Uttar Pradesh, India. European Journal of General Dentistry. 2014 Jan 1;3(1):53-56.
- 9.** Mohan G, Dharman S. Sex Determination and Personal Identification using Frontal Sinus and Nasal Septum—A Forensic Radiographic Study. Prof. RK Sharma. 2019 Jan;13(1):125-130.
- 10.** Kumar M, Shanavas M, Sidappa A, Kiran M. Cone beam computed tomography-know its secrets. Journal of international oral health: JIOH. 2015 Feb;7(2):64-68.