

**Ear Wax And its Impaction: Clinical findings and management**

**ABSTRACT**

Cerumen, sometimes known as "earwax," is a natural material that cleans, coats, and smooths the external auditory canal. It is the most common cause of ear canal obstruction. While cerumen blockage of the ear canal is usually painless, it can result in a variety of implications, for example, loss of hearing, tinnitus, overflowing, itching, otalgia, discharge, odour, and cough. Ear wax becomes a concern only when it causes hearing loss or other ear-related ailments. Cerumen build-up can arise for various causes, including an inability to self-clear, overproduction or underproduction of its essential components due to delayed skin movement, or mechanical difficulties such as usage of cotton buds or hearing aids. Wax can obstruct the understanding and view of the tympanic membrane and must be gone for investigative purposes or to take imprints before installing hearing support or creating earplugs. Cerumen impaction is usually innocuous; however, it might be associated with more significant symptoms. The removal of affected cerumen is typically regarded safe. However, as eardrum tear, canal laceration, and unsuccessful ear wax elimination. These dangers can be reduced by recognizing risky individuals and customising care measures to their specific needs. All common cerumen removal strategies are Cerumenolytics (ear wax emollient agents), irrigation, and manual elimination. It is also prudent not to interfere if asymptomatic individuals and tympanic membrane visualization are not required.

**KEYWORDS:** Cerumen, cerumen impaction, ear wax, primary care.

**INTRODUCTION:**

Cerumen comes in two types: wet wax and dry wax. Caucasians and Africans have wet type more commonly, and Orientals mostly have the dry form.(1). Cerumen is produced when secretions from the glands of the ear in the ear canal's outer two-thirds combine with exfoliated squamous epithelium. Sebaceous and ceruminous gland secretions, hair, desquamated epithelium detritus, keratin, and dirt are all components of wax. These modified sweat glands open into the hair follicle space. Sebaceous glands produce fatty acid-rich fluid, whereas ceruminous glands produce lipids and pigment granules. Both glands' secretions combine with desquamated epithelial cells and keratin lost from the tympanic membrane and deep bone meatus to generate wax. Wax serves a protective role by lubricating the ear canal and encasing any foreign material that enters the canal. It has an acidic pH and is antibacterial and antifungal. In most cases, just a little amount of wax is secreted, which dries and is expelled from the meatus by jaw movements. Because some persons sweat more than others, the activity of the ceruminous glands varies as well; excessive wax may be produced and deposited as a clog in the meatus. Although "impaction" typically connotes cerumen that is stuck, jammed, or tightly filled in the ear canal, the concept of cerumen impaction doesn't necessitate complete occlusion. This concept suggests that ear wax is connected to indications that it may produce or that ear

wax prevents an ear examination from being performed.(2) Other conditions may favor wax retention, such as a small and convoluted ear canal, stiff hair, or an obstructive canal lesion, such as exostosis. It may dry out and harden into a hard impacted mass. (23) Because ear wax in the ear canal might hinder auditory or vestibular tests, it must be removed before these treatments. Cerumen has no influence on the temperature readings of an ear thermometer. (3)

## **OBJECTIVES**

The objective to write this piece of literature is to study about Ear wax (Cerumen) and its impaction. To study a better approach for the same.

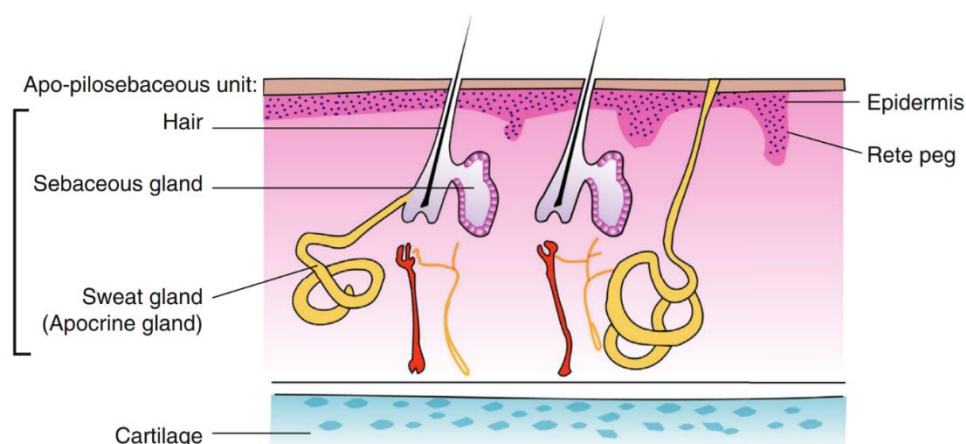
## **METHODOLOGY**

In this article, we have gained the literature on Nasal Septal Reconstruction from PubMed, Lancet, StatPearls [Internet], Elsevier, Google Scholar, Sage journals. While searching various databases. The given key words and phrases were used in different platforms and amalgamation: Cerumen, cerumen impaction, ear wax, primary care. A potential source of information was also the reference list of pertinent articles. There were no attempts to find unpublished data.

Cerumen formation is a healthy and physiological procedure for protecting the ear canal. Cerumen, on the other hand, should be removed if it produces indications (for example loss of hearing, or itching, discomfort, or tinnitus) or avoids the external auditory canal, tympanic membrane, or audio-vestibular system from being evaluated. Cerumen should not be given to patients who are unable to articulate their difficulties, such as people with cognitive impairment or impaired cognitive development, nonverbal patients with behavioral issues, and little toddlers with fever, communication delay, or parental concerns, to name a few. Cerumen impaction is a buildup of ear wax that causes warning signs or prevents inspection of the ear canal, tympanic membrane, or audio-vestibular system; complete blockage is not required..(4) In the outward area of the human ear canal,

Fig.1 Cerumen formation

there are two types of glands: Sebaceous glands that create sebum and Modified apocrine glands that secrete apocrine sweat. Cerumen is made up of these chemicals, which clean, lubricate, and, to some degree, guards the ear canal from germs and fungi(5).



In cerumen phenotypes, there is some proof of genetic variations. Cerumen has been divided into two types: wet and dry. Wet cerumen, which is light or dark brown and sticky, has a lot of lipid and pigment granules. These components are found in smaller proportions in dry ear wax, which is brown in colour and brittle. For instance, dry wax comprises about 20percent lipid, but wet cerumen has approximately 50%.(6). There is currently a developing, if far from convincing, data base demonstrating that adult and juvenile cerumen's differ in various ways. For starters, paediatric cerumen may be wetter than adult cerumen. As a result, compared to adults, cell lysis requires less hydration. Second, because children's cerumen boluses are smaller than adults', children may find it simpler to dissolve impacted wax than adults. Finally, the cerumen bolus of adults may be denser. This is due to the fact that the cerumen has been in the ear for a longer time and is hence drier. Cotton buds can also be used by adults to condense their wax.(7) Antimicrobial proteins and peptides are found in abundance in ceruminous glandular cells, including -defensin-1, -defensin-2, cathelicidin, lysozyme, lactoferrin, and MUC1, a secretory component of IgA. These findings point to a critical involvement in the inherent host defence versus a variety of infections. The apocrine discharge system is a form of discharge wherein the cytoplasm at the apex of the cell is pinched off and covered by a membrane. It has been able to demonstrate that actin filaments, CK 19 and CK 7, appear to play a part in the pinching-off process.(1) Patients with coagulopathies, liver failure, thrombocytopenia, or haemophilia, as well as those using antiplatelet or anticoagulant drugs, should be informed that removing Ear wax increases the risk of external auditory canal bleeding. In these patients, clinicians should avoid forceful irrigation or physical removal and refer them to a subspecialist. Postprocedural otitis externa is more common in immunocompromised patients and patients with diabetes mellitus which isn't under control, particularly when irrigation is applied. Malignant otitis externa, a conceivably deadly external auditory canal disease that expands swiftly to neighbouring tissues and bones, has been related to tap water irrigation.(8–10)

A variety of factors can add to impacted cerumen. For starters, structural alterations (for example stenosis of the external auditory meatus) might increase impacted Ear wax. Furthermore, keratosis obturans (a condition characterised by excessive keratin synthesis) can trigger several indications such as bone Cartilaginous wall erosion, diseases, and loss of hearing. Because sheets of undisturbed and unbroken keratin develop without any fatty material, this looks to be the external auditory canal equivalent of middle-ear cholesteatoma. In individuals with keratosis obturans, the external meatus can become significantly expanded, resulting in severe Ear wax build-up.(11) The most prevalent cause of impacted ear wax is a failure in the separation of keratinocytes in the external auditory canal as part of skin turnover.. Hard Ear wax plugs, as previously noted, contain more keratin sheets than softer wax. Corneocytes in softer wax seem to expand as well. People who have impacted ear wax on a regular basis may not produce enough of an undisclosed 'keratinocyte attachment disrupting chemical'.

**CLINICAL FEATURES** - The patient typically comes with hearing loss or a perception of an obstructed ear. Tinnitus and giddiness can occur because of wax impaction against the tympanic membrane. A reflex cough can develop when the auricular branch of the vagus nerve is stimulated. When water enters the ear canal while bathing or swimming, the wax expands and causes these symptoms to appear suddenly. Long-term impacted wax can cause meatal skin ulceration and granuloma development (wax granuloma).

**MANAGEMENT** - Potential contraindications should be recognised prior to wax removal. These disorders include a non-intact tympanic membrane, exostoses, auditory

canal narrowing, diabetes, anticoagulated or immunocompromised state, and previous radiation to the ear canal. The risk of damage, contamination, or bleeding rises when these qualities are linked with specific ear wax extraction treatments.(13) In clinical practise, three types of Ear wax removal are routinely used: cerumenolytics, irrigation, and manual removal l.(14)

**Cerumenolytic Agents-** Cerumenolytic agents are chemicals that break down impacted Ear wax, reducing the need for irrigation or physical removal. These approaches can be used in concert with cerumenolytics. Since no cerumenolytic pharmaceuticals have demonstrated to be more efficient than water or salt water, they are suggested as first-line treatments. Treatment duration has also been shown to have a negligible effect. When cerumenolytics are used in people who have healthy tympanic membranes and no dermatitis or contamination in the ear canal, consequences are mild and infrequent.(15) The three categories are based on water, oil, and various non-water/oil ear wax softening therapies. Oil-based treatments lubricate the wax, whilst water-based and non-oil treatments enhance it. Miscibility of ear wax. (16) Water based Agents are 10% Triethanolamine polypeptide oleate condensate loosens Ear wax before irrigation. It is filled fifteen to thirty minutes prior to irrigation in the afflicted auditory canal. It can irritate the ear canal and should not be used for extended periods of time; Docusate sodium loosens Ear wax prior to irrigation. It is filled fifteen to thirty minutes prior to irrigation in the ear canal that is infected. One-fifth of tympanic membranes were visible without irrigation in one research; 3% Hydrogen peroxide loosens Ear wax prior to irrigation. fifteen to thirty minutes before irrigation, it is poured in the afflicted ear canal. Bubbles might make it difficult to see the tympanic membrane if they aren't entirely eliminated; It is filled with 2 to 3 cc in the afflicted ear fifteen to thirty minutes before irrigation, or for three to fourteen days at home with or without irrigation. It has a greater impact on youngsters than on adults. Those Agents based neither on water nor oil are Carbamide peroxide (Debrox) softens Ear wax in preparation for irrigation or as a substitute for irrigation. Apply five to ten drops two times a day for up to seven days to the afflicted ear; 50% Choline salicylate and glycerol (for example Earex Plus, Audax); ethylene oxide polyoxypropylene glycol (Addax) etc. Oil-based agents are 2% paradichlorobenzene, '57.3% Arachis oil, 5% chlorbutol, 10% oil of turpentine' (e.g., Cerumol) softens Ear wax in preparation for irrigation or as a substitute for irrigation; 'Arachis oil, almond oil, rectified camphor oil (e.g., Otocerol, Earex)' softens Ear wax in preparation for irrigation or as a substitute for irrigation; 'Olive oil, almond oil, or mineral oil'.

**Irrigation-** Irrigation can be done alone or in conjunction with a cerumenolytic preparation. Technique of syringing the ear is that the patient is seated, with the ear to be syringed facing the examiner. His neck is wrapped with a towel. The patient wears a kidney tray over his or her shoulder and grips it tightly. To collect the return fluid, the patient's head is gently inclined over the tray. A jet of water from the ear syringe is directed along the posterosuperior wall of the meatus while the pinna is moved higher and rearward. The pressure of water that has built up deeper inside the wax causes the wax to be released. The water should be injected slowly, and the canal should be examined for ear wax removal on a regular basis. Irrigation must be avoided if a tympanic membrane hole or a myringotomy tube is there. Irrigation must be averted by people who have had middle ear illness, surgery of ear, radiation therapy of ear, severe otitis externa, sharply pointed unknown objects in the external auditory canal, or vertigo.(17) Alternatively, auditory irrigation performed at home by patients is possibly a more cost-efficient substitute to clinic irrigation and give equivalent advantages. Aural irrigation must be averted in individuals with punctured tympanic membranes or myringotomy tubes to prevent advancing of water

and possibly pathogenic microorganisms into the middle compartment of ear.(18) Ear irrigator tip stops water from entering the tympanic membrane and lowers pressure build-up, the risk of tympanic membrane rupture is lowered.(16) Instrumental manipulation- Manipulation using an instrument. It should always be done by expert hands and in full view of the observer. Cerumen hooks, scoops, and Jobson- Horne probes are frequently employed. First, a gap is made between the wax and the meatal wall, then the instrument is passed beyond the wax, and the entire plug is drawn out in one piece. If it breaks, the bits can be removed using a syringe. If the wax is too hard and impacted to be removed by syringing or tools, it should be softened by instilling drops of 5% sodium bicarbonate in equal parts glycerine and water two or three times a day for a few days.(23) Manual Removal- Manual In the hands of a well-trained practitioner, ear wax removal involves the use of technology to remove ear wax under direct supervision, this type of Ear wax removal is generally safe and effective, although it might cause harm in less experienced hands. (2) The benefit of manual removal is that it is quick and prevents exposing the ear canal to wetness, which decreases the danger of contamination. Manual Individuals with hereditary or developed ear disorders, those who have just undertaken ear surgery, and those who are immune-compromised often choose ear wax removal.(14) When taken before syringing or on their own, the benefits of wax softeners are uncertain. The use of wax softeners before syringing may improve clearance rates, however there is little data to support this. There isn't enough evidence to say if wax softeners alone are successful in removing wax, or whether one sort of softener is better than another.(19) Following the use of wax softeners prior to washing, a subjective assessment of the amount of wax left: the percentage of people who require mechanical removal to relieve their symptoms; Visualization of the tympanic membrane; mechanical removal was claimed to be simple (calculated, for instance, by the amount of water required for effective syringing).(19) Even though cleansing the outer ear is OK if ear wax is evident, patients should avoid putting cotton-tipped swabs or candles into the ear canal. Ear candling is when one end of a hollow candle is lit and the other is inserted into the ear canal. The flame is said to produce negative pressure, which draws wax and debris out of the ear. This strategy, however, has the possibility for negative consequences and is ineffectual. Similarly, using olive oil drops or spray on a daily basis is useless and should be avoided. Self-help alternatives such as cerumen softening drops or home irrigation kits are both effective and safe.(20-29)

## **CONCLUSION**

Misperception and avoidable self-ear cleaning with indiscriminate devices, such as cotton tip swabs, were common predisposing factors in this high recurring earwax impaction. The community's health education might help to alleviate this issue(21). In the examination and treatment of persons suffering from cerumen impaction, family doctors play a critical role. When ear wax removal is required, understanding the various ear wax removal procedures along with their contra-indications make sure that ear wax is eliminated in safety and efficiently. When cerumenolytics and irrigation fail or are contraindicated, and practitioners feel difficult with manual removal, they should be referred to ENT surgery (or lack the appropriate tools). Cerumen removal is only recommended if the patient is sick or if the patient's assessment is being hampered. Non-intact tympanic membrane, active dermatitis, or contamination of the ear canal are all contraindications to cerumenolytics. Cerumenolytic treatments such as water or saline should be utilised initially. Non-intact tympanic membrane, prior ear surgery, ear canal malformations, and history of otitis externa are all contraindications to irrigation. The patient's only hearing ear is the one that

is afflicted. After irrigation, re-acidification of the canal can aid to avoid harmful bacteria colonisation. When cerumenolytics and irrigation are unsuccessful or not indicated, and manual removal is not possible, surgical measures are usually advised.

## REFERENCES:

1. Stoeckelhuber M, Matthias C, Andratschke M, Stoeckelhuber BM, Koehler C, Herzmann S, et al. Human ceruminous gland: Ultrastructure and histochemical analysis of antimicrobial and cytoskeletal components. *The Anatomical Record Part A: Discoveries in Molecular, Cellular, and Evolutionary Biology*. 2006;288A(8):877–84.
2. Schwartz SR, Magit AE, Rosenfeld RM, Ballachanda BB, Hackell JM, Krouse HJ, et al. Clinical Practice Guideline (Update): Earwax (Cerumen Impaction). *Otolaryngol Head Neck Surg*. 2017 Jan 1;156(1\_suppl):S1–29.
3. Zehnder A, Breidthardt T, Schaub N, Reiter M, Laifer G. Limitations of infrared ear temperature measurement in clinical practice. *Swiss Medical Weekly* [Internet]. 2010 Dec 20 [cited 2021 Nov 3];(51). Available from: <https://smw.ch/article/doi/smw.2010.13131>
4. Michaudet C, Malaty J. Cerumen Impaction: Diagnosis and Management. *AFP*. 2018 Oct 15;98(8):525–9.
5. Roeser RJ, Ballachanda BB. Physiology, pathophysiology, and anthropology/epidemiology of human earcanal secretions. *J Am Acad Audiol*. 1997 Dec;8(6):391–400.
6. Guest JF, Greener MJ, Robinson AC, Smith AF. Impacted cerumen: composition, production, epidemiology and management. *QJM: An International Journal of Medicine*. 2004 Aug 1;97(8):477–88.
7. Carr MM, Smith RL. Ceruminolytic efficacy in adults versus children. *J Otolaryngol*. 2001 Jun;30(3):154–6.
8. Rubin J, Kamerer DB, Yu VL, Wagener M. Aural Irrigation with Water: A Potential Pathogenic Mechanism for Inducing Malignant External Otitis? *Ann Otol Rhinol Laryngol*. 1990 Feb 1;99(2):117–9.
9. Driscoll PV, Ramachandrula A, Drezner DA, Hicks TA, Schaffer SR. Student Research Award 1993: Characteristics of Cerumen in Diabetic Patients: A Key to Understanding Malignant External Otitis? *Otolaryngol Head Neck Surg*. 1993 Oct 1;109(4):676–9.
10. Invasive External Otitis after Removal of Impacted Cerumen by Irrigation [Internet]. <http://dx.doi.org/10.1056/NEJM199109263251320>. Massachusetts Medical Society; 2010 [cited 2021 Nov 1]. Available from: <https://www.nejm.org/doi/10.1056/NEJM199109263251320>
11. Ruddy J, Bickerton RC. Optimum Management of the Discharging Ear. *Drugs*. 1992 Feb 1;43(2):219–35.

12. Robinson AC, Hawke M, Naiberg J. Impacted cerumen: a disorder of keratinocyte separation in the superficial external ear canal? *J Otolaryngol*. 1990 Apr;19(2):86–90.
13. Zivic RC, King S. Cerumen-impaction management for clients of all ages. *Nurse Pract*. 1993 Mar;18(3):29, 33–6, 39.
14. Sharp JF, Wilson JA, Ross L, Barr-Hamilton RM. Ear wax removal: a survey of current practice. *BMJ*. 1990 Dec 1;301(6763):1251–3.
15. Horton GA, Simpson MTW, Beyea MM, Beyea JA. Cerumen Management: An Updated Clinical Review and Evidence-Based Approach for Primary Care Physicians. *J Prim Care Community Health*. 2020 Jan 1;11:2150132720904181.
16. McCarter DF, Courtney AU, Pollart SM. Cerumen Impaction. *AFP*. 2007 May 15;75(10):1523–8.
17. Roberts and Hedges' Clinical Procedures in Emergency Medicine and Acute Care [Internet]. [cited 2021 Nov 3]. Available from: <https://www.us.elsevierhealth.com/roberts-and-hedges-clinical-procedures-in-emergency-medicine-and-acute-care-9780323354783.html>
18. Coppin R, Wicke D, Little P. Randomized trial of bulb syringes for earwax: impact on health service utilization. *Ann Fam Med*. 2011 Apr;9(2):110–4.
19. Browning GG. Ear wax. *BMJ Clin Evid*. 2008 Jan 25;2008:0504.
20. Grossan M. Safe, effective techniques for cerumen removal. *Geriatrics*. 2000 Jan;55(1):80, 83–6.
21. Adegbiyi WA, Alabi BS, Olajuyin OA, Nwawolo CC. Earwax Impaction: Symptoms, Predisposing Factors and Perception among Nigerians. *J Family Med Prim Care*. 2014;3(4):379–82.
22. Kalambe, Sanika, Shraddha Jain, Ashish Disawal, Deepshikha Chandravanshi, and Sagar Gaurkar. "Supra-Threshold Hearing Sensitivity Disorders and Mild Permanent Hearing Loss: Neglected Cause of Hidden Hearing Loss and Speech Defects." *INDIAN JOURNAL OF OTOLARYNGOLOGY AND HEAD & NECK SURGERY*, n.d. <https://doi.org/10.1007/s12070-020-01816-x>.
23. Haile LM, Kamenov K, Briant PS, Orji AU, Steinmetz JD, Abdoli A, et al. Hearing loss prevalence and years lived with disability, 1990-2019: findings from the Global Burden of Disease Study 2019. *LANCET*. 2021 Mar 13;397(10278):996–1009.
24. Abbafati, Cristiana, Kaja M. Abbas, Mohammad Abbasi, Mitra Abbasifard, Mohsen Abbasi-Kangevari, Hedayat Abbastabar, Foad Abd-Allah, et al. "Five Insights from the Global Burden of Disease Study 2019." *LANCET* 396, no. 10258 (October 17, 2020): 1135–59.
25. Abbafati, Cristiana, Kaja M. Abbas, Mohammad Abbasi, Mitra Abbasifard, Mohsen Abbasi-Kangevari, Hedayat Abbastabar, Foad Abd-Allah, et al. "Global Burden of 369 Diseases and Injuries in 204 Countries and Territories, 1990-2019: A Systematic Analysis for the Global Burden of Disease Study 2019." *LANCET* 396, no. 10258 (October 17, 2020): 1204–22.
26. Franklin, Richard Charles, Amy E. Peden, Erin B. Hamilton, Catherine Bisignano, Chris D. Castle, Zachary Dingels V, Simon Hay I, et al. "The Burden of Unintentional Drowning:

- Global, Regional and National Estimates of Mortality from the Global Burden of Disease 2017 Study." INJURY PREVENTION 26, no. SUPP\_1, 1 (October 2020): 83–95.  
<https://doi.org/10.1136/injuryprev-2019-043484>.
27. James, Spencer L., Chris D. Castle, Zachary Dingels V, Jack T. Fox, Erin B. Hamilton, Zichen Liu, Nicholas L. S. Roberts, et al. "Estimating Global Injuries Morbidity and Mortality: Methods and Data Used in the Global Burden of Disease 2017 Study." INJURY PREVENTION 26, no. SUPP\_1, 1 (October 2020): 125–53.  
<https://doi.org/10.1136/injuryprev-2019-043531>.
28. James, Spencer L., Chris D. Castle, Zachary Dingels V, Jack T. Fox, Erin B. Hamilton, Zichen Liu, Nicholas L. S. Roberts, et al. "Global Injury Morbidity and Mortality from 1990 to 2017: Results from the Global Burden of Disease Study 2017." INJURY PREVENTION 26, no. SUPP\_1, 1 (October 2020): 96–114. <https://doi.org/10.1136/injuryprev-2019-043494>.
29. Lozano, Rafael, Nancy Fullman, John Everett Mumford, Megan Knight, Celine M. Barthelemy, Cristiana Abbafati, Hedayat Abbastabar, et al. "Measuring Universal Health Coverage Based on an Index of Effective Coverage of Health Services in 204 Countries and Territories, 1990-2019: A Systematic Analysis for the Global Burden of Disease Study 2019." LANCET 396, no. 10258 (October 17, 2020): 1250–84.  
[https://doi.org/10.1016/S0140-6736\(20\)30750-9](https://doi.org/10.1016/S0140-6736(20)30750-9).