

Case study

Effectual physiotherapy treatment in a 16 year old case of atrial septal defect- A single case study

ABSTRACT:

Background:

Paediatric cardiac surgeries have an immense survival rate and rehabilitation plays a major role in such cases. Many patients are diagnosed with septal defects or valve defects at birth which come under cardiac surgeries.

Case presentation:

This is a case of 16 year old boy who had atrial septal defect and underwent atrial septal defect closure.

Investigations:

2D echocardiography revealed atrial septal defect.

Management:

Physiotherapy intervention included patient education, breathing retraining, airway clearance techniques, positioning, and psychological support and mobility program. Outcome measures have shown enhancement in functional independence and performance of activities of daily living.

Conclusion:

The evidence from this study suggest that paediatric cardiac rehabilitation found to play a pivotal role in managing a patient who had atrial septal defect.

KEYWORDS: Atrial Septal Defect, Congenital Heart Defect, Physical rehabilitation

INTRODUCTION:

A hole in the septum, the muscular wall that differentiates the heart's two upper chambers, is identified as an atrial septal defect (ASD) (atria). An atrial septal defect is a birth defect (congenital defect) that occurs when the septum does not form properly. It is commonly referred to as a "hole in the heart." Atrial septal deformities are common congenital heart defects labelled by inadequate or lacking tissue at the inter-atrial septum. The average age at diagnosis is more than four years old(1). Indications of atrial septal defect closure were all provided to very little faults, somewhat pulmonary hypertensive atrial septal defect, older patients and younger kids(2). The strength of the shunt, right ventricular (RV), volume, pulmonary arterial pressures and the presence of arrhythmias determines the ability for exercise in individuals with unseparated atrial septal defect (3).

25-30 percent of the new identified congenital heart abnormalities stay undiscovered until adulthood. Septal atrial failure Closure has become a well-established treatment for more and more adult patients(4). Early surgical reparations have great long-term effects, however the results are less favourable when the procedure is postponed until maturity. Even in patients older than 60 years, operating closure was linked with symptoms and potentially survival. In healthy individuals and persons with ischemic heart disease, the benefits of exercise have been established(5). Children with congenital heart disease are also urged to practise and be completely active following corrective intervention. Kids with congenital cardiac conditions undergoing corrective operations are encouraged to do a graduated rehabilitation programme for exercise(6). The condition was previously analogous to myocardial infarction sufferers.

Clinicians considered it more conservative for these patients, for six weeks till thoracotomy lesions were cured, to avoid strenuous physical exercise. Children were able to resume their previous activities after that period. Clinical investigations have showed that many infants who were operated by congenital cardiac disease have never been completely active. Children with successful cardiac disease repair are often less active than healthy classmates. Some youngsters may complain of tiredness early in a physical exercise, which can in many cases be linked to some decondition(7). Only a minority has a physical activity limitation. This case study focuses on tailor made rehabilitation program on a 16 year old patient diagnosed with atrial septal defect.

PATIENT INFORMATION:

A 16 year old male presented to the hospital with complain of breathlessness, vomiting along with cough after eating food and suffered usually from cough and cold. He also complained about dizziness and suffocation. He stated that he have not done any physical activity in his life. After walking 500 m he used to get breathlessness and fatigue. Consultation with a local doctor revealed a small atrial septal defect. After routine investigations and obtaining fitness from anaesthetist, surgery of atrial septal defect closure was carried out. Midline sternotomy approach was used. Patient was intubated during the procedure. The surgery was carried out successfully and patient was shifted to ICU with intubation. The patient was extubated the next day and physiotherapy rehabilitation was started.

Timeline-

Date of admission	10/10/2021
Date of surgery	14/10/2021
Date of physiotherapy referral	15/10/2021
Date of discharge	26/10/2021

Table 1 showing timeline of the patient from the day of admission till the day of discharge

CLINICAL FINDINGS:

Inspection showed that patient was conscious, in supine position, ECG leads present, mediastinal drain present, and Foley's catheter was seen. The patient was on 6 litres of O₂ via face mask.

Systemic examination revealed pulse rate- 130 beats/min, blood pressure-130/90 mm Hg,SPO₂-98%,Respiratory Rate: - 36 breaths/min with regular rhythm and abdominal-thoracic type of breathing. Chest excursion was bilaterally decreased, **p**ercussion revealed bilateral dull note all over the lung fieldsand auscultation showed bilateral crepitations all over the lung fields.

Diagnostic assessment included 2D echocardiography which revealed small atrial septal defect and chest X-ray.

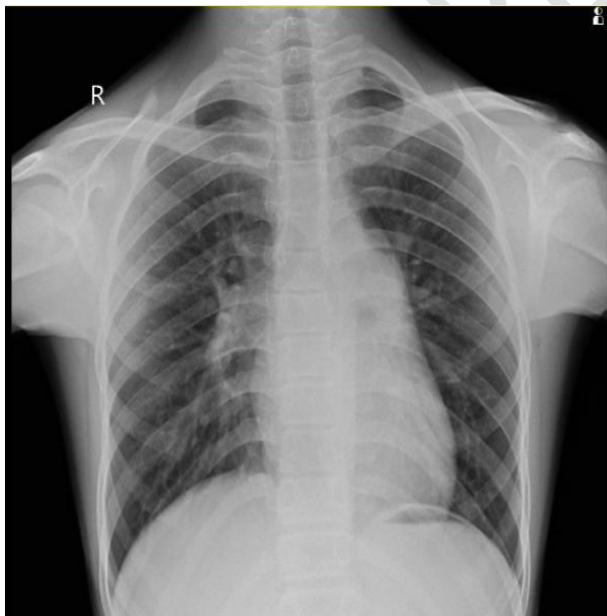


Figure 1- Pre-operative x-ray showing elongated heart and prominence of vascular zone in right lung

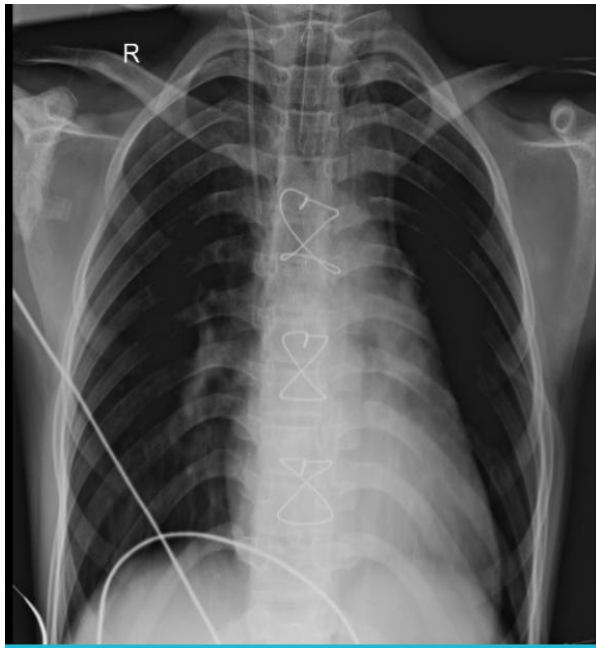


Figure 2-Post-operative x-ray showing presence of ET tube and mid sternal sutures

THERAPEUTIC INTERVENTION:

On reference to physiotherapy, patient and relative education was done first. Awareness about the need and benefits of rehabilitation after cardiac surgery was explained. Written consent was taken from the patient's relative. The patient's goal was to resume his daily life activities as soon as possible without assistance. Therapist's goal was to maintain the bronchial hygiene of the patient, targeted towards early mobilisation and improving the functional capacity.

In a paediatric cardiac operation, the risk of pulmonary complications (retention of the secretions, atelectasis, and pneumonia) is reduced and those complications are treated in the pre- and postoperative period, as well to ensure that the appropriate ventilation and extortions are carried out successfully.

Physiotherapy involves clearing and expansion method, abdominal support and instruction for parents or escorts, and patients capable of understanding such information, on the

significance and aims of intervention for physiotherapy(8). Vibration in the chest wall, percussion, compression, manual hyperinflation, manoeuvre of extension, placement, position drainage and cough stimulation], aspiration, respiratory exercising, mobility and incentive spirometer are the procedures utilised in post-operative physiotherapy. In this case, manual percussions and mechanical vibrations were given to remove secretions from lungs; which developed as a complication of cardiac surgery. Prior to chest manual techniques, humidification was provided to loosen up secretions. Followed by manual chest physiotherapy manoeuvres, suctioning was done. Positioning plays a very important role in paediatric patients to enhance the clearance of secretions in assistance with gravity. Along with this, manual hyperinflation using bag was given in which a series of deep manual inflations were provided which enhances oxygenation and prevents collapse. Followed by chest clearance technique, the patient was instructed to perform deep breathing exercises, followed by segmental expansion and active cycle of breathing technique. The exercises were performed twice a day for 10 repetitions. The physiotherapy rehabilitation was focused at early mobilisation of the patient(9).

Few recent studies on the role of physiotherapy in the post-operative post-cardiac operation, especially those that deal with the efficacy of pre-operative physiotherapy to avoid pulmonary problems following cardiac operation.

OUTCOME MEASURES

Outcome measures used included ICU Mobility Scale, WHOQOL-BREF and spirometer which showed patient's improvement in the course of hospitalization.

--	--	--

SCALES	Day 1	Day 7
ICU mobility scale	0(lying on bed)	10(walking independently)
WHOQOL-BREF	66	80
Incentive Spirometer(lung capacity)	<600cc	900cc

Table 2 showing scoring on ICU Mobility Scale, WHOQOL-BREF and Spirometer indicative of patient's improvement in the condition.

DISCUSSION

Cardiac rehabilitation is a tried-and-true treatment for people who have had heart surgery. The current single case study adds to the existing evidence on the efficacy of cardiac rehabilitation in improving the patient's overall condition. Outcome measures revealed an improvement in the patient's overall quality of life as well as lung capacity. Thus, tailored phase I cardiac rehabilitation can be used effectively in patients who have had valve replacement surgeries.

Children with cardiac problems are taught about proper physical exercise through heart rehabilitation programmes(10). The US Heart Association and the European Guidelines for Children with congenital heart diseases advocate physical exercise (11). In particular, guidelines for physical exercise in children with congenital heart diseases underline the

significance of a developmentally appropriate and pleasurable minimum of 60 minutes of daily activities. Chevrans activity is advised for a minimum of three days a week, and training is required three days a week to improve bone and muscle (e.g. high-impact and anaerobic bursting activities such as leaping (12). The involvement in high-intensity activities, particularly competition, may nonetheless be restricted by children with specific heart problems (e.g., transposition of major arteries or single ventricle disorders)(11). The screening time for children under the age of 5 should be limited to 2 hours per day, and no display time for children under the age of 3 must be permitted(13).

CONCLUSION:

Findings of this study indicates that paediatric cardiac rehabilitation found to plays a pivotal role in managing a patient who is diagnosed with atrial septal defect and undergone atrial septal defect closure ,which included breathing retraining and airway clearing techniques, mobility training. The paediatric cardiac rehabilitation program was extremely beneficial in terms of enhancing overall functional efficiency and improving quality of life. Paediatric chest physiotherapy has been a proven technique in improving the ventilation and oxygenation in post cardiac surgeries.

Consent Disclaimer:

We have added the Consent Disclaimer in the revised paper. The revised paper is attached herewith this mail for your kind perusal. Kindly check the revised paper

REFERENCES:

1. Children Diagnosed with Autism at Earlier Age More Likely to Receive Evidence-Based Treatments | psychiatry.org [Internet]. [cited 2021 Oct 19]. Available from: <https://www.psychiatry.org/newsroom/news-releases/children-diagnosed-with-autism-at-earlier-age-more-likely-to-receive-evidence-based-treatments>
2. Abdullahi A. Safety and Efficacy of Chest Physiotherapy in Patients With COVID-19: A Critical Review. *Front Med* [Internet]. 2020 [cited 2021 Aug 3];0. Available from: <https://www.frontiersin.org/articles/10.3389/fmed.2020.00454/full>
3. Amedro P, Guillaumont S, Bredy C, Matecki S, Gavotto A. Atrial septal defect and exercise capacity: value of cardio-pulmonary exercise test in assessment and follow-up. *J Thorac Dis*. 2018 Sep;10(Suppl 24):S2864–73.
4. Beningfield A, Jones A. Peri-operative chest physiotherapy for paediatric cardiac patients: a systematic review and meta-analysis. *Physiotherapy*. 2018 Sep;104(3):251–63.
5. Impact of Cardiac Rehabilitation on the Exercise Function of Children With Serious Congenital Heart Disease | American Academy of Pediatrics [Internet]. [cited 2021 Oct 26]. Available from: <https://pediatrics.aappublications.org/content/116/6/1339.short>
6. Cass L. Physical Therapy Management and Treatment of an Infant with Hypoplastic Left Heart Syndrome in the PICU with a Strong Parent-Child Bond: A Case Report. 2018;9.
7. Shakuri SK, Salekzamani Y, Taghizadieh A, Sabbagh-Jadid H, Soleymani J, Sahebi L. Pulmonary physiotherapy effect on patients undergoing open cardiac surgery. *Russ Open Med J*. 2014 Sep 15;3(3):0306.

8. Paediatric cardiac rehabilitation in congenital heart disease: a systematic review | Cardiology in the Young | Cambridge Core [Internet]. [cited 2021 Oct 26]. Available from: <https://www.cambridge.org/core/journals/cardiology-in-the-young/article/abs/paediatric-cardiac-rehabilitation-in-congenital-heart-disease-a-systematic-review/E04A0ACF723CC7A8D054F5B83B8C6AD4>
9. Marwali EM, Heineking B, Haas NA. Pre and Postoperative Management of Pediatric Patients with Congenital Heart Diseases [Internet]. Pediatric and Neonatal Surgery. IntechOpen; 2017 [cited 2021 Aug 3]. Available from: <https://www.intechopen.com/chapters/53683>
10. Tenling A, Hachenberg T, Tyden H, Wegenius G, Hedenstierna G. Atelectasis and Gas Exchange after Cardiac Surgery. Anesthesiology. 1998 Aug 1;89(2):371–8.
11. Hussey J, Hayward L, Andrews M, Macrae D, Elliott M. Chest physiotherapy following paediatric cardiac surgery: The influence of mode of treatment on oxygen saturation and haemodynamic stability. Physiother Theory Pract. 1996 Jan 1;12(2):77–85.
12. Rychik J, Atz AM, Celermajer DS, Deal BJ, Gatzoulis MA, Gewillig MH, et al. Evaluation and Management of the Child and Adult With Fontan Circulation: A Scientific Statement From the American Heart Association. Circulation. 2019 Aug 6;140(6):e234–84.
13. Chowdhury UK, Airan B, Sharma R, Bhan A, Kothari SS, Saxena A, et al. One and a half ventricle repair with pulsatile bidirectional Glenn: results and guidelines for patient selection. Ann Thorac Surg. 2001 Jun;71(6):1995–2002.