

**Spectrum of benign breast disease; a critical review of therapy. A single – center experience.**

**Abstract:**

**Background:** A benign breast condition is one that is not cancer. These conditions often go away on their own or are easily treated. Because a few benign breast conditions can increase your risk of getting cancer in the future, you may need to have follow-up tests or exams with your benign breast disease comprises a large spectrum of disease which ranges from mastalgia, nipple discharge to discrete lump. Medical management with Danazol, bromocriptine, primrose oil and Vitamin E capsules has importance along with surgical intervention in few cases.

**Materials & methods:** One hundred and one (n=101) patients with mastalgia, nipple discharge and breast lump were treated with medical or surgical management. Post treatment all patients were followed up for symptomatic relief.

**Results:** Majority of the patients (n=64) presented with mastalgia. Rest of the patients presented with nipple discharge and discrete lump. Most patients (n=75) were treated with Danazol, Linoleic Acid or Vitamin E. 85% patients were satisfied with the treatment administered to them.

**Conclusion:** Benign breast disease is a diverse spectrum with miscellaneous symptoms. Benign breast diseases are common in female patients and fibroadenoma is the commonest of them all. Triple assessment gave a firm diagnosis and it eliminates unnecessary anxiety in the patients about breast cancer or any other serious illness. Medical management is mainstay with indication of surgery in few cases.

**Key words:** Benign breast disease, Aberrations of Normal Development and Involution, Fibrocystic disease, Breast abscess, FNAC, Mammogram.

## **Introduction:**

Benign breast diseases are common disorders, up to 30% of women are clinically presented with benign breast diseases and seeking treatment at sometimes in their lives <sup>[1]</sup>. The term benign breast diseases abbreviated as BBD encompasses a heterogeneous clinical and pathological condition which ranges from inflammatory condition to benign neoplastic conditions <sup>[2-]</sup>. A comprehensive classification which puts all the processes of physiological changes, growth, development and involution into a single frame work termed as ANDI (Aberrations of Normal Development and Involution) <sup>[3]</sup>.

Chart 1: Early and late reproductive phases

	<b>Normal</b>	<b>Disorder</b>	<b>Disease</b>
Early reproductive years (15-25 yrs)	Lobular development	Fibroadenoma	Giant Fibroadenoma
	Stromal development	Adolescent hypertrophy	Giantmastia
	Nipple eversion	Nipple inversion	Subareolar abscess
Late reproductive year (26-35 yrs)	Cyclical changes of menstruation	Cyclic mastalgia	Incapacitatory mastalgia
	NA	Nodularity	NA
	Epithelial hyperplasia of pregnancy	Bloody nipple discharge	NA

The most frequently seen benign lesions of the breast are summarized as developmental abnormalities, inflammatory lesions, fibrocystic changes, stromal lesions, and neoplasms.

## **Developmental abnormalities**

Ectopic breast (mammary heterotopia) is the commonest congenital anomaly, which has been described as both supernumerary and aberrant breast tissue <sup>[4]</sup>. Underdevelopment of the breast (hypoplasia), when congenital, is usually associated with genetic disorders, such as ulnar-mammary syndrome <sup>[5]</sup>. The complete absence of both breast and nipple (amastia) or presence of only nipple without breast tissue (amaziasia) is rare <sup>[6]</sup>.

## **Inflammatory and Related Lesions**

### **Mastitis**

Inflammatory breast cancer, as the name suggests, mimics an infectious or inflammatory etiology. Most patients with inflammatory breast cancer are diagnosed after an initial treatment with antibiotics or anti-inflammatory therapies failed to show clinical improvement. Mammographic and sonographic evaluations are helpful in establishing the diagnosis. Image-guided biopsy of the abnormal breast parenchyma or skin biopsy confirms the diagnosis. A negative skin biopsy should not be used to exclude the diagnosis.

#### **Acute Mastitis**

Acute mastitis usually occurs during the first 3 months postpartum as a result of breast feeding. Also known as puerperal or lactation mastitis. Risk factors fall into two general categories: improper nursing technique, leading to milk stasis and cracks or fissures of the nipple, which may facilitate entrance of microorganisms through the skin; and stress and sleep deprivation, which both lower the mother's immune status and inhibit milk flow [7, 8, 9].

#### **Granulomatous mastitis**

Many different types of organisms can cause granulomatous mastitis. Systemic autoimmune diseases such as sarcoidosis and Wegener's granulomatosis can involve the breast [10, 11]. The etiology of the disease remains largely unknown [12].

Histologically, chronic noncaseating granulomatous inflammation is typically limited to lobuli. The recommended therapy of idiopathic granulomatous mastitis is complete surgical excision whenever possible plus steroid therapy. Long-term follow up is necessary in these patients [13, 14].

#### **Foreign Body Reactions**

Foreign materials, such as silicone and paraffin, which are used for both breast augmentation and reconstruction after cancer surgery, may cause a foreign body-type granulomatous reaction in the breast. Silicone granulomas ("siliconomas") usually occur after direct injection of silicone into the breast tissue or after extracapsular rupture of an implant.

### Recurring Subareolar Abscess

Recurring subareolar abscess (Zuska's disease) is a rare. Bacterial infection of the breast that is characterized by a triad of draining cutaneous fistula from the subareolar tissue; a chronic thick, pasty discharge from the nipple <sup>[15]</sup>. The disease is caused by squamous metaplasia of one or more lactiferous ducts in their passage through the nipple, probably induced by smoking <sup>[16]</sup>.

### **Mammary Duct Ectasia**

It is a disease of primarily middle-aged to elderly parous women, who usually present with nipple discharge, a palpable subareolar mass, noncyclical mastalgia, or nipple inversion or retraction. The most important histologic feature of this disorder is the dilatation of major ducts in the subareolar region. The pathogenesis and the etiology of the disease are still being debated. Smoking has been implicated as an etiologic factor in mammary duct ectasia <sup>[17, 18]</sup>. Mammary duct ectasia generally does not require surgery and should be managed conservatively <sup>[19]</sup>. In some patients, clinical presentation and mammographic findings may suggest malignancy, and biopsy may be required to exclude malignancy.

### **Fat Necrosis**

Fat necrosis of the breast is a benign nonsuppurative inflammatory process of adipose tissue. . It can occur secondary to accidental or surgical trauma. Clinically, fat necrosis may mimic breast cancer if it appears as an ill-defined or spiculated dense mass, associated with skin retraction, ecchymosis, erythema, and skin thickness <sup>[20]</sup>. Mammographic, sonographic, and magnetic resonance imaging findings may not always distinguish fat necrosis from a malignant lesion. Excisional biopsy is required if carcinoma cannot be excluded preoperatively <sup>[21]</sup>.

### **FIBROCYSTIC CHANGES**

Fibrocystic changes (FCCs) constitute the most frequent benign disorder of the breast. Such changes generally affect premenopausal women between 20 and 50 years of age <sup>[22– 29]</sup>.

FCCs may be multifocal and bilateral. The most common presenting symptoms are breast pain and tender nodularities in breasts. The exact pathogenesis of the entity is not clear, hormonal

imbalance, particularly estrogen predominance over progesterone, seems to play an important role in its development <sup>[30]</sup>.

Therefore, it is practical to evaluate FCCs under a classification system first proposed by Dupont and Page <sup>[31]</sup>, as nonproliferative lesions, proliferative lesions without atypia, and proliferative lesions with atypia (atypical hyperplasia). In various studies, it has been shown that the great majority of breast biopsies (up to 70%) show nonproliferative lesions. FCCs comprise both cysts (macro and micro) and solid lesions, including adenosis, epithelial hyperplasia with or without atypia, apocrine metaplasia, radial scar, and papilloma.

### **Cysts**

Cysts are fluid-filled, round or ovoid structures that are found in as many as one third of women between 35 and 50 years old. Cysts cannot reliably be distinguished from solid masses by clinical breast examination or mammography; in these cases, ultrasonography and fine needle aspiration (FNA) cytology, which are highly accurate, are used.

### **Adenosis**

Adenosis of the breast is a proliferative lesion that is characterized by an increased number or size of glandular components, mostly involving the lobular units. The most common types are Sclerosing adenosis and Microglandular adenosis <sup>[32]</sup>. Sclerosing adenosis can manifest as a palpable mass or as a suspicious finding at mammography. It is strongly associated with various proliferative lesions, including epithelial hyperplasias.

Microglandular adenosis of the breast is characterized by a proliferation of round, small glands distributed irregularly within dense fibrous and/or adipose tissue. Most of the glandular structures have open lumina in which eosinophilic material is usually seen. The most important histological feature of microglandular adenosis is that it may lack the outer myoepithelial layer seen in other types of adenosis <sup>[33, 34]</sup>.

## **Metaplasia**

They are more frequently found in younger women. All normal and metaplastic apocrine cells can be stained with gross cystic disease fluid protein 15. Clear cell metaplasia of the breast is a rare lesion. Its significance comes from its morphologic similarity to clear cell carcinoma <sup>[35]</sup>.

## **Epithelial Hyperplasia**

Epithelial hyperplasia (ductal or lobular type) is one of the most challenging FCCs to diagnose properly. Epithelial hyperplasia is the most common form of proliferative breast disease. It can be difficult to distinguish between ductal and lobular hyperplasias.

### ***Ductal Lesions***

Normally, breast ducts are lined by two layers of low cuboidal cells with specialized luminal borders and basal contractile myoepithelial cells. The most important cytologic features of mild, moderate, or florid epithelial hyperplasia are an admixture of cell types (epithelial cells, myoepithelial cells, and metaplastic apocrine cells) and variation in the appearances of epithelial cells and their nuclei <sup>[36, 37]</sup>. The term atypical ductal hyperplasia is defined as a type of a ductal hyperplasia that morphologically mimics low-grade ductal carcinoma in situ (DCIS). Atypical ductal hyperplasia is a rare condition among patients having biopsies for a palpable mass, seen in 4% of symptomatic benign biopsies. In contrast, 31% of biopsies performed because of micro calcifications show atypical ductal hyperplasia <sup>[38]</sup>. Women with atypical ductal hyperplasia develop cancer usually within 10–15 years of the diagnosis. The risk for cancer declines after 15 years <sup>[39, 40]</sup>.

Routine follow-up for both breasts is recommended. Therapy options, such as chemoprevention, should be determined on the basis of other risk factors for breast cancer.

### ***Lobular Lesions***

Lobular-type epithelial proliferations, both atypical lobular hyperplasia and lobular carcinoma in situ, are collectively termed lobular neoplasia because, unlike ductal lesions, which exhibit heterogeneous morphologic features, the histologic features of lobular type epithelial proliferations are very similar, and the only difference between atypical lobular hyperplasia and

lobular carcinoma in situ is the extent and degree of epithelial proliferation. Lobular neoplasia is a relatively rare breast lesion. It rarely manifests itself clinically. Lobular neoplasia is identified as an incidental finding in biopsies excised for other abnormalities.

### **Columnar Cell Lesions**

Columnar cell lesions of the breast represent a spectrum of lesions that have been encountered with increasing frequency in needle core breast biopsies because these lesions are commonly associated with microcalcifications and detected by mammographic screening.

### **Radial Scar and Complex Sclerosing Lesion**

Radial scars are benign pseudoinfiltrative lesions of uncertain significance. They are characterized by a fibroelastotic core with entrapped ducts, surrounded by radiating ducts and lobules displaying variable epithelial hyperplasia, adenosis, duct ectasia, and papillomatosis<sup>[41]</sup>. The role of FNA cytology in diagnosis is limited. A spiculated lesion suggestive of radial scar or complex sclerosing lesion at mammography may be excised on the basis of its size and amount of sampling performed by core biopsy<sup>[42 - 44]</sup>.

### **Intraductal Papilloma and Papillomatosis**

Intraductal papilloma is a discrete benign tumor of the epithelium of mammary ducts. It can arise at any point in the ductal system and shows a predilection for the extreme ends of the ductal system: the lactiferous sinuses and the terminal ductules<sup>[45]</sup>. Juvenile papillomatosis of the breast is defined as severe ductal papillomatosis occurring in young women of <30 years old. There only eight male juvenile papillomatosis cases reported in the literature<sup>[46]</sup>.

## **PROLIFERATIVE STROMAL LESIONS**

### **Diabetic Fibrous Mastopathy**

Diabetic fibrous mastopathy is an uncommon form of lymphocytic mastitis and stromal fibrosis. Clinically, diabetic fibrous mastopathy is characterized by solitary or multiple ill-defined, painless, immobile, discrete lesions in one or both breasts that raise the suspicion of carcinoma.

The pathogenesis of diabetic fibrous mastopathy is unknown. The mammographic and sonographic findings of these lesions are also highly suspicious for breast cancer, so a biopsy is always essential for definitive diagnosis <sup>[47, 48]</sup>.

### **Pseudoangiomatous Stromal Hyperplasia of the Breast**

Pseudoangiomatous stromal hyperplasia (PASH) is a benign myofibroblastic proliferation of nonspecialized mammary stroma. Originally, hormonal stimulation (particularly with progesterone) was suggested in the etiology of PASH. Clinically, rare cases of PASH present as a well-circumscribed, dense, rubbery mass mimicking a fibroadenoma or a phyllodes tumor. Both the mammographic and sonographic features in PASH are nonspecific, so biopsy of these lesions is necessary to exclude a malignancy <sup>[49, 50]</sup>.

## **NEOPLASMS**

### **Fibroadenoma**

Fibroadenoma is the most common lesion of the breast; it occurs in 25% of asymptomatic women. It is usually a disease of early reproductive life; the peak incidence is between the ages of 15 and 35 years <sup>[51]</sup>. Fibroadenoma presents as a highly mobile, firm, nontender and often palpable breast mass. Phyllodes tumor is a fibroepithelial tumor of the breast with a spectrum of changes. Benign phyllodes tumor is usually difficult to differentiate from fibroadenoma. Minimally invasive techniques, such as ultrasound-guided cryoablation, seem to be an excellent treatment option for fibroadenoma in women who wish to avoid surgery <sup>[52]</sup>.

Fibroadenomas in older women or in women with a family history of breast cancer have a higher incidence of associated carcinoma <sup>[53, 54]</sup>.

### **Lipoma**

Lipoma of the breast is a benign, usually solitary tumor composed of mature fat cells. If the clinical diagnosis of lipoma is confirmed by either FNA biopsy or core biopsy, and the mammogram and the ultrasonogram show nothing suspicious for malignancy at the site, the patient is normally followed through palpation after 6 months. However, if the diagnosis is not certain or the lesion grows rapidly, the tumor should be surgically removed <sup>[55, 56]</sup>.



## **Adenoma**

An adenoma is pure epithelial neoplasm of the breast. This lesion is divided into tubular, lactating, apocrine, ductal, and so-called pleomorphic (i.e., benign mixed tumor) adenoma <sup>[57]</sup>.

### **Nipple Adenoma**

This is a benign tumor of the ductal epithelium that often clinically mimics Paget's disease and pathologically may be misinterpreted as an adenocarcinoma. Typically, nipple adenoma presents as a discrete, palpable tumor of the papilla of the nipple. Erosion of the nipple and nipple discharge are usually seen. Nipple adenoma is considered a benign lesion, but rarely malignant change within or contiguous with nipple adenoma has been defined <sup>[58, 59]</sup>.

### ***Hamartoma***

Hamartoma of the breast is an uncommon benign tumorlike nodule, also known as fibroadenolipoma, lipofibroadenoma, or adenolipoma, composed of varying amounts of glandular, adipose, and fibrous tissue. Clinically, hamartoma presents as a discrete, encapsulated, painless mass. On macroscopic examination, hamartomas are typically well-circumscribed lesions with smooth contours. The current management of hamartomas is surgical removal.

## **Granular Cell Tumor**

Granular cell tumor is an uncommon, usually benign neoplasm that originates from Schwann cells of the peripheral nervous system. Clinically, granular cell tumor can simulate carcinoma because of its fibrous consistency, fixation to the pectoral fascia, skin retraction, and ulceration. Mammographic and ultrasonographic findings may further increase the suspicion of a malignant lesion <sup>[60]</sup>. Clinical presentations include cyclic or noncyclic mastalgias, nipple discharge, and discrete lump or diffuse lumpiness. 90% Patient may present with one or more symptoms. Breast lump in premenopausal women are benign and usually represents with fibroadenoma in early reproductive period. In middle reproductive period fibrosis, hyperplasia and cyst are more likely. In later reproductive period hyperplasia, cyst and carcinoma in situ are more common. Multipapilloma, sclerosing adenosis and radial scar are other clinical presentations of breast lump. Spontaneous, serous or bloody, unilateral single duct discharges are considered pathological or non-pathological. It needs radiological evaluation. Etiology of mastalgia remains

unproven. Role of caffeine, iodine deficiency, and alteration in fatty acid levels in the breast, fat intake in diet and psychological factors in the etiology of breast pain has been suggested <sup>[61-69]</sup>.

Medical management of BBD is mainstay of treatment. Danazol, bromocriptine and tamoxifen has been proven to be effective. Linoleic acid in the form of evening primrose oil has been found to be effective. In randomized trials Vitamin E tablets being widely used and found to be ineffective. Surgical management in discrete breast lump is found to be satisfying in subset of patients of fibroadenoma, multiple papilloma, sclerosis adenosis and fibrocystic disease. This study was conducted at a tertiary cancer centre. Patients with BBD were followed up for a period of 6 months with surgical and non surgical treatment. Results were interpreted in terms of patient satisfaction and quality of life.

### **Methods:**

<u>Study design</u>	: Observational study
<u>Sample Size</u>	: 101 patients
<u>Study Duration</u>	: 6 months (From June 2020 to December 2020)
<u>Sponsor</u>	: No funding to conduct this study
<u>Mode of contact</u>	: Telephonic Follow ups done

### **Inclusion Criteria:-**

- Women of age groups 16-55 years.
- Lactating mothers.
- Willingness to sign the informed consent form.
- Willingness to turn up for routine follow ups.

### **Exclusion Criteria:-**

- Histopathologically proven cases of neoplastic lesions.
- Lost to follow ups.
- Not willing to sign informed consent form.

One hundred and one patients (n=101) clinically presented with mastalgia, breast lumps and nipple discharge visited OPD of tertiary cancer care centre between June 2020 to December 2020. Histopathologically confirmed neoplastic lesions were excluded from this study. Biopsy proven fibroadenoma and phyllodes tumor cases were also excluded from this study. All patients undergone USG and breast bilateral mammography (B/L MMG). Majority of medical

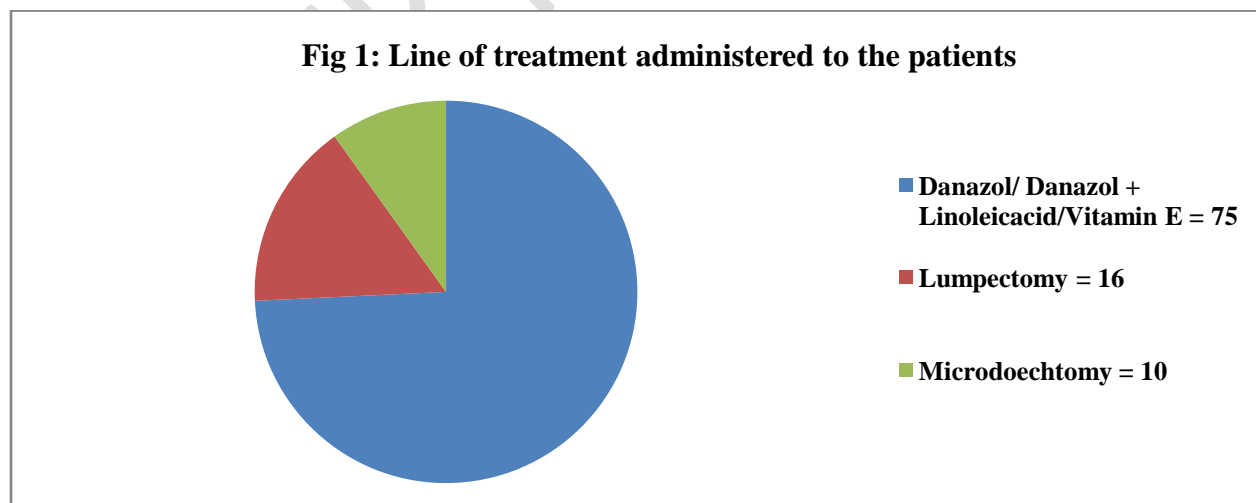
management in the form of Danazol or Vitamin E/ Linoleic acid for at least 2 months or maximum 6 months. Few patients underwent surgery in the form of lumpectomy or microdochectomy. Patients post treatment were on regular follow ups.

### **Result:**

A total of (n=101) patients visited tertiary cancer centre in the Medical and Surgical Oncology department. Patients presented with Fibrocystic disease was 29 (29.29%), Fibroadenosis 17 (17.17%), Ductal papilloma 13 (13.13%), Ductal ectasia 20 (20.2%), Ductal hyperplasia 6 (6.02%), Inflammatory breast disease 10 (10.1%), Granulomatous mastitis 6 (6.06%).

Data interpretation of the treatment result was done in the form of symptoms relive and patient satisfaction. Most of the patients (64.6%) clinically presented with mastalgia followed by breast lumps in 22.2% patients. Nipple discharge was also observed in the patients and discharge was classified into Serous (14.14%), Greenish (5.05%), Milky (6.06%), Bloody discharge (8.08) patients. Discrete breast lump, another remarkable clinical presentations found in 22.22% patients followed by menstrual irregularity were seen in 41.41% patients.

**Table 1: Result of treatment captured on the basis of patient satisfaction and relief in symptoms.**



During follow-up we have observed 85% had satisfactory response where in 15% patients they had not satisfied with the treatment administered. Complete response seen in 55% patient, partial response seen in 25 patients and 20% patients had not symptomatic relief. They were advised to visit the hospital for routine follow up.

**Discussions:** In this study majority of the patients presented with cyclic or non-cyclic mastalgia. One third of the patients experienced nipple discharge and few patients presented with breast lump. Menstrual irregularity was almost present in patients with mastalgia. Among all diagnosed benign breast disease fibrocystic disease was in majority followed by ductal papilloma and ductal ectasia. Navneet et al found 40% women with fibroadenoma, 50% patients with nodularity and mastalgia and less than 10% with galactorrhea and nipple discharge <sup>[70]</sup>.

Hatim et al similarly found 77.62% cases of fibroadenoma followed by fibrocystic disease (4.3%) and gynaecomastia <sup>[71]</sup>. As fibroadenoma was excluded from our study, fibrocystic disease was also in majority in our study too. Many randomized and non-randomized clinical trials have been done regarding the efficacy of Linoleic acid, Danazol, bromocriptine and tamoxifen in the treatment of BBD. Linoleic Acid is found promising in few randomized clinical trials but Vitamin E is considered ineffective in randomized trials <sup>[72-74]</sup>.

As hormonal depletion principle of mastalgia is well effective treatment. Many hormonal treatments i.e. GnRH analogue, Androgens have been tried to treat symptoms associated with Danazol, Linoleic acid or Vitamin E. Lumpectomy and microdochectomy is the main surgical modality being used in minority of the patients with mixed results. In our study 75% of the patients were treated medically with Danazol, linoleic acid or Vitamin E. Rest of the patients were treated surgically. Majority of the patients were satisfied by their treatment with 55% having complete symptomatic relief.

Finally we concluded that benign breast disease being a wide spectrum of disorder is successfully treated by medicine in majority of the cases followed by surgery in few cases.

**Financial Support & Sponsorship:** Nil

**Conflicts of Interest:** There are no conflicts of interest.

## References:

1. Caleffi M, Filho DD, Borghetti K et al. Cryoblation of benign breast tumors: evolution of technique and technology. *Breast* 2004;13:397-407.
2. Kelsey JL, Gammon MD. Epidemiology of cancer. *Epidemiology Rev* 1990;12:228-240.
3. Cole P, Mark Elwood J, Kaplan SD. Incidence rates and risk factors of benign breast lesion. *Am J Epidemiol* 1978;108:112-120.
4. Pfeifer JD, Barr RJ, Wick MR. Ectopic breast tissue and breast-like sweat gland metaplasias: an overlapping spectrum of lesions. *J Cutan Pathol* 1999; 26:190–196.
5. Schinzel A. Ulnar-mammary syndrome. *J Med Genet* 1987; 24:778–781.
6. Rosen PP, ed. Chapter 2. Abnormalities of mammary growth and development. In: *Rosen's Breast Pathology, Second Edition*. Philadelphia: Lippincott Williams & Wilkins, 2001:23–27.
7. Foxman B, D'Arcy H, Gillespie B et al. Lactation mastitis: occurrence and medical management among 946 breastfeeding women in the United States. *Am J Epidemiol* 2002; 155:103–114.
8. Michie C, Lockie F, Lynn W. The challenge of mastitis. *Arch Dis Child* 2003; 88:818–821.
9. Dener C, Inan A. Breast abscesses in lactating women. *World J Surg* 2003; 27:130–133.
10. Erhan Y, Veral A, Kara E et al. A clinicopathologic study of a rare clinical entity mimicking breast carcinoma: idiopathic granulomatous mastitis. *Breast* 2000; 9:52–56.
11. Diesing D, Axt-Flidner R, Hornung D et al. Granulomatous mastitis. *Arch Gynecol Obstet* 2004; 269:233–236.
12. Azlina AF, Ariza Z, Arni T et al. Chronic granulomatous mastitis: diagnostic and therapeutic considerations. *World J Surg* 2003; 27:515–518.
13. Diesing D, Axt-Flidner R, Hornung D et al. Granulomatous mastitis. *Arch Gynecol Obstet* 2004;269:233–236.
14. Tewari M, Shukla HS. Breast tuberculosis: diagnosis, clinical features & management. *Indian J Med Res* 2005;122:103–110.
15. Passaro ME, Broughan TA, Sebek BA et al. Lactiferous fistula. *J Am Coll Surg* 1994;178:29–32.

16. Donegan WL. Common benign conditions of the breast. In: Donegan WL, Spratt JS, eds. *Cancer of the Breast, Fifth Edition*. St. Louis, MO: Saunders, 2002:67–110.
17. Furlong AJ, al-Nakib L, Knox WF et al. Periductal inflammation and cigarette smoke. *J Am Coll Surg* 1994; 179:417–420.
18. Rahal RMS, de Freitas-Junior R, Paulinelli RR. Risk factors for duct ectasia. *Breast J* 2005; 11:262–265.
19. Sakorafas GH. Nipple discharge: current diagnostic and therapeutic approaches. *Cancer Treat Rev* 2001; 27:275–282.
20. Kinoshita T, Yashiro N, Yoshigi J et al. Fat necrosis of breast: a potential pitfall in breast MRI. *Clin Imaging* 2002; 26:250–253.
21. Rosen PP, ed. Chapter 3. Inflammatory and reactive tumors. In: *Rosen's Breast Pathology, Second Edition*. Philadelphia: Lippincott Williams & Wilkins, 2001:29–63.
22. Kelsey JL, Gammon MD. Epidemiology of breast cancer. *Epidemiol Rev* 1990; 12:228–240.
23. Cole P, Mark Elwood J, Kaplan SD. Incidence rates and risk factors of benign breast neoplasms. *Am J Epidemiol* 1978; 108:112–120.
24. Hutchinson WB, Thomas DB, Hamlin WB et al. Risk of breast cancer in women with benign breast lesion. *J Natl Cancer Inst* 1980; 65:13–20.
25. Fitzgibbons PL, Henson DE, Hutter RV. Benign breast changes and the risk for subsequent breast cancer: an update of the 1985 consensus statement. Cancer Committee of the College of American Pathologists. *Arch Pathol Lab Med* 1998; 122:1053–1055.
26. Sarnelli R, Squartini F. Fibrocystic condition and “at risk” lesions in asymptomatic breasts: a morphologic study of postmenopausal women. *Clin Exp Obstet Gynecol* 1991; 18:271–279.
27. Bartow SA, Pathak DR, Black WC et al. Prevalence of benign, atypical, and malignant breast lesions in populations at different risk for breast cancer. A forensic autopsy study. *Cancer* 1987; 60:2751–2760.
28. Cook MG, Rohan TE. The patho-epidemiology of benign proliferative epithelial disorders of the female breast. *J Pathol* 1985; 146:1–15.

29. La Vecchia C, Parazzini F, Franceschi S et al. Risk factors for benign breast disease and their relation with breast cancer risk. Pooled information from epidemiologic studies. *Tumori* 1985; 71:167–178.
30. Vorherr H. Fibrocystic breast diseases: pathophysiology, pathomorphology, clinical picture, and management. *Am J Obstet Gynecol* 1986; 154:161–179.
31. Dupont WD, Page DL. Risk factors for breast cancer in women with proliferative breast disease. *N Engl J Med* 1985; 312:146–1
32. Lee K, Chan JKC, Gwi E. Tubular adenosis of the breast: a distinctive benign lesion mimicking invasive carcinoma. *Am J Surg Pathol* 1996; 20:46–54
33. Millis RR, Eusebi V. Microglandular adenosis of the breast. *Adv Anat Pathol* 1995; 2:10–18.
34. Eusebi V, Foschini MP, Betts CM et al. Microglandular adenosis, apocrine adenosis, and tubular carcinoma of the breast: an immunohistochemical comparison. *Am J Surg Pathol* 1993; 17:99–109.
35. Vina M, Wells CA. Clear cell metaplasia of the breast: a lesion showing eccrine differentiation. *Histopathology* 1989; 15:85–92.
36. Tavassoli FA, ed. Chapter 6. Ductal intraepithelial neoplasia. In: *Pathology of the Breast*, Second Edition. CT: Appleton & Lange, 1999:205–323.
37. Koerner FC. Epithelial proliferations of ductal type. *Semin Diagn Pathol* 2004;21:10–17
38. Pinder SE, Ellis IO. The diagnosis and management of pre-invasive breast disease: ductal carcinoma in situ (DCIS) and atypical ductal hyperplasia (ADH)--current definitions and classification. *Breast Cancer Res* 2003;5:254–257
39. Page DL, Dupont WD, Rogers LW et al. Atypical hyperplastic lesions of the female breast. A long-term follow-up study. *Cancer* 1985; 55:2698–2708.
40. Dupont WD, Page DL. Relative risk of breast cancer varies with time since diagnosis of atypical hyperplasia. *Hum Pathol* 1989; 20:723–725.
41. Tavassoli FA, ed. Chapter 5. Benign lesions. In: *Pathology of the Breast*, Second Edition. Stamford, CT: Appleton & Lange, 1999:115–204.
42. Kennedy M, Masterson AV, Kerin M et al. Pathology and clinical relevance of radial scars: a review. *J Clin Pathol* 2003; 56:721–724.

43. Patterson JA, Scott M, Anderson N et al. Radial scar, complex sclerosing lesion and risk of breast cancer. Analysis of 175 cases in Northern Ireland. *Eur J Surg Oncol* 2004; 30:1065–1068.
44. Fasih T, Jain M, Shrimankar J et al. All radial scars/complex sclerosing lesions seen on breast screening mammograms should be excised. *Eur J Surg Oncol* 2005; 31:1125–1128.
45. Oyama T, Koerner FC. Noninvasive papillary proliferations. *Semin Diagn Pathol* 2004; 21:32–41.
46. Pacilli M, Sebire NJ, Thambapillai E et al. Juvenile papillomatosis of the breast in a male infant with Noonan syndrome, café au lait spots, and family history of breast carcinoma. *Pediatr Blood Cancer* 2005;45:991–9
47. Haj M, Weiss M, Herskovits T. Diabetic sclerosing lymphocytic lobulitis of the breast. *J Diabetes Complications* 2004; 18:187–191.
48. Camuto PM, Zetrenne E, Ponn T. Diabetic mastopathy: a report of 5 cases and a review of the literature. *Arch Surg* 2000; 135:1190–1193.
49. Pruthi S, Reynolds C, Johnson RE et al. Tamoxifen in the management of pseudoangiomatous stromal hyperplasia. *Breast J* 2001; 7:434–439.
50. Mercado CL, Naidrich SA, Hamele-Bena D et al. Pseudoangiomatous stromal hyperplasia of the breast: sonographic features with histopathologic correlation. *Breast J* 2004; 10:427–432.
51. El-Wakeel H, Umpleby HC. Systematic review of fibroadenoma as a risk factor for breast cancer. *Breast* 2003; 12:302–307.
52. Caleffi M, Filho DD, Borghetti K et al. Cryoablation of benign breast tumors: evolution of technique and technology. *Breast* 2004; 13:397–407.
53. El-Wakeel H, Umpleby HC. Systematic review of fibroadenoma as a risk factor for breast cancer. *Breast* 2003; 12:302–307.
54. Shabtai M, Saavedra-Malinger P, Shabtai EL et al. Fibroadenoma of the breast: analysis of associated pathological entities--a different risk marker in different age groups for concurrent breast cancer. *Isr Med Assoc J* 2001; 3:813–817.
55. Donegan WL. Common benign conditions of the breast. In: Donegan WL, Spratt JS, eds. *Cancer of the Breast, Fifth Edition*. St. Louis, MO: Saunders, 2002:67–110.



56. Lanng C, Eriksen BO, Hoffmann J. Lipoma of the breast: a diagnostic dilemma. *Breast* 2004; 13:408–411.
57. Silverberg SG, Masood S. The breast. In: Silverberg SG, DeLellis RA, Frable WJ, eds. *Principles and Practice of Surgical Pathology and Cytopathology*, Third Edition. New York: Churchill-Livingstone, Inc., 1997:575–673.
58. Donegan WL. Common benign conditions of the breast. In: Donegan WL, Spratt JS, eds. *Cancer of the Breast*, Fifth Edition. St. Louis, MO: Saunders, 2002:67–110.
59. Montemarano AD, Sau P, James WD. Superficial papillary adenomatosis of the nipple: a case report and review of the literature. *J Am Acad Dermatol* 1995;33:871–875.
60. Ilvan S, Ustundag N, Calay Z et al. Benign granular-cell tumour of the breast. *Can J Surg* 2005; 48:155–156.
61. Khan SA, Apkarian AV. The characteristics of cyclical mastalgia: a prospective study using a modified McGill pain Questionnaire. *Breast Cancer Research & Treatment* 2002; 75(2):147-157.
62. Kessel B. Premenstrual syndrome. Advances in diagnosis and treatment. *Obstetrics & Gynecology Clinics of North America* 2000; 27(3):625-639.
63. Goodwin PJ, Neelam M, Boyd NF. Cyclical mastopathy: a critical review of therapy. *British Journal of Surgery* 1988; 75(9):837-844.
64. Goodwin PJ, Miller A, Del Giudice ME, Ritchie K. Breast health and associated premenstrual symptoms in women with severe cyclic mastopathy. *American Journal of Obstetrics & Gynecology* 1997; 176(5):998-1005.
65. Ader DN, Shriver CD. Cyclical mastalgia: prevalence and impact in an outpatient breast clinic sample. *Journal of the American College of Surgeons* 1997; 185(5):466-470.
66. Ader DN, South-Paul J, Adera T, Deuster PA. Cyclical mastalgia: prevalence and associated health and behavioural factors. *Journal of Psychosomatic Obstetrics and Gynecology* 2001; 22(2):71-76.
67. Berg JC, Visscher DW, Vierkant RA, Pankratz VS, Maloney SD, Lewis JT et al. Breast cancer risk in women with radical scars in benign breast biopsies. *Breast cancer research and treatment* 2008; 108(2):167-174.
68. Seltzer MH, Perloff LJ, Kelley RI, Fitts WT, Jr. The significance of age in patients with nipple discharge. *Surgery, Gynecology & Obstetrics* 1970; 131(3):519-522.

69. Kaur N et al. Clinico-pathological profile of benign breast disease in Indian women; Prospective study based on aberrations of normal development and involution classification. *World J Surgery* 2012 September.
70. Hatim KS, Laxmikant NS, Mulla T. Patters and prevalence of benign breast disease in western India. *Int J Res Med Sci* 2017; 5:684-8.
71. O'Brien PM, Abukhalil IE. Randomized controlled trial of the management of premenstrual mastalgia using luteal phase-only danazol. *American Journal of Obstetrics & Gynecology* 1999; 180(1):1-23.
72. Millet AV, Dirbas FM. Clinical management of breast pain. A review. *Obstetrical & Gynecological Survey* 2002; 57(7):451-461.
73. Pashby NL, Mansel RE, Hughes LE, Hanslip JI, Preece P. A clinical trial of evening primrose oil in mastalgia. *British Journal of Surgery* 1981; 68:801.
74. Preece PE, Hanslip JI, Gilbert L. Evening primrose oil (Efamol) for mastalgia. In: Horrobin DF, editor. *Clinical uses of essential fatty acid*. Montreal: Eden; 1982. P. 147-154.