

Case study

A Huge Liposarcoma: Case Study

UNDER PEER REVIEW

8

Abstract

9 A 53-year-old had complaints of vague abdominal pain for the past few months. The patient had
10 a history of diabetes mellitus, hypertension, and iron deficiency. The pain was aching, mild,
11 intermittent, non-radiating, and generalized. An ultrasound of the abdomen, CT scan and MRI
12 were recommended. After initial examination and reports, the patient was diagnosed with a
13 retroperitoneal tumor. The liposarcoma found was dedifferentiated, high grade, and
14 retroperitoneal. The tumor extended to the inked resection margin, and was large, with 24 cm
15 and 14 cm in greatest dimension measurements. The liposarcoma was lipomatous and solid,
16 with hot spots of mitosis. In terms of treatment, surgery was recommended to remove the
17 enlarged mass.

18 Two heterologous fragments, which were different in morphology, size, and color, were obtained
19 from the retroperitoneal area during surgery. The mass was a huge grade 3 liposarcoma with a
20 mitotic rate of > 20 mitoses per 10 high-power fields (HPF). The examination and diagnosis
21 included some special studies such as immunohistochemistry assay, which was positive for p16,
22 vimentin, and MDM2. A post-operative scan showed that there was no evidence of recurrence or
23 residual retroperitoneal tumour. Chemotherapy was initiated by the Oncology Department.

24

25 Keywords: Liposarcoma, retroperitoneal, lipomatous, mitosis

INTRODUCTION

Heterogenous solid tumors originating from mesenchymal cells are called sarcomas. They have various clinicopathologic subtypes, but they are mainly classified into two forms: primary bone sarcoma and soft tissue sarcoma.⁽¹⁾

A liposarcoma is a soft tissue sarcoma. Malignant tumors with highly differentiated adipocytes are known as liposarcomas. There are four types of liposarcomas:⁽²⁾

1. Dedifferentiated liposarcoma
2. Well differentiated liposarcoma
3. Pleomorphic liposarcoma
4. Myxoid/round cell liposarcoma

Liposarcomas, being the most common kind of soft tissue sarcomas, account for about 20% of all known cases. Among them, retroperitoneal account for 50%, while extremity soft tissue sarcomas are 25%.⁽³⁾

A liposarcoma is a rare heterogeneous tumor. Usually, it is painless and enlarging mass, but compression caused by the mass can cause pain or neuropathy. It occurs in fats and can be present in any part of body, but most commonly occur in limb muscles and the abdomen. It can occur at any stage of life, but older adults are more susceptible to the disease.⁽⁴⁾

Abdominal swelling, constipation, abdominal pain, feeling full sooner during meals, and blood in stools are common symptoms of abdominal liposarcoma. To diagnose, a percutaneous core biopsy, MRI, and CT chest scan are done. The surgical removal of the tumor mass is the most common type of treatment.

History and Initial Examination

The patient reported his pain to the endocrinology clinic. The 53-year-old had suffered from complaints of vague abdominal pain for the past few months. He had a history of diabetes mellitus, hypertension, and iron deficiency. The pain was aching, mild, intermittent, non-radiating, and generalized. An ultrasound of the abdomen, CT scan and MRI were recommended and the reports showed following results:

1	Ultrasound	Heterogeneous mass at splenorenal sulcus, 10.3 x 8.9 cm, no significant hypervascularity with colour doppler.
2	CT Scan	Presence of huge 30X15cms mass mainly containing heterogeneous soft tissue and a cystic component. Mass lesion in retroperitoneum left side, Mass was pushing the left kidney medially.
3	MRI	A huge fatty mass lesion in retroperitoneal side with oval heterogeneous (mixed cystic and soft tissue) components in the left upper quadrant, measuring about, 11.7 x 14.3 x 9.6cm with perifocal congestive features. The mass pushed the left kidney antero-medially. Superiorly, the mass was intimately related to the left hemidiaphragm (mainly posterolateral), superiorly with spleen, medially with the pancreatic tail, and anteriorly with the splenic flexure of colon. Another small mass lesion, measuring 1.8 x 1.5cm, is noted to be inferior to the previously-described lesion.
4	Exploratory laparotomy	Wide radical resection of retroperitoneal sarcoma with splenectomy

54 *Special studies*

55 The examination and diagnosis also included some special studies such as an
 56 immunohistochemistry assay. However, no cytogenetics and molecular pathology tests were
 57 performed.

58 **Table 3: Immunohistochemistry profile**

MDM2	Positive
Desmin	Negative
CD117	Negative
CD34	Negative
DOG1	Negative
CKAE/AE3	Negative
SMA	Negative
S100	Negative
p16	Positive
p53	Negative
Vimentin	Positive
Factor XIIIa	Negative

59

60

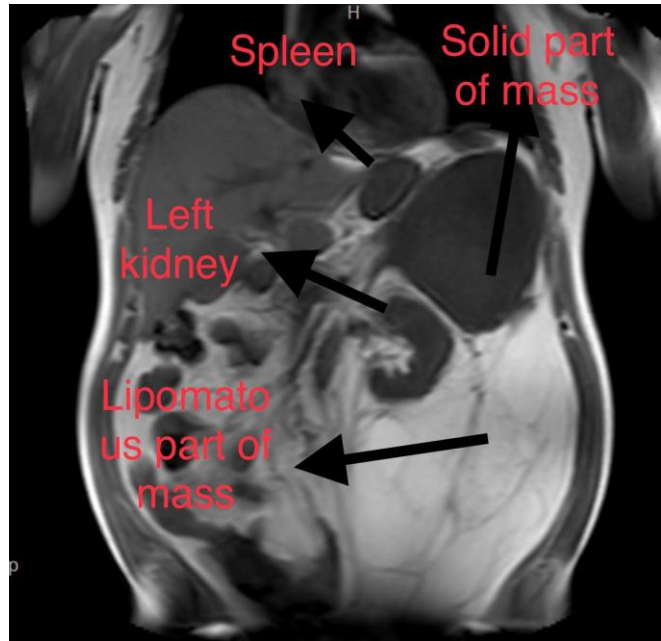
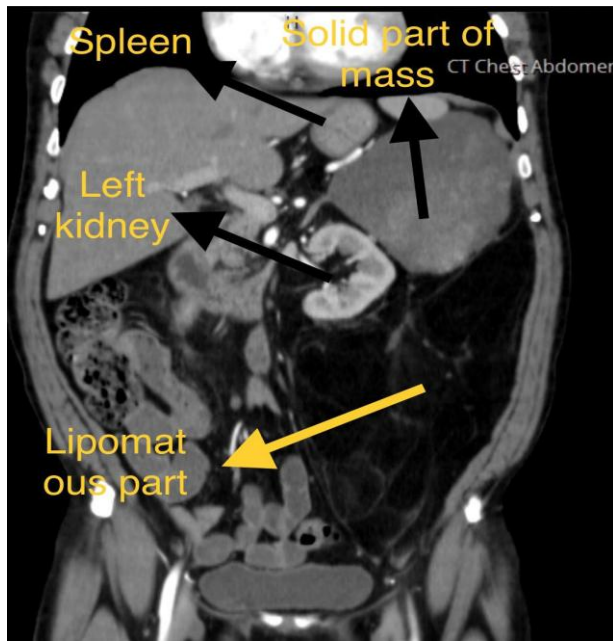
Patient was recommended CT scans of the chest, pelvic and abdomen. Here are the findings of the

Pelvic CT scan:

The CT scan of the chest found a huge 30X15cms mainly containing fat, with dimensions of 11x10cm. It was heterogeneous soft tissue with a cystic component mass lesion in the retroperitoneum left side. The heterogeneous part was enhanced after a contrast injection. The mass lesion was encasing, pushing, and displacing left kidney medially. However, kidneys had normal size and outline. The presence of a small 13x7mm heterogeneous fat mass pointed toward angiomyolipoma, but both adrenals were normal. The mass also displaced small intestinal loops medially. The size and outline of liver was normal. No focal lesions were present. No dilated intrahepatic passages were detected. CBD caliber was also normal. Normal spleen with no focal lesion was present. Pancreas had normal size, but the tail was compressed and displaced by the mass lesion. No pelvic collection and free air was detected. Urinary bladder was also normal.

Chest CT scan:

Two enlarged mediastinal lymph nodes just medial to right brachiocephalic vein were identified. Other detections included clear lungs with no patchy opacification or abnormality, normal hilars with no significant lymphadenopathy, and no pleural effusion. Chest wall, mediastinum and cardiac size was normal.



A. CT scan abdomen with IV contrast

B. MRI abdomen

Fig 1: Radiological finding in the MRI and CT scan

Diagnosis:

After initial examination and reports, the patient was diagnosed with a retroperitoneal tumor.

Surgery/gross pathology and histopathology:

A. Spleen, Splenectomy:

The splenic capsule was encased by the tumour, but the splenic parenchyma was not directly invaded.

B. Retroperitoneal Tumour, Resection (Fragmented):

The liposarcoma was found to be dedifferentiated, high grade, and retroperitoneal. The tumor extended to the inked resection margin. The tumor was large, with 24 cm and 14 cm in greatest dimension measurements.

Table 1: Gross Specimen description

Condition	Retroperitoneal sarcoma invading the spleen	Retroperitoneal tumor smaller lobe	Retroperitoneal tumor larger lobe
Source	Spleen	Retroperitoneal tumor	Retroperitoneal tumor
Weight	84 grams	830 grams	2146 grams
Measurement	10 x 6 x 3.5 cm	14 x 10 x 9 cm	24 x 20 x 10 cm
Appearance of cut surface	Unremarkable.	Pinkish yellow and lobulated.	Lobulated fat with no necrotic or hemorrhagic areas.

Microscopic examination of the specimens showed that:

- The liposarcoma was de-differentiated.

- It had a differentiated lipomatous components that had scattered lipoblasts and atypical stromal cells.

- The de-differentiated component was solid, with no further specific histological subtype and no heterologous components.

113 - A marked cytological atypia with hot spots of mitoses was present. However, there was no
114 necrosis.

115 ***Treatment:***

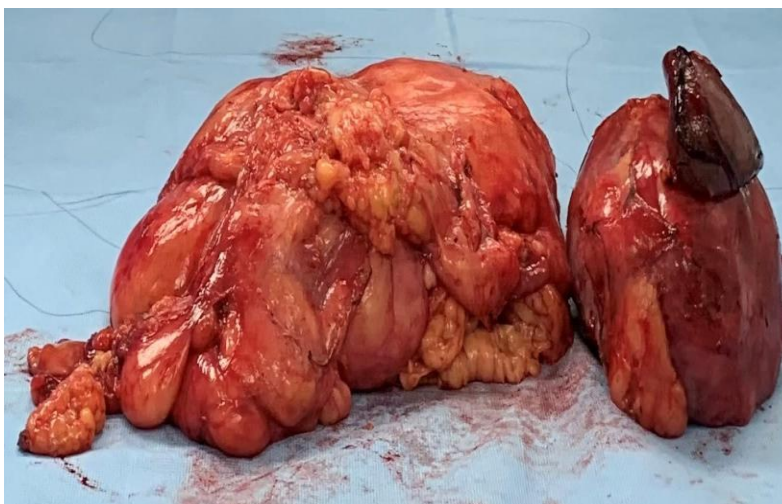116 Surgery was recommended to remove the enlarged mass as a treatment for liposarcoma.

117 **Table 2: Case Summary (Soft Tissue Resection):**

Pre-Resection Treatment	No known pre resection therapy
Procedure	Marginal resection (two fragments were received)
Tumor focality	Unifocal
Tumor site	Retroperitoneum
Tumor size	24cm was observed as the largest dimension of the larger fragment, whereas the smaller fragment had a largest dimension of 14cm
Histologic type	Dedifferentiated liposarcoma
Histologic grade	Grade 3 (French Federation of Cancer Centers Sarcoma Group)
Mitotic Rate	> 20 mitoses per 10 high-power fields (HPF)
Necrosis	Not identified
Treatment effect	Not reported
Lymphovascular invasion	Not identified
Regional lymph nodes	Not applicable
Distant Metastasis	Not applicable

Pathologic stage classification	pT4 pNX pMX
pT category	pT4 (Tumor more than 15cm in greatest dimension)
pN category	pN not assigned

118



119

Figure 1: Liposarcoma mass obtained after surgical excision.

120

121

122

123 **CT of the Neck, Chest Abdomen and Pelvis with Contrast: Five Months Post-Surgery**

124 **Neck scan:**

125 Although neck images were distorted by patient movement and swallowing, it showed normal
 126 appearance of bilateral submandibular glands with no mass lesions. 1.2x0.8 cm reactive nodes
 127 adjacent and lateral to the right submandibular gland were detected. Bilateral parotid gland and
 128 thyroid gland were normal in appearance. No significant enlarged nodes and no bone lesions in
 129 the cervical spine were detected.

130 **Chest scan:**

Lungs were clear. There were multiple bilateral tiny 2-3mm calcified granulomas and few centrimeters medistinal lymph nodes, most of which demonstrate fatty hilum were present. Axilla, thoracic wall, thoracic spine and mediastinum showed normal appearance.

Abdomen and pelvis:

Liver, gall bladder and pancreas were clear. Upper abdominal retroperitoneal sarcoma was completely resolved. Residual linear scarring in the region of previous surgery were present, but no soft tissue mass lesions were detected. The mid-descending colon appears closely approximated to left posterior abdominal wall - probably secondary to post-surgical scarring adherence. The appearance of adrenal glands, both kidneys, abdominal aorta, interior vena cava, urinary bladder outline, small and large bowel were normal. However, tiny simple bilateral cysts were present in kidneys, but there was no evidence of free fluid.

Results showed that there was no evidence of recurrence or residual retroperitoneal tumour.

PET scan:

Mildly FDG-avid peritoneal nodular stranding near the splenectomy bed were present that could be due to post-surgical inflammation. No evidence of FDG-avid malignancy.

DISCUSSION

Malignant tumors with adipocytic differentiation are liposarcomas. They are the second most common type of soft tissue sarcomas and account for about 15-20% of all soft tissue sarcomas.⁽⁴⁾ De-differentiated liposarcoma is the most common type among liposarcomas which represent an aggressive and high-grade disease. The retroperitoneum is the most common target for liposarcomas.⁽⁵⁾ They are associated with high metastatic recurrence. Disease-specific mortality is six-fold higher than well-differentiated liposarcomas.^{(6),(7)} This case presented an example of a huge liposarcoma detected in the retroperitoneum. It was also high grade and aggressive.

Both dedifferentiated and well-differentiated sarcomas are sensitive to chemotherapy, but present study was a case of dedifferentiated liposarcoma.⁽⁸⁾ Usually, de-differentiated liposarcoma occurs as an outgrowth of well-differentiated liposarcomas.⁽⁹⁾ The majority of de-differentiated liposarcomas are de novo lesions, whereas the rest develop from pre-existing well-differentiated liposarcoma as a late complication, with an average timeline of 7.7 years.⁽⁶⁾

Immunohistochemistry assays are usually positive for MDM2 biomarker in liposarcomas cases, as well as for CDK2 to a lesser extent. In the reported case, only MDM2 gave a positive result. As this condition is more common in patients with age between 50 and 80 years, and the reported case is a complaint of liposarcoma in a 53-year-old male. The liposarcoma was slow growing and painless, but compression with other organs caused abdominal pain. For high-grade liposarcomas, wide surgical resection is usually used. Surgical treatment is the most common treatment for de-differentiated sarcoma.⁽¹⁰⁾

In a different case, a de-differentiated liposarcoma was reported in a 75-year-old man with anorexia. This was also a giant retroperitoneal liposarcoma.⁽¹¹⁾ Most of the giant liposarcomas reported in literature belong to the de-differentiated group of liposarcomas.^{(12),(13)} This case also reported the presence of a huge liposarcoma.

CONCLUSION

The case found the presence of huge liposarcoma in a 53-year-old patient. Liposarcomas are usually large, more than 5 cm, but this case presented 24cm as the largest dimension. The sarcoma itself was painless but it was compressing other vital organs which caused pain. Compression was most evident in the spleen, which was removed during surgery.

- 176 1. Lee, A.T.J., Thway, K., Huang, P.H., and Jones, R.L. "Clinical and Molecular Spectrum
177 of Liposarcoma." *Journal of Clinical Oncology*. 2018;36(2):151-9.
- 178 2. Solar, A. (2021) "Liposarcoma". In: Paulos J., Poitout D.G. (eds) *Bone Tumors*. Springer,
179 London.
- 180 3. Mocellin S. (2021) Liposarcoma. In: Soft Tissue Tumors. Springer, Cham.
181 https://doi.org/10.1007/978-3-030-58710-9_155
- 182 4. Ducimetière, F., Lurkin, A., Ranchère-Vince, D., Decouvelaere, A., Péoc'h, M., Istier, L.,
183 et al. "Incidence of Sarcoma Histotypes and Molecular Subtypes in a Prospective
184 Epidemiological Study with Central Pathology Review and Molecular Testing". *PLOS*
185 *ONE*. 2011;6(8):e20294.
- 186 5. Bagaria, S. P., Gabriel, E., & Mann, G. N. "Multiply recurrent retroperitoneal
187 liposarcoma". *Journal of Surgical Oncology*. 2018;117(1): 62-68.
- 188 6. Henricks, W.H., Chu, Y.C., Goldblum, J.R., and Weiss, S.W. "Dedifferentiated
189 Liposarcoma". *The American Journal of Surgical Pathology*. 1997;21(3): 271-81.
- 190 7. Thway, K. "Well-differentiated liposarcoma and dedifferentiated liposarcoma: An
191 updated review". *Seminars in Diagnostic Pathology*. 2019;36(2): 112-21.
- 192 8. Jones, R.L., Fisher, C., Al-Muderis, O., and Judson, I.R. "Differential sensitivity of
193 liposarcoma subtypes to chemotherapy". *European Journal of Cancer*, 2005;41(18):
194 2853-2860.
- 195 9. Singer, S., Antonescu, C.R., Riedel, E., and Brennan, M.F. "Histologic subtype and
196 margin of resection predict pattern of recurrence and survival for retroperitoneal
197 liposarcoma". *Annals of Surgery*, 2003;238(3): 358.
- 198 10. Nascimento, A.G.. "Dedifferentiated liposarcoma". *Seminars in Diagnostic*
199 *Pathology* 2001;18(4): 263-266.
- 200 11. Herzberg, J., Niehaus, K., Holl-Ulrich, K., Honarpisheh, H., Guraya, S. Y., and Strate, T.
201 "Giant retroperitoneal liposarcoma: a case report and literature review". *Journal of*
202 *Taibah University Medical Sciences*, 2019;14(5): 466-471.

- 203 12. Eltweri A.M., Gravante G., Read-Jones S.L., Rai S., Bowrey D.J., Haynes I.G. A case of
204 recurrent mesocolon myxoid liposarcoma and review of the literature. Case Rep. Oncol.
205 Med. 2013;1–6. 2013.
- 206 13. Sharma M., Mannan R., Bhasin T.S., Manjari M., Punj R. Giant inflammatory variant of
207 well differentiated liposarcoma: a case report of a rare entity. J. Clin. Diagn. Res.
208 2013;7:1720–1721.

209
210
211
212
213
214
215
216
217 Funding: No funding sources
218 Conflict of interest: None declared
219 Ethical approval: Not required
220