

# **BRONCHOGENIC CYST: A RARE CASE REPORT**

## **ABSTRACT**

Bronchogenic cysts are rare congenital malformations which arise from abnormal budding of primitive tracheobronchial tube and can localize either in mediastinum or lung parenchyma. It may be called congenital if it is detected in early age group. Usually they are incidentally detected mediastinal masses. Bronchogenic cyst are asymptomatic in most adults. We present a case of 55 year old female complaining of chest pain, heaviness, dyspnea and cough since last one year.

## **KEY WORDS**

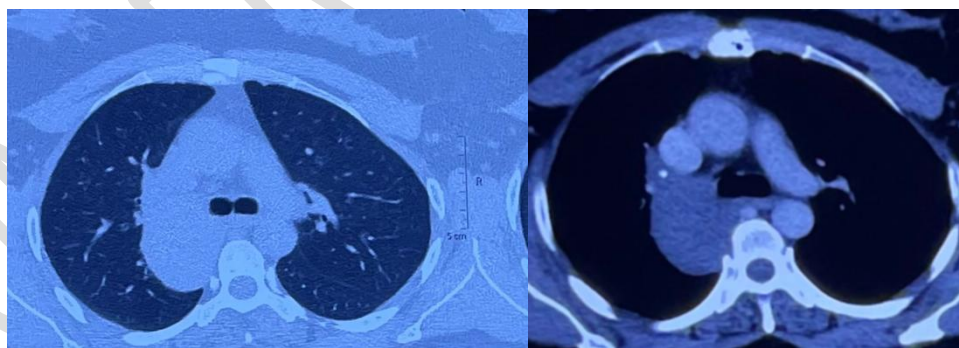
Bronchogenic cyst , Mediastinal , Tracheobronchial

## **INTRODUCTION**

Bronchogenic cysts are rare congenital lesions accounting for only 5-10% of paediatric mediastinal masses. [1]. "Bronchogenic cysts result from the abnormal or late budding of ventral lung bud or tracheobronchial tree during the process of development. Most bronchial branches form within 15 weeks of development of fetal life but they continue to divide and complete by eight years of life. Mediastinal bronchogenic cyst cannot clinically be detected usually until adult life" [2]. "Bronchogenic cysts can be either intrapulmonary or mediastinal .About 70% of parenchymal bronchogenic cyst produce some symptoms but 90% of mediastinal bronchogenic cyst are asymptomatic" [3].Bronchogenic cysts are incidental radiographic finding in adult most common location being mediastinum (65-90%) followed by lung parenchyma (15-20%) [4,5].Pulmonary bronchogenic cysts are usually in lower lobe often single [6] .The paratracheal or carinal types can produce symptoms due to compression of trachea and bronchi .Secondary infection can occur in mediastinal bronchogenic cyst. The cyst is lined by the ciliated ,secretory respiratory epithelium with cartilage ,smooth muscle ,fibrous tissue and mucous glands.

## CASE REPPORT

A 55 year old female presented with complaint of right side chest pain and heaviness ,dyspnea on exertion MMRC (Modified medical research council) grade 1 and cough since last one year .Patient was nonsmoker and there was no history of bio mass fuel exposure .Patient had no past history of Hypertension, Diabetes mellitus ,Tuberculosis. Patient was frequently treated by oral antibiotics since last years but was not relieved .Blood counts, liver function test, kidney function test, sputum culture, sputum acid fast bacilli, sputum cbnaat,blood culture, PT/INR, HIV, HBsAg, HCV were advised and done. All blood parameters were normal .Sputum for AFB ,CBNAAT and pyo c/s was negative. 2D Echo was normal with LVEF 55%.Patient CECT chest was done which revealed a large well defined non enhancing lesion seen on right side with broad base to the mediastinum seen in close relation to the right main stem bronchi ,the size of the lesion measured 48x42x56 mm and no haemorrhage or calcification was seen within the lesion rest of the b/l lung field appeared normal. Fibreoptic bronchoscopy was done which showed there was no endobronchial growth and opening of all lobes were patent. Bronchoalveolar lavage was negative for afb ,cbnaat ,pyogenic culture and fungal culture. CT guided aspiration showed content to be transparent fluid negative for pyogenic culture, afb ,cbnaat and malignant cell cytology It only revealed inflammatory changes. Surgical removal of bronchogenic cyst was planned by video assisted thoracoscopy and cyst was removed without any complication.



A.

B.

Fig 1. CECT showing a large well defined non enhancing lesion. (precontrast HU 28, post contrast HU 32).

Lesion is seen on the right side of mediastinum measuring 48\*42\*56(AP\*Tr\*CC) A.Parenchymal window, B. mediastinal window

## DISCUSSION

Bronchogenic cyst is a rare congenital malformation. It results from abnormal or late budding of ventral lung and tracheobronchial tree. Bronchogenic cysts in early childhood present with noisy breathing, cough, dysphagia, anorexia and a CT scan can confirm the diagnosis. Tracheobronchial compression and life threatening symptoms due to cyst enlargement are common in the pediatric population because of relative soft tracheobronchial tree. In adults most of the cyst are incidental radiographic findings and are asymptomatic. If the cyst gets infected, ruptures, bleeds or undergoes malignant transformation patient can develop serious symptoms[7]. Common symptoms associated with bronchogenic cyst are cough, dyspnea, chest pain and fever. Unusual presentation includes hemoptysis, pneumothorax and dysphagia. Superimposed cyst infection is usually the result of communication with the tracheobronchial tree. Intra-parenchymal bronchogenic cyst is more likely to have connection with the tracheobronchial tree than mediastinal cyst and is more prone to infectious complications. In one of the largest reported series of 86 patients, St Georges et al. found only one infected mediastinal cyst[8]. Khalil et al. suggested "surgical excision of cyst should be preferred because of the risk of future complications. Bronchogenic cyst can be excised as completely as possible as partial excision there are chances of relapse" [9]. Video-assisted thoracoscopy has replaced the conventional thoracotomy as surgical modality to remove bronchogenic cyst. Videoassisted thoracoscopy has excellent results with no significance recurrence rate [10]. Removal of bronchogenic cyst with mediastinoscopy has also been reported. Percutaneous or transbronchial aspirations of the content of the cyst has also been used to treat bronchogenic cyst for high risk surgical patient [11]. "In all symptomatic patients, according to Mawatari et al. the treatment should depend on the size and location of the cyst and their adherence to the surrounding structures" [12]. A small cyst, carinal in location and free from surrounding structures could be operated when diagnosed. Operation sometime become complicated as there may adhesions with surrounding structures so complete separation becomes impossible and excision is only done when complication such as fistula formation, bronchial ulceration, bleeding or infection occur.

## CONCLUSION

Bronchogenic cyst are rare mediastinal masses which may present with varied respiratory symptoms . Delay of treatment can lead to complications.

## Consent

As per international standard or university standard, Participants' written consent has been collected and preserved by the author(s).

## DISCLAIMER:

Authors have declared that no competing interests exist. The products used for this research are commonly and predominantly use products in our area of research and country. There is absolutely no conflict of interest between the authors and producers of the products because we do not intend to use these products as an avenue for any litigation but for the advancement of knowledge. Also, the research was not funded by the producing company rather it was funded by personal efforts of the authors.

## REFERENCES

1. Staatz G, Honnef D, Piroth W, Radkow T . Pediatric Imaging. George Thieme Verlag. (2007)
2. Schmidt FE, Drapanas T. Congenital cystic lesions of the bronchi and lungs. *Ann Thorac Surg* 1972 Dec;14(6):650-7
3. Mawatari T, Itoh T, Hachiro Y, Harada H, Kobayashi T, Saitoh T, Ohsawa H, Watanabe A ,Abe Tomio. Large bronchial cyst causing compression of the left atrium. *Ann Thorac Cardiovasc Surg* 2003 Aug;9(4):261-3.
4. J. Zylak, W. R. Eyler, D. L. Spizarny, and C. H. Stone. "Developmental lung anomalies in the adult: radiologic-pathologic correlation," in *Radiographics : A Review Publication of The Radiological Society of North America, Inc*, 2002, Spec No:S25-43.
5. Y.-C. Chang, Y.-L. Chang, S.-Y. Chen , T-C Wang , P-C Yang , H-M Liu , Y-C Lee . "Intrapulmonary bronchogenic cysts: Computed tomography, clinical and histopathologic correlations," *Journal of the Formosan Medical Association*, vol. 106, no. 1, pp. 8–15, 2007.
6. Mehta AC ,Ahmad M ,Golish JA, Buonocore E .Congenital anomalies of the lung in adult .*Clev Clin Q*.1983;2:454-63
7. M. E. Ribet, M.-C. Copin, and B. H. Gosselin . "Bronchogenic cysts of the lung," *The Annals of Thoracic Surgery*, vol. 61, no. 6, pp. 1636–1640, 1996

8. Kostopoulos , A. Efstathiou , A. Skordalaki , and I. Fessatidis . “Bronchogenic cyst infected by Salmonella enteritidis followed gastroenteritis,” European Journal of Cardio-Thoracic Surgery, vol. 21, no. 5, pp. 935–937, 2002.
9. Bogers AJ , Hazebrock FW, Molenaar J , E Bos . .Surgical treatment of congenital bronchopulmonary disease in children.Eur J Cardiothorac Surg.1993;7:117-20
10. .Weber T , Roth TC , Beshay M ,Herrmann P ,Stein R ,Schmid RA . Videoassisted thoracoscopic surgery of mediastinal bronchogenic cysts in adult:A single centre experience.Ann Thorac Surg 2004;78:987-91
11. Schwartz DB , Beals TF , Wimbish KJ, Hammersley JR ..Transbronchial fine needle aspiration of bronchogenic cyst.Chest.1995;88:573-5
12. Khalil A, Carette MF, Milleron B, Grivaux M, Bigot JM. Bronchogenic cyst presenting as mediastinal mass with pleural effusion. Eur Respir J 1995 Dec;8(12):2185-7.