

## **Case study**

### **Niemann Pick disease –Rare cause of chronic liver Disease-Case series**

#### **Abstract:**

Niemann pick disease refers to a group of autosomal recessive disorder lysosomal lipid storage disorders with a multisystem involvement with a wide variety of clinical manifestations. The pathogenesis of disease is yet to be defined clearly. Here, we report to you a series of two cases including that of a three-year old girl and a four-year old boy.

**Keywords:** Niemann-Pick Disease, hepatosplenomegaly, genetic counseling

#### **Introduction:**

Niemann pick disease (NPD) is the rare autosomal recessive disorder lysosomal lipid storage disorder with an incidence estimated at between 1:120,000 and 1: 150,000 live births. The disease is pan-ethnic and lack of clinical awareness and unavailability of readily available biochemical testing makes diagnosing the disease, a cumbersome task.<sup>1</sup> It is a highly heterogeneous multisystemic disease, as a result of excessive lipid accumulation in the liver, spleen, brain and bone marrow. The visceral, neurological and psychiatric manifestations may present alone, or in specific or non-specific combinations. The age of onset and disease course generally varies from person to person and the type of NPD affecting the patient.<sup>2</sup> This familial disease has a challenging and varied presentation, making it difficult to get diagnosed earlier on.<sup>1,3-5</sup> It is characterized by inherited deficiency of an enzyme, acid sphingomyelinase which leads to deposition of sphingomyelin and cholesterol within the lysosome of reticuloendothelial cells of various organs like liver, spleen, bone marrow, lymph node, brain, nerves and kidney.<sup>6-9</sup> It has been classified into 2 major forms It is classified into two major entities: Acid sphingomyelinase deficient Niemann-Pick Disease

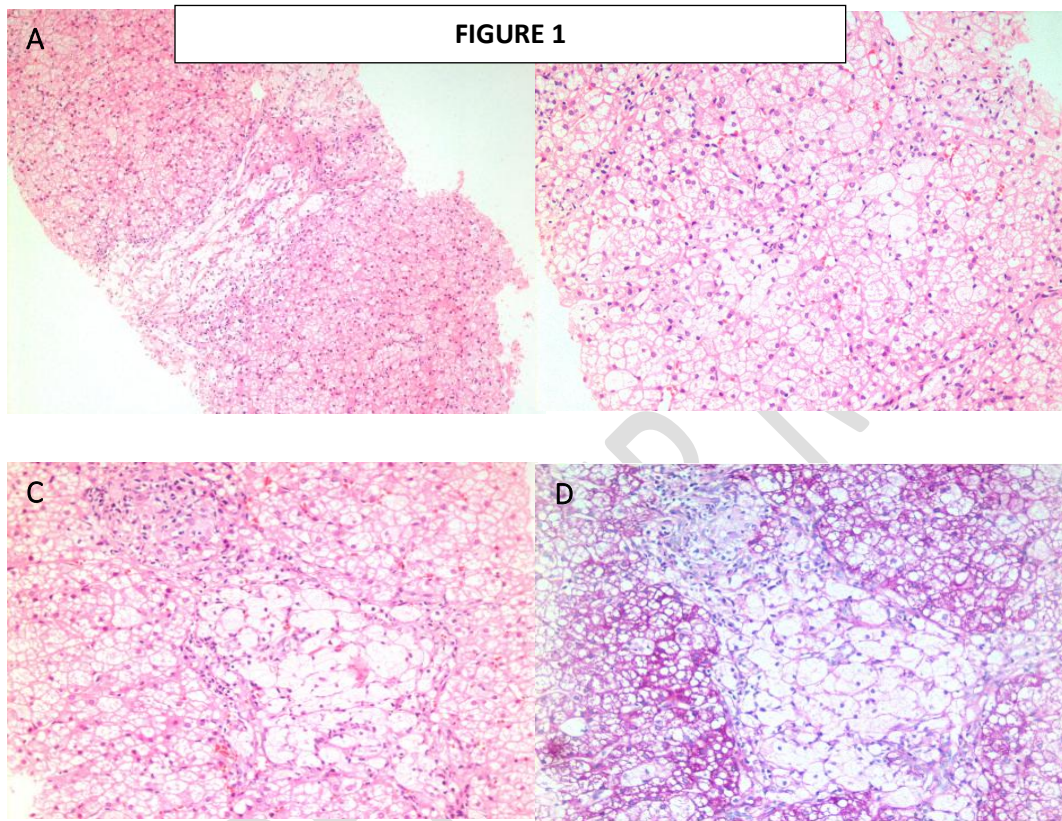
which result from mutations in SMPD1 gene and it includes type A and type B, Niemann-Pick Disease type C and type D result from mutations in NPC1 and NPC2 gene.<sup>6</sup>

Here we present to you a case series of children presenting with features of chronic liver disease and were later on diagnosed to have Neimann Pick disease on liver biopsy.

#### Case 1:

A Three-year old female child, born through normal vaginal delivery, presented at gastroenterology clinic with complaints of failure to thrive since birth associated with fever on and off. She has a history of absent left kidney which was diagnosed at birth and has history of recurrent admissions with urinary tract infections. She has a history of delayed developmental milestones with holding of neck at 8 months and social smile at the age of 1 year. On examination, the patient was pale while rest of the general physical examination was unremarkable. She was afebrile, vitally stable. On abdominal examination, liver was enlarged 6 cm below costal margin with firm consistency and was non tender with sharp borders. Spleen was also enlarged by 6cm and it was non tender. Complete blood count and peripheral blood smear examination done which was suggestive of mild hypochromic microcytic anemia with Hemoglobin of 10.8(g %), Total leukocyte count was within normal limit [ $8.5 \times 10^9/L$ ] and platelet count was normal [ $2.62 \times 10^9/L$ ]. Her liver function tests revealed raised transaminases (Total bilirubin-1.11mg/dl ,Direct Bilirubin-0.14mg/dl ,Alkaline Phosphatase-439U/L, Aspartate Transaminase-139 U/L, Alanine Transaminase-72 U/L, Gamma Glutamyl Transferase-42 U/L. Considering raised Liver function enzymes ,viral serology was performed which included HBsAg (hepatitis B Surface Antigen) and anti-Hepatitis C antibody ,both of which were negative .She also underwent workup for autoimmune etiology which revealed ANA 1:160 while AMA ,ASMA and anti LKM were all negative. IgG was also done which was normal. Serum ceruloplasmin and alpha 1 antitrypsin both were within normal limits. Ultrasound abdomen was done, which revealed hepatosplenomegaly. Liver elastography was performed, showing F3 fibrosis.

Subsequently, she then underwent liver parenchymal biopsy which revealed moderately expanded portal tracts with lymphocytic infiltrates and clusters of enlarged kupffer cells with foamy and vacuolated cytoplasm. The findings were suggestive of Neimann Pick disease (**Figure 1**).

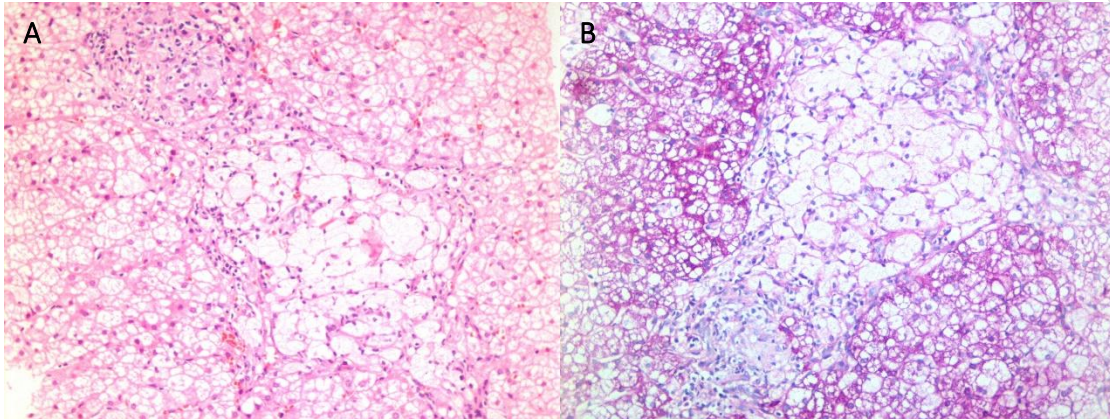


**Figure 1****A**-lower power scanner view of hepatic parenchyma **B**-Liver parenchyma show an effaced architecture reveal a few clusters and individual kupffer cells in the sinusoidal spaces of lobular parenchyma. These kupffer cells are compressing the sinusoidal spaces. **C**-Portal tracts are moderately expanded with lymphocytic infiltrate and clusters of enlarged kupffer cells with foamy and vacuolated cytoplasm. **D**- Portal tracts are moderately expanded with lymphocytic infiltrate and clusters of enlarged kupffer cells with foamy and vacuolated cytoplasm. These kupffer cells are negative on PAS stain.

Case 2:

4year old boy, who was born through normal vaginal delivery with no history of delayed mile stones. Initially presented at GI clinic with complaints of jaundice, Abdominal distension and failure to thrive for 3 months. He has history of recurrent hospital admissions due to pneumonia. He has no history of delayed milestones. On examination, he was pale, icteric ill looking while rest of the general physical examination was unremarkable. He was febrile with temperature of 100°F, pulse of 100bpm and Blood pressure of 90/60 mmHg. On abdominal examination, fluid thrill was positive. Chest examination revealed bilateral creptitations in basal area. Complete blood count and peripheral blood smear examination done which was suggestive of mild hypochromic microcytic anemia with Hemoglobin of 10.8(g %), Total leukocyte count was within normal limit [ $10.7 \times 10^9/L$ ] and platelet count was normal [ $460 \times 10^9/L$ ]. His liver function tests revealed raised transaminases with reversed ALT/AST ratio (Total bilirubin-2-15mg/dl, Direct Bilirubin-1.04 mg/dl, Alkaline Phosphatase-259 U/L, Aspartate Transaminase-63 U/L, Alanine Transaminase- U/L, Gamma Glutamyl Transpeptidase-86 U/L. Considering raised Liver function enzymes and increased bilirubin, viral serology was performed which included HBsAg (hepatitis B Surface Antigen) and anti-Hepatitis C antibody, both of which were negative. He also underwent workup for autoimmune etiology which was normal. IgG was also done which was normal. Serum ceruloplasmin and alpha 1 antitrypsin both were within normal limits. Ultrasound abdomen was done, which revealed hepatosplenomegaly. He underwent ascetic fluid analysis, which revealed spontaneous bacterial peritonitis (SBP) (ascetic fluid culture-Salmonella) and was treated with intravenous antibiotics(IV). After therapeutic ascetic fluid drainage, he underwent liver parenchymal biopsy which revealed minimally expanded portal tracts with lymphocytic infiltrates and clusters of enlarged kpuffer cells with foamy and vacuolated cytoplasm (**figure 2**). The findings were suggestive of Niemann Pick disease. During the same admission, he developed hospital acquired pneumonia and generalized **tono clonic** seizures and underwent mechanical intubation and was kept on ventilator support but couldn't revive.

**FIGURE 2**



**Figure 2A:** Portal tracts are moderately expanded with lymphocytic infiltrate and clusters of enlarged kupffer cells with foamy and vacuolated cytoplasm. **B:** Portal tracts are moderately expanded with lymphocytic infiltrate and clusters of enlarged kupffer cells with foamy and vacuolated cytoplasm. These kupffer cells are negative on PAS stain.

#### Discussion:

Accumulation of lipids in monocytes-macrophages of various organs like liver, spleen, bone marrow, lymph node, brain, nerves and kidney causes permanent damage to that organ. The group of inherited metabolic disorders termed as Lysosomal lipid storage disorder or lipidoses is characterized by complete absence or deficiency of enzyme which is needed to metabolise lipids. Niemann pick disease, tay sachs disease, fabry disease, farber disease etc. are examples of lipidosis.<sup>7</sup> Our topic of interest here is



Niemann-Pick Disease which is an autosomal recessive disorder and has been classified by Crocker 4 types-

**NEIMANN PICK DISEASE TYPE A (classic infantile)**

**NEIMANN PICK DISEASE TYPE B (visceral)**

**NEIMANN PICK DISEASE TYPE C (subacute/juvenile)**

**NEIMANN PICK DISEASE TYPE D (Nova/Scottian)**

The death in type A occurs in infancy. While in type B, the lifespan is comparatively longer but supplemental oxygen is required due to lung impairment.<sup>12</sup> In Type C and Type D, prognosis is again variable with some patients die in childhood while others are less affected may live up to adulthood. Our first case is a true presentation of Type A NPD while second one points towards type B.

There is 25 % chance that the child will have the disease if both of the parents are carriers and 50% chance that a child will be carrier. The diagnosis of NPD can be confirmed by measurement of sphingomyelinase enzyme in leukocytes and cultured skin fibroblasts and also by genetic testing for genetic mutation but the lack of widespread availability of the enzyme assay and genetic study have limited its application in clinical practice. Currently, NPD is mainly diagnosed by bone marrow and liver biopsy. In areas with high prevalence of consanguineous marriages, these autosomal recessive diseases are more prevalent. Pakistani marriages comprise of the higher rates of consanguinity accounting for approximately 65%, mostly occurring within the first cousins.<sup>10</sup> In both of our cases, diagnosis was done on the basis of liver parenchymal biopsy. DNA mapping of patient as well as the carrier parents gives the definite diagnosis. In both our cases, there was family history of consanguineous marriages.

No specific treatment options are available, only supportive treatment can be offered. Newer modalities like bone marrow transplantation, enzyme replacement therapy and gene

therapy are likely to be useful for NPD type B but late presentation with complications of chronic liver disease can halt the treatment options. So, genetic counselling and genetic testing is recommended for families who maybe carriers of Niemann Pick disease.

### **Conclusion:**

Neimann Pick disease is a fatal disease. Although no definitive treatment available till now, only supportive treatment is offered, early diagnosis and management of complications can improve life expectancy. Hence, the focus should be on Genetic counselling and testing of the family members of the patients.

### **Ethical Approval:**

As per international standard or university standard written ethical approval has been collected and preserved by the author(s).

### **Consent**

As per international standard or university standard, patients' written consent has been collected and preserved by the author(s).

### **References:**

- 1- Vanier MT. Niemann-Pick disease type C. Orphanet J Rare Dis 2010; 5: 16.
- 2- Crocker AC, Farber S: Niemann-Pick disease: a review of eighteen patients. Medicine (Baltimore) 1958, 37:1-95.

- 3- McKay Bounford K, Gissen P. Genetic and laboratory diagnostic approach in Niemann-Pick disease type C. *J Neurol* 2014; 261 Suppl 2: S569-S575.
- 4- Fan M, Sidhu R, Fujiwara H, Tortelli B, Zhang J, Davidson C, Walkley SU, Bagel JH, Vite C, Yanjanin NM, Porter FD, Schaffer JE, Ory DS. Identification of Niemann-Pick C1 disease biomarkers through sphingolipid profiling. *J Lipid Res* 2013; 54: 2800-2814.
- 5- Mengel E, Klünemann HH, Lourenço CM, Hendriksz CJ, Sedel F, Walterfang M, Kolb SA. Niemann-Pick disease type C symptomatology: an expert-based clinical description. *Orphanet J Rare Dis* 2013; 8: 166
- 6- Mane V, Joshi RT, Mane VP. Niemann pick disease-a case report. *J Evol Medic Dental Sci.* 2012;1(6):955-58.
- 7- Sutay NR, Choudhary D, Samariya P, Jha S, Gangul S. Niemann-pick disease type B-a case report. *JMSCR.* 2017;5(4):19732-6
- 8- Shubhankar M, Sunil KA, Bikash RP, Shantanu KM. Niemann pick disease type A in an Infant: a case report. *Sch Acad J Biosci.* 2014;2(10):728-30.
- 9- Bari MI, Haque MI, Siddiqui AB, Hossain MA, Alam T. Niemann Pick Disease: A Case Report. *TAJ: J Teachers Association.* 2011;15(1):32-4
- 10- Bhinder MA, Sadia H, Mahmood N, Qasim M Hussain Z, Rashid MM, et al. Consanguinity: A blessing or menace at population level? *Ann Hum Genet.* 2019;83(4)214-219