

# **Recent Advances of Magnetic Resonance Imaging in Evaluation of Recurrent Perianal Fistula**

## **Abstract**

**Background:** Evaluation of recurrent perianal fistulae can be challenging; knowledge of relevant pelvic anatomy and fistula classification remains crucial in the diagnosis of recurrent perianal fistula. Magnetic Resonance Imaging (MRI) has been shown to demonstrate accurately the anatomy of the perianal region. In addition to showing the anal–sphincter mechanism, MRI clearly showed the relationship of fistulae to the pelvic diaphragm and the ischiorectal fossae, especially for patients with complex and recurrent fistulae

**Objective:** The aim of this study is to discuss the usefulness of high-resolution magnetic resonance imaging with contrast and/or local gel or saline injection in evaluation of recurrent perianal fistula.

**Methods:** This prospective study included 30 symptomatic cases with suspected recurrent perianal fistula referred to Radiodiagnosis and Medical Imaging Department at Tanta University Hospitals through period extending from May 2017 to December 2019. MRI had been done for all selected patients. Perianal fistulas were classified according to the St James's University Hospital classification.

**Results:** Contrast enhanced MRI and local gel or saline injection showed 93.3% accuracy in detecting grade I, grade II and 100% accuracy with grade III, grade IV fistulae, ischioanal abscesses and fibrotic tracts.

**Conclusion:** Contrast enhanced MRI with local gel or saline injection in selective cases with external oozing opening is a very useful procedure for successful management of recurrent peri-anal fistula by correct assessment of the extent of fistulae, relationship to sphincter complex, detection of secondary tracts and abscesses, aiming to reduce complications and recurrences.

**Key words:** MRI, perianal fistula, recurrent, St James's University Hospital classification

## **Introduction:**

“Perianal fistulization is an inflammatory condition that affects the region around the anal canal, causing significant morbidity and often requiring repeated surgical treatments due to its high tendency to recur” <sup>(1)</sup>.

“It is not uncommon disease with incidence ranges from approximately 1 to 2 per 10,000 individuals with an approximate 2:1 male to female predominance, most patients present with discharge (65%) and local pain, some may be asymptomatic” <sup>(1)</sup>.

“Perianal fistula is a tract lined by infected granulation tissue that connects anal canal or rectum to the skin around anus. Its wall is made of inflammatory granulation as well as fibrous tissue” <sup>(2)</sup>.

“Many anal fistulae are suspected to arise from infected anal glands that open into the anal crypts at the dentate line, a theory known as the cryptoglandular hypothesis. Around 35% of patients develop recurrent disease after initial presentation for cryptoglandular perianal abscess” <sup>(3)</sup>.

“Recurrence of perianal fistula is usually due to infection that has escaped surgical detection, persistent infection and associated inflammatory disease of the rectum and colon, pelvic malignancy and radiation therapy” <sup>(4)</sup>.

“Role of imaging is to define the course of the tract between these openings so that the appropriate surgical option can be used. Surgical treatment of fistula-in-ano is notorious for high recurrence rates. The successful surgical management of fistula-in-ano depends upon accurate preoperative assessment of the course of the primary fistulous tract, the presence and site of any secondary extensions or abscesses” <sup>(2)</sup>.

“In the past, various imaging modalities including fistulography, anal endosonography and computed tomography (CT) have been used in assessing perianal fistula.

Fistulography is unreliable and difficult to interpret as the sphincter complex is not directly visualized. Anal endosonography too has proved inferior to expert clinical assessment as infection may not be distinguished from fibrosis and its insufficient depth of penetration which may result in failure to identify secondary ramifications. CT performed with rectally and intravenously administered contrast media, also showed some early promise. However, similar attenuation values for the sphincters, levator ani, fibrotic fistulous tracks, and active fistulae make characterization of these structures difficult on CT. Those modalities could not provide all the information that were required, and there were recurrences”<sup>(1)</sup>.

“Now, preoperative contrast enhanced magnetic resonance imaging (MRI), can help identify infected tracts and abscesses that would otherwise have been missed. Preoperative MRI findings have been shown to influence subsequent surgery and markedly diminish the chance of recurrent disease as a result. Because of this, preoperative imaging is likely to become increasingly routine in the future, especially in patients with recurrent disease”<sup>(1)</sup>.

The advantage of MRI with IV contrast and local injection is the high soft tissue contrast resolution, multiplanar display of pelvic anatomy, assessment of the anatomic relationship between the fistula and the anal sphincter complex and identify secondary branches, horseshoe tracts and abscesses, which are the primary source of recurrence<sup>(5)</sup>.

“MRI helped to limit the recurrence and incontinence after surgery as it helps to avoid unnecessary wide exploratory dissection through the sphincter. While direct non-imaging guided dissection may enforce the surgeon to do generous trans-sphincteric or supralelevator dissection for detailed exploration, which is incriminated for postoperative incontinence”<sup>(6)</sup>.

The purpose of this study is to discuss the usefulness of high-resolution magnetic resonance imaging with contrast and/or local gel or saline injection in evaluation of recurrent perianal fistula.

## **Patients and Methods:**

This prospective observational study included thirty cases from both sex with suspected recurrent perianal fistula within one year after surgery referred to Radiodiagnosis and Medical Imaging Department at Tanta University Hospitals through period extending from May 2017 to December 2019.

The exclusion criteria were: patients with electrically, magnetically or mechanically activated implant (e.g., cardiac pacemaker, cochlear implant, neurostimulator, insulin pump bio-stimulator), patients with intracranial aneurism clips (unless made of titanium) and patients with history of allergy to MRI contrast media.

All patients in the study were subjected to:

- 1. Complete history taking including:** personal data, patient symptoms, important points in the patient's history that may suggest a complex fistula include the following (Inflammatory bowel disease, Diverticulitis, Previous radiation therapy for prostate or rectal cancer, Tuberculosis, steroid therapy, HIV infection). History of chronic diseases including hypertension, diabetes mellitus and cardiac diseases.
- 2. General examination:** including vital signs, assessment of general condition of the patient and weight.
- 3. Physical examination:** All patients were examined in Tanta Surgery Department, the examiner observes the entire perineum, looking for an external opening that appears as an open sinus or elevation of granulation tissue.
  - Spontaneous discharge of pus or blood via the external opening may be apparent or expressible on digital rectal examination.
  - Digital rectal examination (DRE) may reveal a fibrous tract or cord beneath the skin. It also helps to delineate any further acute inflammation that is not yet drained.

- Lateral or posterior induration suggests deep post anal or ischiorectal extension.

The examiner determines the relationship between the anorectal ring and the position of the tract. Anoscopy is usually required to identify the internal opening.

Proctoscopy is also indicated in the presence of rectal disease (e.g., Crohn disease or other associated conditions).

4. **Laboratory investigations:** renal function test.

5. **Radiological imaging:**

**MRI has been done for all selected patients.**

Patients should be fasting for six hours at least to avoid vomiting which may be induced by contrast medium. No bowel preparation needed. Examination was done using 1.5 Tesla system (Signa, GE medical system, Milwaukee, WI, USA). The examination was done after explanation of the procedure to the patient & ensuring there is no contraindication to the study. All patients were examined in the supine position. Marker was put at the site of complaint (external opening, inflamed area) for better assessment while patient on left lateral position. Gel\saline was locally injected on 17 cases with external discharging opening while patient on left lateral position. IV Gadolinium contrast was given to all cases.

**MRI sequences:**

- “On the sagittal images, axial cuts of the T1-weighted fast spin echo with fat suppression images and T2-weighted fast spin echo with fat suppression images were planed parallel to the pelvic diaphragm.
- Then on the same sagittal plane, coronal cuts were planed parallel to the anal canal tilted forward from the vertical by approximately 45, T1-weighted fast spin echo with fat suppression images and T2-weighted fast spin echo with fat suppression images.

- After obtaining the axial and coronal images, contrast material (Gd DPTA) (Magnevist) was injected IV with a dose of (0.1-0.2) mmol/kg.
- Then the axial and coronal T1-weighted fast spin echo with fat suppression images was obtained. The T1-weighted fast spin echo with fat suppression (TR/ TE 600/15) was obtained with Echo Train Length 3, field of view 300 mm, slice thickness 5 mm and matrix (256 x 512).
- The T2-weighted fast spin echo with fat suppression (TR/ TE 2500/150) was obtained with Echo Train Length 10, field of view 300 mm, slice thickness 5 mm and matrix (256 x 512).
- Location of internal opening was determined in axial images with respect to the clock face with 12 o'clock being directed anterior.
- The objective in performing and interpreting MR images was identification of the primary track and its orientation with reference to the anal clock, its course, secondary branches, and relation with respect to the anal sphincter complex, abscesses, in an attempt to grade them based on the classification described.

Perianal fistulas are classified according to the St James's University Hospital classification into the following"<sup>(71)</sup>:

Grade 1: Simple linear inter-sphincteric fistula.

Grade 2: Intersphincteric fistula with abscess or secondary track.

Grade 3: Trans-sphincteric fistula.

Grade 4: Trans-sphincteric fistula with abscess or secondary track.

Grade 5: Supralelevator and Translevator .

Our results were confirmed and correlated with surgical findings and clinical assessment.

### Statistical analysis:

We determined the sensitivity (how accurate the test is in positive cases), specificity (how accurate the test is in negative cases), overall accuracy of the test, positive predictive value (how accurate the test is when it gives a positive result) and negative predictive value (how accurate the test is when it gives a negative result). The proportion of surgically confirmed perianal fistula was defined as true positive and the proportion of surgically confirmed absence of perianal fistula was defined as true negative.

### Results

This prospective study included 30 symptomatic cases with suspected recurrent perianal fistula within one year after surgery referred to Radiodiagnosis and Medical Imaging Department at Tanta University Hospitals. 27 (90%) cases were males and 3 (10%) cases were females with male to female ratio of 9:1. Their ages ranged from 23 - 63 years with a mean age of  $37.67 \pm 10.02$  years, the most common age group 30 - < 40 years included 15 patients representing 50%, the above findings were listed in (table 1)

**Table (1): Distribution of the studied cases according to age (years)**

<b>Age (years)</b>	<b>Study participants (n =30)</b>
<b>20 – &lt; 30</b>	<b>6 (20%)</b>
<b>30 – &lt; 40</b>	<b>15 (50%)</b>
<b>40 – &lt; 50</b>	<b>5 (16.6%)</b>
<b>50 – &lt; 60</b>	<b>2 (6.7%)</b>
<b>≥ 60</b>	<b>2 (6.7%)</b>
<b>Min. – Max.</b>	<b>23.0 – 63.0</b>
<b>Mean ± SD.</b>	<b>37.67 ± 10.02</b>
<b>Median (IQR)</b>	<b>36 (30- 43)</b>

n: number, %: percentage, SD: standard deviation

Nine (30%) cases had a simple linear active intersphincteric fistula sparing external anal sphincter (grade I); 3 (33.3%) of them were seen at left side and 6 (66.7%) of them were

seen at right side, length of fistulae ranged from 2 - 3.5 cm (4 cases 2-2.9 cm and 5 cases 3-3.5cm).

Four (13.3%) cases had intersphincteric fistula with abscess and/or secondary track (grade II); 2 were seen at right side and 2 were at left side. 2 cases had intersphincteric fistula with abscesses, the length of fistulae ranged 2.5-3 cm and the measurements of the abscesses were about (3x2x1 cm and 3x1x1 cm in maximum diameters); while other 2 cases had intersphincteric fistula with secondary branches, the length of the fistulae ranged between 2-2.5 cm with secondary branches measured 1 cm and 2 cm.

Six (20%) cases had trans sphincteric fistula (grade III); 3 were seen at right side and 3 at left side, their lengths ranged 3-3.5 cm. 4 (13.3%) cases had trans sphincteric fistula with abscess and or secondary branches (grade IV), all were seen at left side. 2 of them had trans sphincteric fistula with abscess and secondary track, length fistulae ranged 3-3.5 cm, the abscesses measured (6.7x 3.2x 1.3 cm and 4x 3x 2 cm in maximum diameters), secondary tracks were about (2 cm and 1.5 cm), the other 2 cases had transphincteric fistula with abscess without secondary branches their lengths measured 3-3.5 cm and the abscess measured (3x 2 x 1cm and 2x1x1 cm in maximum diameters).

Two (6.7%) cases had left ischeoanal abscess with no evidence of active fistulae tracks, the abscesses measured about (3x2x2 cm and 2x2x1 cm). 5 (16.7%) cases had intersphincteric healed fibrotic tracks; 3 were seen at right side and 2 at left side, their lengths ranged 2-3 cm. MRI findings in the studied cases (30 cases) were listed in table 2.

**Table (2): MRI findings among the studied cases.**

MRI findings		Studied group (n=30)	
		n (%)	
Grade I		9 (30%)	
Grade II	abscess and secondary branches	0	4 (13.3%)
	abscess	2 (6.67%)	
	Secondary branches	2 (6.67%)	



Grade III		6 (20%)	
Grade IV	Abscess and secondary branches	2 (6.67%)	4 (13.3%)
	abscess	2 (6.67%)	
	Secondary branches	0	
Ischeoanal abscess		2 (6.7%)	
Fibrotic tract		5 (16.7%)	

Length of fistula and size of abscesses are important to surgeons. Length of the fistulae measured 2 -< 2.5 cm in 2 (8.7%) cases (one grade I and one grade II), 2.5 - < 3 cm in 5 (21.7%) cases (3 grade II and 2 grade II), 3 - 3.5 cm in 16 (69.6%) cases (5 grade I, one grade II, 6 grade III and 4 grade IV). Fibrotic tract detected in 5 cases; its length ranged from 2 -< 2.5 cm in 2 (40%) cases, 2.5 -< 3 cm length in one case and 3- 3.5 cm in 2 (40%) cases. These findings were listed in table (3).

Eight (26.67%) cases had perianal abscesses, 2 (6.7%) cases had ischioanal abscesses without fistula measured 2x2x1 cm and 3x 2 x2 cm, 2 (6.7%) cases had ischioanal abscesses with inter-sphincteric fistula measured 3x1x1cm and 3x2x1 cm in maximum diameters. Four (13.3%) cases had ischioanal abscesses with trans sphincteric fistula; 2 of them associated with secondary branches measured about (6.7x 3.2x 1.3 cm and 4x 3x 2 cm in maximum diameters) and the other 2 cases had no secondary branches measured about (3x 2 x 1 and 2x1x1 cm in maximum diameters) table (3).

**Table (3):** Length and size of fistulae and length of fibrotic tract in the studied cases.

	<b>n (%)</b>	<b>Length</b>
<b>Length of fistula (n=23)</b>	<b>2 (8.7%)</b>	<b>2- &lt;2.5 cm</b>
	<b>5 (21.7%)</b>	<b>2.5- &lt;3cm</b>
	<b>16 (69.6%)</b>	<b>3-3.5 cm</b>

<b>Length of fibrotic tract (n=5)</b>	<b>2 (40%)</b>		<b>2- &lt;2.5 cm</b>
	<b>1 (20%)</b>		<b>2.5- &lt;3cm</b>
	<b>2 (40%)</b>		<b>3- 3.5 cm</b>
	<b>n (%)</b>		<b>measurements</b>
<b>Abscess with no fistula</b>	<b>2 (6.7%)</b>		<b>2x2x1cm</b> <b>3x2x2 cm</b>
<b>Intersphincteric with abscess grade II</b>	<b>2 (6.7%)</b>		<b>3x1x1 cm</b> <b>3x2x1 cm</b>
<b>Transsphincteric with abscess</b>	<b>2</b> <b>(6.7%)</b>	<b>4</b> <b>(13.3%)</b>	<b>3x 2 x 1cm</b> <b>2x1x1 cm</b>
<b>Trans sphincteric with abscess and secondary branches</b>	<b>2</b> <b>(6.7%)</b>		<b>6.7x 3.2x 1.3cm</b> <b>4x 3x 2 cm</b>

MRI identify mucosal opening in 23 (76.67) patients that were confirmed by surgical exploration with a true positive rate (TPR) (100%), the detected internal openings were located at a mean distance to the anal verge of  $2.2 \pm 0.2$  cm.

By surgical exploration, 11 cases were diagnosed as simple inter-sphincteric fistula (**grade I**), MRI correctly identify 9 cases with simple inter-sphincteric fistula (**grade I**) and failed to diagnose two cases that misdiagnosed as grade II intersphincteric fistula with secondary tracks with sensitivity 81.8%, specificity 100%, accuracy 93.3%, PPV 81.8% and NPV 90.5%.

MRI identify 4 cases with grade II intersphincteric fistula; two of them with abscess confirmed by surgical exploration and the other 2 cases with secondary tracks not identified by surgical exploration with sensitivity 100%, specificity 92.9%, accuracy of 93.3%, PPV 100% and NPV 100%.

MRI was able to correctly identify 6 out of 6 cases with simple trans-sphincteric fistula (**grade III**), 4 out of 4 cases with transsphincteric fistula with abscess and or

secondary branches (**grade IV**), 2 out of 2 cases with **ischioanal abscess** without active fistula track compared to surgical finding with sensitivity 100%, specificity 100%, accuracy 100%, PPV 100% and NPV 100%.

MRI was able to correctly identify 5 out of 5 patients with healed fibrotic track when compared to clinical assessment and follow up with sensitivity 100%, specificity 100%, accuracy 100%, PPV 100% and NPV 100%.

Sensitivity, specificity, accuracy, PPV and NPV of MRI in detection of recurrent fistula or healed fibrotic tract in comparison to surgical finding and clinical assessment were listed in

**Table (4):** Validity, Sensitivity, specificity, accuracy, PPV and NPV of MRI in detection of recurrent fistula or healed fibrotic tract in comparison to surgical finding and clinical assessment as Gold standard.

<b>Statistic</b>	<b>Grade 1</b>	<b>Grade II</b>	<b>Grade III</b>	<b>Grade IV</b>	<b>Ischeoanal abscess</b>	<b>Fibrotic tract</b>
------------------	----------------	-----------------	------------------	-----------------	---------------------------	-----------------------

<b>MRI finding</b>	9	4	6	4	2	5
<b>Accurate</b>	9	2	6	4	2	5
<b>Inaccurate</b>	0	2	0	0	0	0
<b>Sensitivity</b>	81.8%	100%	100%	100%	100%	100%
<b>Specificity</b>	100%	92.9%	100%	100%	100%	100%
<b>Positive Predictive Value (PPV)</b>	81.8%	100%	100%	100%	100%	100%
<b>Negative Predictive Value (NPV)</b>	90.5%	100%	100%	100%	100%	100%
<b>Accuracy</b>	93.3%	93.3%	100%	100%	100%	100%

## **Illustrative cases:**

### **Case 1:**

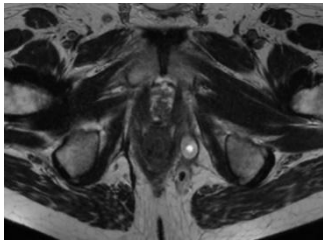
A 52-year-old male patient presented with discharging perianal opening and pain. Patient had history of operated perianal fistulous tract since 7 months.

### **Findings**

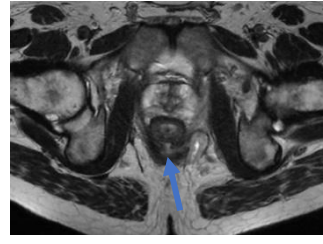
A perianal linear fistulous tract is seen opening externally between 6 and 7 o'clock, the track is seen deviated to left side reaching the left ischioanal fossa to end in a cavity posterolateral to the anal canal (yellow arrow), a secondary branch is also seen cross midline to right side (green arrow). The fistulous track pass through the external anal sphincter, intersphincteric space and internal anal sphincter to open at the anal canal at about 6 o'clock (blue arrow). The fistulous tract, cavity and 2ry tract are seen eliciting low T1, high signal in T2 and STIR WIs, with a hypointense margin surrounding the cavity and showed marginal enhancement after IV contrast injection (grey arrows).

### **Diagnosis:**

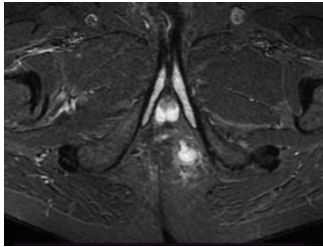
- Recurrent trans-sphincteric perianal fistula with secondary branch and abscess (grade IV).



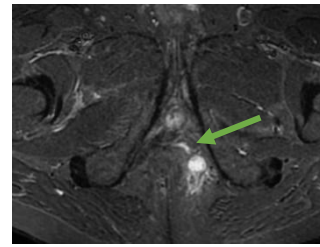
(A)



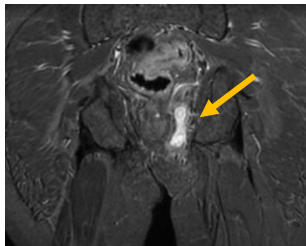
(B)



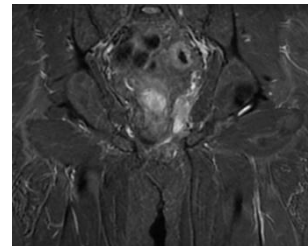
(C)



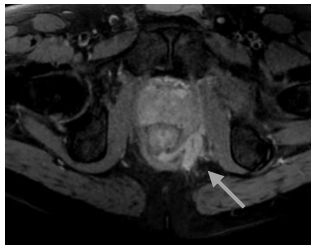
(D)



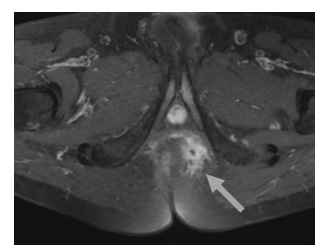
(E)



(F)



(G)



(H)

**Figure 1: A, B (Axial T2) C, D (Axial STIR) E, F (Coronal STIR), G&H (post contrast Axial T1 fat sat)**

## **Case 2:**

A 28-year-old male patient presented with perianal pain. Patient had history of operated perianal fistulous tract 11 months ago.

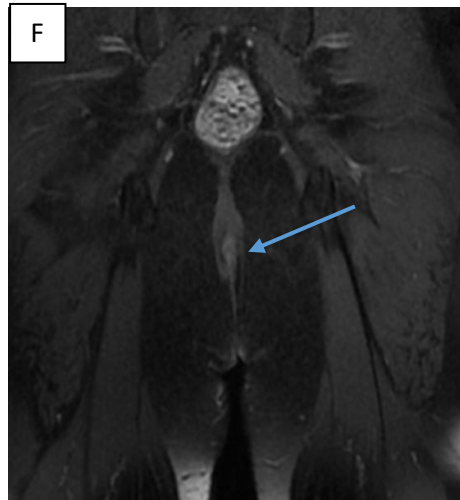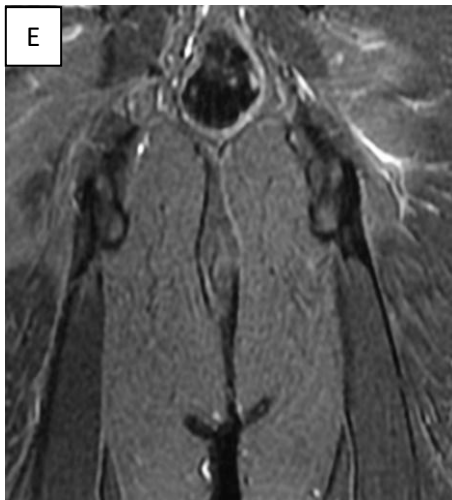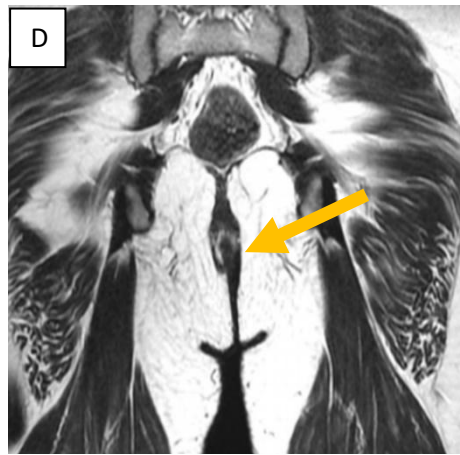
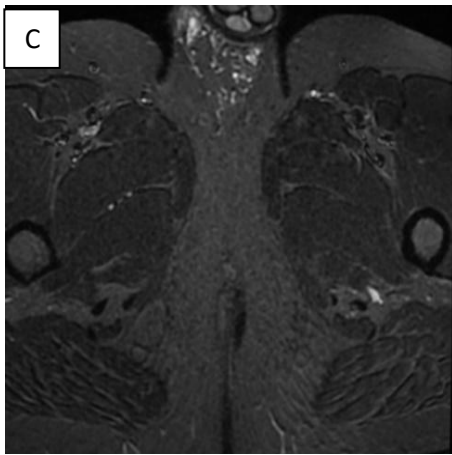
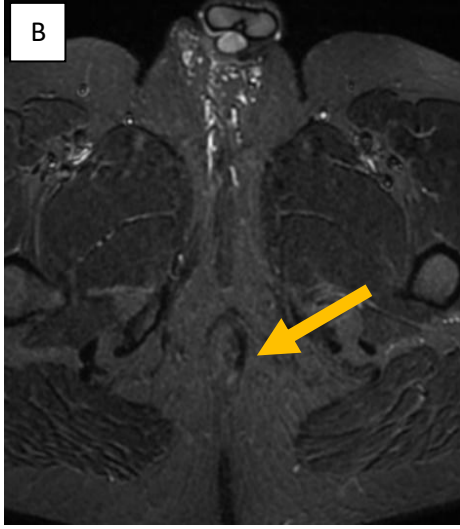
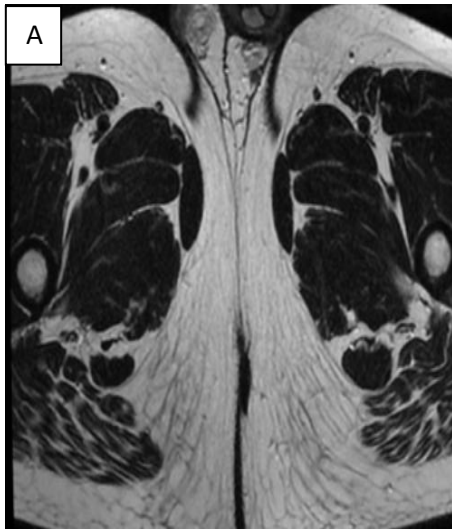
### **Findings**

**A (Axial T2) B, C (Axial STIR), D (Coronal T2), E (Coronal STIR) & F (post contrast coronal T1 fat sat) revealed:**

A left perianal linear thin fibrosed tract of low signal intensity in all pulse sequences (yellow arrows) seen inter sphincteric in location with no fluid signal inside. The tract showed no enhancement after IV contrast injection (blue arrow). No evidence of active fistulous tracking, branching or abscess formation.

### **Diagnosis:**

- A left sided fibrosed fistulous tract.



**Figure 2: A (Axial T2) B, C (Axial STIR), D (Coronal T2), E (Coronal STIR) & F (post contrast coronal T1 fat sat)**



### **Case 3:**

A 39-year-old male patient presented with perianal pain. Patient had history of operated perianal fistulous tract since 10 months.

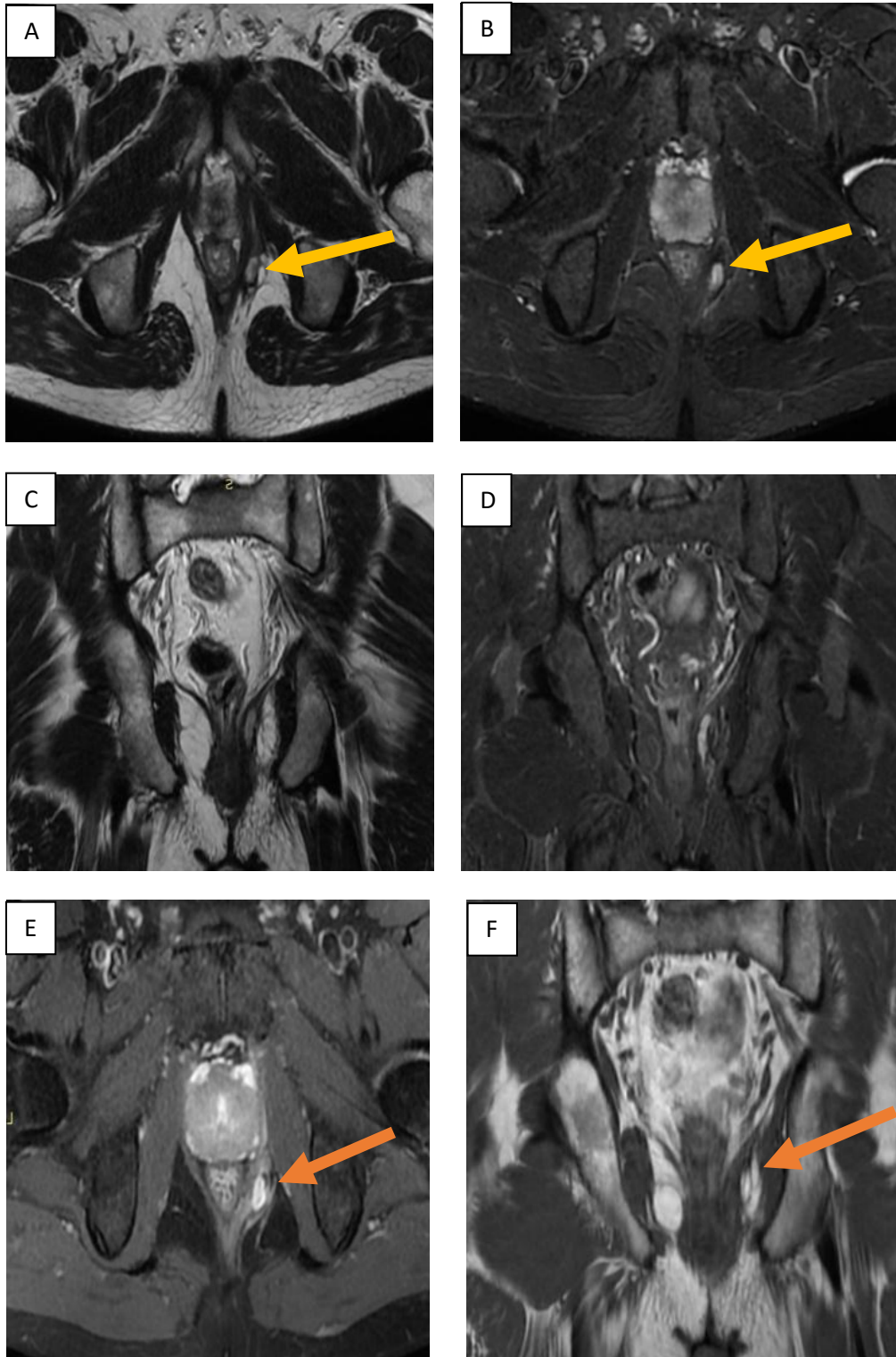
#### **Findings:**

**A (Axial T2), B (Axial STIR), C (Coronal T2), D (Coronal STIR), E (post contrast Axial T1 fat sat) & F (coronal T1 post contrast) revealed:**

A left side oblong shaped collection is seen at the left ischioanal fossa lateral to the external anal sphincter (yellow arrows) measures about 3x2 cm in maximum diameters, with no evidence of connection with the anal canal, no fistulous tracks seen. The collection elicits low T1, high T2 and STIR signal intensities with mild post contrast enhancement (orange arrows).

#### **Diagnosis:**

- Left ischioanal abscess.



**Figure 3: A (Axial T2), B (Axial STIR), C (Coronal T2), D (Coronal STIR), E (post contrast Axial T1 fat sat) & F (coronal T1 post contrast)**

## **CASE 4:**

A 38-year-old male patient presented with discharging perianal opening. Patient had history of operated perianal fistulous track since 9 months.

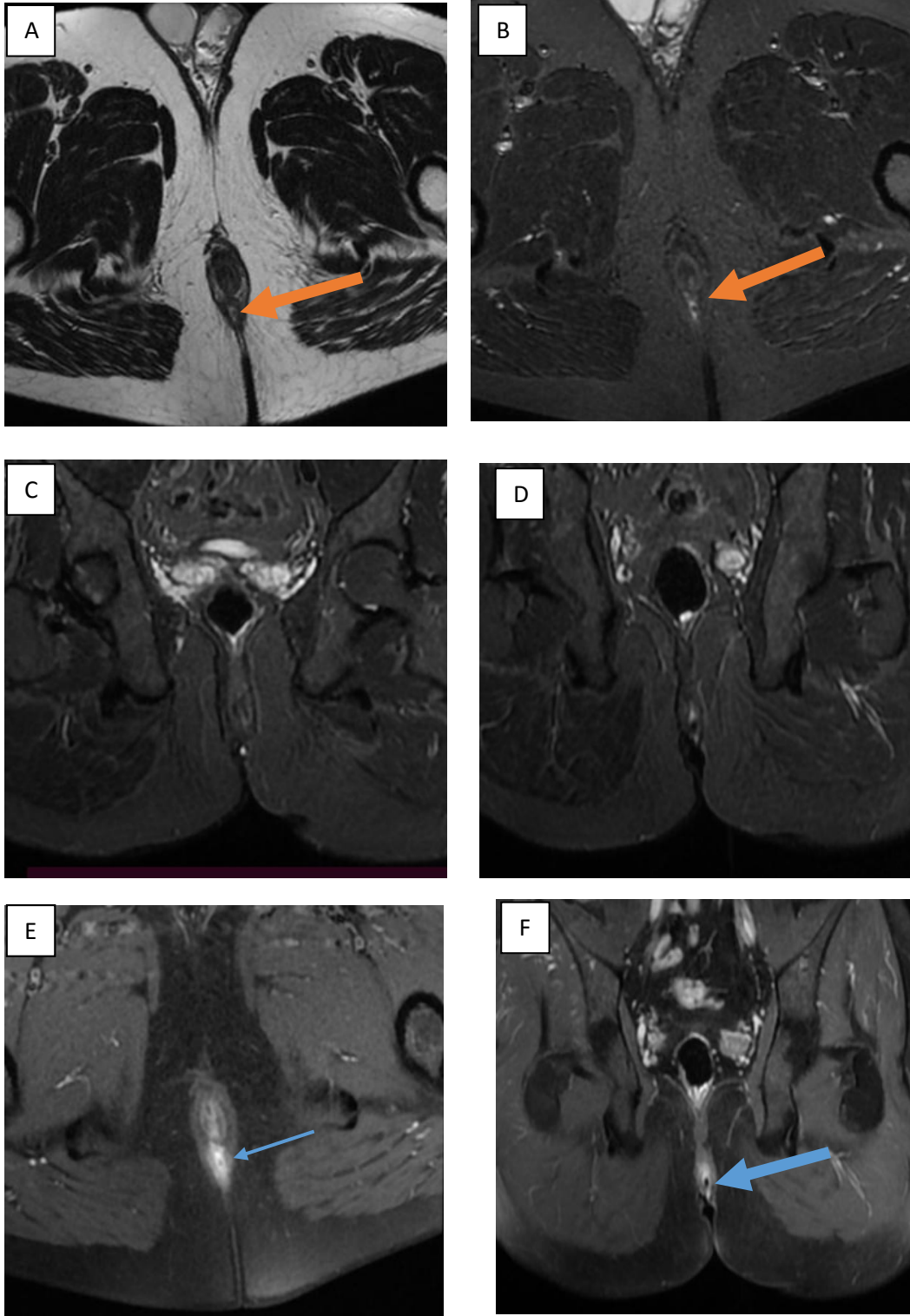
### **Findings:**

**A (Axial T2), B (Axial STIR) C, D (Coronal STIR), E (post contrast Axial T1 fat sat) & F (post contrast Coronal T1 fat sat) revealed:**

A linear perianal fistula tract seen opening externally at 6 o'clock, passing cranially between the internal and external anal sphincters (intersphincteric in location) (orange arrows), the fistulous track open in the anal canal at 6 o'clock, the tract elicits low signal in T1, high T2& STIR with post IV contrast enhancement (blue arrows). No evidence of secondary branches or abscess formation. The inserted canula showed hypointense signal inside the tract in all sequences.

### **Diagnosis:**

- Recurrent simple intersphincteric perianal fistula without secondary branch or abscess (grade I).



**Figure 4: A (Axial T2), B (Axial STIR) C, D (Coronal STIR), E (post contrast Axial T1 fat sat) & F (post contrast Coronal T1 fat sat)**

## Discussion

“Fistula-in-ano is the second most common anorectal disease after haemorrhoids. Surgery is considered the treatment of choice aiming to avoid recurrence and preserve anal sphincter function. The risk of recurrence increases to 25% if surgeons fail to recognize and remove radically a fistula and its associated elements during corrective surgery, especially internal openings and secondary tracts. Accordingly, a precise and comprehensive preoperative assessment of fistula tract is a pivotal diagnostic strategy and contributes significantly to the success rate of surgery”<sup>(96)</sup>.

“Recurrence is regularly caused by infection that was not detected by surgery and thus gone untreated. Recurrence rate after surgery is variable depending on the type of the operation, may reach up to (13.3%) with a median time to recurrence of 7.5 months”<sup>(125)</sup>.

“Recently, MRI has been considered the ‘gold standard’ technique for the preoperative evaluation of fistula-in-ano. The advantages of MRI include multiplanar imaging and a high degree of soft-tissue differentiation, which showed the fistulous track in relation to the underlying anatomy in a projection relevant to surgical exploration”<sup>(126,127)</sup>.

“MRI has the ability to detail accurately fistulas, associated abscesses and secondary extensions, which would otherwise be challenging for other radiology modalities. In addition, it can provide comprehensive images of the anatomical correlation between fistulas and anal sphincters, pelvic floor and levator ani muscle”<sup>(96)</sup>.

**Mohamed R E & Abo-Sheisha D M.**<sup>(131)</sup> reported accuracy of 100% of post contrast axial and coronal T1WI in detecting the internal mucosal opening, while on the other hand, the lowest accuracy was encountered at non contrast axial and coronal T1WI which agreed with the present study.

“Fistulae should be classified prior to surgery since the crucial point for the right surgical approach and functional results is the exact preoperative localization of the tract of the fistula.

Fistulotomy of subcutaneous or sub mucosal fistulae can be performed with a probe. Exact localization of the inner opening of the fistula can be attained by endosonography or by probes.” (132,133).

In the current study, mucosal opening was identified in 23 (76.76%) patients that were confirmed by surgical exploration with a true positive rate (TPR) (100%), in agreement with a study did by **Vo D et al.** <sup>(96)</sup>, they reported that MRI correctly identified 381/385 (99.0%) internal openings.

Simple intersphincteric fistula (grade I) was the most common type of perianal fistula in the current study among studied cases represented 36.7%, which agreed with **Mohey N and Hassan T A.** <sup>(124)</sup>, they reported that 6 of 20 cases (45%) were simple linear intersphincteric fistula (grade I).

In the current study simple inter-sphincteric fistula (grade I) confirmed in 11 cases by surgical exploration (36.7 %), MRI was correctly identified 9 cases with simple inter-sphincteric fistula (grade I) and failed to diagnose 2 cases that misdiagnosed as grade II intersphincteric fistula with secondary tracks which could be explained by confusion between neural and vascular elements with branching secondary tracks within the ischio-anal fossa. **Daabis N et al.** <sup>(134)</sup>.

Intersphincteric fistulae were the most common type of perianal fistula reported in the present study detected in 13 (43.3%) cases (11 of them grade I and 2 were grade II) followed by transphincteric fistulae grade III and IV (33.3% of cases), which agreed with study did by **Mohey N and Hassan T A.** <sup>(124)</sup>, they reported that the MRI grading revealed that fistulae (1 and 2 grades) were the commonest type detected in 24 (80%) cases also agreed with study did

by **Elzawawi M S et al.** <sup>(98)</sup>, they reported that the most common grades were intersphincteric fistula (1 and 2 grades) detected in 50% of cases.

In contrast to our study, a study did by **Baz R & Deacu C M.** <sup>(115)</sup>; Twenty-one patients with perianal sepsis were included in this study, 7 cases were grade III (trans-sphincteric fistula), 5 cases grade IV (trans-sphincteric fistula with abscess (3 cases), secondary track within the ischio-rectal fossa (1 case) and both (1 case), the transphincteric were the commonest grades reported, they were 13 of 21 cases (61.9%), another study did by **Buchanan G N** <sup>(135)</sup>, reported that the majority of 411 primary tracts found during surgery were trans-sphincteric (64.0%) and intersphincteric (22.4%).

In the current study we reported that half of the patients 15 (50%) with simple fistulous tract, 9 simple intersphincteric and 6 transsphincteric without abscess or secondary branches; in agreement with study did by **Elzawawi et al.** <sup>(98)</sup> reported that 8 of 20 cases (40%) were simple fistulous tract 5 simple intersphincteric and 3 transsphincteric without abscess or secondary branches.

The length of fistula is important to surgeons. Length of the fistulae in the current study measured 2 - < 2.5 cm in 2 (8.7%) cases, 2.5 - < 3 cm in 5 (21.7%) cases, 3 - 3.5 cm in 16 (69.6%) cases with a mean length of 2.8 cm, which agreed with study did by of **Shenoy B A et al.** <sup>(136)</sup>, reported that the mean fistula length was 2.85 mm (10–41 mm; SD 12.4).

“Contrast enhanced MRI images were found to be helpful in identifying the tract and abscess formation. Fluid, granulation tissue and pus are visualized as high signal intensity areas on a background of low-signal-intensity fat on FS T2W images. Abscesses showed a central area of low signal intensity due to pus surrounded by intense ring enhancement on contrast-enhanced FS T1WFSE images” <sup>(137,138)</sup>.

In the current study, 8 cases (26.7%) had perianal abscesses; 2 (6.7%) cases had ischeoanal abscesses without fistula, 2 (6.7%) cases had ischeoanal abscesses with inter-

sphincter fistula, 4 (13.3%) cases had ischioanal abscesses with trans sphincteric fistula. Abscesses were detected with 100% accuracy by contrast enhanced fat suppressed sequences compared to surgical exploration.

In the current study we reported sensitivity 81.8%, specificity 100%, PPV 81.8% and NPV 90.5% of MRI in detection of grade I fistula which agreed with study did by **Mohey N and Hassan T A.** <sup>(124)</sup>, they reported that sensitivity, specificity, PPV, NPV of MR grading in correlation with surgery to detect grade I fistula was 95.8%, 83.3%, 95.8%, 83.3% respectively.

We reported sensitivity 100%, specificity 92.9%, accuracy of 93.3%, PPV 100% and NPV 100% of MRI in detection of grade II fistula which agreed with study did by **Mohey and Hassan** <sup>(124)</sup>, reported that the sensitivity, specificity, PPV, NPV of MR grading in correlation with surgery was 95.8%, 83.3%, 95.8%, 83.3% respectively in detection of grade II fistula.

We noticed sensitivity 100%, specificity 100%, accuracy 100%, PPV 100% and NPV 100% of MRI in detection of grade III and IV fistulae which agreed with **Elzawawi et al.**, <sup>(98)</sup>, they reported that MRI had sensitivity of 100%, specificity of 100%, PVP of 100% and PVN of 100% in detecting grade III and grade IV fistulae.

## **Conclusion**

Contrast enhanced MRI with local gel or saline injection in selective cases with external oozing opening is a very useful procedure for successful management of recurrent peri-anal fistula by correct assessment of the extent of fistulae, relationship to sphincter complex, detection of secondary tracts and abscesses, aiming to reduce complications and recurrences.



### **Ethical Approval and Consent :**

Approval from institutional review board was obtained before starting the fieldwork. Informed written consent was obtained from participants.

### **References**

1. Attauabi M, Burisch J, Seidelin JB. Efficacy of ustekinumab for active perianal fistulizing Crohn's disease: a systematic review and meta-analysis of the current literature. *Scandinavian Journal of Gastroenterology*. 2021 Jan 2;56(1):53-8.
2. Chang YC, Tsai PH, Chou YC, Lu KC, Chang FY, Wu CC. Biomarkers Linked with Dynamic Changes of Renal Function in Asymptomatic and Mildly Symptomatic COVID-19 Patients. *Journal of Personalized Medicine*. 2021 May;11(5):432.
3. Johnson EK, Bernier G. Cryptoglandular Abscess and Fistula. In *The ASCRS Textbook of Colon and Rectal Surgery 2022* (pp. 249-269). Springer, Cham.
4. Chin Koon Siw K, Engel J, Visva S, Mallick R, Hart A, de Buck van Overstraeten A, McCurdy JD. Strategies to Distinguish Perianal Fistulas Related to Crohn's Disease From Cryptoglandular Disease: Systematic Review With Meta-Analysis. *Inflammatory Bowel Diseases*. 2021 Nov 18.
5. Varsamis N, Kosmidis C, Chatzimavroudis G, Sapalidis K, Efthymiadis C, Kiouti FA, Ioannidis A, Arnaoutoglou C, Zarogoulidis P, Kesisoglou I. Perianal fistulas: a review with emphasis on preoperative imaging. *Advances in Medical Sciences*. 2022 Mar 1;67(1):114-22.
6. Agha ME, Eid M, Mansy H, Matarawy K, Wally M. Preoperative MRI of perianal fistula: Is it really indispensable? Can it be deceptive?. *Alexandria Journal of Medicine*. 2013 Jun 1;49(2):133-44.

7. Vo D, Phan C, Nguyen L, Le H, Nguyen T, Pham H. The role of magnetic resonance imaging in the preoperative evaluation of anal fistulas. *Scientific Reports*. 2019 Nov 29;9(1):1-8.
8. Chugal NM, Clive JM, Spångberg LS. A prognostic model for assessment of the outcome of endodontic treatment: effect of biologic and diagnostic variables. *Oral Surgery, Oral Medicine, Oral Pathology, Oral Radiology, and Endodontology*. 2001 Mar 1;91(3):342-52.
9. de Miguel Criado J, del Salto LG, Rivas PF, del Hoyo LF, Velasco LG, de las Vacas MI, Marco Sanz AG, Paradela MM, Moreno EF. MR imaging evaluation of perianal fistulas: spectrum of imaging features. *Radiographics*. 2012 Jan;32(1):175-94.
10. Mohamed RE, Abo-Sheisha DM. Assessment of acromial morphology in association with rotator cuff tear using magnetic resonance imaging. *The Egyptian Journal of Radiology and Nuclear Medicine*. 2014 Mar 1;45(1):169-80.
11. Mohey N, Hassan TA. Value of mammography and combined grey scale ultrasound and ultrasound elastography in the differentiation of solid breast lesions. *The Egyptian Journal of Radiology and Nuclear Medicine*. 2014 Mar 1;45(1):253-61.