

Original Research Article

Comparison of Ultrasound Guided Thoracic Erector Spinae Plane, Thoracic Paravertebral and Thoracic Epidural Blocks for Pain Management after Nephrectomy

Abstract

Background: Thoracic epidural and paravertebral blocks carry many risks and hazardous complications when performed for adequate pain management after nephrectomy. Therefore, we evaluated the efficacy and safety of Erector Spinae block (ESB) as an alternative block compared to thoracic paravertebral (TPVB) and epidural block (TEB) for pain management after nephrectomy.

Methods: This prospective randomized single-blinded controlled study was conducted on 105 adult patients undergoing elective nephrectomy. Patients were randomized into 3 groups (35 patients in each). Group I: ESB, group II: TPVB and group III TEB done at the same level and using the same LA mixture. Postoperative pain evaluated using visual analogue scale (VAS) meperidine (0.5 mg/kg) was given when $VAS \geq 4$.

Results: Intraoperative hypotension and bradycardia were observed at 30 minutes (min) in group III with a significant difference when compared to other groups ($P < 0.001$). Early first rescue analgesia & high analgesic consumption after surgery was noticed in group III.

Conclusion: US-guided thoracic ESB produced adequate analgesia for nephrectomy.

Keywords: Erector Spinae Plane Block, Nephrectomy.

1. Introduction:

Nephrectomy is a surgical procedure done to remove either a diseased or healthy kidney via open or laparoscopic approaches. [1] Persistent untreated pain adversely affect various body systems including endocrine, cardiovascular, immune, neurologic, musculoskeletal systems. [2]

ESB first described by Forero et al, for management of thoracic neuropathic pain. [3]

Many case series concluded that ESB leads to adequate analgesia when performed at T 5 for thoracic surgery and T 7 for abdominal surgeries. [4, 5]

Thoracic paravertebral block and TEB were common analgesic blocks used in different thoracic and abdominal surgeries with some hazardous complications. [3]

ESB was reported to exert its analgesic effect by spread of the LA into the paravertebral space. [6]

Research articles [6, 7] claimed that ESB has equal analgesic effects to paravertebral and epidural blocks but no controlled studies proved these claims. Our aim was to compare the analgesic effects of three blocks to each other after nephrectomy.

2. Patients and Methods:

This prospective randomized controlled double-blinded study was conducted on 105 adult patients of both sexes, aged more than 21 years, ASA physical status I & II, scheduled for elective open nephrectomy.

Exclusion criteria were patient refusal, patients with hepatic or renal disease, coagulopathy, uncontrolled cardiovascular or respiratory problems.

Routine laboratory investigations were done, Participants were randomly assigned into 3 groups using computer-generated numbers.

Group I: Patients received ultrasound-guided ESB, **Group II:** Patients received ultrasound-guided TPVB and **Group III (control group):** Patients received TEB using bupivacaine 20 ml (0.25%) before GA induction.

A peripheral intravenous line (18 G cannula) was inserted then Ringer's Lactate solution was infused at a rate of 10 mL/ kg to compensate for the fasting hours. [8] Standard ASA monitoring was done by: ECG, NIBP, Etco₂ and pulse oximetry. An ultrasound machine (Phillips®, Cx-50, Amsterdam, Netherlands) with a linear probe (5-12) MHz was placed lateral to the midline and counting ribs upward from the last rib till the 8th rib and a skin mark was done at the 8th thoracic spine (T8).

The technique of US-guided ESB:

The block was performed after skin sterilization using Povidone-iodine 10% at the level of the 8th thoracic spine. An echogenic needle (Sonoplex, Pajunk, Germany) was inserted from the caudal end of the probe & advanced in-plane direction until the needle tip hit the tip of the transverse process, then the needle is withdrawn slowly to be within the interfascial plane below the erector spinae muscle then LA injected with linear spread cranially and caudally visualized indicating successful block. [9]

The technique of US-guided TPVB:

The block was performed at the level of the 8th thoracic spine then the US probe was placed 3 cm lateral and parallel to the 8th spinous process till the transverse process (TP), superior costotransverse ligament (SCTL), and the pleura were visualized then lateral tilt of the probe was done for better visualization of the paravertebral space between the SCTL and the pleura then an echogenic needle was inserted at the caudal end of the transducer using the in-plane technique till crossing the SCTL. Gentle aspiration was done to exclude blood and air then LA injected. [10]

The technique of TEB:

TEB was performed in paramedian plane using 18 G Tuohy needle (B. Braun, Melsungen, Germany) & loss of resistance indicates passage of the needle beyond the ligamentum flavum then then LA injected. [11]

2.1. General anesthesia:

Induction of anesthesia done by IV fentanyl (2 µg/kg), propofol (2 mg/kg), and Cisatracurium (0.15 mg/kg) then tracheal intubation was done. Maintenance of anesthesia was done by 1 MAC isoflurane and Cisatracurium.

After extubation, patients were transferred to the post-anesthesia care unit (PACU) then discharged to the ward fully conscious and hemodynamically stable.

Paracetamol 1 gm intravenous infusion was given every 8 hours as routine analgesia. Intravenous meperidine (0.5 mg/ kg) was administered as rescue analgesia if VAS was ≥ 4 .

2.2. Measurements:

All results and study outcomes were assessed and recorded by another anesthesiologist blinded to group allocation.

Demographic data (age, gender, weight, body mass index, duration of surgery). Onset of sensory block, Heart rate (HR) and mean arterial pressure (MAP) were recorded before block performance (T0), intraoperatively at 30, 60, 90, 120 min and before discharge from PACU at (T 00), postoperatively at 2, 4, 6, 12, 18, 24 hours. Also, we recorded the time of the first rescue analgesia, and total meperidine consumption in the first 24 h. Visual Analogue Score (VAS) was used to assess the postoperative pain (0 = no pain and 10 = severe pain) before discharging from the PACU at (T 00) and postoperatively at 2, 4, 6, 12, 18, 24 h. Postoperative adverse effects were evaluated: hypotension, bradycardia, or local anesthetic toxicity. The degree of patient satisfaction was assessed on a 3-point scale: [12] (1= unsatisfied 2= neither satisfied nor unsatisfied 3= satisfied)

The primary outcome was the total meperidine consumption in the first 24 h after surgery and the secondary outcomes were the VAS and incidence of complications.

2.3. Sample size calculation and statistical analysis:

The sample size was calculated according to a pilot study done before the start of the study (10 patients in each group). The mean (\pm SD) total dose of postoperative meperidine consumption (the primary outcome) was 113 ± 29.46 mg in group I, 123 ± 31.99 mg in group II and 140 ± 39.72 mg in group III. With a 95% confidence limit, 80% power, 0.33 effect size, and 4 cases added to overcome dropout, 35 cases were included in each group.

Statistical analysis was done by SPSS v25 (IBM®, Chicago, IL, USA). Parametric variables were expressed as mean and standard deviation (SD) and were compared using the F test among the three groups with post hoc (Tuckey test) to compare every two groups. Non-parametric variables were analyzed using the Kruskal-Wallis test; further analysis was performed by Mann–Whitney (U) test to compare every two groups. P-value was considered statistically significant when $P < 0.05$.

UNDER PEER REVIEW

3. Results

One hundred twenty-six patients were evaluated for eligibility; 13 patients didn't match with the inclusion criteria and 8 patients refused to participate in the trial. 105 patients were enrolled in the study and allocated in three groups of 35 patients each. Figure 1

Demographic data including age, sex, weight, height, BMI, and the duration of surgery showed no significant difference among the studied groups. Table 1

Regarding hemodynamic parameters (HR & MAP); there was an early significant increase in group III (TEB) compared to group I & II at 4, 6, and 12 h postoperatively with no significant differences while comparing group I & II to each other at these times. Figure 2 & 3

Regarding VAS: there was an early increase in VAS in group III (TEB) compared to group I & II at 4, 6, and 12 h postoperatively with no significant differences while comparing group I and II to each other at these times. Figure 4

There was early analgesic demand in group III compared to group I & II (5.31 ± 1.23 vs 7 ± 1.81 & 7.4 ± 1.99 hours; $P < 0.001$) with no difference between group I and II ($P = 0.592$). Table 2

Also, meperidine consumption in the 1st 24^h showed more consumption in group III compared to the other groups; $P < 0.001$) with no difference between group I & II to each other; $P = 0.758$. Table 2

There was an early incidence of intraoperative hypotension and bradycardia in group III at 30 min with a significant difference when compared to group I & II ($P < 0.05$) with an early increase in HR and MAP in group III at 4 h when compared to the other groups that were correlated to higher VAS values at the same recorded times. There was no incidence of major adverse events as; LAST, pneumothorax in the 3 groups. Table 3

Patient satisfaction showed no significant difference among the 3 groups.

4. Discussion

Ultrasound changed regional anesthesia practices away from needle targeting nerve to injecting LA in facial planes where the needle can be visualized and the injectate spreads to affect target nerves. This simple mechanism has made performing nerve blocks safer and easier. [13]

Acute pain after nephrectomy remains a major problem. Chronic pain develops in nearly 20–26% of patients undergoing open nephrectomy leading to higher opioid consumption with many adverse effects. [14]

TEB carries many risks including hypotension, bradycardia, wet tap, high block, LAST, and total spinal anesthesia, nerve injury, hematoma, and abscess formation. [15]

The paravertebral block is an effective analgesic technique for thoracic and upper abdominal surgeries but with risk of pneumothorax. [16]

Erector spinae block (ESB) is a superficial interfascial plane block that was easily performed by ultrasound compared to TPVB& TEB. **Forero et al (2016)** first report on ESB; documented the mechanism of ESB is due LA spread to the paravertebral space after visualizing dye spread deep to the erector spinae muscle beyond the superior costotransverse ligament. [3]

In agreement with our results, Moawad et al found that single-injection PVB produced adequate analgesia during the perioperative period for nephrectomy with more hemodynamic stability compared to TEB. [8]

In contrast to our result, Gautam et al compared continuous TEB and TPVB for open nephrectomy and found no significant difference regarding MAP between the two groups and this may be due to continuous, low volume and concentration of LA mixture with bupivacaine 0.1%. [17]

Regarding VAS comparison among the studied groups, In agreement with our finding, Gürkan et al found no significant difference regarding VAS recording in the 1st 24 h after mastectomy when comparing between ESB group and TPVB group. [18]

In contrast to our finding, Gautam et al found no significant difference regarding VAS scores between the TPVB and TEB groups for patients who had been operated on for nephrectomy. [17]

Regarding the 1st rescue analgesia postoperatively; In agreement with our results, Moustafa et al & El Ghamry et al found no significant difference in time of 1st rescue analgesia after modified radical mastectomy between patients who received US-guided TPVB versus ESB. [19, 20]

Regarding the total meperidine consumption in the first 24 h, In agreement with our results, Zhao et al & Fang et al found no significant difference in total opioid consumption in patients operated for VATS & thoracotomy receiving ESB compared to TPVB. [21, 22]

In contrast to our results, Moawad et al compared TEB, TPVB and found no significant difference in total meperidine consumption in the 1st day after nephrectomy and this may be attributed to the blind technique used in TPVB. [8]

Regarding complications: In agreement with our results, Swicher et al studied 100 cases of mastectomy received US-guided ESB, TPVB with single-shot LA mixture and found no major adverse events occurred in both groups. [23] Also, Pace *et al* conducted a study on 1427 patients undergoing mastectomy receiving US guided TPVB, found no incidence of pneumothorax. [24]

Regarding the incidence of hypotension: Our results were similar to Biswas et al who found higher incidence of hypotension and bradycardia in the epidural group compared to the paravertebral group. (25)

One of the limitations of our study was the limited duration of analgesia due to single-injection techniques utilized.

5. Conclusion:

US-guided thoracic ESB produced adequate analgesia for nephrectomy.

DISCLAIMER:

Authors have declared that no competing interests exist. The products used for this research are commonly and predominantly use products in our area of research and country. There is absolutely no conflict of interest between the authors and producers of the products because we do not intend to use these products as an avenue for any litigation but for the advancement of knowledge. Also, the research was not funded by the producing company rather it was funded by personal efforts of the authors.

Ethical Approval and Consent :

The trial was started after receiving approval from the Ethical Committee (32575/09/18), registered in the Pan African Clinical Trials Registry (PACTR201812544261175), after consent obtained from all participants.

References:

- [1] Acar C, Bilen C, Bayazit Y, et al. Quality of life survey following laparoscopic and open radical nephrectomy. *Urology journal*. 2014;11(06):1944-50.
- [2] Greenberg EN. The consequences of chronic pain. *Journal of pain & palliative care pharmacotherapy*. 2012;26(1):64-7..
- [3] Forero M, Adhikary SD, Lopez H, et al. The erector spinae plane block: a novel analgesic technique in thoracic neuropathic pain. *Reg Anesth Pain Med*. 2016;41(5):621-7..
- [4] Restrepo-Garces CE, Chin KJ, Suarez P, et al. Bilateral continuous erector spinae plane block contributes to effective postoperative analgesia after major open abdominal surgery: A case report. *Anesthesia & Analgesia case reports*. 2017;9(11):319-21.
- [5] Chin KJ, Malhas L, Perlas A. The erector spinae plane block provides visceral abdominal analgesia in bariatric surgery: a report of 3 cases. *Regional Anesthesia Pain Medicine*. 2017;42(3):372-6.
- [6] Bonvicini D, Tagliapietra L, Giacomazzi A, et al. Bilateral ultrasound-guided erector spinae plane blocks in breast cancer and reconstruction surgery. *Journal of clinical anesthesia*. 2018; 44:3-4.
- [7] Chin K, Adhikary S, Sarwani N, et al. The analgesic efficacy of pre-operative bilateral erector spinae plane (ESP) blocks in patients having ventral hernia repair. *Anaesthesia*. 2017s;72(4):452-60.
- [8] Moawad HE, Mousa SA, El-Hefnawy AS. Single-dose paravertebral blockade versus epidural blockade for pain relief after open renal surgery: A prospective randomized study. *Saudi journal of anesthesia*, 2013, 7.1: 61.
- [9] Kot P, Rodriguez P, Granell M, et al. The erector spinae plane block: a narrative review. *Korean J Anesthesiol*. 2019;72(3):209-20.
- [10] ELdeen H. Ultrasound-guided thoracic epidural and paravertebral blocks for cholecystectomy in pediatric patients with a cyanotic heart disease: a randomized controlled study. *Egyptian Journal of Anesthesia*, 2016, 32.1: 89-96.
- [11] Toledano R and Van de Velde M. Epidural Anesthesia and Analgesia. *Hadzic textbook of regional anesthesia and acute pain management*, 2nd ed. McGraw-Hill, New York, USA, 2017; 380-438.
- [12] Sasikumar G, Koshy RC, Prabhu DJ. Thoracic Paravertebral Block, a Suitable and Safe Adjunct for General Anaesthesia, for Post-Operative Pain Relief in Modified Radical Mastectomies. *Journal of Medical Science And Clinical Research*. 2018; 06(03): 447-54.
- [13] Akerman M, Pejčić N, Veličković I. A review of the quadratus lumborum block and ERAS. *Frontiers in medicine*. 2018 ;5:44.
- [14] Owen M, Lorgelly P, Serpell M. Chronic pain following donor nephrectomy – A study of the incidence, nature and impact of chronic post-nephrectomy pain. *European Journal of Pain*, 2010, 14.7: 732-734.
- [15] Buvanendran A and Kroin JS. Multimodal analgesia for controlling acute postoperative pain. *Current opinion in Anesthesiology*, 2009, 22.5: 588-593.
- [16] Cox F and Cousins A. Thoracic paravertebral block (PVB) analgesia. *Journal of Perioperative Practice*, 2008, 18.11: 491-496.
- [17] Gautam SKS, Das PK, Agarwal A, et al. Comparative Evaluation of Continuous Thoracic Paravertebral Block and Thoracic Epidural Analgesia Techniques for Post-operative Pain Relief in Patients Undergoing Open Nephrectomy: A Prospective, Randomized, Single-blind Study. *Anesthesia, Essays and Researches*, 2017, 11.2: 359.
- [18] Gürkan Y, Aksu C, Kuş A, et al. Erector spinae plane block and thoracic paravertebral block for breast surgery compared to IV-morphine: a randomized controlled trial. *Journal of clinical anesthesia*, 2020, 59: 84-88.

- [19] Moustafa MA, Alabd AS, Ahmed AM, Deghidly EA. Erector spinae versus paravertebral plane blocks in modified radical mastectomy: Randomised comparative study of the technique success rate among novice anaesthesiologists. *Indian Journal Anaesthesia*, 2020;64:49-54.
- [20] El Ghamry MR, Amer AF. Role of erector spinae plane block versus paravertebral block in pain control after modified radical mastectomy. A prospective randomised trial. *Indian Journal Anaesthesia*. 2019 Dec;63(12):1008-1014.
- [21] Zhao H, Xin L, Feng Y. The effect of preoperative erector spinae plane vs. paravertebral blocks on patient-controlled oxycodone consumption after video-assisted thoracic surgery: A prospective randomized, blinded, non-inferiority study. *Journal of Clinical Anesthesia*, 2020, 62: 109737.
- [22] Fang B, Wang Z, Huang X. Ultrasound-guided preoperative single-dose erector spinae plane block provides comparable analgesia to thoracic paravertebral block following thoracotomy: a single center randomized controlled double-blind study. *Annals of translational medicine*, 2019, 7.8.
- [23] Swisher MW, Wallace AM, Sztain JF, *et al.* Erector spinae plane versus paravertebral nerve blocks for postoperative analgesia after breast surgery: a randomized clinical trial. *Regional Anesthesia & Pain Medicine*, 2020;45:260-266.
- [24] Pace MM, Sharma B, Anderson-Dam J, *et al.* Ultrasound-guided thoracic paravertebral blockade: A retrospective study of the incidence of complications. *Anesthesia & Analgesia*, 2016; 122:1186–91.
- [25] Biswas S, Verma R, Bhatia VK, *et al.* Comparison between Thoracic Epidural Block and Thoracic Paravertebral Block for Post Thoracotomy Pain Relief. *Journal of clinical and diagnostic research*, 2016;10(9):8-12.

Table 1: Patient characteristics of the three groups

		Group I (n = 35)	Group II (n = 35)	Group III (n = 35)	P value
Age (years)		56.51 ± 9.60	55.91 ± 9.67	54.14 ± 9.80	0.569
Sex	Male	30 (85.7%)	26 (74.3%)	29 (82.9%)	0.448
	Female	5 (14.3%)	9 (25.7%)	6 (17.1%)	
Weight (Kg)		91.26 ± 6.43	91.54 ± 7.50	92.4 ± 4.73	0.734
Height (cm)		180.2 ± 3.54	178.63 ± 4.76	179.8 ± 4.95	0.313
BMI (kg/m ²)		28.13 ± 2.08	28.74 ± 2.57	28.64 ± 2.01	0.477
Duration of surgery (min)		138.29 ± 16.36	140.86 ± 18.37	148.29 ± 21.49	0.075

Data are presented as mean ± SD or patient number (%) BMI: Body mass index

Table 2: Block characteristics of the three groups

	Group I (n = 35)	Group II (n = 35)	Group III (n = 35)	P value
Onset of sensory block (min)	23.71 ± 3.90	17.14 ± 5.85 [#]	11.0 ± 4.17 ^{Δ∞}	<0.001*
Time to first rescue analgesia (h)	7 ± 1.81 [∞]	7.4 ± 1.99 ^Δ	5.31 ± 1.23	<0.001*
Total meperidine consumption (mg/24h)	120.57 ± 28.28 [∞]	115.43 ± 26.05 ^Δ	162 ± 35.71	<0.001*

Data are presented as mean ± SD

*: Statistically significant difference between the three groups (P value ≤ 0.05).

#: Statistically significant difference when I compared with II; Tukey's test (P value ≤ 0.05).

Δ: Statistically significant difference when II compared with III; Tukey's test (P value ≤ 0.05).

∞: Statistically significant difference when I compared with III; Tukey's test (P value ≤ 0.05).

Table 3: Adverse effects in the three groups.

	Group I (ESB) (n = 35)	Group II (TPVB) (n = 35)	Group III (TEB) (n = 35)	P-value
Bradycardia	0 (0%)	3 (8.6%)	6 (17.1%)	0.038*
Hypotension	0 (0%)	5 (14.3%)	12 (34.3%)	0.005*
Pneumothorax	0 (0%)	0 (0%)	0 (0%)	----

*: Statistically significant difference between the three groups (P value ≤ 0.05).

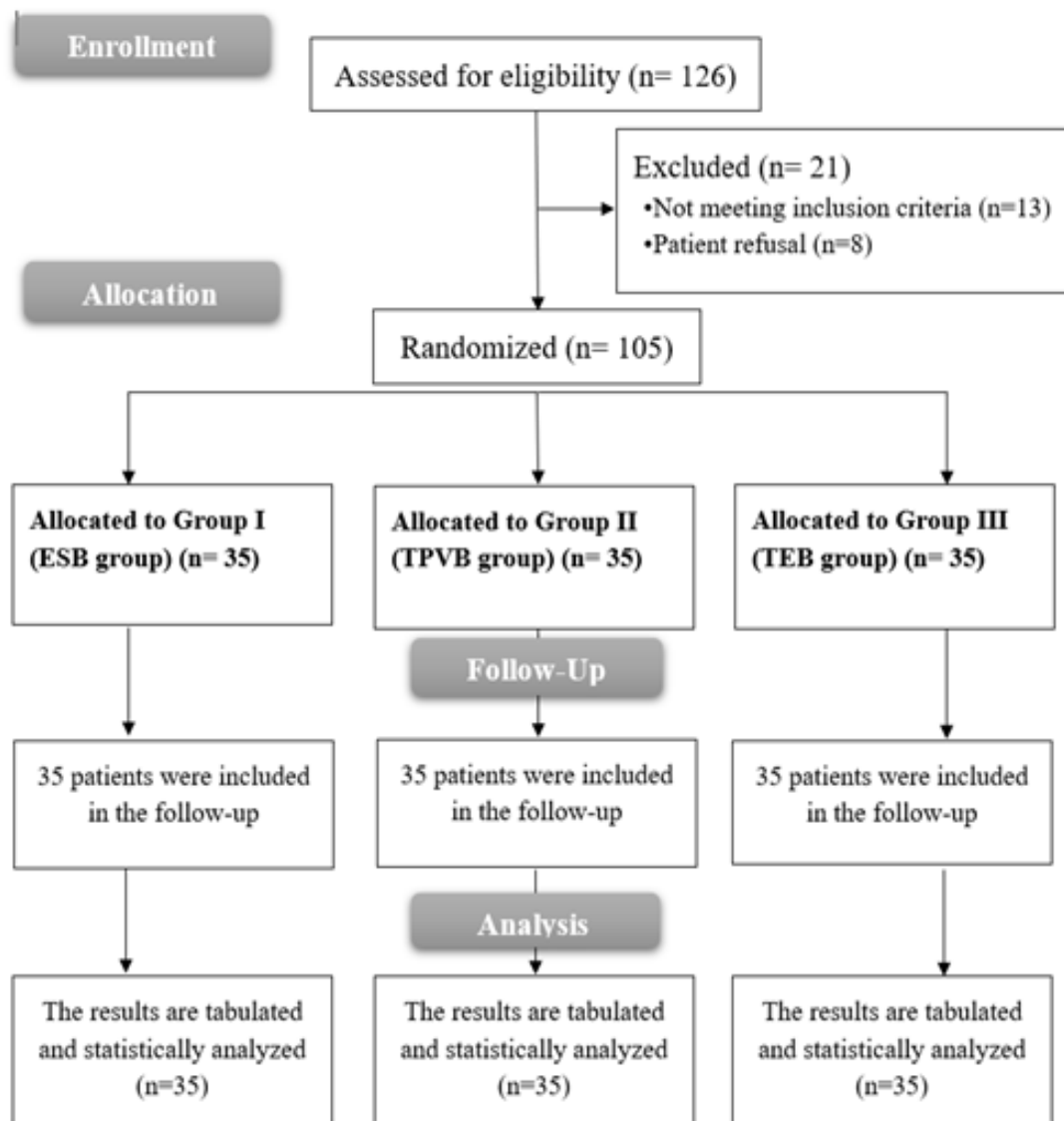


Figure 1: CONSORT flow diagram of the three groups

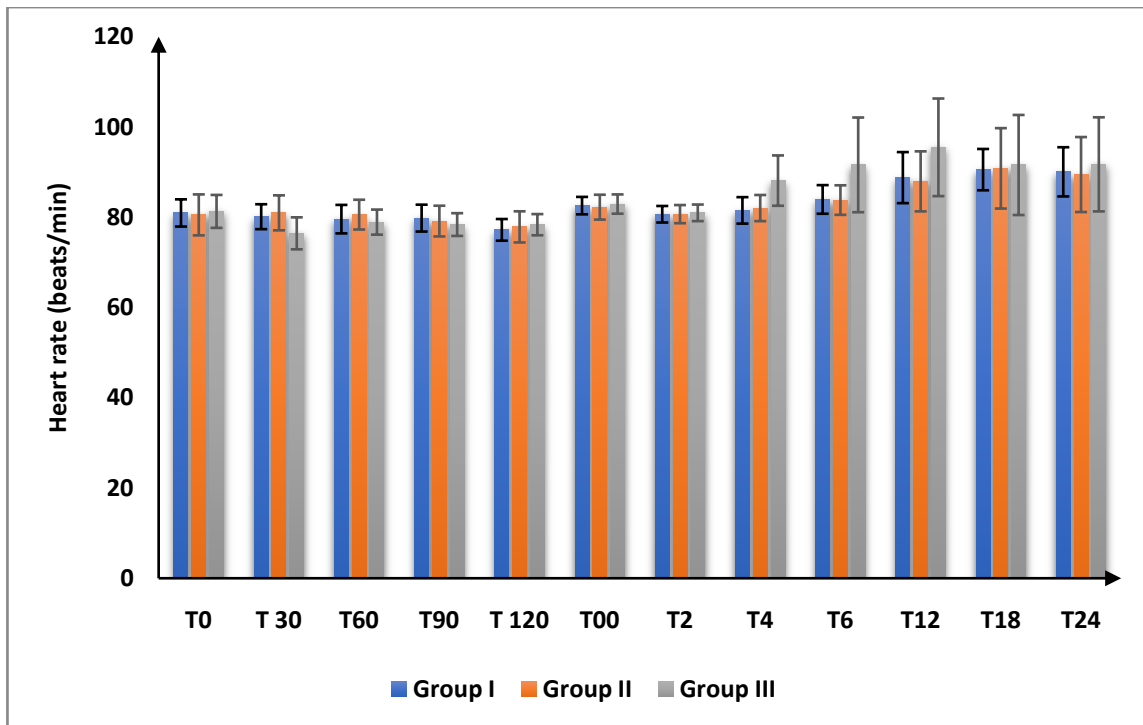


Figure 2: Heart rate changes in the studied groups

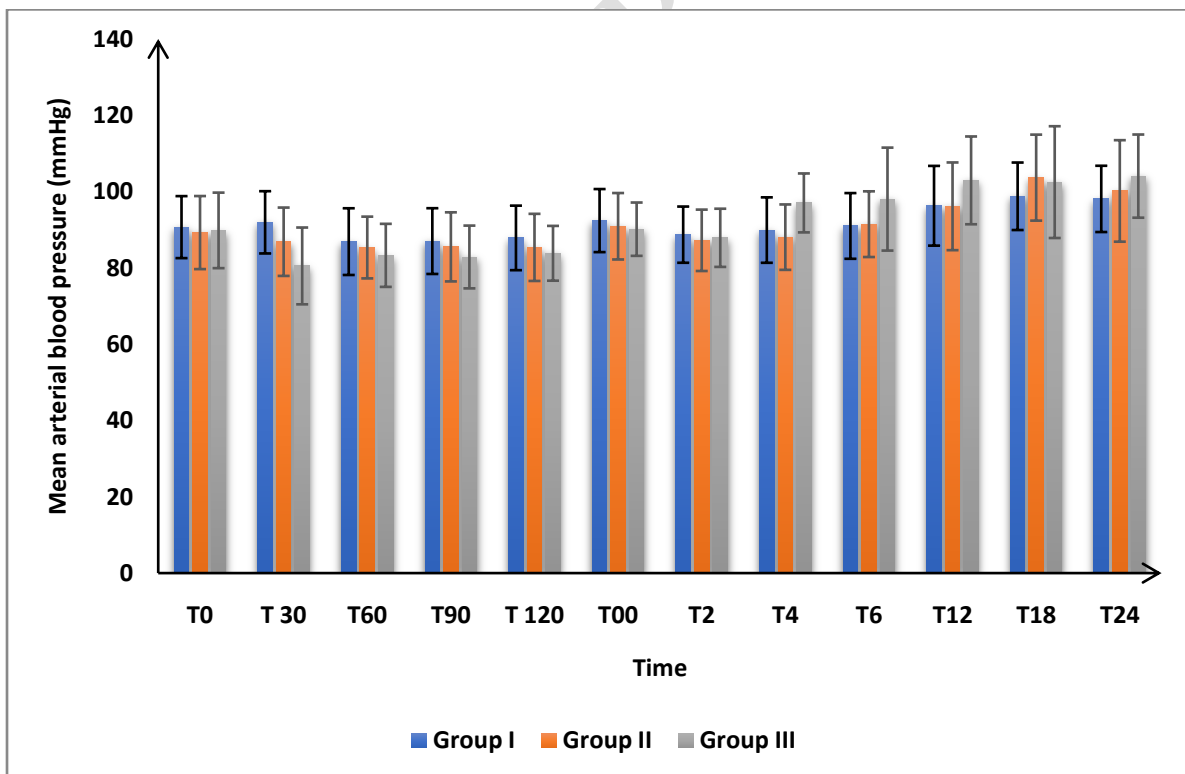


Figure 3: Mean arterial blood pressure changes in the studied groups

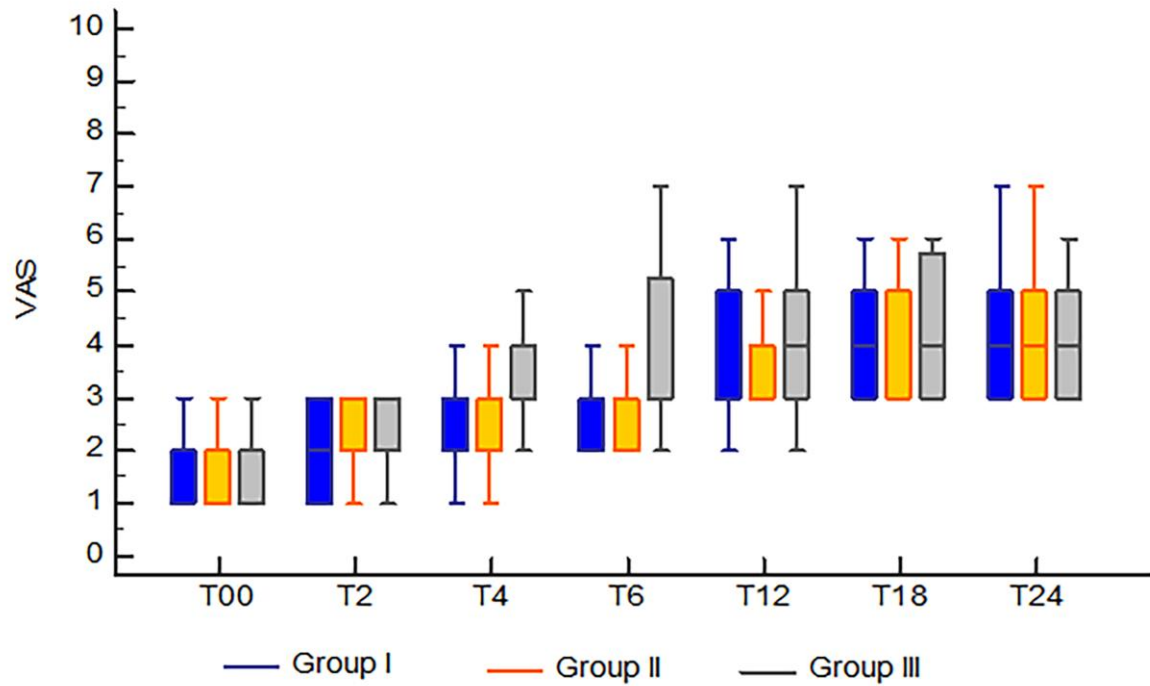


Figure 4: Visual analogue scale (VAS) changes in the studied groups

Figure captions

Figure 1: CONSORT flow diagram of both groups

Figure 2: Heart rate changes in the studied groups

Figure 3: Mean arterial blood pressure changes in the studied groups

Figure 4: Visual analogue scale (VAS) changes in the studied groups