

---

## Case study

# A Mass Occupied In Neck Carotid Bifurcation Territory Diagnosed Sebaceous Adenocarcinoma: A Case Report

### ABSTRACT

**Aims:** To describe a rare case presenting with pulsing mass stumbled across the right upper neck.

**Presentation of Case:** The patient was presented to the outpatient department of ENT due to a pulsing mass stumbled across the right upper neck for half a year. Cervical enhancement CT scan was performed, which disclosed a lesion at the bifurcation of the right carotid artery and possessed insignificant blood supply. Hospitalization was arranged for a full examination, and culminating in a diagnostic resection.

**Discussion:** This case was challenging for clinicians to differentially diagnose the placeholder at the carotid artery bifurcation, and the pathological results in this case was extremely rare and have never been reported in the literature. Extraocular SGC is strongly associated with Muir-Torre syndrome (MTS), a phenotypic variant of Lynch syndrome and results from mutations in DNA MMR genes. It suggests all patients presenting with sebaceous neoplasms should be screened for MTS.

**Conclusion:** Our case creates a paradigm for otolaryngologists and oral and maxillofacial surgeons.

**Keywords:** neck; sebaceous gland carcinoma; carotid bifurcation; surgery.

### 1. INTRODUCTION

Sebaceous gland carcinoma (SGC) is a rare but potentially aggressive malignancy. Due to the high density of sebaceous glands found in the skin of the head and neck, SGC occurs in there not rare[1]. It can be classified into two groups by location traditionally: periorbital and extra-orbital, and approximately 70% of late group are in the head and neck regions due to the high density of sebaceous glands found there[2, 3]. It reported that the incidence rates ranging from 0.5 per million in the black population to 1 per million in Asians and Pacific Islanders and 2 per million in Caucasians[4]. Because of the paucity of data, diagnosis may be challenging, and the gold standard treatment or quantify prognostic factors is not available.

In the English literature, the non-cutaneous SGC of parotid gland is the most site encountered, the rest in the submandibular, sublingual, minor glands, oral cavity, vallecula, hypopharynx and larynx, has been reported sparsely[3, 5-7]. Herein, we present a case of an older man with a mass at the right neck Carotid bifurcation area eventually diagnosed as sebaceous gland carcinoma, with a brief review of the literature. To date, no cases of sebaceous carcinoma from neck carotid bifurcation area have been reported in the English literature.

### 2. CASE PRESENTATION

A 62-year-old man presented with a mass in his right neck for approximately six months. A nonpainful mass was stumbled across the right upper neck. He had no symptoms of dysphagia or cerebral ischemia related symptoms. He had a 20 pack-year of smoking history and had no alcohol abuse or social history. Physical examination revealed a pulsing mass with cardiac rhythm on the right neck zone III. The mass border was regular, spreading to the submandibular gland area, and the overlying skin of the lesion was found no abnormalities and other area. No palpable regional lymphadenopathy was investigated in I-V area of the right neck. Endoscopy panel was studied for nasopharynx, larynx and oesophagus, no other unusual appearance founded. Ultrasonography showed a 4.2× 2.6cm circumscribed mass superior lateral to the right neck carotid bifurcation. An enhanced computerized

---

tomography (CT) of neck scan showed a slightly low density of lesion around the right carotid sheath (FigA), possessed uneven light enhancement and nodular sheet-like low-enhancement area. The external carotid artery branches closely adhere to and extend into the lesion locally. The internal jugular vein was squeezed and the lumen proximal part severely narrowed. A fine-needle aspiration was arranged but no definitive pathology diagnosis obtained. We performed diagnostic surgery in the operating theater based on the clinical and radiologic findings above.

### 3. DISCUSSION

Histologically, routine paraffin section and Hematoxylin and Eosin staining of specimen was disclosed rimed with basaloid polygonal cells, with large and irregular vesicular nuclei striking multiple prominent nucleoli, central areas of necrosis, and increased mitosis. Immunohistochemical (IHC) analysis results showed: CK (+), CK5/6(+) p63(+), p40(+), Ki-67(40%+), calponin (-), CD117(-), AB-PAS (-), TTF-1(-), TG (-) (Sup1-15). These findings were consistent with a diagnosis of extraocular sebaceous gland carcinoma (SGC) (FigB). No characters of extraparenchymal extension, perineural infiltration, and lymph invasion were identified.

Extraocular SGC was rare, and most cases occur in dermal of the head and neck area. Only four cases arising within submandibular area of cervical region have been reported[6, 8-10]. No suspicious primary lesions were identified by enhanced CT of head-to-abdomen for this patient. The diagnosis of extraocular SGC mainly based on HE staining, poorly differentiated tumors sebaceous may require IHC confirmation. EMA and adipophilin were sensitive markers in distinguishing sebaceous differentiation[11]. This case was challenging to classify and must be distinguished from basal cell carcinomas, squamous cell carcinomas and mucoepidermoid carcinoma.

The exact pathogenesis of extraocular SGC is mysterious and requires further research, and also the exact origin of oncocytes and the carcinogenesis. Some posit that such tumor cells were derived from pluripotent epithelial cells [8], Boecker et al[12] elucidated the p63+ K5+ progenitor cells may be the cells of origin of the extraocular SGC, but which subpopulation preferentially targeted for SGC initiation was unknown. While others suggest they developed from malignant transformation of differentiated sebaceous cells[10].

The recommended treatment is based on surgery with wide surgical excision and elective neck dissection for low grade differentiations. Adjuvant radiotherapy is recommended for higher grade tumors or positive margins, but chemotherapy is not a recognized standard treatment [8, 9].

Extraocular SGC is strongly associated with Muir-Torre syndrome (MTS), a phenotypic variant of Lynch syndrome and results from mutations in DNA MMR genes. It suggests all patients presenting with sebaceous neoplasms should be screened for MTS[13]. We performed IHC panel for MSH2, MSH6, MLH1 and PMS2 (Sup16-19), the testing revealed no mutations of the related genes. The patient was clinically in good condition 16 months after diagnosis and continued to be closely monitored. Recent research disclosed that PD-L1 expression shows a higher intertumoral heterogeneity in extraocular SGC than periocular cases, but the responses to PD-1 blockade remain challenging[14].

In this case, an otolaryngologist or oral and maxillofacial surgeons needs to make a differential diagnosis of the related diseases. Carotid body tumor, most commonly located within the bifurcation of the common carotid artery in the infrathyoid region. The symptomatic clinical findings may include a cervical beating mass, lateral pharyngeal wall submucosal mass, or Horner's syndrome. It intensely enhanced on CT, splay the internal and external carotid arteries and own flow voids, these findings help differential diagnosis [15]. Cervical lymph nodes tuberculosis is a common condition of extrapulmonary tuberculosis within tuberculosis-endemic area[16]. Due to no typical clinical features

and imaging characteristics, this case scenario was easy to put the differential diagnosis of cervical masses into a dilemma, especial tuberculosis and metastatic nodes. It is crucial for comprehensive evaluate the diagnostic value of neck imaging including ultrasonography, computed tomography, MRI, PET-CT, and laboratory tests such as tuberculosis spot test, the final conclusion still needs pathological diagnosis.

#### **4. Conclusion**

The final diagnosis of sebaceous carcinoma from a mass at the carotid bifurcation site is rare, and its pathological evolution is unclear. Extraocular SGC is strongly associated with Muir-Torre syndrome, and special attention should be paid to screening for MTS in patients with sebaceous carcinoma. Our case creates a paradigm for otolaryngologists and oral and maxillofacial surgeons.

#### **Funding**

This case study was funded by a project from the Yunnan Provincial Department of Science and Technology of china, 2019FE001(-007).

#### **Competing interests**

The authors declare no conflict of interest.

#### **Informed consent statement**

Consent was obtained from relatives of the patient for publication of this report and any accompanying images.

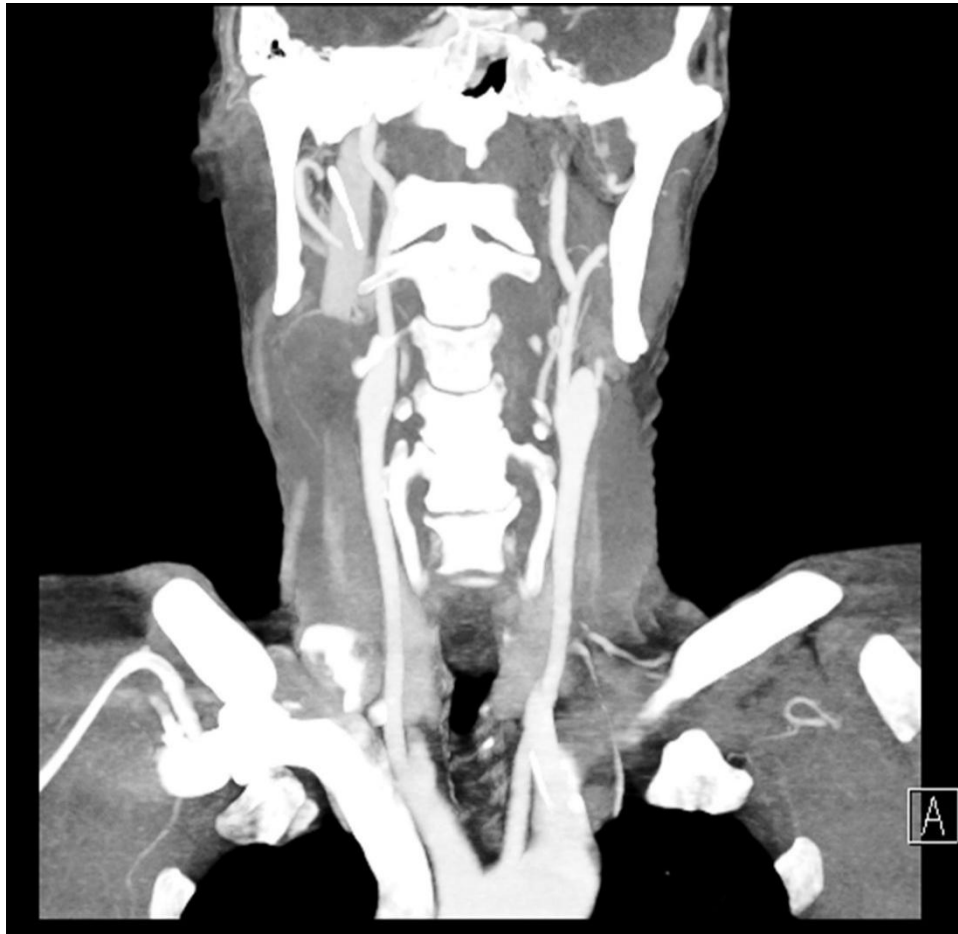#### **REFERENCES**

- 1 W.W. Thomas, V.A. Fritsch, E.J. Lentsch. Population-based analysis of prognostic indicators in sebaceous carcinoma of the head and neck. *Laryngoscope*. 2013;123 (9):2165-2169.  
DOI: 10.1002/lary.24042
- 2 M.A. Pickford, F.J. Hogg, M.E. Fallowfield, M.H. Webster. Sebaceous carcinoma of the periorbital and extraorbital regions. *Br J Plast Surg*. 1995;48 (2):93-96.  
DOI: 10.1016/0007-1226(95)90103-5
- 3 Q. Lu, X.Y. Fu, Y. Huang. Sebaceous carcinoma of the right palate: case report and literature review. *Gland Surg*. 2021;10 (5):1819-1825.  
DOI: 10.21037/gs-21-218
- 4 T. Dasgupta, L.D. Wilson, J.B. Yu. A retrospective review of 1349 cases of sebaceous carcinoma. *Cancer*. 2009;115 (1):158-165.  
DOI: 10.1002/cncr.23952
- 5 M. Khmou, K. Laadam, N. Cherradi. Parotid gland, an exceptional localization of sebaceous carcinoma: case report. *BMC Clin Pathol*. 2016;16:10.  
DOI: 10.1186/s12907-016-0031-y
- 6 A. Diedhiou, D. Cazals-Hatem, E. Rondini, O. Sterkers, C. Degott, M. Wassef. [Sebaceous carcinoma of the submandibular gland: a case report]. *Ann Pathol*. 2001;21 (4):348-351.  
<https://www.ncbi.nlm.nih.gov/pubmed/11685135>
- 7 A. Cardesa, A. Nadal, L. Alos, J. Lloreta-Trull, A. Ferlito. Sebaceous Differentiation in Squamous Cell Carcinoma of the Larynx and Adjacent Pharynx: Case Report with Review and Discussion of the Literature. *Head Neck Pathol*. 2018;12 (1):118-122.  
DOI: 10.1007/s12105-017-0839-5
- 8 N. Ohara, K. Taguchi, M. Yamamoto, T. Nagano, T. Akagi. Sebaceous carcinoma of the submandibular gland with high-grade malignancy: report of a case. *Pathol Int*. 1998;48 (4):287-291.

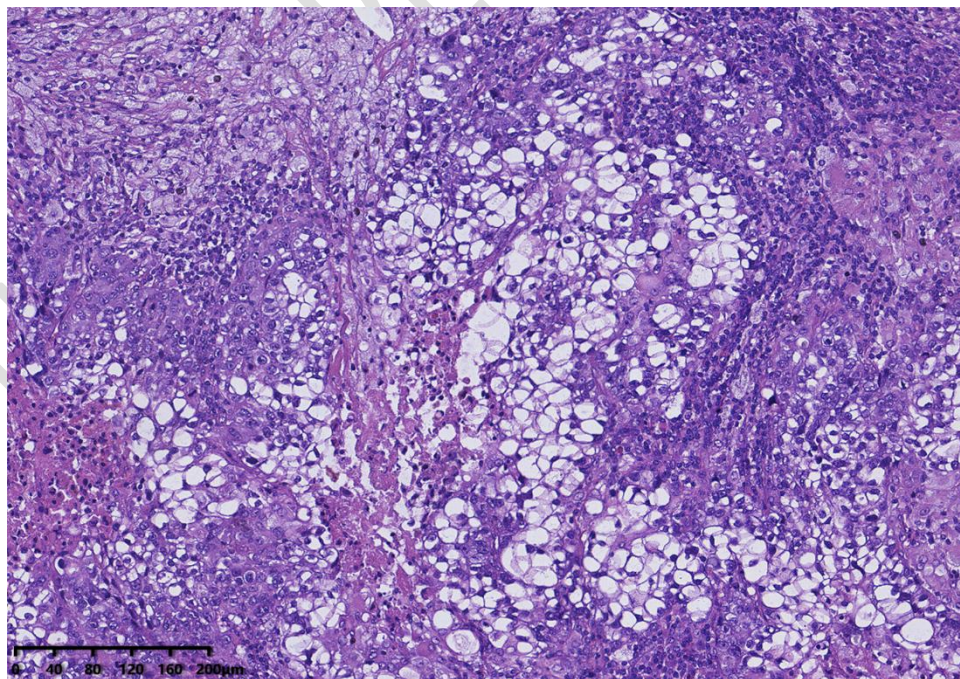
---

DOI: 10.1111/j.1440-1827.1998.tb03907.x

- 9 C.D. Soares, T.M.L. Morais, R. Carlos, J. Jorge, O.P. de Almeida, M.G.F. de Carvalho, A.M.M. Altemani. Sebaceous adenocarcinomas of the major salivary glands: a clinicopathological analysis of 10 cases. *Histopathology*. 2018;73 (4):585-592.  
DOI: 10.1111/his.13664
10. R. Zare-Mahmoodabadi, J. Salehinejad, S. Saghafi, N. Ghazi, P. Mahmoudi, A. Harraji. Sebaceous adenoma of the submandibular gland: a case report. *J Oral Sci*. 2009;51 (4):641-644.  
DOI: 10.2334/josnurd.51.641
11. I. Ferreira, K. Wiedemeyer, P. Demetter, D.J. Adams, M.J. Arends, T. Brenn. Update on the pathology, genetics and somatic landscape of sebaceous tumours. *Histopathology*. 2020;76 (5):640-649.  
DOI: 10.1111/his.14044
12. W. Boecker, M. Reusch, V. Mielke, U. Reusch, T. Loening, M. Tiemann, I. Buchwalow. Spatial analysis of p63, K5 and K7 defines two groups of progenitor cells that differentially contribute to the maintenance of normal sebaceous glands, extraocular sebaceous carcinoma and benign sebaceous tumors. *J Dermatol*. 2019;46 (3):249-258.  
DOI: 10.1111/1346-8138.14765
13. N. Kibbi, B. Worley, J.L. Owen, R.C. Kelm, C.K. Bichakjian, S. Chandra, H. Demirci, J. Kim, K.S. Nehal, J.R. Thomas, E. Poon, M. Alam. Sebaceous carcinoma: controversies and their evidence for clinical practice. *Arch Dermatol Res*. 2020;312 (1):25-31.  
DOI: 10.1007/s00403-019-01971-4
14. M. Saliba, M. Shaheen, R.E. Hajj, F. Abbas, S. Bashir, U.N. Sheikh, R. Mahfouz, A. Loya, I. Khalifeh. PD-L1 expression in sebaceous carcinomas. *Cancer immunology, immunotherapy : CII*. 2021;70 (7):1907-1915.  
DOI: 10.1007/s00262-020-02821-3
15. H.E. Stambuk, S.G. Patel. Imaging of the parapharyngeal space. *Otolaryngol Clin North Am*. 2008;41 (1):77-101, vi.
16. Q.L. Cui, S.S. Yin, Z.H. Fan, W. Yang, S. Wang, K. Yan. Diagnostic Value of Contrast-Enhanced Ultrasonography and Time-Intensity Curve in Differential Diagnosis of Cervical Metastatic and Tuberculous Lymph Nodes. *J Ultrasound Med*. 2018;37 (1):83-92.  
DOI: 10.1002/jum.14311



**Fig A** Coronal contrast-enhanced computed tomography scan in neck.



**Fig B** Routine paraffin section and Hematoxylin and Eosin staining of specimen.