

Case report

Are osteoid osteoma and ankylosing spondylitis in some way linked? A case report

Abstract

We present a 35-year-old male, who initially complained of progressive and persistent inflammatory back pain for 2 years, which was diagnosed as a T12 thoracic spine osteoid osteoma. The patient underwent intralesional resection of the tumor via a posterior approach, with immediate post-operative pain relief, and 2 years of pain-free spine interval. Recently, the patient presented with an inflammatory back pain. Visual Analogic Scale (V.A.S) was 7/10 and stiffness, The Back Pain Functional Scale (BPFS) was 30/60, suggesting a recurrence of the spinal osteoid osteoma (OO), diagnosis ruled out giving the negativity of the spine MRI and CT scan. Therefore, an ankylosing spondylitis was suspected, hence, sacroiliac joints MRI was performed, depicting an active bilateral sacroiliitis, confirming the diagnosis of AS according to ASAS criteria. The aim of this paper is to point out similarities between OO and AS and their clinical and probable therapeutic implications. Though few cases of their association have been reported in the literature, both of bone osteoblastic tumors and ankylosing spondylitis (AS) share a number of common features, which let us assuming a possible relationship and therefore, the necessity to assess for sacroiliitis in patients with osteoid osteoma. Differential diagnosis should be considered especially in patients with inflammatory back pain. Moreover, a purely pharmacological approach to the management of OO by the use of biological agents may be considered.

Keywords: osteoid osteoma, osteoblastoma, sacroiliitis, dorsalgia, biological agents

Introduction

At first glance, ankylosing spondylitis (AS) and osteoid osteoma (OO) seem to be totally different diseases. While OO is a small benign bone tumour, it surprisingly can cause a severe pain and even scoliosis. It occurs predominantly in children and young adults. It has a predilection for lower extremities long bones shafts. However, approximately 7-20% of osteoid osteomas involve the spine, (1) with a predilection for posterior elements. Only 12% of osteoid osteoma affect thoracic spine. (2) Usually, presenting symptom is pain that is worse at night and relieved by aspirin. Initial treatment of osteoid osteoma remains nonoperative based on non-steroidal anti-inflammatory drugs. Surgical therapy is the treatment of choice, many options are available ranging from classic open surgery to minimally invasive such as percutaneous excision, laser coagulation, radiofrequency. On the other hand, AS is a chronic inflammatory rheumatic disease, the hallmark manifestation of which is inflammatory back pain, with or without peripheral joints involvement, and a close association with HLA B27. In the literature, few case reports have been published, indicating that Both of OO and AS can clinically or radiologically mimic each other. To the best of our knowledge, only two case reports of bilateral sacroiliitis in association with osteoid osteoma have been reported (3,4). Moreover, in contrast to our case, in all reported cases of OO associated to either sacroiliitis or peripheral joints arthritis, OO was close to the affected joint, while OO in our case was remotely located from the Sacro-iliac joints. Clinical,

radiological and even pathophysiological Similarities may suggest a possible link between them.

Case report

We report a case of a 35 years-old male, who attended our clinic in september 2021, with the complaint of a progressive and persistent inflammatory back pain with a morning stiffness that lasted more than 2 hours, for 6 months. There was no history of trauma or fall, fever, recent infection or weight loss. He denied a family history of arthritis or back pain. However, 2 years back, the patient consulted our clinic for an inflammatory back pain, diagnosed as a T12 right pedicle osteoid osteoma. (Fig.1) Giving the severity of the pain (VAS pain score was 8/10)which interfering with the patient's daily life (BPFS score: 20/60), pedicular location with potential neurological risk; surgical management was decided. It consisted of tumour excision (Fig. 2), with immediate post-operative pain relief and a 2 year-pain-free interval. Histopathological tissue analysis confirmed the diagnosis of osteoid osteoma. Clinical examination showed, a flexible spine with no deformity, negative Schober's test and normal chest expansion. Both sacroiliac joints were tender on palpation with a positive faber 's test. There were no extra articular manifestations (skin, nails, eyes and bowel) nor peripheral joints involvement, enthesitis or dactylitis. Laboratory investigation findings were unremarkable, including a negative HLA B27 antigen. Hence a possible spinal osteoid osteoma recurrence was suspected, diagnosis ruled out giving the negativity of the spine MRI and CT scan. Therefore, an ankylosing spondylitis was suspected, and a sacroiliac joints MRI was performed, depicting an active bilateral sacroiliitis (Fig.3), confirming as per ASAS criteria the diagnosis of AS.

Discussion

Osteoid osteoma is a rare osteoblastic benign bone tumour. Osteoblastoma and osteoid osteoma together are the most frequent benign bone-forming tumor (5). Adolescents and young adults are usually affected in the second decade of life, with most patients being under the age of 20 years. It is less likely to be seen in patients under 5 years of age or in adults greater than 40 years. (6) Males are more commonly affected with an approximate male/female ratio of 2 to 1. (7) which is similar to our patient demographics. The common presentation of OO in a spinal location is a painful scoliosis or an isolated spinal night pain alleviated with the use of aspirin or nonsteroidal anti-inflammatory drugs, (8) as in our case. Ankylosing Spondylitis is a chronic inflammatory rheumatic disease, the hallmark manifestation of which is inflammatory back pain, with or without peripheral joints involvement, and a close association with HLA B27. It usually initially presents during the third decade of life, and rarely after the age of 45 years. The prevalence of AS is generally believed to be between 0.1% and 1.4% globally. (9) The gender ratios is around 2:1 (male: female), (10) which is the same sex-ratio for the OO. CT scan is the gold standard imaging method in the diagnosis of OO, the nidus is usually described as a well-defined round or oval low-density area, surrounded by sclerotic bone changes, ranging from mild cancellous sclerosis to exuberant periosteal reaction. (11) Despite the frequent evidence of osteoporosis, sites of joint and vertebral inflammation in AS patients are characterized by increased local bone formation (12,13). Moreover, AS can cause sclerotic lesions on radiographs and intense uptake in the vertebral bodies at scintigraphy, mimicking osteoblastic bone tumours. In OO, It is thought that this pain is caused by the presence of nerve endings and production of prostaglandins in the nidus (14, 15). The production of prostaglandin may lead to an increase in vascular pressure, which may produce pain by stimulating afferent nerves around the nidus (14). Some authors suggested that synovitis and nonspecific arthritis observed in the OOs located adjacent joints is also due to

prostaglandin release from osteoma. In line with that, Yoji Kawaguchi et al. (16) reported that, initially, COX-2 expression in osteoblasts within the nidus activates the arachidonic acid metabolic pathway and production of prostaglandins, which might induce synovitis in the adjacent synovial tissue. As a result of inflammation, inflammatory cytokines such as IL-1b and TNF alpha further enhance COX-2 expression in the osteoblasts, which amplifies the inflammatory reactions. On the other hand, in their paper, Fischer CP et al. (17) stated that Seronegative spondyloarthritis may also infrequently result in new bone formation and sclerosis simulating osteoblastic skeletal metastasis, they presumed that the sclerosis is a manifestation of reactive new bone formation secondary to osteitis. Inflammatory cytokines, such as IL-17, IL22 and IL-23 play a central role in abnormal bone formation by inducing the differentiation of osteoblasts in AS (18). Abnormal activation of BMPs pathway and Wnt signalling were suggested as well. (19,20) Finally Sungsin Jo et al. (21) provided evidence for crosstalk between osteoblasts and proinflammatory cytokines during inflammation. They demonstrated a correlation between IL-17A concentration and osteoblast differentiation in AS patients' sera and synovial fluid. The aforementioned pathophysiological findings outline multiple common features between OO and AS. In therapeutic terms, it is well known that the pain in both of AS and OO is relieved by non-steroidal anti-inflammatory drugs. Moreover, in OO, the natural history is for regression to occur within 6 to 15 years with no treatment; however, this can be reduced to 2 to 3 years with the use of aspirin and non-steroidal anti-inflammatory drugs. (22) It is also reported for AS that significant percent of patients can reach a spontaneous remission. In our case, Giving the severity of the pain interfering with patient's daily life, pedicular location with potential neurological risk; surgical management was decided. In treated AS patients, remission can occur in up to a third of the patients with axial Spondyloarthritis treated with NSAIDs only, and in approximately half to two-thirds of the patients treated with TNF α inhibitors, especially in those treated in early stages (within first 3–5 years of disease). (23) To the best of our knowledge, only two case reports of bilateral sacroiliitis in association with osteoid osteoma have been reported. The first case was reported by Duman et al. (3) in a 23-year-old male patient, who had been diagnosed and treated initially as bilateral sacroiliitis. CT was performed in order to evaluate the sacroiliac joint space detected coincidentally an osteoid osteoma located adjacent the sacroiliac joint causing pain mimicking sacroiliitis. The second case reported recently by Barta et al. (4) was also of a 23-year-old male patient with low backache and stiffness with lumbar focal scoliosis for one year. Ankylosing spondylitis was highly suspected, then confirmed based on positive HLA B27 and bilateral sacroiliitis on sacroiliac joints MRI. Besides the forementioned changes, an expansile sclerotic lesion in the right posterior neural elements of the L5 vertebra associated with focal scoliotic deformity was revealed. CT-guided biopsy and histopathology confirmed osteoblastoma. However, in contrast to our case, our patient initially presented with a histopathologically confirmed thoracic spine OO, surgically treated with immediate post-operative pain relief, and 2 years of pain-free spine interval, followed by inflammatory back pain and stiffness suggesting a recurrence of the spinal OO. Giving the negativity of the spine MRI and CT scan, a sacroiliac joints CT was performed, depicting bilateral sacroiliitis with joint space narrowing and important subchondral sclerosis of both sacral and iliac opposing articular surfaces, findings confirmed by a sacroiliac joints MRI, which visualized an important bone marrow edema. The HLA B27 test was negative in our patient. Moreover, and interestingly, the OO in our case was remotely located from the Sacro-iliac joints. In the literature, all reported cases of OO associated to either sacroiliitis or peripheral joints arthritis, OO was close to the affected joint (3,4)

Conclusion

In summary, Giving the above findings which outlined multiple similarities, and despite some limitations, such as lack of ability to generalize, difficulty to establish relationship and over-interpretation, we believe that it may be assumed that there is a shared background between AS and OO. Differential diagnosis should be considered especially in patients with inflammatory back pain. In our opinion, the upshot of this, is the necessity to assess for sacroiliitis in patients with osteoid osteoma. Furthermore, the possibility that the management of OO may change toward a purely conservative treatment with the use of biologic DMARDS. We think that our findings might be useful for future studies on the topic in order to establish the link between AS and OO and its diagnostic and therapeutic implications.

Ethical Approval:

As per international standard or university standard written ethical approval has been collected and preserved by the author(s).

Consent

As per international standard or university standard, patients' written consent has been collected and preserved by the author(s).

References

1. Pettine KA, Klassen RA. Osteoid-osteoma and osteoblastoma of the spine. *J Bone Joint Surg Am.* 1986;68(3):354–61.
2. Wani AS, Sahu S, P J. Osteoid osteoma of thoracic vertebra- a case report. *Int J Health Sci Res.* 2016;6(3)
3. Duman İ, Aydemir K, Tan AK, Dinçer K, Kalyon TA. An unusual case of osteoid osteoma clinically mimicking sacroiliitis. *Clin Rheumatol.* 2007;26(7):1158–60.
4. Batra V, Batta NS, Gupta A. Toxic flare phenomenon in osteoblastoma: A case report with literature review. *Indian Journal of Musculoskeletal Radiology.* 2021;0(1):1–5.
5. Amary F, Markert E, Berisha F, Ye H, Gerrand C, Cool P, et al. FOS expression in osteoid osteoma and osteoblastoma: A valuable ancillary diagnostic tool. *Am J Surg Pathol.* 2019;43(12):1661–7.
6. Kitsoulis P, Mantellos G, Vlychou M. Osteoid osteoma. *Acta Orthop Belg.* 2006;72(2):119–25.
7. Ward WG, Eckardt JJ, Shayestehfar S, Mirra J, Grogan T, Oppenheim W. Osteoid osteoma diagnosis and management with low morbidity. *Clin Orthop Relat Res.* 1993;NA;(291):229–35.
8. Tekaya AB, Moalla M, Salah MB, Saidane O, Tekaya R, Hadhri K, et al. Spinal osteoid osteoma revealed by radiculopathy: Case report and literature review. *Int J Spine Surg.*

2021;14(s4):S26–32.

9. Akkoc N. Are spondyloarthropathies as common as rheumatoid arthritis worldwide? A review, *Curr Rheumatol Rep*. Vol. 10. 2008. p. 371–8.
10. Braun J, Sieper J. Ankylosing spondylitis. *Lancet*. 2007;369(9570):1379–90.
11. Gamba JL, Martinez S, Apple J, Harrelson JM, Nunley JA. Computed tomography of axial skeletal osteoid osteomas. *AJR Am J Roentgenol*. 1984;142(4):769–72.
12. Lories RJU, Schett G. Pathophysiology of new bone formation and ankylosis in spondyloarthritis. *Rheum Dis Clin North Am*. 2012;38(3):555–67.
13. Neve A, Maruotti N, Corrado A, Cantatore FP. Pathogenesis of ligaments ossification in spondyloarthritis: insights and doubts. *Ann Med*. 2017;49(3):196–205.
14. Qiao J, Zhu F, Zhu Z, Liu Z, Qian B, Qiu Y. Conservative treatment for osteoid osteoma of the odontoid process of the axis: a case report. *World J Surg Oncol* [Internet]. 2014;12(1). Available from: <http://dx.doi.org/10.1186/1477-7819-12-305>
15. Greco F, Tamburrelli F, Ciabattini G. Prostaglandins in osteoid osteoma. *Int Orthop*. 1991;15(1):35–7.
16. Kawaguchi Y, Sato C, Hasegawa T, Oka S, Kuwahara H, Norimatsu H. Intraarticular osteoid osteoma associated with synovitis: A possible role of cyclooxygenase-2 expression by osteoblasts in the nidus. *Mod Pathol*. 2000;13(10):1086–91.
17. Fischer CP, Emary PC, Taylor JA. Presumptive late-onset ankylosing spondylitis simulating osteoblastic skeletal metastasis in a patient with a history of prostate carcinoma: A diagnostic challenge. *J Chiropr Med*. 2015;14(4):259–64.
18. Baum R, Gravalles EM. Bone as a target organ in rheumatic disease: Impact on osteoclasts and osteoblasts. *Clin Rev Allergy Immunol*. 2016;51(1):1–15.
19. Chen H-A, Chen C-H, Lin Y-J, Chen P-C, Chen W-S, Lu C-L, et al. Association of bone morphogenetic proteins with spinal fusion in ankylosing spondylitis. *J Rheumatol*. 2010;37(10):2126–32.
20. Lories RJU, Derese I, Luyten FP. Modulation of bone morphogenetic protein signaling inhibits the onset and progression of ankylosing enthesitis. *J Clin Invest*. 2005;115(6):1571–9.
21. Jo S, Wang SE, Lee YL, Kang S, Lee B, Han J, et al. IL-17A induces osteoblast differentiation by activating JAK2/STAT3 in ankylosing spondylitis. *Arthritis Res Ther* [Internet]. 2018;20(1). Available from: <http://dx.doi.org/10.1186/s13075-018-1582-3>
22. Boscainos PJ, Cousins GR, Kulshreshtha R, Oliver TB, Papagelopoulos PJ. Osteoid osteoma. *Orthopedics*. 2013;36(10):792–800.
23. Poddubnyy D, Gensler LS. Spontaneous, drug-induced, and drug-free remission in peripheral and axial spondyloarthritis. *Best Pract Res Clin Rheumatol*. 2014;28(5):807–18.

UNDER PEER REVIEW

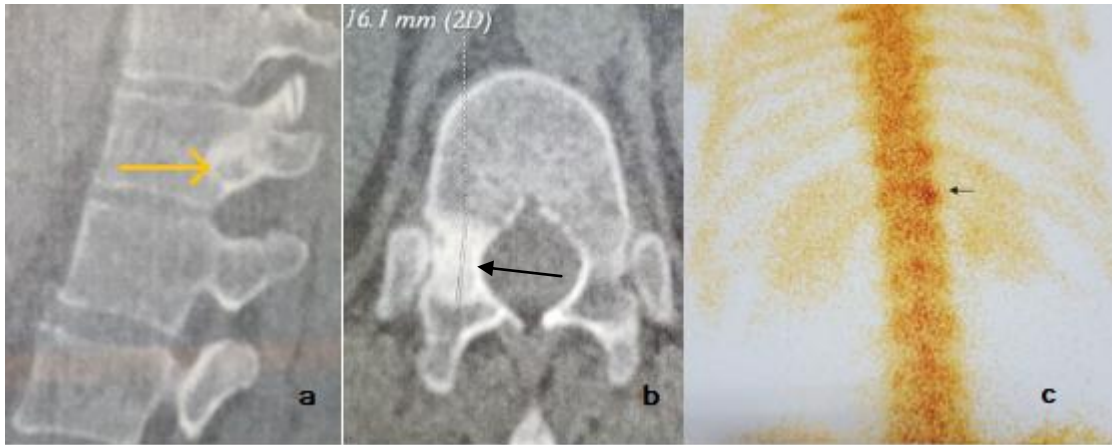


Figure 1: Thoracic spine CT scan (A&B) show a right pedicular small osteolytic lesion surrounded by a sclerotic (arrow) reaction. Bone scan (C) shows hyper-fixation of the right T12 vertebra region (arrow)

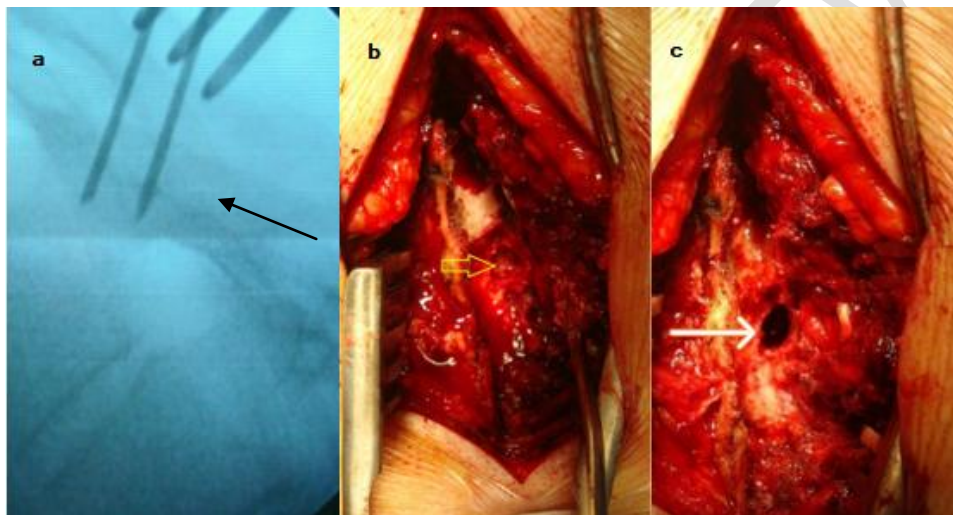


Figure 2: Surgical management, localization (a) , incision (b) and excision(c) of the osteoid osteoma (arrow)

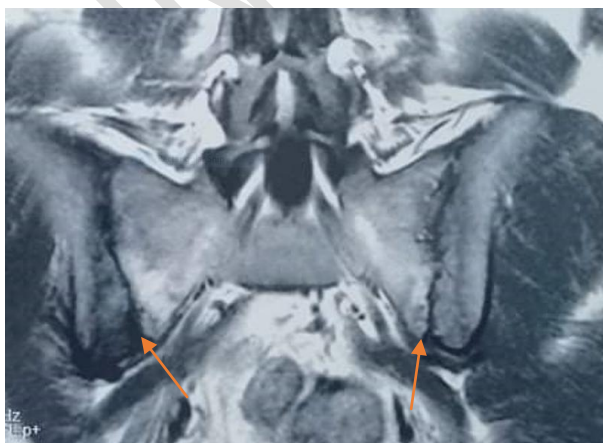

Figure 3: Sacroiliac joints MRI showing a bilateral active sacroiliitis (arrow)

UNDER PEER REVIEW