

Case study

Gastrointestinal stromal tumor (GIST): Case Study

Abstract

A 38-year-old male presented with a complaint of upper GIT bleeding. The patient is an alcoholic and a smoker for the last 5 years. The patient had vomited blood for the last three days. Endoscopy, Biopsy, Esophagogastroduodenoscopy and CT scan of abdomen and pelvis with IV contrast were recommended. After initial examination and reports, the patient was diagnosed with Gastrointestinal Stromal Tumor. Gastrointestinal stromal tumor was found that was spindle cell type, unifocal and low grade with mitotic speed of 2-3 /5 mm². The tumor originated in the gastric submucosa and spread to the pericolic fat omentum. The tumor was large, being 9.5cm cm and 6.5 x 5.5 cm in greatest dimension measurements. The tumor measured more than 5 cm, but was less than 10 cm in diameter. The overlying gastric mucosa showed focal mild chronic inflammation. *Helicobacter pylori* and focal intestinal metaplasia was noted. As a treatment for gastrointestinal stromal tumor, surgery was recommended to remove the large exophytic gastric mass. After surgery, heterologous fragments were received. The mass of the tumor was 0.8cm with a mitotic rate of 2-3 /5 mm² per 10 high-power fields (HPF). The examination and diagnosis also included some special studies such as immunohistochemistry assay. However, no mutational analysis test was performed. Immunohistochemistry assay was positive for C-KIT (CD117), CD34 and DOG1.

Keywords: GIT bleeding; Gastrointestinal Stromal Tumor; Intestinal metaplasia; Immunohistochemistry

INTRODUCTION

Gastrointestinal stromal tumor (GIST) is the term applied to the group of morphologically spindle cells,⁽¹⁾ or mesenchymal tumors of the gastrointestinal tract and abdomen.⁽²⁾ It was first introduced by Mazur and Clark.⁽²⁾ These tumors are the result of a mutation of the gene encoding for type III receptor tyrosine kinase.⁽³⁾ These tumors are KIT positive and the main reason for the GIST pathogenesis is the signal transduction of pathologically active kit. The activated kit leads to the cellular proliferations. GISTs tumors detected by immunohistochemistry uniformly express kit protein.

The KIT-positive Cajal cells and GIST shares a phenotypic similarity. On the basis of histological and immunohistochemical similarities the Gastrointestinal autonomic nerve tumors (GANTs) are called as ultrastructural variants of GIST.⁽⁴⁾

Patients suffering from GIST usually present with symptoms like fatigue and dyspepsia. The upper gastrointestinal bleeding and has been reported in multiple cases. Aggressive types of GIST not only metastasize to the liver but also to the lung and bone in advanced cases.⁽⁵⁾

GISTs tumors vary greatly in size ranging from 0.6 to 25.5cm. GISTs tumors median size is 6.8cm. Usually tumor size range from 5-10 cm. GISTs tumors having size larger than 5cm are included in large GIST group.

GIST can present in the soft tissues of the GI-tract from the lower esophagus to the anus. The most common site of occurrence of GIST is the far stomach and small intestine. The probability of GISTs in the esophagus and appendix is very low. Cases of hereditary GISTs are rare while sporadic GISTS are more common.⁽⁶⁾

Though there are no specific symptoms for GISTs, but abdominal pain, nausea, vomiting, loss of weight or appetite and anemia are the most common presentations of GISTs. So it is not wrong to conclude that GISTs are diagnosed by incidental findings usually done for other examinations. Imaging studies are performed, if the GISTs are suspected. The probability of middle-aged people being affected by GIST is low in comparison to people of old age (60-70 years).⁽⁷⁾

In order to treat GIST with specific kit tyrosine kinase inhibitor imatinib, the identification of GIST site of occurrence is necessary.⁽⁸⁾

CASE PRESENTATION

History and Initial Examination

A 38-year-old male presented with the complaint of upper GIT bleeding. The patient had a complaint of vomiting blood from the past three days. He was suffering from abdominal pain and Shortness of breath. The Hemoglobin units 8.7 g/dl. Ultrasound showed epigastric mass. The patient is an alcoholic and a smoker for the last 5 years. Endoscopy, Biopsy, Esophagogastroduodenoscopy and CT Abdomen/Pelvis with IV Contrast were recommended and reports showed the following results.

Table 1: History and Initial Examination

1	Esophagogastroduodenoscopy	Normal esophagus, fundal gastric mass with two large white base ulcers and clots, no active bleeding was observed. CLO test was positive and duodenal mucosa (D1+D2) was intact .
2	CT Abdomen/Pelvis with IV Contrast	There is a large oval, exophytic, submucosal soft tissue mass lesion, measuring about 11.1cm, CC x 6.8 cm, ML

		<p>x 5.5cm, AP, arising from the lesser curvature of the stomach, showing moderate heterogeneous enhancement, in post-contrast scan with central low attenuating areas (suggest necrosis). It shows some linear calcification peripherally. The mass extends inferiorly between the stomach and pancreas and compresses the body of the pancreas, posteriorly. There is a breach of the overlying mucosa of the stomach, at some area of the stomach-tumour interface, measuring about, 2.0 x 1.7cm (suggestive of ulcer crater). In the arterial phase, the bed of ulcer crater shows some enhancement.</p> <p>No regional or abdominal lymphadenopathy was observed.</p> <p>Differential diagnosis: Gastric lymphoma (unlikely in absence of lymphadenopathy)/ Leiomyoma.</p> <p>Enhancement at the bed of the ulcer crater, in the arterial phase, may suggest active bleeding/ associated inflammatory hyperemia. As the patient has a history of hematemesis, clinical correlation is highly important.</p> <p>Mildly dilated jejunal loops on the left side were observed.</p>
3	CT of the Thorax with Contrast	<p>Tiny, calcified granuloma were observed at the right lung base and minimal fibrotic bands at the posterior basal</p>

		<p>segments of lower lung lobes bilaterally as well as A few calcific foci at the right paratracheal and right perihilar regions likely old calcified lymph nodes. There was no evidence of lung parenchymal collapse/consolidation or over inflation and no significant perihilar or mediastinal lymphadenopathy. The bony thorax was unremarkable.</p>
--	--	--

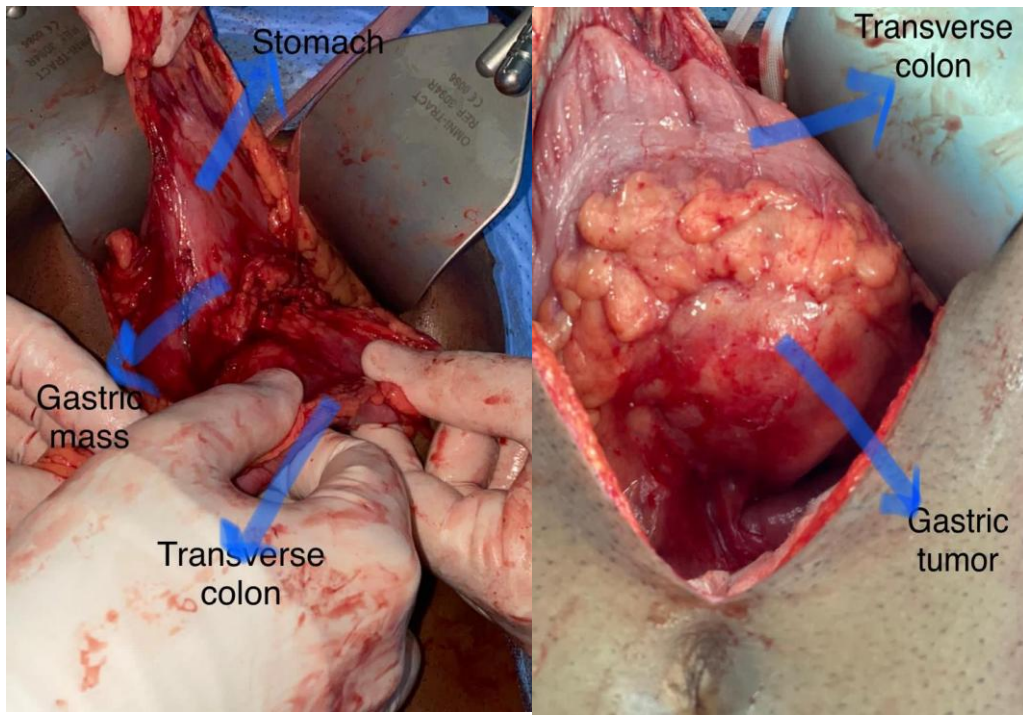


Figure 1: Gastrointestinal tumor

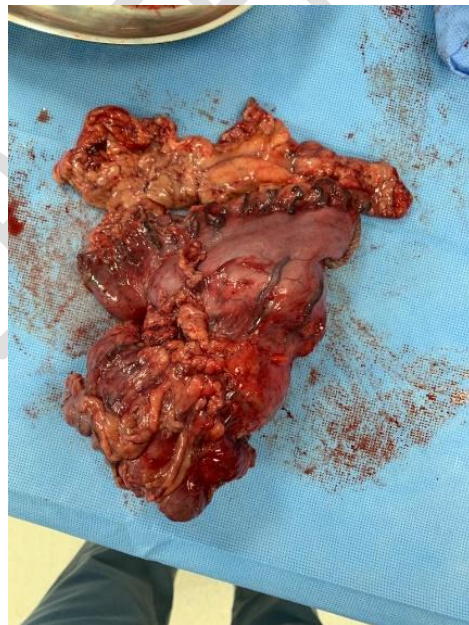

Figure 2: Gastric mass obtained after surgical excision.

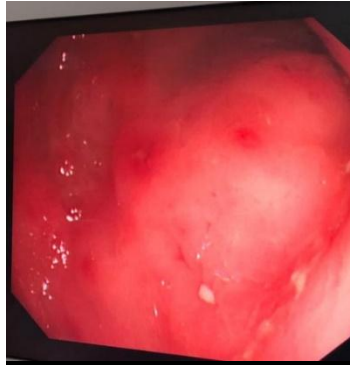


Figure 3: Endoscopic view of the stomach

Diagnosis:

After initial examination and reports, the patient was diagnosed with a gastrointestinal stromal tumor.

A.Gastric mass infiltrating the transverse colon:

The low-grade spindle cell type tumor is seen arising in the lesser curvature of the stomach in the submucosa of the gastric wall and infiltrates the pericolic fat, but invasion of the transverse colonic muscularis propria or mucosa is not seen. Both proximal and distal resection margins of the stomach and transverse colon are free of tumors. No lymphovascular or perineural invasion is identified. The separate pieces of omentum are unremarkable. The tumor has a greatest dimension of 9.5 cm and Additional dimensions of: 6.5 x 5.5 cm. The primary tumor was more than 5 cm but not more than 10 cm was diagnosed.

Table 2: Histopathology:

Condition	Gastrointestinal stromal tumor GIST
Source	Gastric mass infiltrating the transverse colon
Exophytic mass	9.5 x 6.5 x 5.5 cm
Tumor mass from proximal gastric margin	0.8cm
Tumor mass from distal duodenal margin	2cm
Ulceration in inner wall of stomach	1cm
Colon segment	7.5 cm x 3.5 cm

Macroscopic examination of the specimens showed that

- Partial gastrectomy with mass at the outer surface and part of bowel segment adhered to the mass.
- The stomach measures 10 x 6.5 x 3.5 cm with a part of omental fat attached measuring 8 cm in distance from the stomach wall.
- There is an exophytic mass attached to the stomach wall along the lesser curvature measuring 9.5 x 6.5 x 5.5 cm, inked black from the outer surface.
- Ulceration like area in the inner wall of the stomach measures about 1 cm in maximum diameter noted at the site of the mass.
- The tumor mass is 0.8 cm from the proximal gastric margin and 2 cm from the distal duodenal margin.
- The mass appears to be infiltrating the pericolic fat but not the colon mucosa

- Proximal and distal margins are negative.
- The overlying gastric mucosa shows focal mild chronic inflammation. *H.pylori* and focal intestinal metaplasia is noted.

Treatment:

As a treatment for the gastrointestinal stromal tumor, surgery was recommended to remove the mass.

Subtotal gastrectomy with en bloc resection of the invaded part of transverse colon, with Roux gastrojejunostomy and colostomy to restore GI tract continuity.

Table 3: Case Summary (Soft Tissue Resection):

Pre resection Treatment	No known pre resection treatment
Procedure	Partial gastrectomy with part of transverse colon
Tumor focality	Unifocal
Tumor site	Lesser curvature of stomach
Tumor size	Greatest dimension: 9.5 cm + Additional dimensions: 6.5 x 5.5 cm
Histologic type	Gastrointestinal stromal tumor, spindle cell type
Histologic grade	G1: Low grade
Mitotic Rate	Specify: 2-3 /5 mm ²
Necrosis	Absent
Distant Metastasis (pm)	Not Known

Margins	Proximal and distal margins are negative
Regional lymph nodes	Number of Lymph Nodes Involved: 0 Number of Lymph Nodes Examined: 10
Risk Assessment	Low risk
Regional lymph nodes (pN)	pN0: No regional lymph node metastasis
Distant Metastasis	Not applicable
Molecular Genetic Studies (eg, <i>KIT</i> or <i>PDGFRA</i> mutational analysis)	Not performed
Pathological staging pTNM	pT3: Tumor larger than 5 cm but not more than 10 cm
Regional Lymph Nodes (pN)	pN0: No regional lymph node metastasis

Special studies

Some special studies such as immunohistochemistry assays are performed for examination and diagnosis of tumor. However, no cytogenetics and molecular pathology test was performed.

Table 4: Immunohistochemistry profile

C-KIT (CD117)	Positive
CD34	Positive
DOG1	Positive
CKAE1/AE3	Negative

Desmin	Negative
S100	Negative
S100	Negative

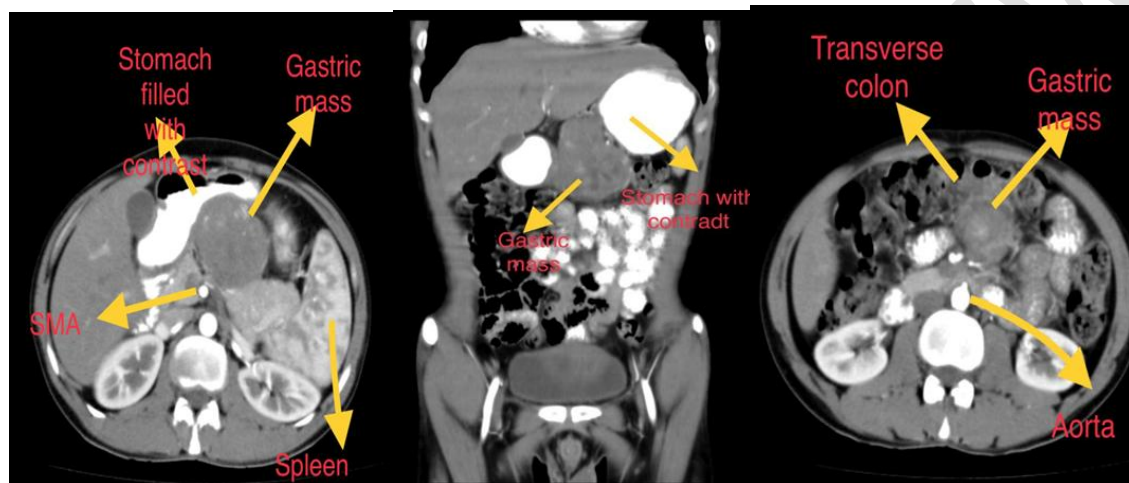


Figure 4: Radiological finding in the CT scan

DISCUSSION

GISTs were originally viewed as smooth muscle tumor (leiomyoblastomas).⁽⁸⁾ They either arise from the interstitial cells of Cajal (ICCs) or ICC precursor cells. The morphologic, and immunohistochemical, features of GISTs are very similar to ICCs.⁽⁹⁾

Because of increasing diagnostic reliability of the GISTs they are considered to be the most common human sarcomas.⁽¹⁰⁾ The annual incident of GISTs in a population-based study estimated is to be 10 cases in one million.⁽¹¹⁾ GISTs effect people of all ages but with highest number of people of 64-year-old.⁽¹⁰⁾

A case of 62-year-old man having GIST tumor of size of 4.5cm was reported. The symptoms were abdominal pain, anemia, nausea and palpable mass in abdomen.

GISTs can consist of spindle cell in 70% cases, epithelioid cells in 20% cases and a combination of both in 10% cases. ⁽¹¹⁾ Spindle cell GISTs usually arrange in the form of fascicles while, epithelioid GISTs arrange in a sheetlike pattern. ⁽¹²⁾

A case of 47-year-old man with gastric tumor of size 10cm was reported. The symptoms were similar to the above reported case. The tumor also constituted the large gastrointestinal stromal tumor group.

Immunohistochemistry assays of GISTs are usually positive (CD117, c-kit). ⁽⁶⁾ Normally in 99% of the cases of GISTs the DOG1 expressed. This assay is specific to the GISTs diagnosis and confirmation. ⁽¹³⁾ This reported case is also about a complaint of gastrointestinal stromal tumor in 38-year-old male. In the reported case, the C-KIT, DOG1 and CD34 gave positive results. The spindle cell gastrointestinal tumor arising from submucosa of gastric wall growing and infiltrating into the pericolic fat and partially indenting the opposing pancreatic body and tail portion without apparent pancreatic parenchymal changes. For non-metastatic lesions, the surgery is considered to be the standard therapy. ⁽¹⁴⁾ Normal GISTs tumor size ranges from 0.78 to 5.6cm. In this case the tumor was of unusual size of 9.5cm with additional dimensions of 6.5 x 5.5 cm. This tumor constituted the large GIST group. In case of metastatic or large sized lesions with pain and bleeding the therapy, imatinib mesylate is suggested before surgical interventions.

(13)

CONCLUSION

The case represents the presence of gastrointestinal stromal tumor in a 38-year-old patients. The gastrointestinal tumor in this case is 9.5cm at the largest dimension. The patient was suffering from abdominal pain and upper GIT bleeding. The primary tumor of the gastric submucosa was diagnosed.

CONSENT

As per international standard or university standard, patients' written consent has been collected and preserved by the author(s).

ETHICAL APPROVAL

As per international standard or university standard written ethical approval has been collected and preserved by the author(s).

COMPETING INTERESTS

Authors have declared that no competing interests exist.

REFERENCES

1. Saund, Mandeep S.^a; Demetri, George D.^b; Ashley, Stanley W.^a Gastrointestinal stromal tumors (GISTs), Current Opinion in Gastroenterology: March 2004 - Volume 20 - Issue 2
- p 89-94

2. Miettinen M, Majidi M, Lasota J: Pathology and diagnostic criteria of gastrointestinal stromal tumors (GISTs): A review. *Eur J Cancer* 2002, 38(suppl 5):S39–S51.
3. Davila RE, Faigel DO: GI stromal tumors. *Gastrointest Endosc* 2003; 58:80–88. A nice summary of the current status of endoscopic diagnosis and therapy for GISTs.
4. Joensuu H, Fletcher C, Dimitrijevic S, et al.: Management of malignant gastrointestinal stromal tumours. *Lancet Oncol* 2002, 3:655–664. Very complete review on all aspects of GISTs
5. Stroobants S, Goeminne J, Seegers M, Dimitrijevic S, Dupont P, Nuyts J, *et al.* 18FDG-Positron emission tomography for the early prediction of response in advanced soft tissue sarcoma treated with imatinib mesylate (Glivec). *Eur J Cancer* 2003; **39**: 2012– 20
6. Miettinen, M., & Lasota, J. (2003). Gastrointestinal stromal tumors (GISTs): definition, occurrence, pathology, differential diagnosis and molecular genetics. *Pol J pathol*, 54(1), 3-24.
7. Sugiyama, Y., Sasaki, M., Kouyama, M., Tazaki, T., Takahashi, S., & Nakamitsu, A. (2022). Current treatment strategies and future perspectives for gastrointestinal stromal tumors. *World Journal of Gastrointestinal Pathophysiology*, 13(1), 15.
8. Papke, D. J., Forgó, E., Charville, G. W., & Hornick, J. L. (2022). PDGFRA immunohistochemistry predicts PDGFRA mutations in gastrointestinal stromal tumors. *The American Journal of Surgical Pathology*, 46(1), 3-10.
9. Du, C., Chai, N., Linghu, E., Li, H., Zhai, Y., Li, & Tang, P. (2022). Clinical outcomes of endoscopic resection for the treatment of gastric gastrointestinal stromal tumors originating from the muscularis propria: a 7-year experience from a large tertiary center in China. *Surgical Endoscopy*, 36(2), 1544-1553.

10. Steigen, S. E., & Eide, T. J. (2009). Gastrointestinal stromal tumors (GISTs): a review. *Apmis*, 117(2), 73-86.
11. Roberts, P. J., & Eisenberg, B. (2002). Clinical presentation of gastrointestinal stromal tumors and treatment of operable disease. *European journal of cancer*, 38, S37-S38.
12. Menge, F., Jakob, J., Kasper, B., Smakic, A., Gaiser, T., & Hohenberger, P. (2018). Clinical presentation of gastrointestinal stromal tumors. *Visceral Medicine*, 34(5), 335-340.
13. Chung, J. C., Chu, C. W., Cho, G. S., Shin, E. J., Lim, C. W., Kim, H. C., & Song, O. P. (2010). Management and outcome of gastrointestinal stromal tumors of the duodenum. *Journal of Gastrointestinal Surgery*, 14(5), 880-883.
14. Goh, B. K., Chow, P. K., Chok, A. Y., Chan, W. H., Chung, Y. F. A., Ong, H. S., & Wong, W. K. (2010). Impact of the introduction of laparoscopic wedge resection as a surgical option for suspected small/medium-sized gastrointestinal stromal tumors of the stomach on perioperative and oncologic outcomes. *World journal of surgery*, 34(8), 1847-1852.

Anwar Kamel Adwan¹, Ashraf ALakkad², Fadi Bassam Almahameed³, Maher Fahd Hejazee⁴

^{1 2}Department of Internal Medicine, Madinat Zayed Hospital, UAE

^{3 4}Department of General Surgery, Madinat Zayed Hospital, UAE.

^{1 3}Consultant and Head

*Corresponding author: Dr.Ashraf ALakkad

Email: ashraf.alagqad@gmail.com

UNDER PEER REVIEW