

Case report

DIRECT SINUS LIFT WITH PIEZOSURGERY

ABSTRACT

Piezosurgery is an alternative technique over conventional oral surgical procedure which is gained popularity in the field of dentistry. It's a minimally invasive procedure that reduces the chance of harming soft tissues and vital systems including nerves, blood vessels, and mucosa. This device is utilised in operations such as osteotomies, periodontology, and implantology, as well as oral surgical procedures and sinus augmentation. The salient feature of peizosurgery includes bone cutting without damage to the surrounding soft tissues with sufficient visibility in the operating field without generation of heat. This case report illustrates its use in the direct sinus lift procedure.

KEYWORDS: Peizosurgery, Direct sinus lift, Osteotomy, Bone healing

INTRODUCTION:

The maxillary and mandibular teeth are commonly associated with endodontic and periodontal problems and are often lost first. Following extraction there is residual alveolar ridge resorption. In the maxilla, pneumatisation of sinus may be often seen following tooth extraction. This leads to poor bone quality and reduced bone height posing a challenge in restoration of the tooth using implants with subsequent requirement of bone graft.

Sinus lift procedure in posterior maxilla is one of the most important procedures in Implantology to facilitate implant placement in patients with reduced bone height. Tatum first described the elevation of the maxillary sinus floor in 1976, and Boyne published it in 1980 [1, 2]. There are 2 important approaches to elevate the maxillary sinus floor. The first approach includes lateral antrostomy, which is the most definitive and the frequently performed technique. Summers advocated the crestal approach, using osteotomes [3]. Pal concluded that there was significant gain in bone height in lateral antrostomy approach (mean 8.5mm) than in crestal approach performed by osteotome method (mean 4.4 mm) [4].

One of the most common complications following maxillary sinus augmentation is Schneiderian membrane perforation. The conventional approach involves the use of rotary instruments during osteotomy risking the membrane perforation [5, 6], followed by hand instruments during manual elevation. However, piezosurgery as proposed by Torella [7] and Vercelotti [8] can be used for osteotomy and membrane floor elevation. Piezoelectric devices uses low-frequency ultrasonic vibrations for osseous surgeries that are designed to cut bony structures precisely without damaging the soft tissues [9].

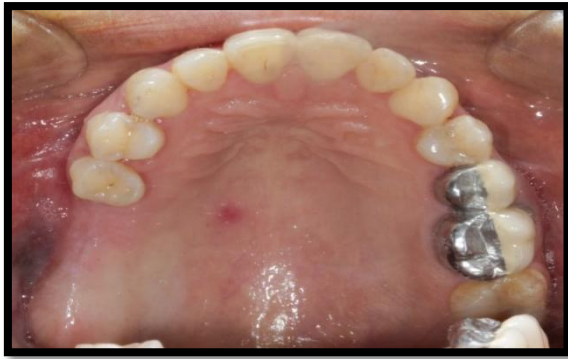These devices usually has a handpiece and foot control unit that are connected to the main power unit. The handpiece has a holder which contains irrigation fluids that create an adjustable jet of 0–60 ml/min because of peristaltic pump attached to it. The debris are removed from cutting area maintaining a clean blood free operating field due to cavitation (production of imploding bubbles). Thus providing adequate visibility in the area [10]. This device offers three specific therapeutic features. Initially, it offers micrometric sectioning, favoring precise cutting with no loss of bone. Later, it selectively sections mineralized bone, without damaging the soft tissues surrounding the bone. Finally, this device ensures less bleeding due to physical cavitation [11].

This case report presents the direct sinus lift procedure of maxillary posterior edentulous region using Acteon Piezotome Cube and Acteon tips ®. The aim of this clinical case report is to show the use of piezosurgery in direct sinus lift procedure.

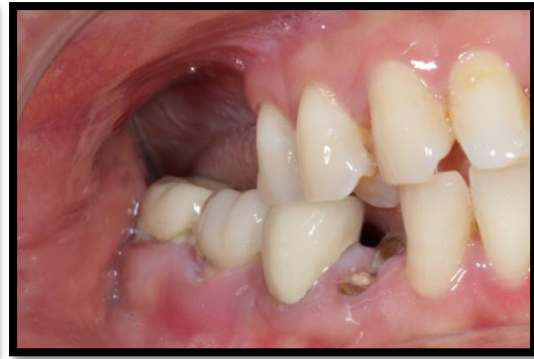CASE DESCRIPTION:

A female patient, aged 48 years reported to the hospital with chief complaint of missing teeth in upper right and left lower back teeth region and difficulty in chewing. She wanted to replace them with fixed artificial teeth. History revealed that the teeth were extracted due to caries 4 years back. She was systemically fit and had no history of chronic sinusitis or long standing nasal obstruction and no other deleterious oral habits.

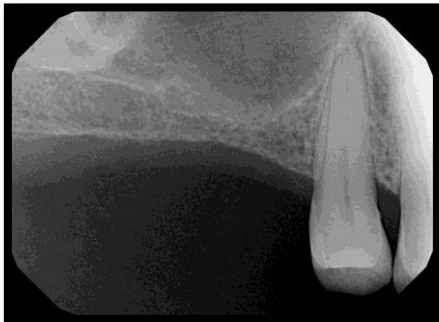On clinical examination, teeth no 16, 17 were missing [Figure 1, 2] with well healed bony ridges. RVG, OPG and CBCT findings showed that the bone height was 4mm in 16 & 17 region and was insufficient to place implant. [Figure 3, 4, 5] Therefore, Lateral osteotomy was planned with two stage surgery followed by implant placement. Informed consent was obtained after discussing the planned procedure from the patient. Blood investigations were done.



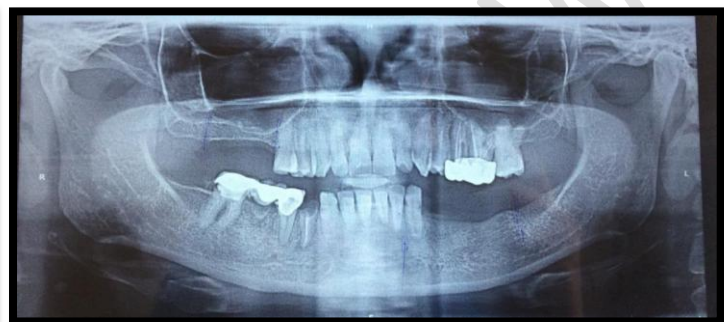[Figure 1]



[Figure 2]



[Figure 3]



[Figure 4]

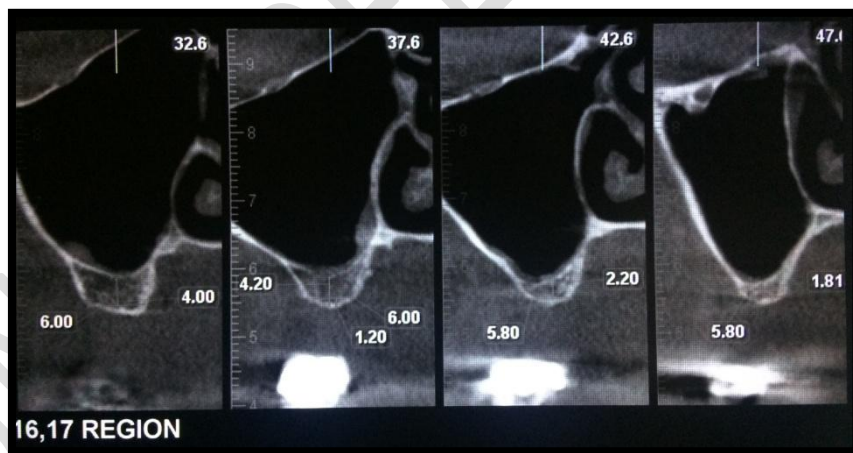
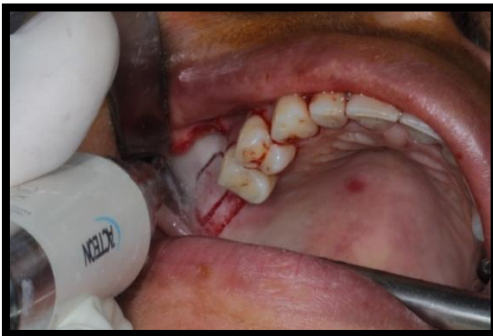

Fig. 1-5. clinical examination

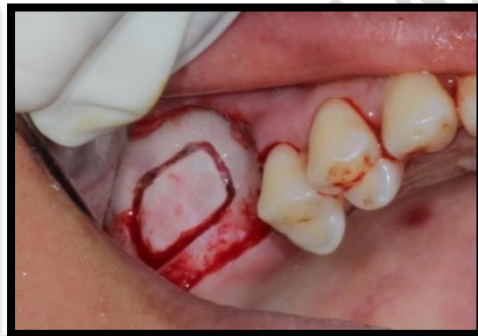SURGICAL PHASE:

Local anesthesia of 2% lignocaine with 1:80,000 adrenaline was given in the right maxillary posterior region. An incision was given using #15 surgical blade extending from the distal surface of premolar to the maxillary tuberosity region. A vertical incision was placed from

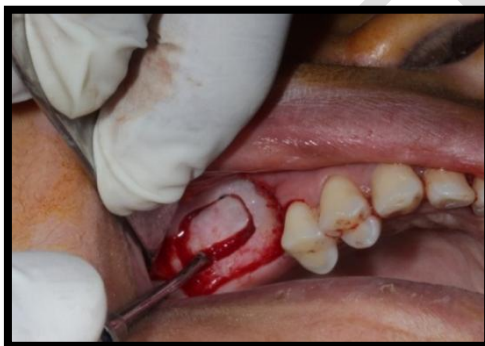premolar to the sulcus. A full thickness buccal flap was reflected, and a bony window was traced using Acteon Piezotome Cube ® and Acteon tips. The initial bone marking was done using tip #BS5. This was followed by the deepening with SL1 tip [Figure 6]. The bone was traced till a very thin plate of buccal bone remained over the sinus lining [Figure 7]. The lining in the vicinity of the bony window was partially raised and lifted using the SL3 tip. The sinus floor was elevated using sinus floor elevators [Figure 8]. The space between bone and sinus lining was filled with PRF (Platelet rich fibrin) and a collagen membrane was placed on top [Figure 9, 10].



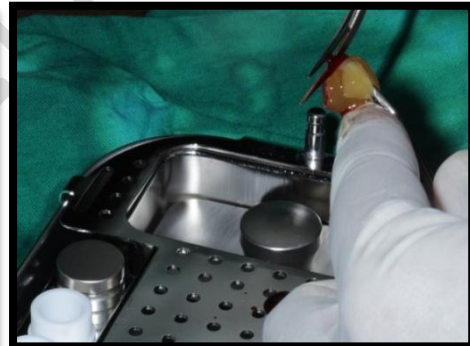[Figure 6]



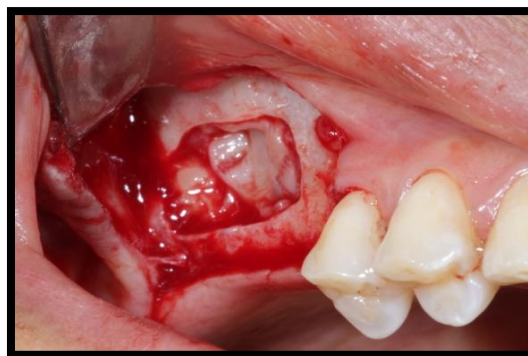
[Figure 7]



[Figure 8]

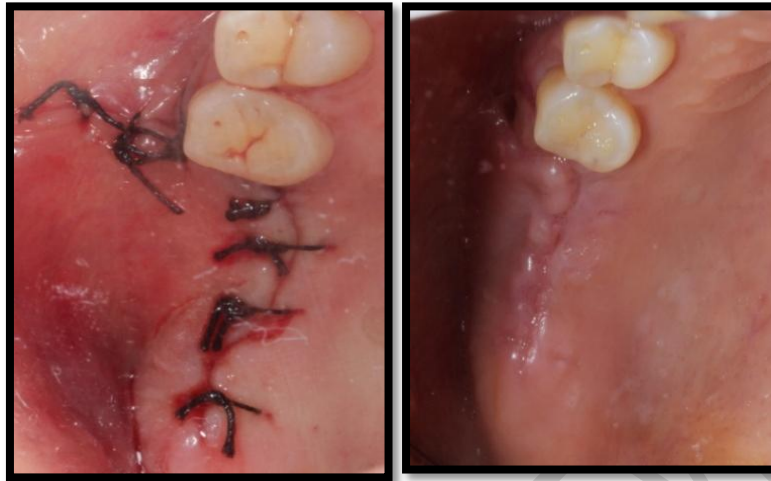


[Figure 9]



[Figure 10] Figure 6-10: bone tracing

Flaps were approximated, and sutured with 3-0 silk [Figure 11]. Postoperative instructions were given to the patient with antibiotic and anti-inflammatory coverage. The patient was recalled after 7 days for evaluation and suture removal [Figure 12].



[Figure 11]

[Figure 12]

Figure 11,12: sutured structure

Postoperative assessment of following parameters was done after 1week [Table 1& 2].

Pain (by Visual Analogous Scale) [Table 1].

0	No pain
1-3	Mild pain
3-7	Moderate pain
7-10	Severe pain

Gingival inflammation status: Gingival index [Table 2].

0	No inflammation
1	Mild inflammation
2	Moderate inflammation
3	Severe inflammation

- Swelling (Present/Absent)
- Complication – If any

Postoperatively the patient reported no pain or any inconvenience during the healing period.

On the VAS, score 0 was recorded. Patient took analgesics for only two days. Gingival Index of the surgical site was 0- no inflammation. There was excellent wound healing, with no swelling or nerve and soft tissue injuries. Post-op CBCT was obtained after 6 months showed 2mm increase of bone height from the original 4mm [Figure 13].

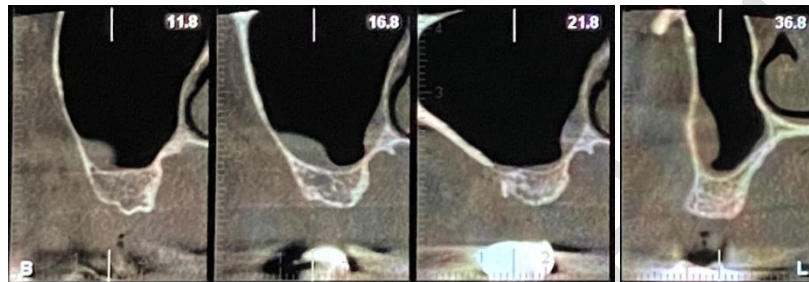


Figure 13: Soft tissue injuries

DISCUSSION:

Iatrogenic perforation of sinus floor is greater with the use of rotary instruments. Piezosurgery instrument does not cut the soft tissues had made the surgery easy. It provided a clear vision in our mind as well as on the site due to the bloodless field.

Piezosurgery was easy to operate because it was similar to ultrasonic scaler, it is highly precise and safe during cutting of hard tissue, the hand piece was light in weight the LED light was very convenient in accessing the site during the procedure as there was no need to adjust the light of the dental chair. The selective and thermally harmless nature of Acteon piezotome cube resulted in a low bleeding with clean and smooth cut during surgery.

The complications associated with the use of mechanical instruments such as high temperature even for a short period of time is detrimental to the cells as the regenerative process of these vital structures will be impaired [12].

In their study, Chiriac et al. discovered that using piezoelectric surgery speeds up the healing process and lowers inflammatory reactions while the graft is healing, which aids in maintaining the live bone tissue after it has been transplanted [13]. With the rotational technique and ultrasonography, Pearrocha-Diago discovered perforations of Schneider's

membrane in 7% and 1.7 percent of the patients, respectively, with membrane integrity intact in 91.2 percent. The rotary method resulted in a 5.9 mm bone gain compared to 6.7 mm with ultrasound [14]. Literature shows controversial opinions regarding the osteogenic ability of PRF. PRF alone is mainly used for treatment of maxillary sinus augmentation, intrabony defects (IBD), and tooth extraction. Some studies concluded that PRF alone can improve bone formation, but many scientists doubted this finding [15]. Our case findings showed a bone gain of 2mm only in the augmented region and this is insufficient for implant placement. Thus we advocate the use of bone graft with PRF for better osteogenic potential.

Harder examined the bone-cutting performance and intraosseous temperature of three current ultrasonic bone surgery equipment and discovered that the Piezotome and Piezosurgery II outperformed the SurgiSonic substantially. The Piezotome caused the least amount of intraosseous warmth to rise [16].

Delilbasi discovered that a sinus lifting treatment using Piezosurgery generates less postoperative pain and swelling than a conventional approach [17].

CONCLUSION:

Piezosurgery aims in reducing the intraoperative and post-operative complications, and increases the patient's comfort and efficiency of the novice operator. We feel that Piezosurgery with its ease of superior precise cutting and exclusive targeting of hard tissue, its use must be recommended to more complex surgical cases and be an essential instrument of every dental operator.

DISCLAIMER:

Authors have declared that no competing interests exist. The products used for this research are commonly and predominantly use products in our area of research and country. There is absolutely no conflict of interest between the authors and producers of the products because we do not intend to use these products as an avenue for any litigation but for the advancement of knowledge. Also, the research was not funded by the producing company rather it was funded by personal efforts of the authors.

Consent

As per international standard or university standard, patients' written consent has been collected and preserved by the author(s).

REFERENCES:

1. Tatum JH. Maxillary and sinus implant reconstructions. *Dental Clinics of North America*. 1986 Apr; 30(2):207-229.
2. Boyne PJ, James RA. Grafting of the maxillary sinus floor with autogenous marrow and bone. *Journal of Oral Surgery* 1980 Aug 1; 38(8):613-616.
3. Woo I, Le BT. Maxillary sinus floor elevation: review of anatomy and two techniques. *Implant dentistry*. 2004 Mar 1; 13(1):28-32.
4. Pal US, Sharma NK, Singh RK, Mahammad S, Mehrotra D, Singh N, Mandhyan D. Direct vs. indirect sinus lift procedure: A comparison. *National Journal of Maxillofacial Surgery*. 2012 Jan 1; 3(1):31-37.
5. van den Bergh J, ten Bruggenkate C, Krekeler G, Tuinzing D. Sinusfloor elevation and grafting with autogenous iliac crest bone. *Clinical Oral Implants Research*. 1998 Dec; 9(6):429-435.
6. Kasabah S, Krug J, Simunek A, Lecaro MC. Can we predict maxillary sinus mucosa perforation?. *Acta Medica (Hradec Kralove)*. 2003 Jan 1; 46(1):19-23.
7. Torrella F, Pitarch J, Cabanes G, Anitua E. Ultrasonic osteotomy for the surgical approach of the maxillary sinus: a technical note. *The International Journal of Oral & Maxillofacial Implants*. 1998 Sep 1; 13(5):697-700.
8. Vercellotti T, De Paoli S, Nevins M. The piezoelectric bony window osteotomy and sinus membrane elevation: introduction of a new technique for simplification of the sinus augmentation procedure. *International Journal of Periodontics and Restorative Dentistry*. 2001 Dec 1; 21(6):561-568.
9. Eggers G, Klein J, Blank J, Hassfeld S. Piezosurgery: an ultrasound device for cutting bone and its use and limitations in maxillofacial surgery. *The British Journal of Oral & Maxillofacial Surgery*. 2004 Oct 1; 42(5):451-453.
10. Deepa D, Jain G, Bansal T. Piezosurgery in dentistry. *Journal of Oral Research and Review*. 2016 Jan 1;8(1):27-.27.

11. Gupta SJ, Gupta A, Gautam V, Nangia R, Verma P. Stipulative Interdisciplinary Approach Of Piezosurgery In Modern Dentistry. J Pharm Biomed Sci 2015; 05(08):624-631.
12. Srinivasan S, Ganapathy D, Jain AR. Applications of piezoelectric surgery in dentistry. Drug Invention Today. 2019 Jan 1; 11(1):122-125.
13. Chiriac G, Herten M, Schwarz F, Rothamel D, Becker J. Autogenous bone chips: influence of a new piezoelectric device (Piezosurgery®) on chip morphology, cell viability and differentiation. Journal of clinical periodontology. 2005 Sep; 32(9):994-999.
14. Peñarrocha-Diago M, Sanchez-Recio C, Peñarrocha-Oltra D, Romero-Millán J. Osteotomy in direct sinus lift. A comparative study of the rotary technique and ultrasound. Medicina Oral, Patologia Oral y Cirugia Bucal. 2012 May 1; 17(3):e457-461.
15. Liu Y, Sun X, Yu J, Wang J, Zhai P, Chen S, Liu M, Zhou Y. Platelet-Rich Fibrin as a Bone Graft Material in Oral and Maxillofacial Bone Regeneration: Classification and Summary for Better Application. Biomed Research International. 2019 Dec 6;2019: 3295756-3295756.
16. Harder S, Wolfart S, Mehl C, Kern M. Performance of ultrasonic devices for bone surgery and associated intraosseous temperature development. The International Journal of Oral & Maxillofacial Implants. 2009 May 1; 24(3):484-490.
17. Delilbasi C, Gurler G. Comparison of Piezosurgery and Conventional Rotative Instruments in Direct Sinus Lifting. Implant dentistry. 2013 Dec; 22(6):662-665.