

Case study

Diastema closure through Z plasty frenectomy technique and composite build-up – A case report.

Abstract

Introduction- Patient's aesthetic concern in dentistry is very important now a days and increasing in day-to-day life. Now a day's those who having aesthetic problems are demanding aesthetic dentistry with minimally invasive procedure and they also want immediate results. Upper labial frenum is a fold of mucous membrane that attaches cheek and lips to the gingiva, alveolar mucosa, and the underlying periosteum. This aberrant upper labial frenum can contribute to midline diastema and can also affect the orthodontic treatment outcomes. This aberrant maxillary labial frenum can be treated effectively by frenectomy procedure and spacing in between two upper central incisors can be corrected successfully further by composite build up.

Key words- Z-plasty, composite build up, midline diastema

Introduction

Now a day's patients are more concerned about their aesthetic appearance. Spacing in between two upper central incisors is a common aesthetic complaint of patients¹. Keene described midline diastema as spacing in between upper anterior which is more than 0.5mm². Many studies have shown that maxilla has a higher prevalence of midline diastema than mandible³. The Spacing in between upper central incisors has a multifactorial etiology. In addition to the upper labial aberrant frenum, peg-shaped lateral incisors, tongue thrusting, lip sucking, dental malformations, lateral incisor agenesis, cysts in the midline region, finger sucking, microdontia, mesiodens, genetics, maxillary incisor proclination, and dental-skeletal discrepancies are the factors that can cause diastema⁴. Though many factors are responsible for midline diastema, presence of an aberrant frenum is being considered as main aetiological

factor⁵. when these aberrant frenum are closely attached to gingival margin they may cause gingival recession⁶.

Frenum have been classified according attachment of fibres as:⁷

1. Mucosal – frenal fibers are attached up to mucogingival junction
2. Gingival – fibers are attached to attached gingiva
3. Papillary – fibers extending into interdental papilla
4. Papilla penetrating – fibers extend up to palatine papilla.

Prevalence of various frenal attachments includes,⁸

1. mucosal - 46.5%,
2. gingival -34.3%,
3. papillary t -3.1%,
4. papilla penetrating - 16.1%.

Upper labial frenum encroaching on the gingival margin leads to distention of the gingival sulcus, and which further leads to plaque accumulation, increasing the rate of progression of gingival recession and thereby may lead to chances recurrence after treatment⁹.

Papillary and papilla penetrating frenum which are clinically considered as pathological have been found to be associated with loss of papilla, recession, diastema, difficulty in brushing, and psychological disturbances to individual¹⁰. Abnormal or aberrant frenum are detected clinically by tension test. In this test tension is applied over frenum to see the movement of papillary tip or blanch produced due to ischemia of the region ¹⁰. In such cases of aberrant frenum it is necessary to perform a frenectomy for aesthetic, psychological, and functional reasons. Frenectomy procedure can be accomplished either by the routine scalpel techniques which includes Miller's technique, V-Y plasty, Z-plasty, paralleling technique, classical technique etc, or by electro-surgery and lasers¹¹. Laser and electrosurgery are especially recommended in patients with bleeding disorders and these two procedures are popular in soft tissue surgical procedures. Conventional scalpel techniques are preferred in patients where precise incision, flap reflection and mobilization and early healing is indicated. However, many frenectomy techniques are not preferred due to risk of hypertrophic scar formation and high risk of recurrence. The risk of hypertrophic scar formation and recurrence can be eliminated or reduced by using a technique known as Z-plasty frenectomy¹². This

technique is indicated in cases of short vestibule and when there is hypertrophy of the frenum with a low insertion¹³. After successful frenectomy procedure and complete healing, the spacing in between teeth is closed by composite layering technique. Direct composite resins in diastema closure cases allow dentist to achieve natural smile¹⁴.

Case Report

A 24-year-old male patient reported to our department periodontology government dental college and hospital, Aurangabad with chief complaint of spacing in between upper central incisors causing aesthetic problem. The cause of spacing in between two upper central incisors was found to be abnormal frenal attachment. A thorough family and medical history was taken to rule out any contraindications for the surgery. On intra oral examination it was found that there was a thick aberrant upper labial frenum extending into the interdental papilla between upper central incisors with short vestibule. The abnormal frenal attachment was detected clinically by applying tension over the frenum to see the movement of the papillary tip or the blanch which is produced due to ischaemia in the region. Intraoral Periapical Radiograph was taken to rule out the cause of diastema and presence of any unerupted mesiodens. Because of hypertrophy of frenum with low insertion and short vestibule, case was considered for Z-plasty frenectomy to avoid scar formation. The surgical procedure was explained to the patient. Blood investigations were carried out before surgery. Written informed consent was obtained from the patient. Then phase 1 therapy, Scaling and root planning was performed 2 to 3 days after enrolment of patient and 7 days then after. After successful phase 1 therapy patient was recalled after 1 month. After obtaining proper oral prophylaxis, extraoral scrubbing was done with 10% betadine and patient was asked to do intraoral rinsing with 2% betadine. Local anaesthesia in the form of local infiltration on both the side of frenum and nasopalatine nerve block was given. After achieving local anaesthesia patient was asked for subjective and objective signs and symptoms. After checking subjective signs and symptoms, incision line was marked with pencil on the frenum. Then vertical incision was made on the frenum with 15 no blade. Two lateral horizontal incisions of same length (approximately 1-2 cm) were placed at the coronal and apical end of vertical incision at an angle of 60° to the vertical incision (in opposite direction), creating two triangular flaps of equal size and shape¹⁵. Adequate undermining of the surrounding tissues was performed to achieve proper mobilisation of the flaps. The two triangular flaps were then

rotated and transposed to the opposite side of the apex of each flap. Tips of the flap were sutured with 5-0 vicryl suture. Then rest of the flap were sutured. Post-operative instruction was given to patient. Patient was asked to maintain a soft diet for a week, and antibiotics and analgesics were also prescribed and was advised 0.2% chlorhexidine gluconate mouth-rinse twice daily for 2 weeks. patient was recalled after 7 days. Post-operative healing was accessed at 7th day, 1month and 6month. After complete healing, patient was recalled for composite restoration. Scaling was done to remove any plaque and debris. Firstly, shade selection was carried out. Proper isolation was done using cotton and cheek retractor was applied. 37% phosphoric acid (Etching Gel) was applied for etching on the mesial surface of tooth to be restored for 15-20 seconds, rinsed for 20 seconds, and dried. Then a bonding agent was applied and polymerized for 20 seconds with a curing light. After that layers of composite were applied and cured with curing light. After complete layering of composite, polishing was done with polishing disc to convert rough surface to smooth one by using low speed handpiece. Then patient is recalled after 24 hrs for finishing which was done by finishing burs. Then patient is recalled at 1month, 3month and 6month intervals for checking the restoration, and polishing rough surfaces if any. Patient was advised to practise proper oral hygiene, brushing twice a day and use of chlorhexidine mouthwash for a period of 2 weeks.

Discussion

The upper labial frenum is an anatomic formation which is only considered as an aesthetic problem and under normal conditions, causes no pathological consequences. However, in some cases it may cause a periodontal, orthodontic, prosthetic and phonetic problems and in these cases, surgical correction would be necessary. The management of this upper labial aberrant frenum is more important and for aesthetic reasons has gained much of interest in the present era. There are various frenectomy procedures which includes the classical technique, Miller's technique, V-plasty, Y-plasty, Z-plasty, electrocautery and laser. The classical technique can lead to scarring and leaves a longitudinal surgical incision, which may lead to further periodontal problems and an anaesthetic appearance. Electrocautery and laser are mostly beneficial in patients with bleeding disorders. Z-plasty frenectomy technique avoids scar formation and has better post-operative healing. According to Mehrotra et al., 2018 the Z-Plasty technique is indicated in cases of short vestibule and hypertrophic frenum

with low insertion. A study by Heller et al. in 2005 compared the treatment outcome for Z-frenectomy technique and other traditional horizontal to vertical frenectomy techniques in the management of upper labial aberrant frenum. Total 16 patients were included in study. 11 patients underwent a frenectomy by Z-plasty technique and 5 patients had undergone a frenectomy by horizontal to vertical plasty. The length of frenum, length of tongue protrusion and speech was analyzed pre- and post-operatively. The results of this study have concluded that the, Z-plasty frenectomy technique was a superior technique than other techniques and has some advantages than the other, with an improvement in length of frenum and tongue protrusion of 37.5 ± 13.5 mm compared to the other method at 36.2 ± 7.6 mm respectively. In addition, it was also found that 91% of the patients with Z-plasty showed improvement in speech compared to other 40% who underwent the horizontal-to-vertical plasty. Many conventional techniques have disadvantages of scar formation post operatively. The main advantage of the Z-plasty method over the conventional technique is minimal or no scar tissue formation post-operatively. The disadvantage of Z-plasty frenectomy technique is its sensitivity¹⁶. Z-plasty technique results in less soft tissue tension, improves the lip and tongue function and also increases the length of lip. In terms of aesthetic dentistry, composite restoration has numerous advantages than ceramic veneers and orthodontic treatment. Composite restoration has good longevity, can be repaired if fractured, has good bond strength with tooth, and is economic restorative material¹⁷. However, bruxism, Class III end-to-end occlusal schemes, or noxious oral habits such as nail biting can potentially jeopardize the longevity of direct composite resin restorations¹⁸.

Conclusion

Z- plasty frenectomy technique is mainly advocated in cases of short vestibular depth and hypertrophy of frenum with low insertion which are associated with the midline diastema. Z-plasty technique has advantage of redistributing tension over skin, minimal or no scar formation, increases the length of lip in cases of short vestibule, showing excellent functional and esthetic results.

Ethical Approval:

As per international standard or university standard written ethical approval has been collected and preserved by the author(s).

Consent

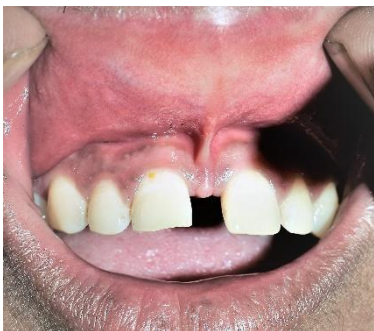As per international standard or university standard, patients' written consent has been collected and preserved by the author(s).

References

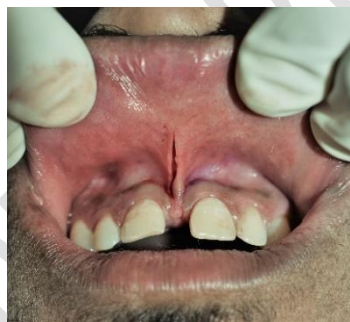1. K. Koora, M. S. Muthu, and P. V. Rathna, "Spontaneous closure of midline diastema following frenectomy," *Journal of Indian Society of Pedodontics and Preventive Dentistry*, vol. 25, no. 1, pp. 23–26, 2007.
2. H. J. Keene, "Distribution of diastemas in the dentition of man," *American Journal of Physical Anthropology*, vol. 21, no. 4, pp. 437–441, 1963.
3. J. T. Kaimenyi, "Occurrence of midline diastema and frenum attachments amongst school children in Nairobi, Kenya," *Indian Journal of Dental Research*, vol. 9, no. 2, pp. 67–71, 1998.
4. Weber, Quoted in: *Orthodontic Principles and Practice*, edited by: T. M. Graber, W.B. Saunders Company, 3rd edition, 1972.

5. Huang WJ, Creath CJ. The midline diastema: a review on its etiology and treatment. *Pediatric Dentistry* 1995;17:171-9.
6. Jhaveri H. The Aberrant Frenum. In: Dr. Hiral Jhaveri (ed), Dr. PD Miller the father of periodontal plastic surgery, 2006;29-34.
7. Placek M, Miroslavs, Mrklas L. Significance of the labial frenal attachment in periodontal disease in man. Part 1; Classification and epidemiology of the labial frenum attachment. *J Periodontol* 1974;45:891-4.
8. Mirko P, Miroslav S, Lubor M. Significance of the labial frenum attachment in periodontal disease in man. Part 1. Classification and epidemiology of the labial frenum attachment. *J periodontol.* 1974; 45(12):891-894.
9. Dewel BF. The labial frenum, midline diastema and palatine papilla: A clinical analysis. *Dent Clin North Am* 1966;175-84.
10. Newman MG, Takei HH, Klokkevold PR, Carranza FA. Carranza's Clinical Periodontology. 10th ed. Philadelphia: WB Saunders Co.; 2006. p. 866-70.
11. DeviShree SK, Shubhashini PV. Frenectomy: A review with the reports of surgical techniques. *J Clin Diagn Res.* 2012; 6(9):1587.
12. Abullais SS, Dani N, Ningappa P, Golvankar K, Chavan A, Malgaonkar N, Gore A. Paralleling technique for frenectomy and oral hygiene evaluation after frenectomy. *J Indian Soc Periodontol.* 2016; 20(1):28.

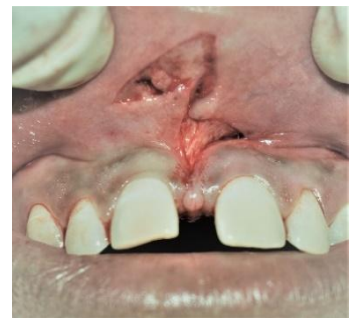13. Burke M. Z-plasty. How, when and why. Australian family physician. 1997; 26(9):1027-9.
14. B. G. Dale and K. W. Aschheim, Eds., Esthetic Dentistry: A Clinical Approach to Techniques and Materials, vol. 11, Lea and Febiger, Philadelphia, Pa, USA, 1993.
15. Dusara K, Mohammed A, Nasser NA. Z-frenulop lasty: A better way to ‘untangle’lip and tongue ties. J Dent Oral Disord Ther. 2014; 2(1):4.
16. Heller J, Gabbay J, O’Hara C, Heller M, Bradley JP. Improved ankyloglossia correction with four-flap Z-frenuloplasty. Ann Plast Surg 2005;54:623-8.
17. P. Magne and U. C. Belser, “Porcelain versus composite inlays/onlays: effects of mechanical loads on stress distribution, adhesion, and crown flexure,” The International Journal of Periodontics & Restorative Dentistry, vol. 23, no. 6, pp. 543–555, 2003.
18. K. W. Hemmings, U. R. Darbar, and S. Vaughan, “Tooth wear treated with direct composite restorations at an increased vertical dimension: results at 30 months,” The Journal of Prosthetic Dentistry, vol. 83, no. 3, pp. 287–293, 2000.



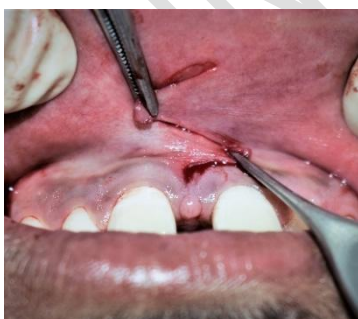Pre-op



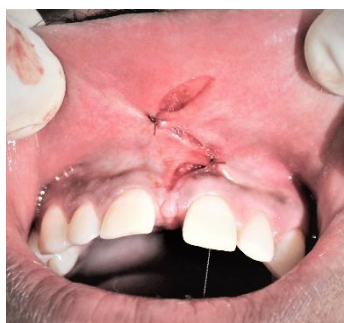Initial vertical incision



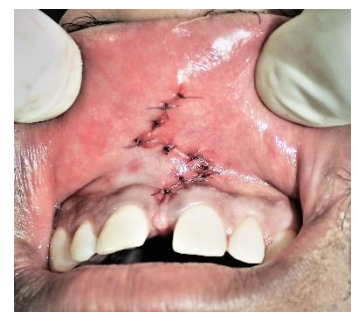Z shape incisions



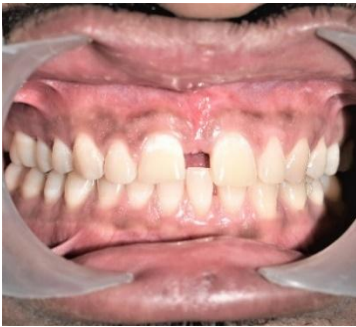Flap approximation



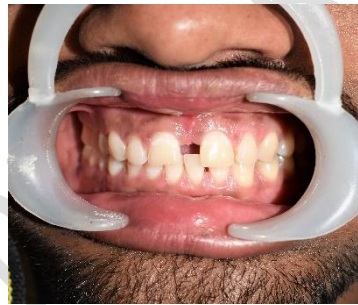
Tips of flap were sutured



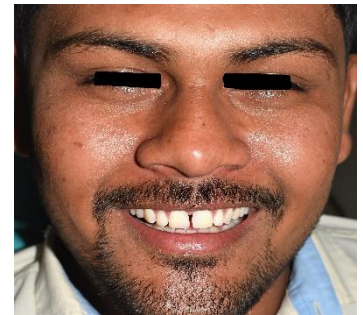Complete suturing



1 month follow up



6 month follow up



Esthetic smile after
composite restoration