

## MODIFIED CLINICAL PRACTICE OF SARIVA KSHARA SUTRA WITH PARTIAL FISTULECTOMY IN THE MANAGEMENT OF BHAGANDARA (FISTULA-IN-ANO)

### Abstract

*Bhagandara is Ashta Mahagaroga (8 major disease) by Sushruta because of highest recurrence. Anorectal disorders are at peak, because to sedentary lifestyle and many other factors. 2 words Bhaga and Darana is bifurcation bhagandara, it is a common disease occurring in Anorectal region around the anus which may extends up to Genitalia. Pidika creation causes Bhagandara to develop, which is countered by opening up in the Guda Pradesh region with suffering and discharge. Kshara Sutra therapy is the one-of-a-kind, specific Parasurgical procedure that is employed in Fistula in Ano. Bhagandara is treated using a variety of modern scientific modalities, but to far no single modality has proven to be comprehensive for Fistula. The goal of the current study was to evaluate the modified way to treat fistula-in-ano with Sariva Kshara Sutra with partial fistulectomy. Case was taken from OPD/IPD of SHAH PILES FISTULA HOSPITAL, AHMEDABAD.*

*CASE 1: - Age 31 yrs. Male Patient came to our hospital with complain of pain, swelling, discharge in scrotal to anterior anal canal (scrotal extension) treated with Sariva Kshara Sutra with partial fistulectomy considering its a best procedure in the treatment of Bhagandara preserving the Sphincter it treats the track.*

**KEY WORDS:** - *Fistula in Ano, Bhagandara , Sariva Kshara Sutra with partial fistulectomy, recurrent fistula.*

### Introduction

*Bhagandara is fistula in ano, Bhagandara means formation of new tract other then the original anal track.<sup>[1]</sup> The word fistula, which is derived from the Latin for reed, pipe, or flute, is particularly dangerous in Ashtamahagada[2]. Fistula in ano, also known as an aberrant track creation between the anal canal and the rectum, is most frequently caused by an anorectal abscess that spontaneously bursts on the perianal skin.*

*In this case study, we discovered that the recurrent fistula stretched all the way to the base of the scrotum, where the symptoms started to manifest. Goodsall's Rule is used to determine the course of fistula track with help of Probe.*

*Application of Kshara Sutra in treatment of fistula-in-ano has become familiar due to less recurrent rates.*

*In this case, a partial fistulectomy performed by Sariva Kshara Sutra successfully corrected a fistula in ano. No complaints or recurrences were discovered during or after the procedure. With the Chedana, Bhedana, Lekhana, and Tridoshaghna characteristics, Kshara is superior than Shastra and Anushastra Karma.*

### Case report:-

A 31 years young male patient came with complaints of painful swelling and discharge from of base of scrotum, with induration on 26/11/2020 at our OPD. h/o - surgery, Post Covid19 before 3 months on date not remembered in G.C.S Hospital, Ahmedabad (Gujarat State). Underwent a spinal anaesthetic for a fistulotomy. Currently, the patient's anterior perineum, which is below the scrotum, had a discharge wound that was tender and uncomfortable upon examination; an MRI on November 25th, 2020 verified the diagnosis, indicates a high scrotal anal fistula with an internal entrance at 12 o'clock position. There was a fistula that returned in Ano.

H/o past illness – Post Covid 19

GE:-

- G.C – moderate
- C.V.S - S1 S2 Heard clearly
- Pulse - 88/min, BP-120/90mmhg
- R.S. - Bilateral Air entry is clear
- Appetite – good, Bowel- 1-2 times per day

On local examination

Patient was examined under lithotomy position,

Post-operative changes with skin defect in anterior perianal region on right side.

Edematous changes with ill-defined fluid collection involving scrotal wall bilaterally

Right spermatic cord appears bulky and edematous – suggestive of changes of Funiculitis

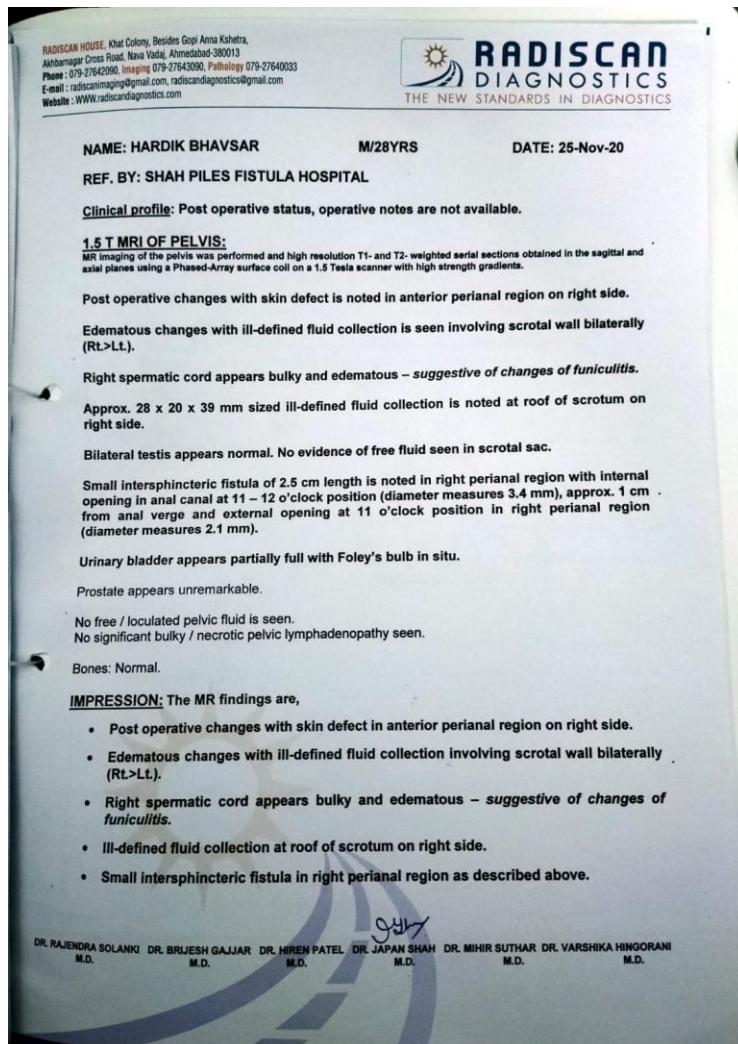
Approx. 28\*20\*39 mm sized ill-defined fluid collection noted

Ill-defined fluid collection at root of scrotum on right side

Small intersphincteric fistula on 2.5 cm length is noted in right perianal region with internal opening in anal canal at 11-12 o'clock position (diameter measures 3.5 mm) approx. 1 cm from anal verge and external opening at 11 o'clock position in right perianal region (diameter measures 2.1mm)

complicated recurrent fistula.

Image 1: MRI Report:-



Preparation of K.S

*Snuhi Ksheera* = 11 coatings

*Snuhi Ksheera* + *Sariva Kshara* = 7 coatings

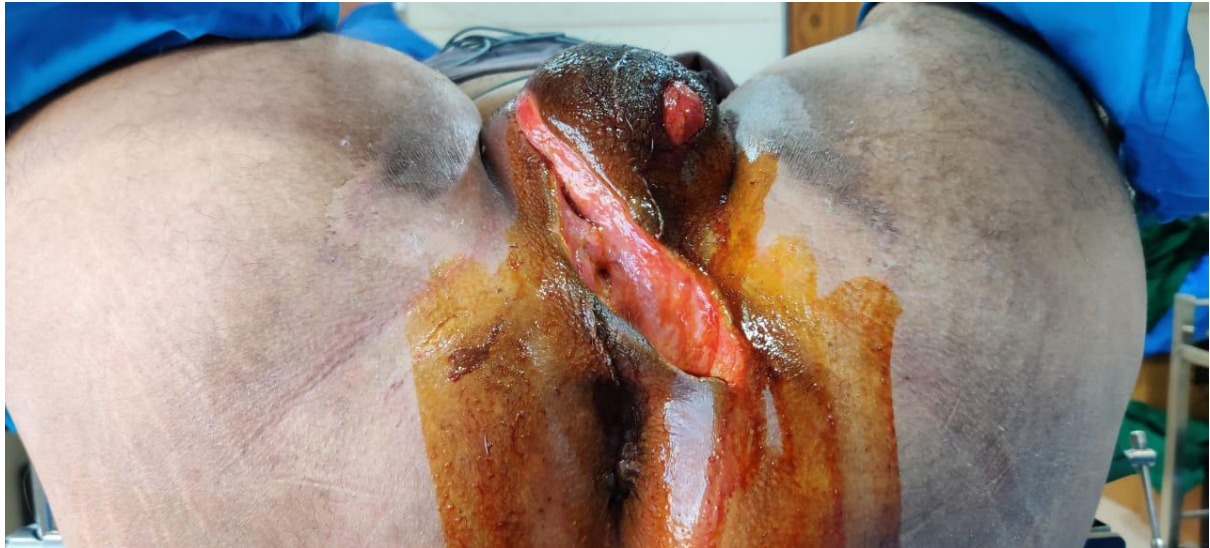*Snuhi Ksheera* + *Haridra Churna* = 3 coatings

“Barbour’s linen thread No. 20, one coating was applied each day and kept for drying the *Kshara Sutra* cabinet.

A total of 21 days was needed to complete the preparation of thread. After these threads were cut in 2 sizes medium length 24cm, small 18cm length and packed in a sterile sealed pack after packing in the UV cabinet with a small pack of silica inside to absorb moisture, all of these were packed in airtight container and stored keep it away from contact with any moisture”.<sup>[5]</sup>

Pre op investigations preop major was done and were normal limits.

**Image 2:** Pre-operative



Under Spinal Anesthesia

Patient will be kept in lithotomy position and perianal region will be cleaned with antiseptic lotions and drapping done. Looking at the type of Bhagandara, partial fistulectomy is done

leaving the sphincter. Later finger with gloves on will gently be examined into the rectum.

Then a

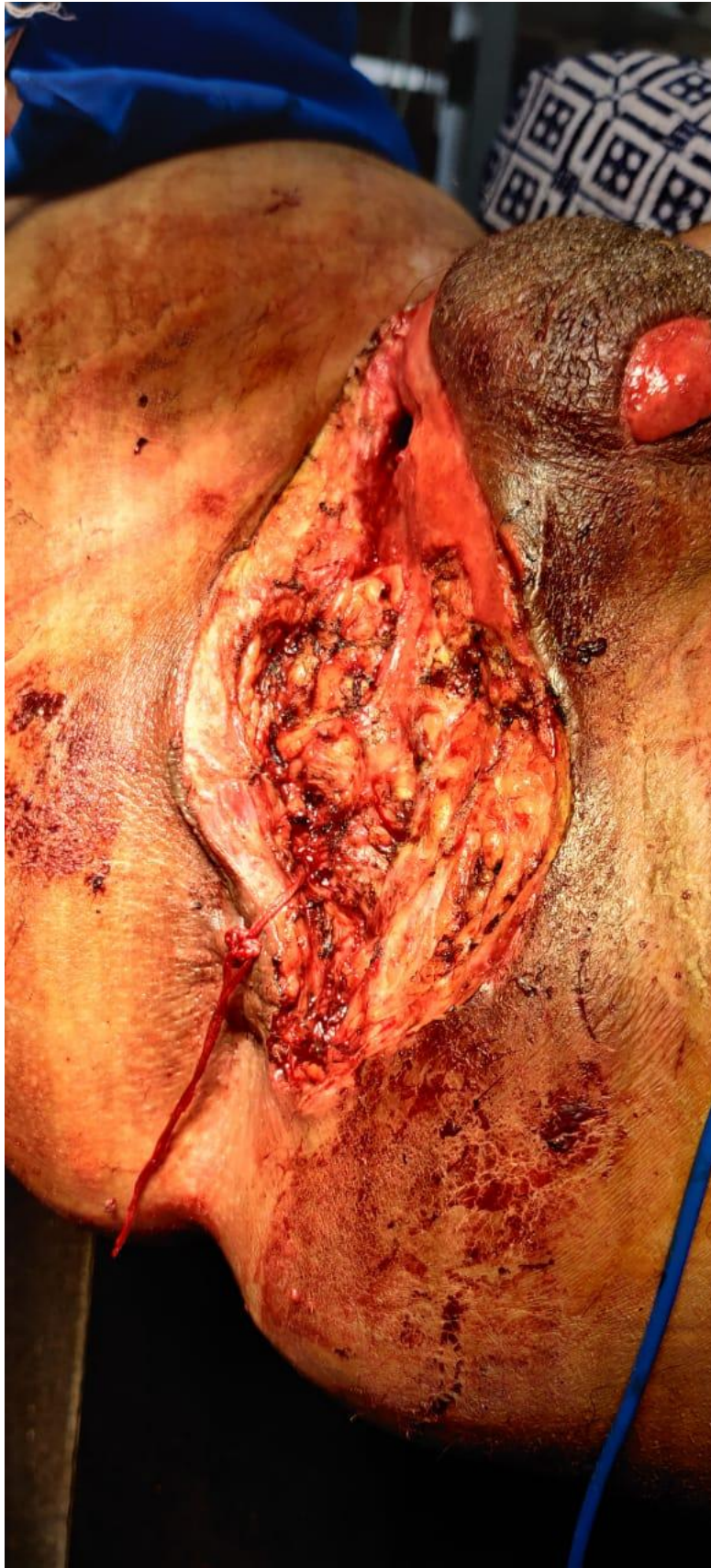suitable selected probe will be passed through the external opening of fistula. The tip of the probe will be forwarded along the path of least resistance and will be guided by the finger in rectum to reach into the lumen of anal canal through the internal opening and its tip will be finally directed to come out of anal orifice. Then a surgical linen thread

No.20 will be taken and threaded into the eye of probe. The probe will then be removed through the anal orifice, leaving the thread in the fistulous track behind. The thread's two ends will then be moderately tightly knotted together outside the anal canal.

Image 3: Post operative:-

Proper analgesics & anti biotics were prescribed along with sitz bath with proper dressing was given





follow up:-

Patient was asked to visit hospital every week for observation. After 20 days of surgery

surgical linen thread No.20 will be replaced by Sariva Kshara sutra and that it will be kept on changing every week till cut through and the wound is healed.

Image 4: Final result:-



OBSERVATION

Initially the wound was allowed to heal by itself with proper betadine and hydrogen peroxide dressing the intersphincteric track's length was 2.5 cm. which got cut-through. Patient was asked to visit hospital every week till complete healing was achieved. No recurrence were observed.

## CONCLUSION

*Kshara Sutra is best* in the cases of fistula in ano even in recurrent and complex high anal fistulas. Giving the best results *Kshara Sutra with partial fistulectomy* requires minimal general surgical setup, equipment's, and instruments. It forms healthy granulation tissue, it also removes fibrous tissue and drains the cavity preserving the sphincters.

## Consent

As per international standard or university standard, patients' written consent has been collected and preserved by the author(s).

## References

1. Shastri Kaviraj Ambikadatta, Sushruta Samhita, Ayurveda Tatva Sandeepika, 2016 edition, Varanasi, Chaukhambha Sanskrit Samsthana, Nidana Sthana, 4/4, page no, 317
2. Shastri Kaviraj Ambikadatta, Sushruta Samhita, Ayurveda Tatva Sandeepika, Hindi commentary, 1997th edition, Reedition 2016, Varanasi, Chaukhambha Sanskrit Samsthana, Sutrasthana, 30/4-5, page no, 165
3. Shenoy K Rajgopal, Shenoy Anita, Manipal Manual of Surgery, 4<sup>th</sup> edition 2014, New delhi, CBS Publishers, p799
4. Shastri Kaviraj Ambikadatta, Sushruta Samhita, Ayurveda Tatva Sandeepika, 2016 edition, Varanasi, Chaukhambha Sanskrit Samsthana, Sutrasthana, 11/3, p-45
5. Deshapande, P G Pathak SN, The treatment of Fistula in ano with kshara sutra treatment, Nagarjuna edition, Varanasi, 1965; p 361- 367.