

# **Case Report on Infantile Tremor Syndrome with Severe Acute Malnutrition.**

## **Abstract:**

A 8 month old female infant presented with a complain of fever since 4 days which was low grade to moderate in nature, intermittent 1-2 spikes/day which was relieved with medication, cough and cold since 2 days which was on and off since last 2 months, and had complain of ear discharge since 1 week from right ear. The discharge was yellowish in color, small in quantity and non foul smelling; the infant was showing tremors of limbs during awake stage. The infant seemed unhealthy and the weight was very low according to the age growth. The infant showed mild tremors which was said to be ITS.

## **Introduction:**

Infantile tremor syndrome (ITS) is a rare clinical disorder, characterized by coarse tremors, anemia and regression of motor and mental milestones in children of around one year of age. Exact incidence is not known. In India, it accounts for 0.2 to 2 % of pediatric hospital admissions (1-2% in 1960s, 1.1 % in 1975-77 and 0.2% in mid-1990s) <sup>[1]</sup>. Improvement in nutritional status, living conditions and better weaning practices could explain the reducing incidence rates over the years. It has been primarily reported from India and South East Asia and has also been reported from other developing countries in Asia and Africa <sup>[2]</sup>. Various nutrient deficiencies (e.g. Vit B<sub>12</sub>, Magnesium, Zinc, Vit C etc.) have been found to be associated with ITS. Other causative theories include viral encephalitis and degenerative processes.

## **Case Report:**

A 8 month old female infant with 63cm height 5.300 kg weight presented with a complain of fever since 4 days low grade to moderate, intermittent 1-2 spikes/day which relieved with medication, cough and cold since 2 days and was on and off since last 2 month, tremors was observed since 2 months and was observed more in limbs but was present only in awaked stage and had complain of ear discharge since 1 week from right ear and discharge was yellowish small in quantity and non foul smelling. Infant had history of same condition before a week and was admitted and treatment given was injection Augmentin and Syrup PCM as it was diagnosed as bronchopneumonia. Infant has also a history of 2 episodes of convulsion at home. Infant's mother informed that her baby was lagging in growth and development in comparison to the other children of same age and sex in the community. In family infant had elder brother of 9 years old and a sister who died at the age of 9 months due to severe bronchopneumonia. Infant's mother has sickling trait. Infant was exclusively breast feed.

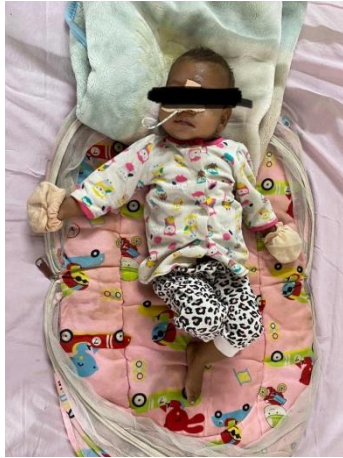

Figure 1 Patient suffering from ITS

The patient **Developmental History** shows as:

Gross Motor Development: was not able to sit with support; neck holding was present, can roll over at age of 5 month.

Fine Motor Development: Palm Grasp present

Language Development: No words

Social Development: Strange Anxiety Present

Gross Developmental Delay present.

Regression of Milestone is present.

According to WHO child growth standards

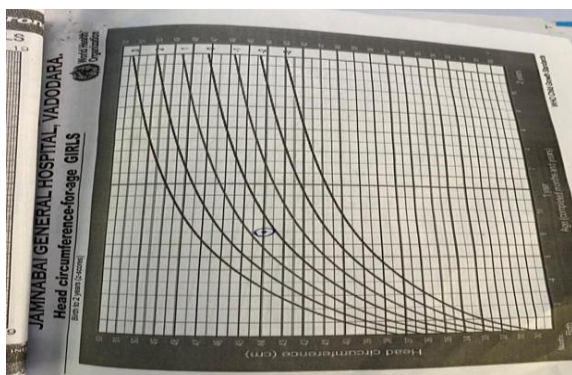


Figure 2 reference from website

Figure 2 WHO

On general examination, the infant has innocent heart murmur which can be probably caused due to anaemia, the infant was found to be underweight (according to WHO child growth standards) and pallor (dark pigmentation in skin) was present. Pulse (126 bpm), temperature (98.2°F), respiratory rate (54bpm), CVS (S1 S2 +, murmur present), RS (AEBE B/L Wheeze > crepts)

### Laboratory investigation:

On investigation infant was found to be anemic with Hb (8.10 gm/dl), RBC (6.78 /cmm) MCV (70 fL), MCH(22 pg), MCHC(31.40 gm/dL), RDW (14.50 %), ESR (12 mm), Eosinophils (7%). Infants sickling test was found positive. CRP (positive). Cerebro-Spinal Fluid, Peripheral Blood Film and Vitamin B12 examination was not conducted.

**THERAPEUTIC PLAN** of infant was as followed:

Drugs	Dose/route/frequency
Ig F <sub>75</sub>	55 cc / 2 hrly
Inj. AUGMENTIN	155 mg/IV/8 hrly
Inj. AMIKACIN	30 mg/ IV/ 8 hrly
Syp. ALBENDAZOLE	5 ml /oral / Stat(immediately)
Syp. VIT.A	1 ml / oral/ Stat(immediately)
Syp. PCM	4 ml/ oral/ SOS (when required)
Syp. NERVITAS GOLD	3 ml /oral/ BD (twice a day)
Syp. ZINC	2.5 ml /oral /OD(once a day)
Syp. Calcium gluconate + D3	2.5 ml /oral/BD(twice a day)
Inj. ELDERVIT	0.5 ml /Intra Muscular/OD (once a day)

### Discussion :

A classical picture of ITS is a plump looking infant between 6 to 18 months with presence of malnutrition. Usually, these children are listless, apathetic and disinterested in surroundings. Scalp hair is sparse and light colored. Dark pigmentation is present over dorsal aspects of hands, nail folds, feet, knees, ankles, buttocks and axillae. There is regression of milestones in the recent past. Tremors have an acute onset following an acute infection or stress. Initially they are intermittent but become continuous in a few days. They are more prominent in distal parts of limbs, head, face and tongue. These tremors disappear during sleep. Most of the classical findings were present in our cases. Tremors have been attributed to structural and functional alterations of extrapyramidal system <sup>[3]</sup>. There is presence of anemia, which may be macrocytic, microcytic or normocytic.

The etiology of ITS is still elusive. Among various theories, nutritional theory is the most accepted. Vitamin B<sub>12</sub> deficiency has been found to be associated with ITS in many studies <sup>[1]</sup>. It is usually seen in children who are exclusively breast-fed for prolonged periods by vegetarian mothers. The low levels of vitamin B<sub>12</sub> and its transport protein Transcobalamin II (TC II) in the

cerebrospinal fluid (CSF) maybe responsible for the neurological features of this syndrome <sup>[4]</sup>. Iron, magnesium and zinc deficiency have also been postulated to cause ITS. It is usual to find direct or indirect evidence of associated other nutritional deficiencies like protein, vitamin A, D, C and B-complex and other micronutrients <sup>[1, 5, 6]</sup>. Other speculations for its etiology include viral encephalitis and degenerative processes.

The treatment was given based on the anemia and the malnutrition deficiency. Due to lack of awareness and unable to afford the cost we were unable to go for further investigations and the main cause of ITS. Infant was given a multivitamins for treating the malnutrition and as the tremors were not severe we had avoided anti seizure drugs while as the infant was suffering from bronchopneumonia we had given antibiotic to that infection.

#### Conclusion:

A classical picture of ITS is a plump looking infant between 6 to 18 months with presence of malnutrition. Usually, these children are listless, apathetic and disinterested in surroundings. Scalp hair is sparse and light colored. Dark pigmentation is present over dorsal aspects of hands, nail folds, feet, knees, ankles, buttocks and axillae. As infants diagnosed was based on the listed criteria, infant was given treatment of anemia and malnutrition. As the tremours were not sever anti-seizure drugs were not prescribed.

#### Abbreviation:

ITS	Infantile Tremor Syndrome
MCV	Mean Corpuscular Volume
MCHC	Mean Corpuscular Hemoglobin Concentration
Hb	Hemoglobin
ESR	Erythrocyte Sedimentation Rate
CRP	C-Reactive Protein

#### Compliance with ethical standards:

##### Acknowledgments

We would like to thank Principal Dr. Gunosindhu Chakraborty, Principal and Professor PIPR, Parul University, all the Authors and PIPR Staff.

Disclosure of conflict of interest: All authors declare that they have no conflict of interest.

Statement of informed consent: Informed consent was obtained from the individual participant included in the study.

No Animal is used in the study and direct intervention was not performed.

## Reference:

1. Gupte S, Pal M, Gupta SK, Sangra KR. Infantile tremor syndrome (ITS) In: Gupte S, editor. *Textbook of Paediatric Nutrition*. Peepee; New Delhi: 2006. pp. 255–265. [[Google Scholar](#)]
2. Ghai OP, Gupta P. Infantile tremor syndrome. In: Ghai OP, Gupta P, Paul VK, editors. *Ghai Essential Paediatrics*. 6th edn. Dr. Ghai; New Delhi: 2005. pp. 539–540. [[Google Scholar](#)]
3. Gupte S. Infantile tremor syndrome (ITS) *Indian J Paediatr*. 2007;74:88. [[PubMed](#)] [[Google Scholar](#)]
4. Avci Z, Turul T, Unal I. Involuntary movements and magnetic resonance imaging findings in infantile cobalamin (vitamin B12) deficiency. *Paediatrics*. 2003;103:684–686. [[PubMed](#)] [[Google Scholar](#)]
5. Vora RM, Tullu MS, Bartakke SP, Kamat JR. Infantile tremor syndrome and zinc deficiency. *Indian J of Medical Sciences*. 2002;56:69–72. [[PubMed](#)] [[Google Scholar](#)]
6. Ratageri Vinod H, Shepur TA, Patil MM, Hakeem MA. Scurvy in Infantile Tremor Syndrome. *Indian J Paediatr*. 2005;72:883–884. [[PubMed](#)] [[Google Scholar](#)]
7. Thora S, Mehta N. Cranial Neuroimaging in Infantile Tremor Syndrome (ITS) *Indian Paediatr*. 2007;44:218–220. [[PubMed](#)] [[Google Scholar](#)]
8. Gupte S. Infantile tremor syndrome. In: Gupte S, editor. *The Short Textbook of Paediatrics*. 10th edn. Jaypee Brothers; New Delhi: 2004. pp. 716–719. [[Google Scholar](#)]
9. Gourie-Devi M. Neurological practice. An Indian perspective. *Annals of Indian Academy of Neurology*. 2006;9:129–130. [[Google Scholar](#)]
10. Kalra V, Infantile tremor syndrome. In: Ghai OP (ed.). *Essential Pediatrics*. 7th edn. New Delhi: CBS Publishers and Distributions Pvt. Ltd, 2009, 558–9. [Google Scholar](#)
11. Sharada B, Bhandari B. Infantile tremor syndrome. *Indian Pediatr* 1987;24:415 21. [Google Scholar PubMed](#)
12. Ghai OP, Gupta P. Infantile tremor syndrome. In: Ghai OP, Gupta P, Paul VK (eds). *Ghai Essential Paediatrics*. 8th edn. New Delhi: Dr. Ghai, 2013, 580–1. [Google Scholar](#)
13. Murali MV, Sharma PP, Koul PB, et al. Carbamazepine therapy for infantile tremor syndrome. *Indian Paediatr* 1993;30:72–4 [Google Scholar](#)

