

Original Research Article

Effect of *Cyperus esculentus* Meal on Glutathione And sperm Parameters in Androgen-Induced Benign Prostate Hyperplasia (BPH) in Adult Male Wistar Rats

Abstract

Introduction: Large populations and diversification of food plant species have continued to play an important role in sustaining healthy lifestyles and enhancing lifespan for everybody. This becomes imperative with growing environmental population and its resultant health hazards which may affect the reproductive system. *Cyperus esculentus* may help to cure erectile dysfunction. Infertility is on the increase especially in the developing countries. However, male infertility is commonly due to deficiencies in the semen, and semen quality is used as a surrogate measure of male fecundity.

Aim: The aim of this project was to study the Effect of *Cyperus esculentus* (Tiger Nut) Meal on Glutathione, Some sperm Parameters such as Semen pH, Sperm count, Sperm without a tail, sperm without head etc. and Morphological changes in Androgen-Induced Benign Prostate Hyperplasia in Adult Male Wistar Rats

Method: A total of sixty (60) male rats weighing between 160 – 200 g were used in this study. They were divided into six groups of ten rats per group. Benign prostate hyperplasia was induced in three groups of the rats (as stated in methodology) with 30 mg/kg sub-cutaneous injections of hormones containing dihydrotestosterone and estradiol valerate dissolved in olive oil in the ratio of 10:1 (three times in a week, one day interval). Administration of tiger nut meal commenced immediately and lasted for two months. At the end of administration, blood sample was collected from the rat via cardiac puncture for the determination of Glutathione. Semen samples were collected for analysis of semen abnormality and Cytoplasmic droplets.

Results: Following the induction of BPH, the administration of tiger nut meal showed some positive effects on the rats. On Glutathione, the administration of the tiger nut meal increased the level of the antioxidant, glutathione, in the induced rats ($P < 0.05$). Also, on the effect of the tiger nut meal on the induced abnormalities of the sperm cells (such as sperm cells without a head and the ones without a tail) there was a significantly decreased the level of these abnormalities of the semen recorded following the induction of BPH ($P > 0.05$)

while at the same time, enhancing the Sperm concentration (sperm count) ($P < 0.05$).

Conclusion: Tiger nut meal decreased the levels of sperm cells without a head, sperm cells without a tail and that of cytoplasmic complete. It also showed a significant increase in the levels of sperm count, Glutathione and semen pH.

Key Words: Glutathione, Sperm count and sperm abnormalities.

1. INTRODUCTION

“The existence of large population and biodiversity of food plant species has continued to play a prominent role in ensuring healthy lives and promoting longevity for all. This becomes imperative with growing environmental population and its resultant health hazards” (1). “One of such plants is Tiger nut (*Cyperus esculentus*). Tiger nut has been grossly underutilized and unexploited despite its potentials, which is due to paucity of information and lack of awareness of the composition. Research shows that tiger nut can be a valuable source of nutrients and phytochemicals as it favourably compared with the proximate and mineral composition of some other edible nuts and tubers” (2).

“*Cyperus esculentus* is an annual or perennial plant called chufa sedge, nut grass, a mildly poisonous crop of the sedge family. It is found wild as a weed (3) or as a crop often cultivated for its edible tubers in many countries including Nigeria”. “Tiger nut, a tuber with sweet and nutty taste can be consumed raw, roasted, dried or as tiger nut milk or oil” (2). “It can be stored and rehydrated by soaking without losing the crop texture which ensures acceptable sensory quality (4). *Cyperus esculentus* may help to cure erectile dysfunction” (5). This finding was later corroborated by the works of Izunwanne (6).

“Infertility is on the increase especially in the developing countries. However, male infertility is commonly due to deficiencies in the semen, and semen quality is used as a surrogate measure of male fecundity” (7).

Going forward, the link between semen quality and fertility has been studied in humans since 1930 (8). “Semen analysis, as a standard laboratory test, gives basic information on spermatogenesis, secretory activity of the gonads, patency

of the male genital tract and semen morphological aberrations” (9). The results of the sperm sample analysis could reveal the lack of spermatozoa, a severe or minor sperm parameter deviation, or normal values for semen volume, sperm count and concentration, motility, and spermatozoa morphology. “Over the years many reproductive specialists have been constantly debating, suggesting and remodeling the frame values of the semen in reference to male fertility. Since 1987, there are several updates in different editions of World Health Organization (WHO) manuals defining the optimal sperm parameters with reference to pregnancy outcomes”. The fifth edition of the manual, published in 2010, defines serious decrease in cut-off values for sperm parameters related to chances of achieving pregnancy and thus its significance was widely discussed (10;11). “One of the strong limitations of semen analysis and the defined fertility potential references in the last WHO edition is the lack of correlation with the female age, as only 30% of infertility in couples is due to male factors alone” (12;13).

2. Methods

2.1 Procurement of Tiger nut tubers and its Authentication

Tiger nut tubers were obtained from the local market at Owerri city, Imo State. The tiger nuts were identified and authenticated at the herbarium of the Department of Plant Science and Biotechnology, Faculty of Natural Sciences, Michael Okpara University of Agriculture, Umudike, Abia State. Its Voucher number is: MOUAU/ZEB/19/004.

The tubers were cleaned, washed, and dried in a stream of hot air for an hour to make tiger nut powder. A laboratory electric mill was used to mill the dried tubers. **2.2 Chemicals and Reagents**

All chemicals used were purchased from Sigma Chemicals, St Louis, USA and were of analytical grade. Kits for evaluation of liver and kidney functions, lipid profile and lipid peroxidation were products of Quimica Clinica Applicada (QCA), Spain.

2.3 Procurement of Experimental Animals

“Healthy two-month-old wistar rats weighing 160-200g were obtained from the University of Port Harcourt's Pharmacology Department (Rivers State). The rats were kept in wooden netted cages in an environmentally controlled room with a 12:12 hour light/dark cycle and a temperature of around 25°C. Pellets (Lab Feeds) and tap water were used to feed them. The rats were allowed to acclimatize to laboratory environment for 21 days before experimentation” [31]. All experimental protocols were subjected to the scrutiny and approval of Institutional Animal Ethics Committee.

2.4 Preparation of plant extract

“The collected fresh tubers were dried in the shade at 25°C for two weeks and thereafter, pulverized in a locally fabricated milling machine. Six hundred (600) grams of the pulverized material was packed into the material chamber of the Soxhlet extractor and extracted by ethanol at a specific temperature (60°C) for 48 hr” [31]. “At the completion of extraction, the solvent in the extract was evaporated at 40°C in a hot air oven to obtain a crude extract which weighed 49.18 g, representing a yield of 49.18%. The extract was preserved in the refrigerator until needed and is hereafter referred to as *C. esculentus* extract” [31].

2.5 Acute Toxicity Test.

“The oral median lethal dose (LD₅₀) of the extracts was determined in rats” according to the method of Lorke, (14). “The study was carried out in two phases. In the first phase, nine (9) rats were divided into 3 groups of 3 rats each and were treated with the extract at doses of 10, 100 and 1000mg/kg body weight respectively after which they were observed for 24 hours for signs of toxicity and/ or mortality”[31]. “Based on the results of the first phase, 9 rats were again divided into 3 groups of 3 rats each and were also treated with the extract at doses of 1600, 2900 and 5000 mg/kg body weight respectively in the

second phase. The rats were also monitored 24 hours after treatment and for signs of toxicity and/or mortality. The median lethal dose (LD₅₀) of each extract was estimated based on the observations in the second phase” [31].

2.6 Preparation of Tiger-nut diet and plan of the experiments

“Tiger-nut powder and the animal feed was weighed and calculated to give exactly the ratio of the tiger nut meal needed. For 20% of the tiger nut meal, 20g of tiger-nut powder was added to 80g of the animal feed (high dose) while for 10% of the tiger nut meal, 10g of tiger-nut powder was added to 90g of the animal feed (low dose). The feed was thoroughly mixed before giving it to the animals for consumption” [31].

2.7 Experimental Design

- Group 1. Normal Control
- Group 2 Negative control (BPH)
- Group 3 dysfunction + Low dose (10% of meal)
- Group 4 dysfunction + high dose (20% of meal)
- Group 5 Normal + Low dose (10% of meal)
- Group 6 Normal + high dose (20% of meal)

Note: The average weight of the rats is 180g and the administration of the tiger nut meal lasted for two months.

2.8 Induction of Benign Prostate Hyperplasia

“Rats in the test groups (groups 2, 3 and 4) weighing between 160 - 200g were given 30mg/kg sub-cutaneous injections of hormones containing Dihydrotestosterone and estradiol valerate dissolved in olive oil in the ratio of 10:1 (three times in a week) as described” by Izunwanne (6).

The drugs used were purchased from Sigma Chemicals, St Louis, USA and were of analytical grade. The administration of the tiger nut meal commenced immediately after the induction and it lasted a period of two months.

2.9 Collection of blood Sample

The rats were anaesthetized by a brief exposure to chloroform vapour and bled extensively by heart puncture after two months of receiving the extract. The sera were isolated with care and utilised for biochemical analysis. The prostates of each rat were carefully removed when the body was dissected. Two prostates were randomly picked from each group and processed for histopathology right away. The remaining prostates in each group were defamed, rinsed in cold normal saline, blotted with filter paper, and weighed on a sensitive balance.

2.10 Qualitative Phytochemical Studies on *Cyperus esculentus*

Phytochemical methods of Trease and Evans (15) and Harborne (16) were used in the study.

2.11 Quantitative Phytochemical Analysis of *Cyperus esculentus*

The quantitative phytochemical analysis of *Cyperus esculentus* was determined using standard methods described by (16,17,18 and 19)

2.12 Semen Collection and Analysis

The epididymal reserve was used to extract the sperm cells. Chloroform (inhalation) was used to anaesthetize the rats, and their epididymis was removed. For evaluation, the caudal section of each epididymis was incised and a smear was formed on preheated glass slides.

2.12.1 Macroscopic Examination

The semen colour and pH were evaluated macroscopically and recorded. The pH scale (1-14), adopted by (20) was used.

2.12.2 Abnormal Sperm Proportion

“The abnormal sperm proportion was determined by the method described by (21). A drop of the semen was stained using E/N stain and the mixture smeared on a glass slide and viewed under a lower magnification of $\times 40$ to check for primary and secondary abnormal sperm cells, percentage of the differential abnormalities such as head abnormalities, tail abnormalities, mid-piece abnormalities etc” [21].

$$\text{GONADOSOMATIC INDEX (RELATIVE ORGAN WEIGHT)} = \frac{\text{Weight of Organ (g)} \times 100}{\text{Live Weight(g)}}$$

2.13 Statistical Analysis

Statistical analysis was carried out using windows (SPSS version 15.0). The data was analysed with a one-way ANOVA followed by a post hoc test for the least significant difference (LSD), and the charts were created with Microsoft Excel. The data was presented as a mean \pm SEM, with $p < 0.05$ being considered significant.

3. Results

3.1 Effect on Semen pH (1-14)

Table 1 shows that the level of the semen pH in the normal control group was 6.99 ± 0.05 . After induction of BPH, there was a significant decrease in the level of semen pH of the sperm cells to about (6.48 ± 0.04) in the negative control group ($p < 0.05$).

Treatment of the BPH with the tiger nut meal after induction shows that, at low dose of 10% (7.08 ± 0.01), the level of semen pH increased significantly from 6.48 ± 0.04 in the negative control to 7.08 ± 0.01 in the treatment group. However, treatment with high dose (20%) (6.98 ± 0.05) of tiger nut meal showed same significant increase of the pH level of the semen in the animals ($p < 0.05$).

Again, the administration of tiger nut meal to the rats under normal condition (i.e without induction of BPH) did not show any statistical difference when compared with the normal control ($p < 0.05$).

Table 1: Effect of tiger nut meal on the Semen pH in rats

Parameters	Control	Induction Only	Induction + Low dose	Induction + High dose	Low dose (10%)	High dose (20%)
Semen pH (1-14)	6.99±0.05 ^b	6.48±0.04 ^a	7.08±0.01 ^b	6.98±0.05 ^b	6.95±0.04 ^b	6.97±0.04 ^b

Values are mean ± SEM, n=10, parameters in the row with the same alphabet are statistically the same ($p > 0.05$), parameters with different alphabets are statistically difference ($p < 0.05$)

3.2 Effect on Sperm concentration (Sperm count) (ml)

Table 2 shows that the level of the proportion of live sperm in the normal control group was 111.19 ± 2.07 . After induction of BPH, there was a significant decrease in the level of sperm concentration to about (76.48 ± 3.12) in the negative control group ($p < 0.05$).

Treatment of the BPH after induction shows that, at low dose of 10% (100.01 ± 2.62), the level of sperm concentration increased significantly from 76.48 ± 3.12 in the negative control to 100.01 ± 2.62 in the treatment group. However, treatment with high dose (20%) (112.34 ± 1.72) of the tiger nut meal showed more significant increase in the level of the sperm concentration in the animals ($p < 0.05$).

On the effect of administering tiger nut meal to the rats under normal condition, both the low dose and the high dose groups of normal rats, which were not induced with BPH has no statistical difference when compared with the normal control ($p < 0.05$).

Table 2: Effect of tiger nut meal on the Semen pH in rats

Parameters	Control	Induction Only	Induction + Low dose	Induction + High dose	Low dose (10%)	High dose (20%)
Sperm conc.	111.19±2.07c	76.48±3.12a	100.01±2.62b	112.34±1.72c	118.31±0.69c	109.92±2.9c

Values are mean ± SEM, n=10, parameters in the row with the same alphabet are statistically the same (p>0.05), parameters with different alphabets are statistically difference (p<0.05)

3.3 Effect on Glutathione (u/L)

Table 3 shows that the level of the Glutathione in the normal control group was 42.98 ± 0.66 . After induction of BPH, there was a significant decrease in its level to about (35.18 ± 0.84) in the negative control group ($p < 0.05$).

Treatment of the BPH with the tiger nut meal after induction showed that, at low dose of 10% (40.06 ± 0.77), the level of glutathione increased significantly from 35.18 ± 0.84 in the negative control to 40.06 ± 0.77 in the 10% treatment group while that of high dose (20%) increased to 42.73 ± 0.82 at $p < 0.05$.

Tab 3: Effect of tiger nut meal on the Glutathione in rats

Parameters	Control	Induction Only	Induction + Low dose	Induction + High dose	Low dose (10%)	High dose (20%)
Glutathione (u/L)	42.98±0.66 ^c	35.18±0.84 ^a	40.06±0.77 ^b	42.73±0.82 ^{bc}	45.17±0.62 ^{cd}	46.1±0.21 ^d

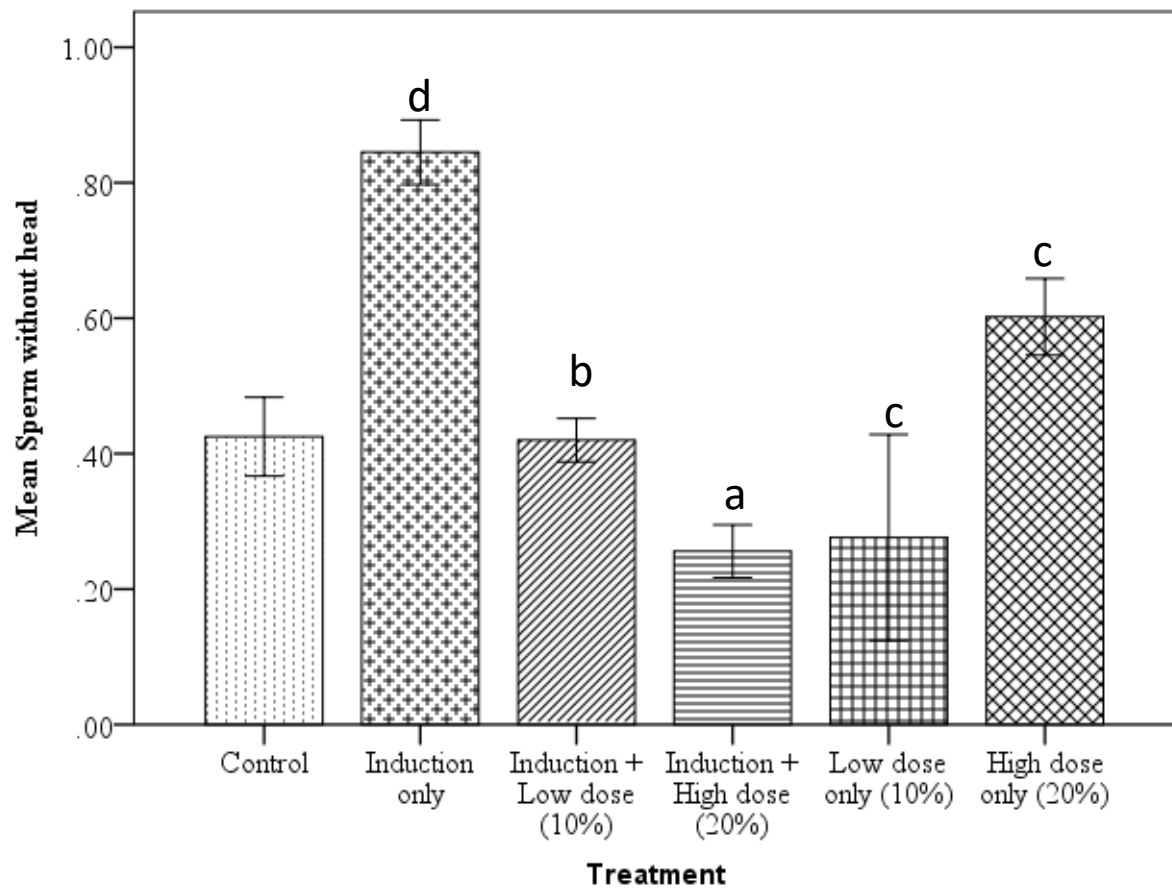
Values are mean ± SEM, n=10, parameters in the row with the same alphabet are statistically the same (p>0.05), parameters with different alphabets are statistically difference (p<0.05).

3.4 Effect of the tiger nut meal on the sperm cells without head (%)

Figure 1 shows that the level of the sperm cells without a head in the normal control group was 0.43 ± 0.03 . After induction of BPH, there was a significant increase in the number of sperm cells without a head to 0.85 ± 0.02 in the negative control group ($p < 0.05$).

Treatment of the BPH with the tiger nut meal after induction showed that, at low dose of 10% (0.42 ± 0.02) and a high dose (20%) (0.26 ± 0.02) of the tiger nut meal, a significant decrease in the number of the sperm cells without a head was recorded when compared with the negative control of 0.85 ± 0.02 ($p < 0.05$). The treatment of the said BPH with tiger nut was able to positively restore the morphology of the sperm by improving the quality of the head of the sperm cells. This finding suggests that, tiger nut may have a strong ameliorative effect on the morphological aberration of the sperm head.

Furthermore, the administration of tiger nut meal to the rats under normal condition at low dose of 10% (0.28 ± 0.08) and that of high dose (20%) 0.60 ± 0.03 . The high dose has no statistical difference when compared with the normal control ($p > 0.05$) but that of low dose is statistically different from both the normal control and that of the negative control ($P < 0.05$).



Values are expressed as mean \pm SEM, n=10

d = $P < 0.05$ vs control

b = $P < 0.05$ vs induction only

a = $P < 0.05$ vs induction only

c = $P < 0.05$ vs induction only

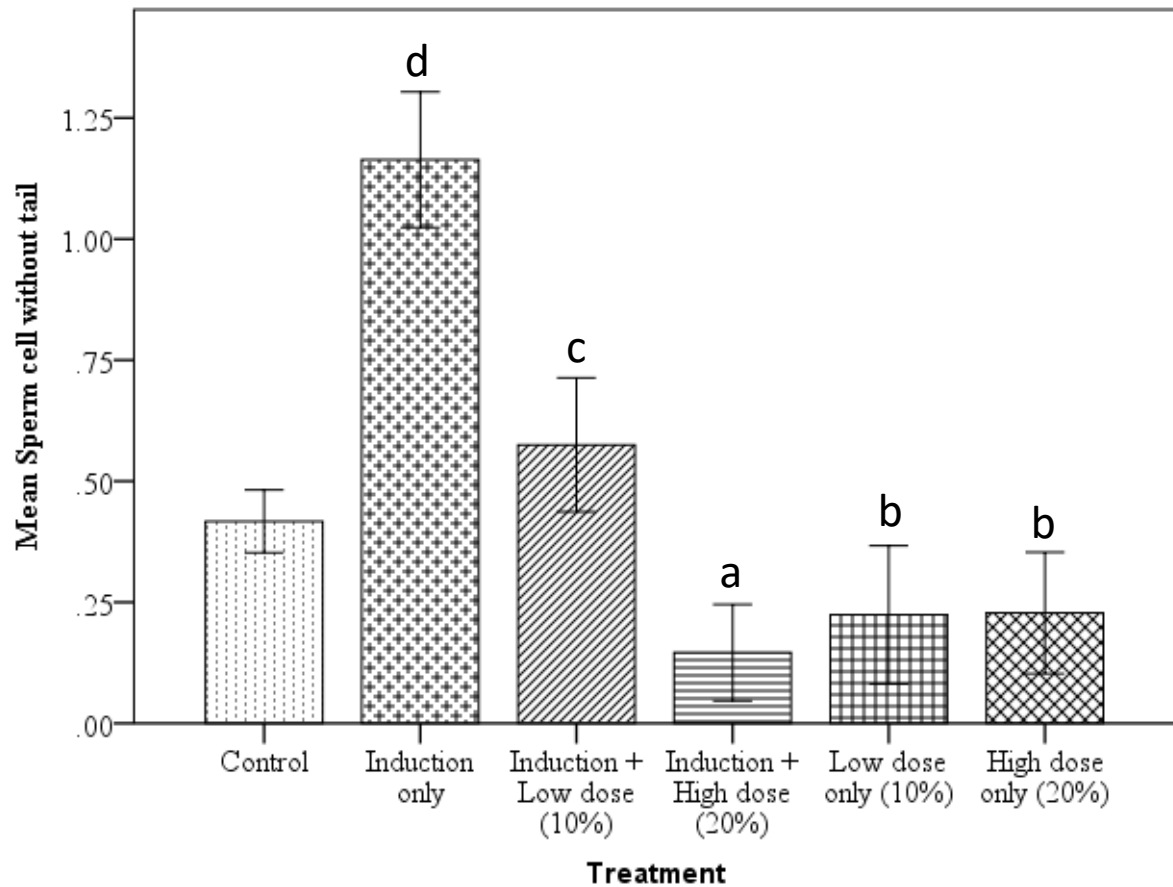
Fig 1: Effect of tiger nut meal on the Sperm without head in rats

3.5 Effect of the tiger nut meal on sperm cells without a tail (%)

Figure 2 shows that the level of the sperm cells without a tail in the normal control group was 0.42 ± 0.03 . After induction of BPH, there was a significant increase in the level of sperm cells without a tail to 1.16 ± 0.07 in the negative control group ($p < 0.05$).

Treatment of the BPH with the tigernut meal showed that, at low dose of 10% (0.58 ± 0.07) and a high dose (20%) (0.15 ± 0.05) of the tiger nut meal, a significant decrease in the number of sperm cells without a tail in the sample was recorded when compared with the negative control of 1.16 ± 0.07 ($p < 0.05$).

Furthermore, the administration of tiger nut meal to the rats under normal condition at low dose of 10% (0.22 ± 0.07) and that of high dose (20%) 0.23 ± 0.06 also showed no statistical difference when compared with the positive control ($p > 0.05$).



Values are expressed as mean \pm SEM, n=10.

d = $P < 0.05$ vs control

c = $P < 0.05$ vs induction only

a = $P < 0.05$ vs induction only

b = $P < 0.05$ vs induction only

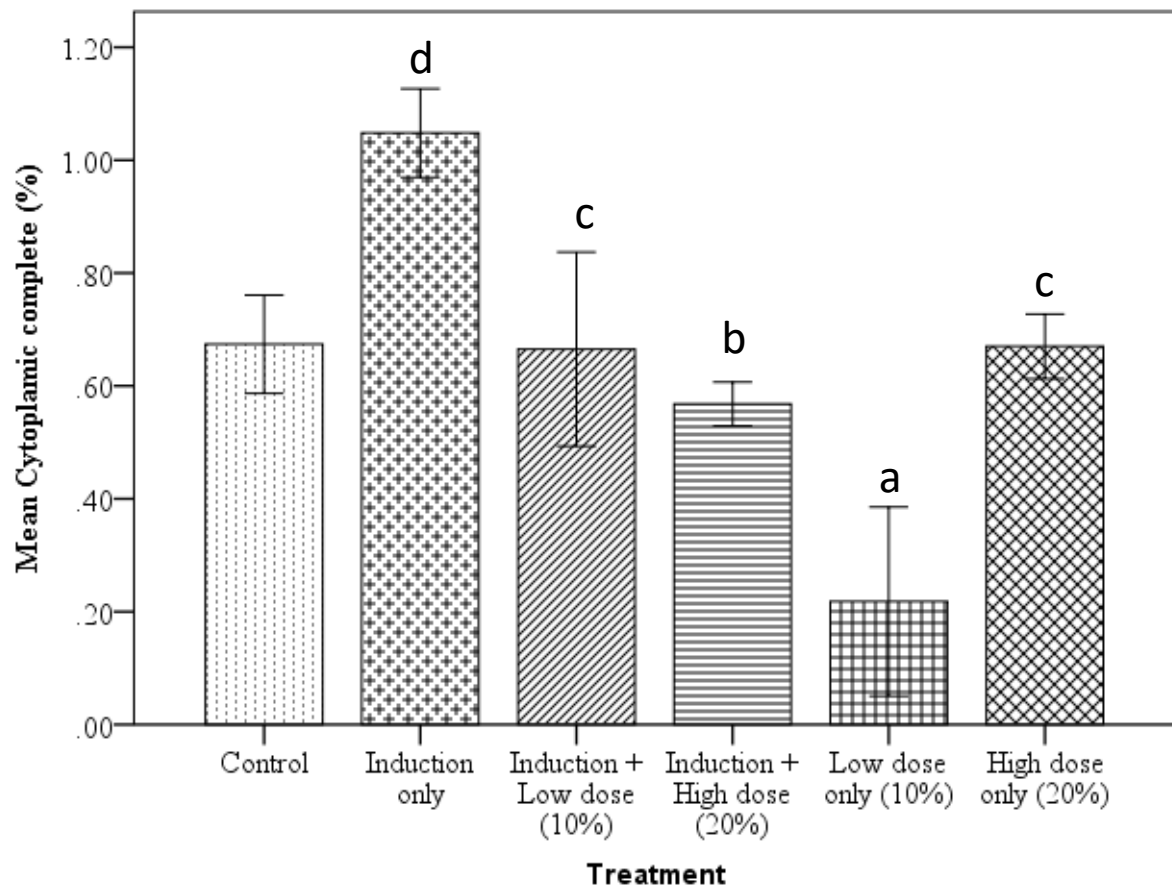
Fig 2: Effect of tiger nut meal on the Sperm without tail in rats

3.6 Effect of the tiger nut meal on sperm cells with cytoplasmic complete (Cytoplasmic droplets) (%)

Cytoplasmic droplets are a normal component of mammalian sperm cell but, are merely abnormal, since they cannot and do not undergo maturation in the epididymis. Its presence is indeed indicative of abnormal spermiogenesis and may result in infertility.

Figure 3 shows that the percentage of the cytoplasmic droplets in the normal control group was 0.67 ± 0.04 . After induction, there was a significant increase in the level of cytoplasmic droplet to about 1.05 ± 0.04 in the negative control group ($p < 0.05$).

Treatment of the BPH with the tiger nut meal after induction showed that, at low dose of 10% (0.67 ± 0.09) and a high dose (20%) (0.57 ± 0.02) of the tiger nut meal, a significant decrease in the level of the cytoplasmic droplets were recorded in the animals when compared with the negative control of 1.05 ± 0.04 ($p < 0.05$). Again, on the administration of tiger nut meal to the rats under normal condition, there is however, no statistical difference when the low and high doses therapy is compared with the normal control ($p > 0.05$).



Values are expressed as mean \pm SEM, n=10.

d = $P < 0.05$ vs control

b = $P < 0.05$ vs induction only

c = $P < 0.05$ vs induction only

a = $P < 0.05$ vs control

Fig 3: Effect of tiger nut meal on the cytoplasmic complete (droplets) in rats

4. Discussion

The effect of *Cyperus esculentus* (tiger nut) on semen parameters namely; semen pH and sperm concentration (count) were studied. The results of these studies showed that tiger nut ameliorated the low levels of semen pH as well as enhancing the sperm concentration in the animals with induced BPH. Furthermore, there was no significant difference noticed in these two parameters in the non-induced animals when compared with the normal controls. This finding showed that tiger nut may more effective in corrective/ameliorating known effects in sperm cells defects. The overall effect/finding may be associated with the increase in testosterone hormone level and is consistent with previous work of Izunwanne (6)

On the effect of *Cyperus esculentus* (tiger nut) on Glutathione antioxidant activity, the result showed a significant increase in the level of glutathione following the administration of tiger nut meal. “Glutathione is a powerful antioxidant that is made in the body’s cells. Its levels decrease as a result of aging, stress and toxin exposure. Boosting glutathione may provide many health benefits against stress and free radicals”. “It is the first line of defence against violent attackers of the cells of the human body namely; free radicals, chemical toxins, radiation and heavy metals that enters our body through the environment and the food and liquids we consume, thus, earning the title of master antioxidant”.

Generally, studies demonstrate that an antioxidant-rich diet has a very positive health impact in the long run (21; 22). Recently, “antioxidants have attracted considerable attention in relation to radicals and oxidative stress, cancer prophylaxis and therapy, and longevity” (23). “All the antioxidants are working together as one (antioxidant system), and they are responsible for prevention of the damaging effects of free radicals and toxic products of their metabolism”

[23]. However, “the antioxidant (team) acts to control levels of free radical formation as a coordinated system where deficiencies in one component impact the efficiency of others” (24).

“Sperm cells are fragile and have a long gauntlet to run from the time of manufacture in the testes, until they arrive at their intended destination. They are usually exposed to a subset of free radical compounds known as reactive oxygen species (ROS)” [24]. “While low levels of ROS play critical role in the normal functioning of sperm cells, an increased concentration can damage the fatty tissue that forms the membrane of the sperm cells resulting in reduced motility and negatively impacting its ability to fuse with a female egg”. ROS can also alter sperm DNA, resulting in the passage of defective paternal DNA on the foetus and thus, making a successful pregnancy unlikely. Therefore, “the cumulative and synergistic activities of the bioactive molecules present in the tiger nut meal are responsible for their enhanced antioxidant properties as well as reproductive function”.

On the effect of *Cyperus esculentus* (tiger nut) on different sperm cells morphological abnormalities namely; sperm cells without head, sperm cells without tail and cytoplasmic complete (droplets), the results of this study showed that tiger nut ameliorated the high levels of sperm cells without a head, sperm cells without a tail and sperm cells with cytoplasmic complete (droplets). In the non-induced rats, tiger nut also reduced the levels of this same parameters. However, it is imperative to note here that the low dose therapy showed more potent effect than the high dose therapy in significantly reducing the levels of sperm cells without head and cytoplasmic droplets in the rats.

Vast majority of literature on ‘cytoplasmic droplets’ of human sperm considers them to be indicative of abnormality with sperm being described as of ‘diminished maturity’ (25) or ‘immature sperm’ (26). According to Trevor *et al.* (27), excess cytoplasmic droplets have been associated with sperm from

smokers (28) and men with varicocele (29) and with deficiencies in sperm DNA (30) and phospholipid-bound docosahexanoic acid (29), its presence is indeed indicative of abnormal spermiogenesis. Such sperm should not be described as of 'diminished maturity' (25) or as immature (26), but merely abnormal, since they cannot and do not undergo maturation in the epididymis. The ameliorative effect of the tiger nut meal on the cytoplasmic droplets as well as other morphological defects could be associated with its increased antioxidant effect. Other possible mechanism responsible for the reduced levels of morphological abnormalities of semen parameters may be associated with the tiger nut enhancing the activities of the Sertoli and Leydig cells of the testes.

5. CONCLUSION

1. Tiger nut meal enhances the pH of the semen.
2. Tiger nut meal enhances the sperm count
3. Tiger nut meal enhances the level of glutathione antioxidant activities
4. Tiger nut meal ameliorates and enhances some of the morphological defect of sperm cell such as sperm cells without a head, sperm cells without a tail and cytoplasmic droplet.

ETHICAL APPROVAL

All experimental protocols were subjected to the scrutiny and approval of Institutional Animal Ethics Committee.

COMPETING INTERESTS DISCLAIMER:

Authors have declared that they have no known competing financial interests OR non-financial interests OR personal relationships that could have appeared to influence the work reported in this paper.

References

- 1 Zhang Y, Huang C, Liu S, Bai J, Fan X, Guo J: Effects of quercetin on intracavernous pressure and expression of nitrogen synthase isoforms in arterial erectile dysfunction rat model. *Int J Clin Exp Med*. 2015 8(5):7599–605.
- 2 Rita, E.S. The use of tiger nut, cow milk and their composite as substrates for yoghurt production. *Park. J. Nutr.*, 2009. 6:755758
- 3 Sanchez-Zapata, Juana Fernandez-Lopez and Jose Angel Perez-Alvarez (2012). Tiger nut commercialization: Health Aspects, Composition, Properties and Food Applications. Institute of Food Technologists, June, 2012.
- 4 Tucson and Arizona. USGS Weed in the West project: Status of introduced plants in Southern Arizona Parks, Factsheets for *Cyperus esculentus* L. 2003. 6(5): 5449-5454.
- 5 Allouh, Z. Mohammed., Haytham M. Daradka and Jamaledin H. Abu Ghaida: Influence of *Cyperus esculentus* tubers (Tiger Nut) on male rat copulatory behaviour. *BMC Complementary and Alternative Medicine*. 2015. 15:331.
- 6 Izunwanne DI, Egwurugwu JN, Emegano CL. Effect of Tiger Nut Meal on PSA, Relative Organ Weight Sperm Cell and Histological Changes in Androgen-induced Benign Prostate Hyperplasia in Adult Male Wistar Rats. *European Journal of Medicinal Plants*. 2020a. 31(15): 1-10
- 7 Cooper TG, Noonan E, von Eckardstein S, Auger J, Baker HW, Behre HM, Haugen TB, Kruger T, Wang C, Mbizvo MT, Vogelsong KM. "World Health Organization reference values for human semen characteristics". *Human Reproduction Update*. 2009. 16 (3): 231–45.
- 8 Andrade-Rocha FT. On the origins of the semen analysis: A close relationship with the history of the reproductive medicine. *Journal of Human Reproduction*. 2017; 10(4):242-255.
- 9 Vasan SS. Semen analysis and sperm function tests: How much to test? *Indian Journal of Urology*. 2011;27(1):41-48. DOI: 10.4103/0970-1591.78424
- 10 Murray KS, Andrew J, McGeady J, Reed ML, Kuang WW, Nangia AK. The effect of the new 2010 World Health Organization criteria for semen analyses on male infertility. *Fertility and Sterility*. 2012; 98(6):1428-1431. DOI: 10.1016/j. fertnstert.2012.07.1130. [Epub: 24 August 2012]

- 11 Alshahrani S, Aldossari K, Al-Zahrani J, Gabr AH, Henkel R, Ahmad G. Interpretation of semen analysis using WHO 1999 and WHO 2010 reference values: Abnormal becoming normal. *First International Journal of Andrology Andrologia*. 2018;50(2):128-138. DOI: 10.1111/and.12838
- 12 Patel A, Leong JY, Ramasamy R. Prediction of male infertility by the World Health Organization laboratory manual for assessment of semen analysis: A systematic review. *Arab Journal of Urology*. 2018 16:96-102.
- 13 Esteves SC, Zini A, Aziz N, Alvarez JG, Sabanegh ES Jr, Agarwal A. Critical appraisal of World Health Organization's New reference values for human semen characteristics and effect on diagnosis and treatment of subfertile men. *Urology*. 2012; 79:16-22.
- 14 Lorke D. A. New approach to practical acute toxicity testing. *Archives of Toxicology*. 1983. 54: 275-287.
- 15 Harborne, J. B. *Phytochemical Methods: A Guide to Modern Technology of Plant Analysis*. 2nd Edn. Chapman and Hall, New York. 1983. p 113.
- 16 Obadoni, B.O. and Ochuko, P.O. Phytochemical studies and comparative efficacy of the crude extract of some homeostatic plants in Edo and Delta States of Nigeria. *Global Journal of Pure and Applied Sciences* 2001. 8: 203-208.
- 17 Boham, B.A. and Kocipai, A.C. Flavonoids and condensed tannins from the leaves of Hawaiian *Vaccinium vaticulatum*. *Pacific Sciences*, 1994. 48: 458 - 463.
- 18 Nabavi, S.M., Ebrahimzadeh, M.A., Nabavi, S.F., Hamidinia, A. and Bekhradnia, A.R. Determination of antioxidant property, phenol and flavonoid contents of *parotia persica meyer*. *Pharmacology Online*. 2008. 2: 560-567.
- 19 Chibundu, U.C. Response of pre-pubertal bucks to administration of estradiol B. Project Report, Federal University of Technology, Owerri. 2013. Pp.30
- 20 El-Sherbiny, A.M. Seasonal variation in seminal characteristics of rabbits. M.Sc. Thesis, Fac. of Agric., Ain-Shams University. 1987.
- 21 Willis L.M., Shukitt-Hale, B. and Joseph, J.A. Recent Advances in Berry Supplementation and Age-Related Cognitive Decline. *Current opinion in clinical nutrition and metabolic care*. 2009. 12(5): 91-94
- 22 Sin, H.P.Y., Liu, D.T.L. and Lam, D.S.C: Life style Modification, Nutritional and Vitamins Supplements for Age-Related Macular Degeneration. *Acta Ophthalmologica*. 2013. 91: pp. 6-11.

- 23 Kalcher, K., Svancara, I., Buzuk, M., Vytras, K. and Walcarius, A: Composition of the human semen and of the secretions of the prostate and seminal vesicles. *Am J Physiol.* 2009. 136(3):467-473.
- 24 Peter, F.S: Natural Antioxidants in Poultry Nutrition: New Developments. 16th *European Symposium on Poultry Nutrition*, 2007. p. 669-676.
- 25 Gergely A, Kovanci E, Senturk L, Cosmi E, Vigue L and Huszar G. Morphometric assessment of mature and diminished-maturity human spermatozoa: sperm regions that reflect differences in maturity. *Hum Reprod* 1999. 14:2007–2014.
- 26 Ollero M, Powers RD and Alvarez JG. Variation of docosahexanoic acid content in subsets of human spermatozoa at different stages of maturation: implications for sperm lipoperoxidative damage. *Mol Reprod Dev* 2000. 55: 326–334.
- 27 Trevor, G. C., Ching Yeung, Sabina F.A., Eberhard, N. Cytoplasmic droplets are normal structures of human sperm but are not well preserved by routine procedures for assessing sperm morphology. *Human Reproduction*, 2004. 19(10):2283–2288.
- 28 Mak V, Jarvi K, Buckspan M, Freeman M, Hechter S and Zini A. Smoking is associated with the retention of cytoplasm by human spermatozoa. 2000.
- 29 Zini A, Defreitas G, Freeman M, Hechter S and Jarvi K. Varicoele is associated with abnormal retention of cytoplasmic droplets by human spermatozoa. *Fertil Steril* 2000. 74: 461–464.
- 30 Fischer MA, Willis J and Zini A. Human sperm DNA integrity: correlation with sperm cytoplasmic droplets. *Urology* 2003. 61: 207–211.
- 31 Izunwanne DI. PSA, Sperm Midpiece, Relative Organ Weight, Histological Changes in Adult Male Wistar Rats Treated with Tiger Nut Meal. *cell. Pathobiology and Physiology* Vol.4 iss.S2 2020