

# **Percutaneous retrograde screw fixation of the acetabulum: A case report**

## **Abstract**

### **Introduction:**

Percutaneous screw fixation techniques for pelvic fractures are mainly described in the management of posterior arch fractures. More recently, improved imaging technology and means for closed reduction have meant that percutaneous techniques have gained popularity in the treatment of acetabular fracture.

The objective of this study is to evaluate the feasibility and interest of percutaneous screw fixation in minimally displaced acetabular fractures.

### **Observation:**

We present the case of an 18-year-old female patient with a psychiatric history who was a victim of defenestration.

The radiological exam revealed a fracture of the right sacral ala associated with a minimally displaced T fracture of the left acetabulum. The patient had a percutaneous right sacroiliac screwing and a percutaneous retrograde screw fixation of the left acetabular posterior column. A psychiatric follow-up was carried out. Touch-down weightbearing is allowed for the first three weeks with crutch. The postoperative course was simple. A postoperative CT scan confirmed the correct placement of the screw. Support was allowed after 45 days. No complications were observed at the last 12-month follow-up.

### **Discussion:**

Orthopedic treatment of minimally displaced or nondisplaced acetabular fractures provides good radiological results but does not allow early mobilization and rehabilitation and exposes to decubitus complications. Percutaneous retrograde screw fixation is a reliable and reproducible technique that allows rapid ambulation while avoiding the complications of conventional surgery, such as bleeding, vascular and nerve damage, and heterotopic ossifications.

### **Conclusion:**

Percutaneous acetabular screw fixation is a safe and reliable technique for the management of non-displaced and minimally displaced acetabular fractures.

**Key words:** Acetabular fracture, percutaneous screwing, case report.

## Introduction:

Acetabular fractures result from high-energy trauma, frequently associated with severe thoraco-lumbar trauma. This type of fracture raises a problem of therapeutic strategy due to the variety of fracture types. Many would consider open reduction and internal fixation the benchmark for the treatment of displaced fractures. Due to the bleeding nature of these fractures, the development of minimally invasive techniques has been explored. Initial descriptions of a percutaneous surgical technique were described in the late 2000s as a treatment option for select acetabular fractures [1].

The objective of this study was to present a case of a minimally displaced T fracture of the acetabulum and highlight the feasibility and interest of percutaneous screw fixation.

## Observation:

We present the case of an 18-year-old female patient with a psychiatric history who was a victim of a polytrauma due to a height fall. After patient stabilization, the radiological exam revealed a fracture of the right sacral ala without neurological deficit, right obturator foramen fracture associated with a minimally displaced T fracture of the left acetabulum (Figure 1). Surgery was performed under general anaesthesia. The patient was placed on supine position with the sacrum elevated on several blankets as a bump. The patient had a percutaneous right sacroiliac screw and a percutaneous retrograde screw fixation of the left acetabular posterior column. Retrograde posterior column screw was placed directly from the medial half of the ischium with the hip and knee flexed. Antero-posterior and orthogonal iliac and obturator oblique Judet views were used to advance the guidewire, with care taken to avoid medial wall and hip joint penetration (Figure 2) [2]. The postoperative follow-up was favorable. A postoperative CT scan confirmed the correct placement of the screw and an anatomical restoration of the joint according to the Matta criteria (Figure 3) [3].

A psychiatric follow-up was carried out. Touch-down weightbearing was allowed for the first three weeks with crutch. Support was allowed after radiological confirmation of bone healing at 60 days (Figure 4). At the last 12-month follow-up, no complications were observed and the functional results were considered very good according to the quotation of patient-reported outcomes measurement information system (PROMIS Mobility) [4].

## Discussion:

Our case study demonstrated the feasibility of retrograde percutaneous screw fixation of the posterior acetabular column in the supine position. The radiological and functional results in the medium term were considered good. Facing these acetabular fractures, we are faced with a therapeutic challenge. This fracture presents a relative low incidence: three patients/100,000/year [5], which explains the difficulty of gaining experience among young operators. Judet and Letournell classification remains the gold standard for studying fracture features [6]. When surgical treatment is indicated: There are different means available,

namely open reduction with osteosynthesis or percutaneous mini invasive approach. In fractures of the posterior column of acetabulum that are simple and minimally displaced, intramedullary screw fixation is advantageous over plate fixation because of its less invasive nature and lesser soft-tissue insult [7].

Advancements in percutaneous **fixation** techniques has led to the broader use of these techniques, particularly as it relates to minimise the potential for complications associated with large surgical wounds.

Surgical planning begins with the evaluation of the intramedullary corridor of the acetabular columns based on CT imaging [8]. Morphometric variations of this **corridor** have been described in the literature for its complex structure, which can influence the safe containment of intramedullary screw for fixation of its fractures [9]. The surgery can be performed under CT or fluoroscopic control. The antero posterior and obturator view shows the target of the long axis of the ischium, whereas the iliac oblique ensures that the wire is outside of the hip joint and the sciatic notch. If passing the screw retrograde, a true lateral shows the exit point [10-11]. The postoperative course is usually less severe than in open reductions. This is mainly due to the preservation of the blood supply and the absence of muscle damage. At the same time, it has the advantage of allowing early crutching compared to functional treatment without the risk of secondary displacement.

## **Conclusion:**

Although percutaneous acetabular surgery has a steep learning curve, providing a less-invasive option with rigid columnar fixation can yield earlier mobilization with weight bearing. Operative positioning and preparation as described are essential for successful outcomes using this technique.

## **Conflicts of interest**

The authors declare no conflicts of interest.

## **CONSENT**

As per international standard or university standard, patients' written consent has been collected and preserved by the author(s).

**Figures list:**

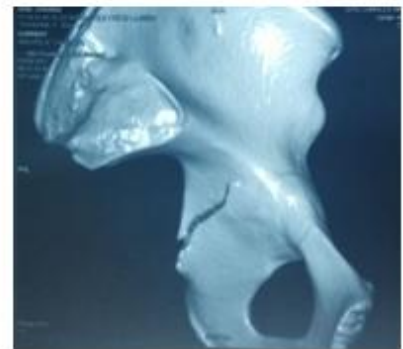
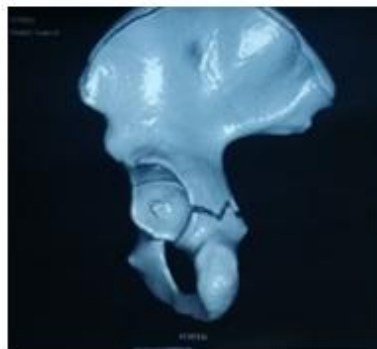
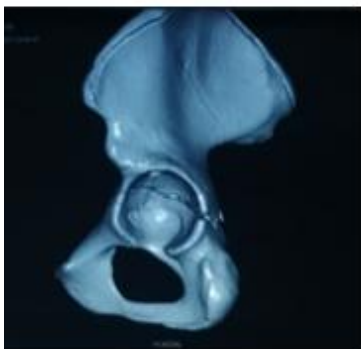
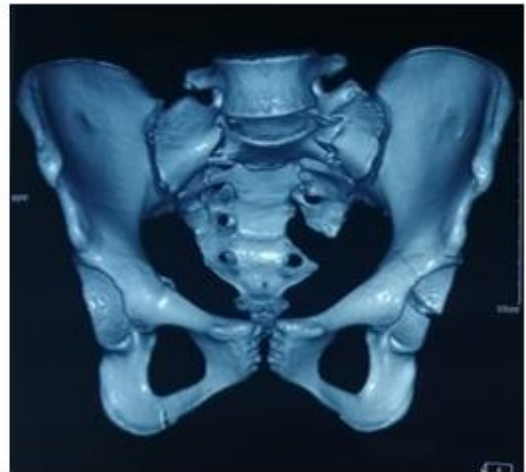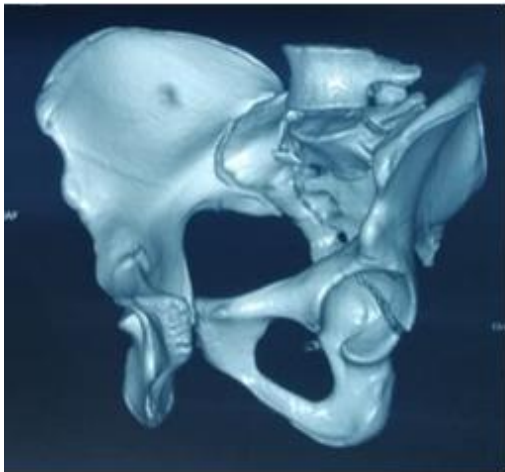


Figure1: 3 D scan of the pelvis

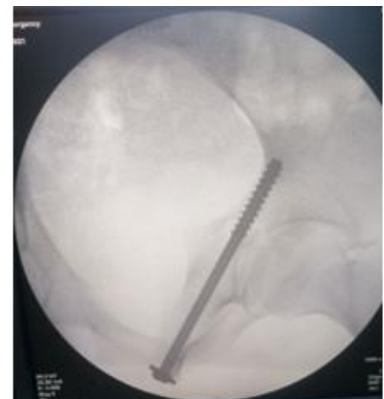
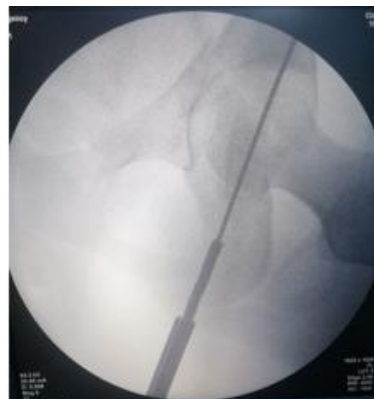
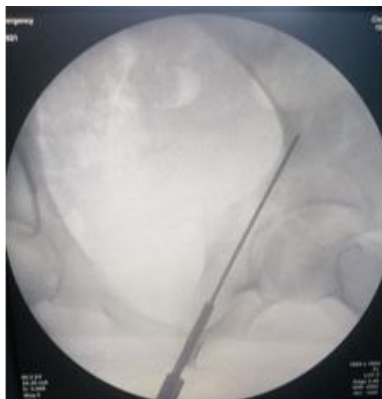Figure 2: Retrograde posterior column screw fixation

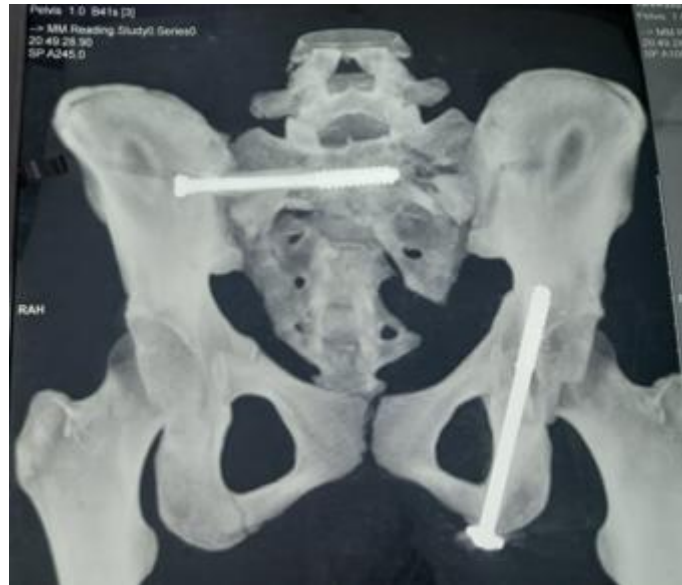

Figure 3: Postoperative CT scan of the pelvis

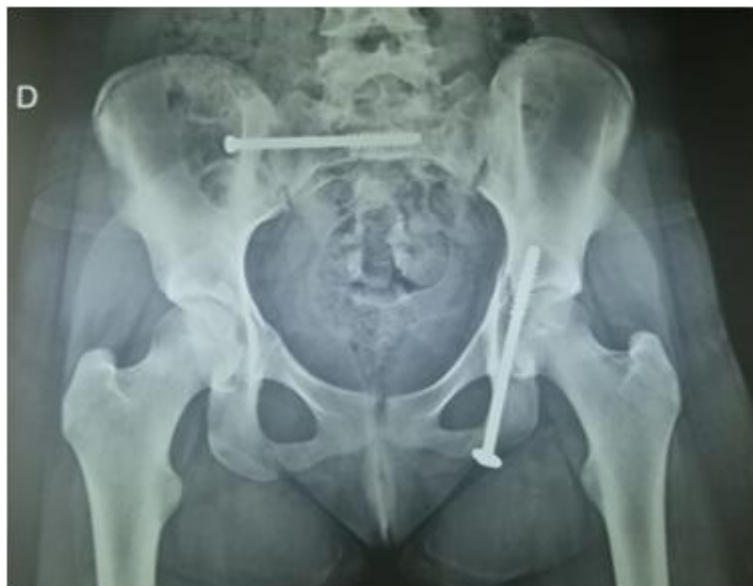

Figure 4: 45 days post operative X-ray of the pelvis

## References

- 1- Starr AJ, Reinert CM, Jones AL: Percutaneous fixation of the columns of the acetabulum: A new technique. J OrthopTrauma 1998;12:51-58.
- 2-Connelly CL, Archdeacon MT: Transgluteal posterior column screw stabilization for fractures of the acetabulum: A technical trick. J OrthopTrauma 2012;26:e193-e197.
- 3- Matta JM, Mehne DK, Roffi R. Fractures of the acetabulum early results of prospective study. Clin Orthop. 1986; 205: 241-250.
- 4- Timothy G., Brandon D., Katherine B., Pamela F. Patient-Reported Outcomes Measurement Information System Tools for Collecting Patient-Reported Outcomes in Children With Juvenile Arthritis. arthritis Care Res. 2017 Mar;69(3):393-402.
- 5- Laird A, Keating JF (2005) Acetabular fractures: a 16-year prospective epidemiological study. J Bone Joint Surg Br 87:969–973.
- 6- Judet R, Judet J, Letournel E (1964) Fractures of the acetabulum. ActaOrthopBelg 30:285–293
- 7-Dunet B, Tournier C, Billaud A, Lavoinne N, Fabre T, Durandea A. Acetabular fracture: long-term follow-up and factors associated with secondary implantation of total hip arthroplasty. OrthopTraumatolSurg Res 99(3):281–290.
- 8-Vivek T., Arvind K., Samarth M., Jigyasa P., Sahil G., Atin K.. Morphometric analysis of the anterior column of the acetabulum and safety of intramedullary screw fixation for its fractures in Indian population: a preliminary report. IntOrthop. 2020 Apr;44(4):655-664.
- 9- Bai Y., Liu Q., Zhongguo X., Fu C., Jian W., Ke Z. and al. Digital study of the ideal position of lag screw internal fixation in the anterior column of the acetabulum. 2021 Jun 15;35(6):684-689.
- 10-Daniel B., Adam J. S., Kelly A.L. Technical Considerations and Fluoroscopy in Percutaneous Fixation of the Pelvis and Acetabulum. J Am AcadOrthop Surg. 2019 Dec 15;27(24):899-908
- 11- João A. M., Murphy P., Flávio R., Maria E., Amanda Do., Jamila Al. and al. The obturator oblique and iliac oblique/outlet views predict most accurately the adequate position of an anterior column acetabular screw. IntOrthop. 2019 May;43(5):1205-1213.