

IMPLANT REMOVAL: CONSIDERATIONS IN A NIGERIAN TEACHING HOSPITAL SETTING

Abstract

Background: Orthopedic implants removal has several indications and may sometimes be a cause of controversy. Once there is union between ends of fractured bone, the implant stopped being important and can be removed. However, there are several considerations before and after removal including patient's choice, giving back the implant to the patient. Our study aimed to identify various indications and considerations for implant removal in a Nigerian Teaching setting.

Methods: Data were extracted from the operation register and patients' case folders on bio-data, diagnosis, type of surgical procedure, site of surgery, dates of surgery and removal of implant, indication for removal. Patients with complete medical record were included in this study.

Results: A total of 12 patients were studied, with 2 males and 10 females. There were 3 Pediatric patients aged 7, 10 and 18 months. Completion of therapy and peri-implant infection were the major consideration for removal of implants. We also found out that the most common implant at our setting was K-wire (41.7%) while femur bone was the major site of implant.

Conclusions: Peri-implant infection, completion of therapy in case of pediatric patients were the major considerations for implants removal. The femur was the most involved bone, all patients saw the implant after removal and this was documented.

Keywords: Hardware removal, Considerations, Implant.

1. INTRODUCTION

Bone is a dynamic tissue, undergoing constant remodeling, according to wolfs law, bone has the ability to regenerate with restorations of its biological and mechanical properties prior to damage [1, 2]. The human bone is a hard biological tissue and consists of cells resident in the bone matrix, which is made by an organic (primarily collagen (90%) and 10% amorphous ground substance) and a mineral phase [3]. The main constituents of bone mineral are calcium phosphate and calcium carbonate. The mineral components consist mainly of hydroxyapatite crystals and amorphous calcium phosphate. Bone acts as a reservoir for our body's calcium, also serves as a protector for vital organs, as well as provides mechanical stability to our body, and makes locomotion possible [4]. Diseases, disorders, fractures and trauma afflicting the skeletal system result in damage to the skeletal system. The resulting fractures and abnormalities in the skeletal system that arise can lead to an increase in mortality, with the severity of the mortality varying by bone [5, 6]. The bone has been regarded as the most transplanted tissue in the human body, after blood [7, 8]

The human bone can gain maximum strength with minimum mass due to continuous activities of various kinds of bone cells, i.e. osteocytes, osteoblasts, osteoclasts, and bone lining cells. There are continuous processes of bone resorption and formation in our bones from birth to death, which is so-called, bone remodeling process [5]. Bone remodeling aims to provide maximum strength with minimum mass to our bones. When a bone is broken, there is no other way than fixing it by employing man-made supportive structures. Bone healing can occur either via indirect or direct healing. Indirect, or secondary, fracture healing is the natural healing process of

bone and contains three phases that overlap temporally. Direct, or primary, healing only occurs when the fragments of the vascular bone surfaces are in contact and therefore only occurs as a result of rigid fixation usually with implants [7]. The same process is followed as indirect bone healing but bypasses the formation of the callus, since the vascular bone surfaces are already in contact [9].

Hardware implantation

Hardware implantation is essential for a variety of orthopedic surgical procedures ranging from joint replacement to fracture fixation [10, 11]. These orthopedic devices are implanted to serve permanent or temporary functions. Orthopedic implants become necessary with severe fractures—that are in need of realignment and fixation for proper healing—or in cases when bone altogether fails to regenerate, producing bone defects [10]. The design of these implants requires consideration of the material's bio- compatibility, mechanical properties, and surface properties as well as its chemical properties and failure properties so that the implant closely parallels the biomechanical properties of bone and integrates with the native tissue while maintaining its integrity for the requisite duration [12]. The cardinal requirements of bone tissue engineering can be summarized with the diamond concept, which provides four basic factors that are needed for successful bone healing with bone tissue engineering : a healthy population of osteogenic cells to permit bone regrowth, growth factors to effectuate cellular events to promote healing, an osteo-conductive scaffold conducive to bone growth, and a good mechanical environment to provide sufficient stability for healing while still mirroring the native tissue's mechanical properties [13]. Additionally, the patient's history needs to be taken into consideration, as risk factors be identified. [14]. For example, a patient's age can have great connotations related to the skeletal system, as aging is related to higher fracture rates and reduced fracture healing and is also

associated with conditions such as osteoporosis and osteoarthritis [15]. Another important consideration is the natural healing process of bone [16].

Orthopedic implants can be defined as medical devices used to replace or provide fixation of bone, or to replace articulating surfaces of a joint. These implants are used to either assist or replace damaged or troubled bones and joints. Orthopedic implants are mainly made from stainless steel and titanium alloys for strength and lined with plastic to act as artificial cartilage in order to reduce the stress at the articulating surfaces. Some implants are cemented into place and others are pressed to fit, so that your bone can grow into the implant for strength. Examples of orthopedic implants are: orthopedic plates, orthopedic nails, and orthopedic screws. The most commonly used metals and polymers for orthopaedic applications are stainless steel, cobalt-chromium alloys, titanium alloys, ultrahigh molecular weight polyethylene (UHMWPE), and polymethyl methacrylate (PMMA) [3]. The purpose of this study is to determine the considerations for implant removal and other variables of orthopedic hardware removal performed at Babcock University Teaching Hospital.

2. METHODS

A retrospective cross-sectional review of patients presenting who have had implants in our center over the last 2 years. This study was conducted at the orthopedic unit of Babcock University Teaching Hospital, Ilishan-Remo, South-western Nigeria. A retrospective study of all cases of implant removal performed in the Orthopedic Unit of Babcock University Teaching Hospital, Ilishan-Remo, South-western Nigeria, from November 2018 to November 2021. This implies that data was sampled from for a period of 36 months. Data were extracted from the operation register and patients' case folders on bio-data, diagnosis, type of surgical procedure, site of surgery, dates of surgery and removal of implant, indication for removal. Only files of patients

with complete medical records were included in this study. All information obtained was treated with strict confidentiality.

3. STATISTICAL ANALYSIS

Data collected were analyzed using the Statistical Package for the Social Sciences for Windows version 26 (SPSS Inc., Chicago, IL, USA). Results were presented with descriptive statistics of frequency, means and standard deviations.

4. RESULTS

A total of 12 patients had implants removed. Among the patients were 10 females (83.3%) and 2 males (16.7%). About 41.7% were less than 25 years of age, 33.3% were between the ages of 25-50 while 25% were 50 years and above (Table 1). We also recoded 3 pediatric cases (7, 10 years of age and an 18 months patient). Table 2 shows that K-wire (41.7%) was the most common implants removed in this study. The most common bone involved was the femur 4 (33.3%), followed by the humerus 3 (25.0%) and knee 2 (16.7%). Completion of duration of therapy (25%) and peri-implant infection (25%) were the most common indications for removal of implants at this setting. All the implants were removed completely and average time for removal ranged from 30 mins to 2 hours. The patients were all shown their implants after removal and only 3 of them requested to take them home, others asked that it should be disposed.

Figure 1: Distribution of implants

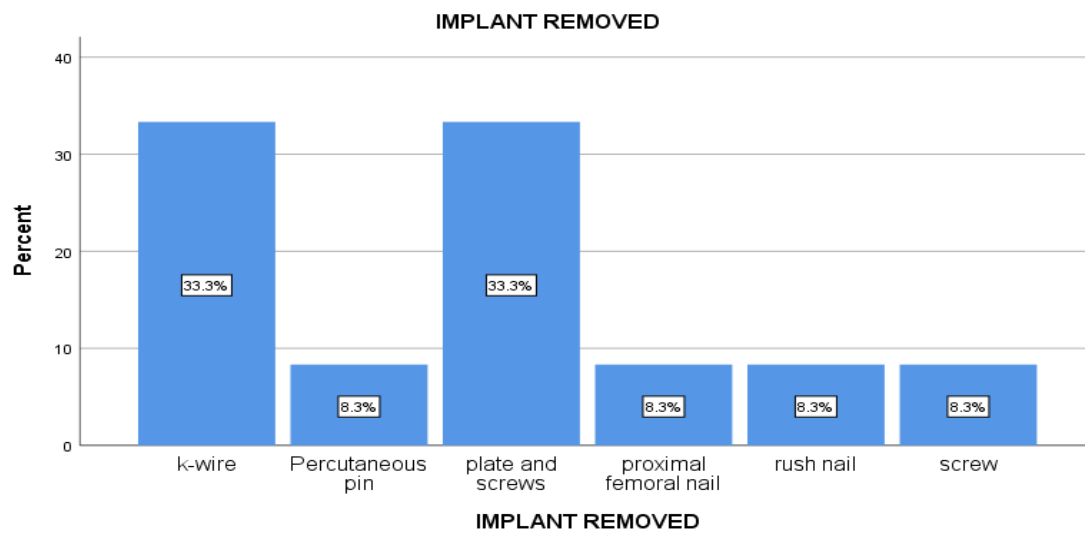


Figure 2: Distribution of implant site

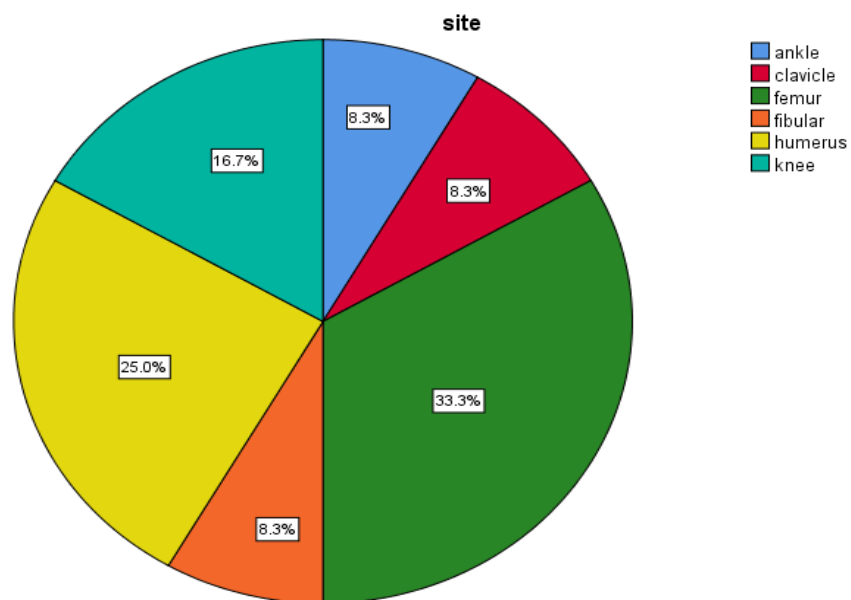


Figure 3: Distribution of indications for removal

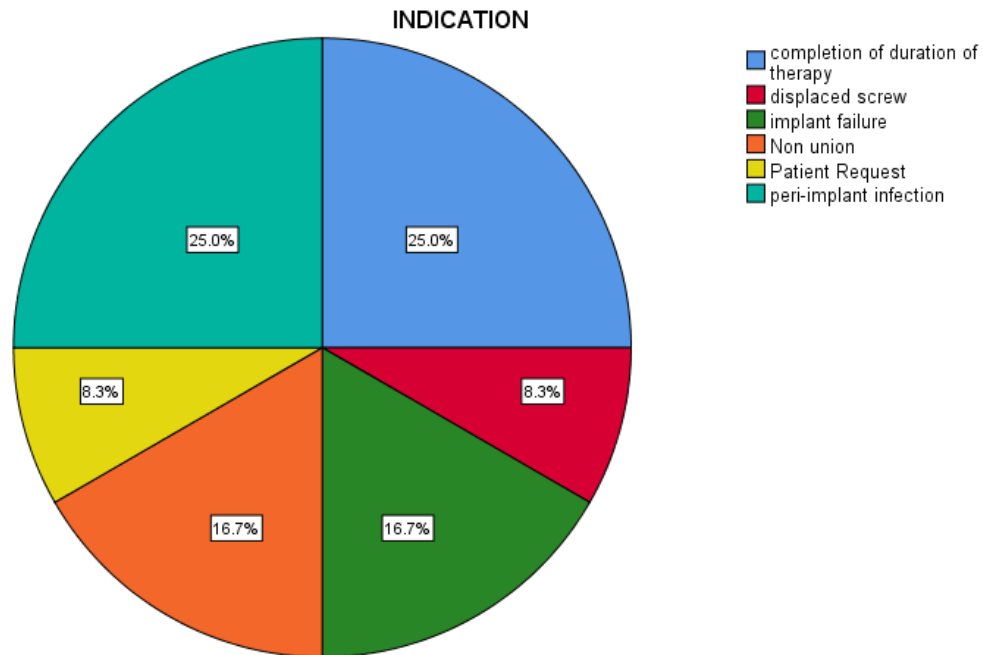


Table1: Socio-demographic characteristics

Characteristics		N (%)
Age (Years)	<25	5(41.7)
	25-50	4(33.3)
	>50	3(25.0)
Gender	Female	10(83.3)
	Male	2(16.7)

Table2: Implant characteristics

Characteristics		N (%)
Implant removed	K-wire	5(41.7)
	Plates and screws	4(33.3)
	Proximal femoral nail	1(8.3)
	Rush nail	1(8.3)
	Screw	1(8.3)
Site of implant	Ankle	1(8.3)
	Clavicle	1(8.3)
	Femur	4(33.3)
	Fibular	1(8.3)
	Humerus	3(25.0)
	Knee	2(16.7)
Indication	Completion of duration of therapy	3(25)
	Displaced screw	1(8.3)
	Implant failure	2(16.7)
	Non union	2(16.7)
	Patient request	1(8.3)
	Peri-implant infection	3(25)

5. DISCUSSION

Orthopedic hardware implant removal is a multifaceted topic with complex legal, ethical, and scientific aspects that require thorough exploration [17]. Orthopedic implants inserted for fracture management may at some time or the other be removed for some reasons. There are still some controversies on if implants be removed routinely in the setting of a healed fracture [18]. The purpose of this study was to determine the considerations and indications for implants removal in a Nigerian Teaching Hospital setting.

This study reveals that most implants removal were done on the females (83.3%). Onche et al [19] reported similar findings of female preponderance over males. However, some studies reported male preponderance over females [20, 21, 22]. Majority of the patients were below 25 years of age and between 25-50 years. 3 pediatric case (23.07%) files were retrieved. Jani et al 2019 in their prospective study also reported 25% that had implant removal were children. This implies that a higher percentage are in their productive age. Nwosu et al [24] reported similar finding.

This study had femur as the most common site of implant (33.3%), followed by humerus (25%). This implies that femur was the commonest bone fractured. This is similar to the findings of Ogundele et al [25], Kadir et al [20] and Shrestha et al [21]. In congruent to this, Reith et al [26] reported tibia and ankle to be the most common explanted bone.

The most common implant removed was K-wire (41.7%). This may be as k wires are typically used as temporary fixation especially in pediatric patients while plates and screws may fail in the long run especially for lower limb fixation. Onche et al [18] and Haseeb et al [27] reported plate and screws to be the most common implant removed in their studies. Shrestha et al [21] reported intramedullary nail as the most common implant removed. Studies revealed that

patient's request was the most common indication for removal of implants [18, 19]. This was however not same with our finding, we found out that peri-implant infection and completion of therapy/fracture union (25%) were the most common considerations for implant removal, in such cases the patient requested removal. The completion of therapy was however limited for pediatric cases. Some studies also reported pain, implant failure to be the most common indication for removal [25, 2]. In our study, we showed the patients their implants for medico-legal reasons and check x-rays were done to confirm these. Also most patients do not need the removed implants as was the case in our study. There were no complications reported after surgeries and patients' operations were successful.

6. CONCLUSION

Implant removal may be overlooked as a simple procedure however there exists much more than we imagine. The nature of the implant, legal and social aspects are very important. Patients must be adequately counselled on these factors before setting out on the journey. Possible complications should also be communicated to the patient.

ETHICAL APPROVAL

Study was approved by the institutional ethics committee (Babcock University Research Committee).

COMPETING INTERESTS DISCLAIMER:

Authors have declared that no competing interests exist. The products used for this research are commonly and predominantly use products in our area of research and country. There is absolutely no conflict of interest between the authors and producers of the products because we do not intend to use these products as an avenue for any litigation but for the advancement of knowledge. Also, the research was not funded by the producing company rather it was funded by personal efforts of the authors.

REFERENCES

1. Wiesel, S, Delahay, J. Essentials of Orthopedic Surgery. (2007).
2. Shrivats AR, Alvarez P, Schutte L, Hollinger JO. (Fourth Ed.), Academic Press, Boston. 2014;pp. 1201–1221.
3. Rouhi1 G, Amani M.A Brief introduction into orthopedic implants: screws, plates, and nails. https://www.researchgate.net/publication/309923041_a_brief_introduction_into_orthopaedic_implants_screws_plates_and_nails
4. Ermanno B. Basic Composition and Structure of Bone, in Mechanical Testing of Bone and the Bone-Implant Interface.1999;CRC Press. p. 3-21.
5. Melton LJ, Achenbach SJ, Atkinson EJ, Therneau TM, Amin S. Long-term mortality following fractures at different skeletal sites: a population-based cohort study, Osteoporos. Int.. 2013;24:1689–1696.
6. Somersalo A et al. Increased mortality after lower extremity fractures in patients < 65 years of age, Acta Orthop. 2016;87:622–625.

7. Turnbull G et al. 3D bioactive composite scaffolds for bone tissue engineering, *Bioact. Mater.* 2018 (3);278–314.
8. Faour O, Dimitriou R, Cousins CA, Giannoudis PV. The use of bone graft substitutes in large cancellous voids: any specific needs, *Injury*. 2011; 42 (Suppl 2)S87–S90 .
9. Al-Rashid M, Khan W, Vemulapalli K. Principles of fracture fixation in or- thopaedic trauma surgery, *J. Perioper. Pract.* 2010;20.113–117.
10. Golbakhsh M, Sadaat M, Noughani F, Mirbolook A, Gholizadeh A, Abedi S. The Impact of Psychological Factors on Device Removal Surgery. *Trauma Mon.* 2016;21(2):e25871.
11. Lill H, Hepp P, Korner J, Kassi JP, Verheyden AP, Josten C, Duda GN. Proximal humeral fractures: how stiff should an implant be? A comparative mechanical study with new implants in human specimens. *Arch Orthop Trauma Surg.*; 2003. 123(2-3):74-81.
12. Einhorn T.A, Gerstenfeld L.C. Fracture healing: mechanisms and interventions, *Nat. Rev. Rheumatol.* 2015;11. 45–54.
13. Giannoudis P.V, Einhorn T.A, Marsh D. Fracture healing: the diamond concept, *Injury* 38 (Suppl 4). 2007;S3–S6.
14. Andrzejowski P, Giannoudis P.V. The 'diamond concept' for long bone non-union management, *J. Orthop. Traumatol.* 2019;20. 21.
15. Clark D, Nakamura M, Miclau T, Marcucio R. Effects of aging on fracture healing, *Curr. Osteoporos. Rep.* 2017;15. 601–608.
16. Hasan A, et al. Advances in osteobiologic materials for bone substitutes, *J. Tissue Eng. Regener. Med.* 2018;12. 1448–1468

17. Black NR, William J, Winslade JD, Ronald W, Lindsey MD, Gugala Z. The Legal, Ethical, and Scientific Considerations for Returning Explanted Orthopaedic Hardware to the Patient. *J Bone Joint Surg Am.* 2021; 00:e1 (1-5)
18. Matthew LB, Robert JE, William TO. Hardware Removal: Indications and Expectations. *J Am Acad Orthop Surg.* 2006;14(2):113-20.
19. Onche II, Osagie OE, INuhu S. Removal of orthopaedic implants: Indications, outcome and economic implications. *J West Afr Coll Surg;* 2011;1:101-12
20. Kuubiere CB, Mogre V, Alhassan A. Incidence and indications for orthopedic implant removal: A retrospective analysis. *J Life Sci Res.* 2015;2:76-86.
21. Kadir BM, Ibraheem GH, Yakub S, Onuchukwu NS, Olawepo K, Babalola OM. Removal of orthopedic hardware: A five year review. *Niger J Orthop Trauma.* 2013; 12:113-8.
22. Shrestha R, Shrestha D, Dhoju D, Parajuli N, Bhandari B, Kayastha SR. Epidemiological and outcome analysis of orthopedic implants removal in Kathmandu university hospital. 2013;12:113-8.
23. Jain RK, Patel Y, Jayaswal A, Verma A. Indications for implant removal: a prospective study. *Int J Res Orthop.* 2019; 5
24. Nwosu C, Adeyemi TO, Salawu ON, Mejabi JO, Fadimu AA. Orthopaedic implant removal: Epidemiology and outcome analysis. *Niger J Orthop Trauma;* 2018:17:12-6.
25. Ogundele OJ, Ifesanya AO, Adesanya AA, Alonge TO. Removal of orthopaedic implants from patients at the university college hospital, Ibadan. *Afr J Med Med Sci;* 2013:42:151-5.
26. Reith G, Schmitz-Greven V, Hensel KO, Schneider MM, Tinschmann T, Bouillon B. Metal implant removal: Benefits and drawbacks – A patient survey. *BMC Surg.* 2015;. 15:96

27. Haseeb M, Butt MF, Altaf T, Muzaffar K, Gupta A, Jallu A. Indications of implant removal:
A study of 83 cases. Int J Health Sci. 2017;(Qassim);11:1-7.

UNDER PEER REVIEW