

# The coverage of large skin tissue losses of the hand by the Mc Gregor flap

## Abstract

### Introduction

Large defects of the hand pose a coverage problem. Several procedures are available, the flap of Mc Gregor or groin flap still retains an important place in the management of these skin defects.

### Materials and methods

It is a retrospective study of 50 patients presenting a skin defect of the hand needing a flap coverage by a pedicled Mc Gregor flap collected at the plastic and burns surgery department, of the University hospital of Nabeul, Tunisia.

### Results

Our study is made of 50 patients with a male predominance (sex ratio = 1.5); and an average age of 40 years. The substance loss was post traumatic in 22 cases and post infectious in 28 cases. The location was mainly the dorsal side of the hand (30 cases), with an average surface area of 50 cm<sup>2</sup>. The average coverage delay was 5 days with nursing period of 21 days. We made 47 fascio-cutaneous flaps and 3 composite ones.

In the short term, we noted a distal necrosis of the flap in 3 cases, a breakdown of sutures in 5 cases. In the long term, an overall satisfactory result was found in 90% of cases.

### Conclusion

Due to its reliability and technical simplicity, the flap of Mc Gregor is still relevant today.

**Keywords :** Mc Gregor flap, skin tissue loss, coverage, hand.

## Introduction

Complex injuries of the hand and large losses of skin pose a problem of coverage despite the development of microsurgery and the advent of new flaps especially microsurgical ones. Despite its old description, the Mc Gregor flap remains a star flap in the management of these defects.

We present a serie of 50 patients who had complex losses of substances after management of infections or traumas of the hand and requiring a coverage by a Mc Gregor flap.

The aim of our work is to recall the advantages and disadvantages of this flap in the management of these skin defects and to emphasize the fact that it remains relevant despite its old description.

## Materials and methods

This is a retrospective study of 50 patients with a large loss of tissue of the hand requiring a coverage by a Mc Gregor flap, collected in the plastic surgery and burns department of the University hospital of Nabeul from 2003 to 2020.

## Results

Our population is made of young adults (average age 40 with extremes of 12 to 70 years), the majority were male (30 men and 20 women). They were manual workers in 80% of cases. The dominant side is affected in 60% of cases. Eight patients were diabetic. The defect was post traumatic in 22 cases (following a work accident by crushing mechanism in 17 cases) and post infectious in 28 cases. It was located at the back of the hand in 30 cases, the first web in 6 patients, the inner border of the hand in 4 patients and the volar side in 10 patients. The average size of the skin defect was 50 cm<sup>2</sup>.

We noted associated lesions in 18 cases:

- **Bone damage:** 10 cases of metacarpal fractures including 3 cases of bone loss requiring bone reconstruction by composite Mc Gregor flap pedicled on the deep circumflex iliac artery which is composed of a corticospongy segment of the iliac crest as well as fascio-cutaneous component.
- **Tendon lesions** in 8 cases involving extensors in 5 cases and flexors in 3 cases.
- **Nerve damage** was observed in 5 patients.

The coverage delay was 5 days with extremes of 1 to 15 days. We performed stabilization by external fixator in 10 patients. The nursing period of the flap lasted an average of 21 days with extremes up to 30 days. A reapplication of the flap was performed in 35 cases. Thirty-five of our patients required further surgeries for debulking the flap.

The Mc Gregor flap allowed us to make secondary reconstructions :

- Two nerve grafts for interdigital nerves
- a tendon graft of flexor tendons in 3 patients
- an extensor graft in one patient.

The evolution is summarized as follows :

- Early outcome:

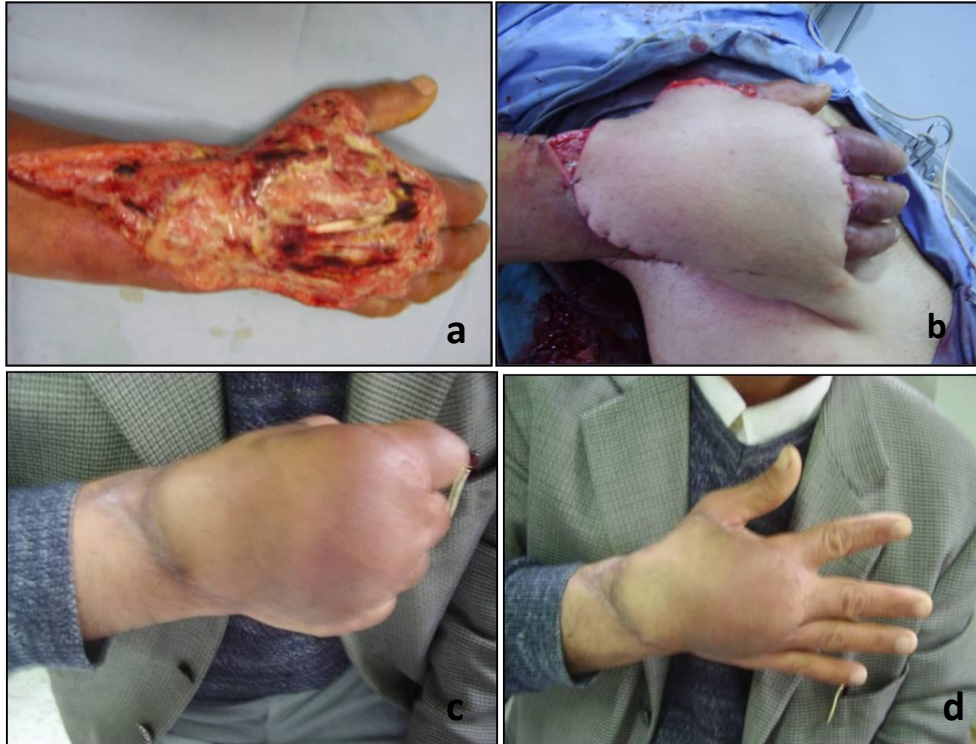Distal flap necrosis was observed in 3 cases. A septic disunion of the flap in 5 cases having evolved favorably after local wound care and antibiotic therapy.

- Long-term outcome:

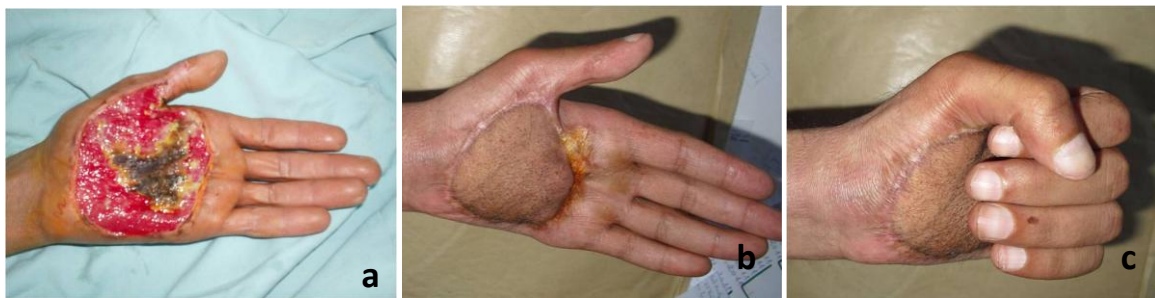Taking into account the aesthetic appearance (pigmentation, bulkiness) of the coverage and the function of the hand, the results were good in 90% of cases (based on patient appreciation).

We noted a dyschromic appearance of the flap in 3 patients.

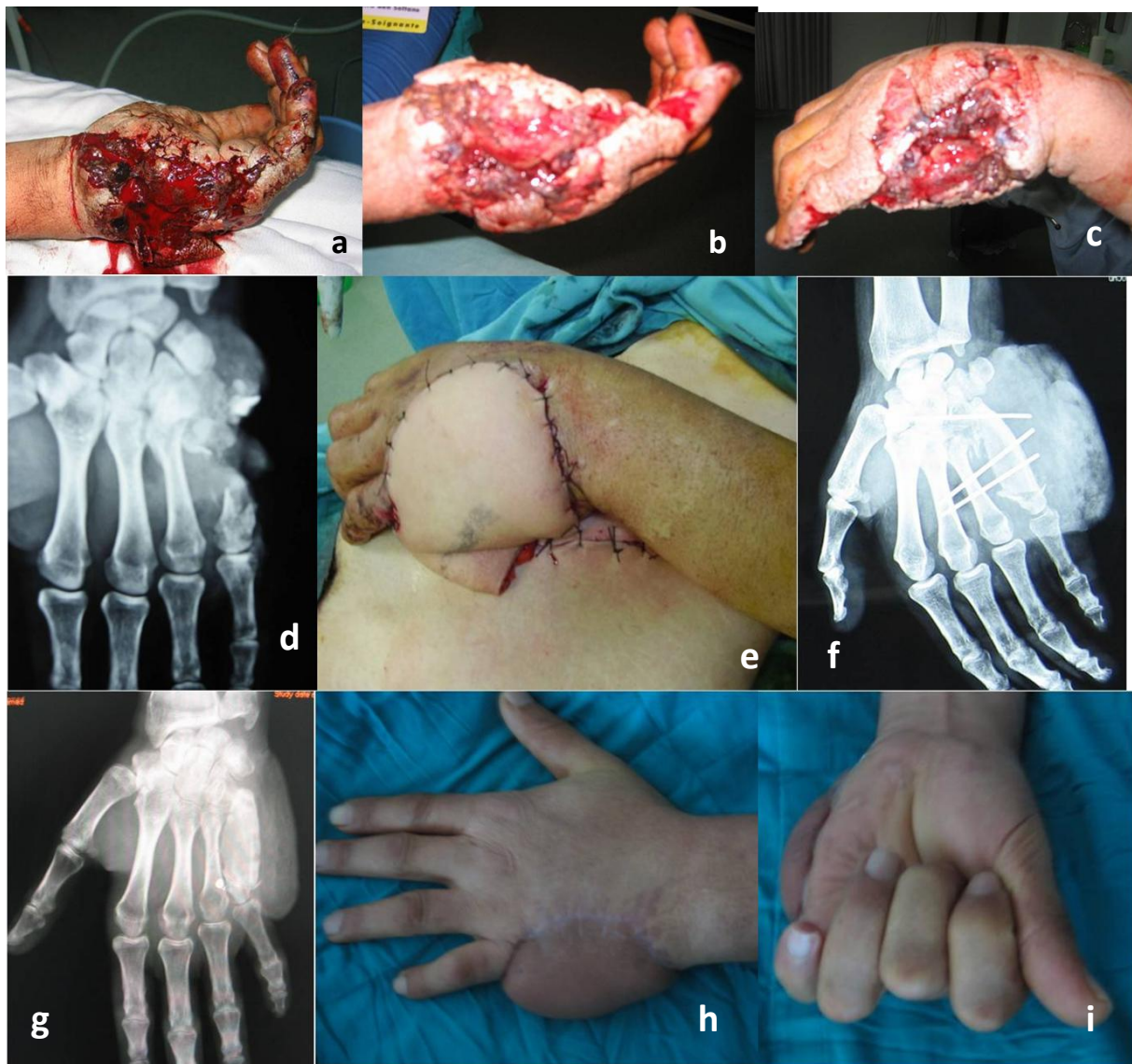
A soaping effect of the flap in 3 cases of volar loss of substance of the hand.



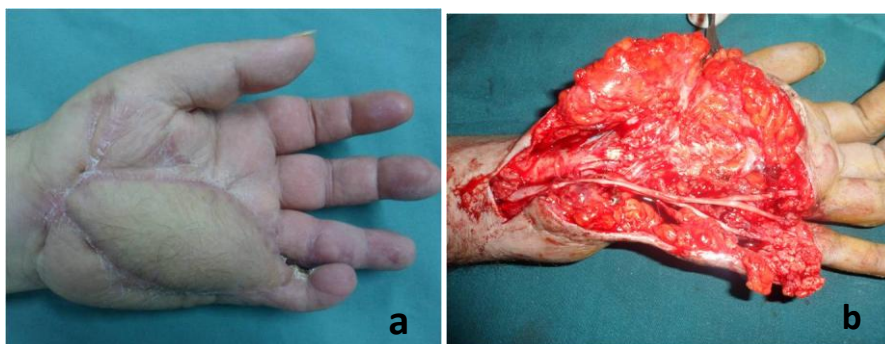
**Figure 1** : dorsal defect of the right hand and wrist after excision of necrotizing fascitis in a diabetic patient, covered by a Mc Gregor flap with an excellent functional outcome.



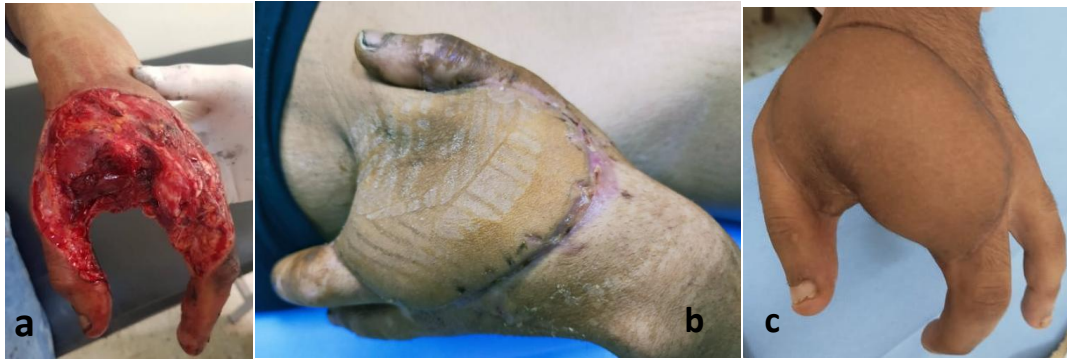**Figure 2** : coverage of a volar skin defect of the hand. Inesthetic and dyschromic aspect of the flap despite a good functional result.



**Figure 3 :** reconstruction by a composite Mc Gregor flap after a gun shot wound of the hand causing a defect of the cubital border of the and as well as a defect of the fifth metacarpal bone.



**Figure 4 :** the Mc Gregor flap allows in this case a secondary graft of the ulnar nerve and is terminal branches.



**Figure 5 :** reconstruction of first web space of left hand after a traumatic amputation of index and middle finger. Good aesthetic result.

## Discussion

The Mc Gregor flap is a fascio-cutaneous flap pedicled on the superficial iliac circumflex artery, described since 1972 [1]. Despite its old description it still retains a place in the coverage of defects of the hand.

Several procedures of covering these skin defects were described : island flaps of the forearm which sacrifice main arterial axes of the hand such as radial forearm flap or Becker's flap and the posterior and anterior interosseous flaps [4] which are less reliable than the Mc Gregor flap. Free flaps require an adequate technical board and are occasionally used at hand level [5,9,10].

For post-infectious defects, we always recommend a second operative time for coverage after controlling the infection. For post traumatic defects exposing noble elements or associated with tendinous, nerve or bone lesions, coverage must be made as soon as possible.

We do not approve the principle of rebuilding everything in a single time, there is no point in running to rebuild it properly.

In regards to the site of the tissue defect, coverage of dorsal skin loss gives better results in terms of quality and appearance of the dorsal skin of the hand which simulates the inguinal region [8]. On the other hand, for volar defects, coverage by a Mc Gregor flap poses an aesthetic (hyperchromic aspect) and functional problem (soaping of flap) that hinders the palmo-digital grasp.

The Mc Gregor flap is a star flap in the coverage of large tissue defects of the hand, given its reliability, simplicity, possibility of collecting large flaps and harvesting of composite flaps allowing to collect bone to reconstruct associated bone defects [3,6].

Some disadvantages that keep certain surgeons from harvesting this flap: several operating times, necessity of a nursing period preventing the use of the hand before the detachment of pedicle (21 days minimum) and dyschromic appearance. Some of which can be improved by better collaboration and proper management of the patient.

## Conclusion

The Mc Gregor flap remains always relevant in the coverage of large tissue defects of the hand because of its reliability and its simplicity. Composite variant offers us the advantage of bone

reconstruction in complex traumas of the hand [7]. The importance of its vascular axis offers the possibility of using it as a free flap.

## CONSENT

As per international standard or university standard, patients' written consent has been collected and preserved by the author(s).

## ETHICAL APPROVAL

As per international standard or university standard written ethical approval has been collected and preserved by the author(s).

## References

1. McGregor IA, Jackson IT. The groin flap. Br J Plast Surg. 1972 Jan;25(1):3-16.
2. El Hacen MM, Limam S, Aw A, Ahmed K, Biha N, Ne C. McGregor's flap: a salvage technique: about a case, clinical features and outcome. Pan Afr Med J. 2019 Jul 19;33:235.
3. Goertz O, Kapalschinski N, Daigeler A, Hirsch T, Homann HH, Steinstraesser L, Lehnhardt M, Steinau HU. The effectiveness of pedicled groin flaps in the treatment of hand defects: results of 49 patients. J Hand Surg Am. 2012 Oct;37(10):2088-94.
4. Tan RES, Lahiri A..Vascular Anatomy of the Hand in Relation to Flaps. Hand Clin. 2020 Feb;36(1):1-8.
5. Witt M, Altintas MA. Reconstruction of defects on the hand . Unfallchirurg. 2021 Oct;124(10):789-796. 5.
6. Biswas D, Wysocki RW, Fernandez JJ, Cohen MS. Local and regional flaps for hand coverage. J Hand Surg Am. 2014 May;39(5):992-1004.
7. H Gisquet<sup>1</sup>, S Barbary, J Vialanex, F Dap, G Dautel. The free groin flap utility. About 19 cases. Ann Chir Plast Esthet. 2011 Apr;56(2):99-106.
8. Al-Qattan, Mohammad M., and Ahmed M. Al-Qattan. "Defining the indications of pedicled groin and abdominal flaps in hand reconstruction in the current microsurgery era." *The Journal of hand surgery* 41.9 (2016): 917-927.
9. SIDHOUM, Nassim, DAST, S., PEREZ, S., et al. Lambeau de SCIP: renouveau du site donneur inguinal. In : *Annales de Chirurgie Plastique Esthétique*. Elsevier Masson, 2017. p. 646-651.
10. GISQUET, H., BARBARY, S., VIALANEX, J., et al. Intérêt du lambeau inguinal libre. À propos de 19 cas. In : *Annales de chirurgie plastique esthétique*. Elsevier Masson, 2011. p. 99-106.