

Cerebral venous sinus thrombosis (CVST) in adults- a case series of (5) five patients from Bisha Saudi Arabia.

Names and affiliations of authors.

Adekunle F Mustapha^a (**corresponding author**)

Lukman Femi Owolabi^b

Ahmed Raafat^a

Aomar G.Belkacem^a

Oluranti Akinyemi^a

Mushabab Alghamdi^c

Hamzah M.Ahmed^c

Francis Ikechukwu Okwuegbuna^c

a- Department of Medicine King Abdullah Hospital Bisha Saudi Arabia

b- Department of Medicine, College of Medicine University of Bisha Saudi Arabia

C-Department of radiology King Abdullah hospital Bisha Saudi Arabia

Abstract

Cerebral venous sinus thrombosis is rare cause of stroke particularly prevalent among young adults. CVST is a potentially life threatening condition if not recognised early, but unlike arterial stroke, it has a good prognosis if appropriate treatment is instituted early. We present five cases of cerebral sinus venous thrombosis managed in our hospital with four of the affected patients being young females signifying a female predilection. The risk factors were varied and included hypothyroidism, post-traumatic epilepsy with subdural haematoma, puerperium and Covid-19 vaccination. The causes of CVST are protean and its symptomatology is diverse. A high index of clinical suspicion and Magnetic Resonance Venogram (MRV) of the brain facilitated early and prompt diagnosis .In our case series, three out five patients had left transverse sinus thrombosis on MRV brain and one patient had a superior sagittal sinus and right transverse sinus thrombosis. The patients had anticoagulation with heparin which is the mainstay of treatment for CVST. Four patients improved and were discharged or referred and one died. Prognosis depends on the predisposing factors. Prognosis is usually good with up to 80% of patients making a complete recovery.

Keywords: cerebral, venous thrombosis, aetiology and treatment

Introduction

Cerebral venous sinus thrombosis (CVST) is a rare type of cerebrovascular disorder affecting 3-4 persons/million/year with a female predisposition particularly affecting those in the age groups of 20-35 years(1). CVST accounts for 0.5% of all strokes (2). Two previous hospital-based retrospective studies in 3 different cities of Saudi Arabia documented several cases of cerebral venous sinus studies in the past few years. Behcet disease was the commonest risk factor in the first study while in the other study, pregnancy /pueperium was the most common risk factor (3, 4). The disease is characterized by clotting of blood in cerebral venous or dural sinuses and in rare cases, cortical veins.

The clinical presentation of CVST varies and can include headache, vomiting, paresis, and seizures (5, 6). This variation often constitutes a diagnostic challenge for the clinicians (5, 6). Documented causes of CVST are hypercoagulable states, dehydration, adjacent central nervous system infectious processes, hormone replacement therapy, pregnancy and puerperium (5,6).

In comparison with other causes of stroke, CVST has a high potential for recovery if adequate therapeutic measures are instituted early in the course of the disease. The prognosis of CVST has improved significantly in recent times due to increased awareness of the disease, availability of more sophisticated neuroimaging techniques and more effective treatments (7,8). Management of CVST is chiefly targeted at early identification and prevention of thrombus extension and complications.

Cases

Case 1:

The patient was a 41 year old Saudi female, a known case of hypothyroidism maintained on thyroxine supplements. She presented at the emergency department of our hospital on account of severe generalised headache of 3 days duration and 2 episodes of generalised seizures of few hours duration. There was associated neck pain but no fever, no limb weakness, no loss of consciousness, no visual difficulty and no vomiting. She was neither diabetic nor hypertensive patient. Her obstetrics and gynaecological history was significant for two miscarriages in the past.

On examination, she was an acutely ill-looking young lady, in painful distress, afebrile, anicteric and not pale. The neurological examination revealed a fully conscious patient who was alert and well-oriented. Her cognitive functions were well-preserved. There was no sign of meningeal irritation, no facioparesis and no pronator drift.

Cardiovascular examination revealed a pulse rate of 96beats/min, regular and normal volume.

Blood pressure was 130/75 mmHG and heart sounds were normal first and second heart sounds only.

Examination of the chest and abdomen did not reveal any significant abnormality.

Plain MRI brain revealed a resolving haemorrhagic infarct in the left temporal area affecting both cortical and sub-cortical matters with surrounding oedema. However, MRV brain revealed absent normal flow signals in left transverse sinus, left sigmoid sinus and left jugular in keeping with cerebral venous sinus thrombosis with consequent left temporal lobe cerebral haemorrhage as shown in figure1 .Serial CBC, coagulation profile, renal function tests, thyroid function tests were within normal limits. HIV I& II, Hepatitis B& C serology were all negative. Patient was commenced on anticoagulation- Clexane 60 mg **bid**, warfarin 5mg **od**, IV dexamethasone 4mg **tid** as well as Levetiracetam 500mg **bid** .Patient improved remarkably and was discharged a few days after admission.

Case 2

The patient was a 24 year old Saudi female with no significant past medical history who had a normal childbirth a week earlier to presentation to our hospital. She presented at our facility with history of severe generalised headache, right sided body's weakness and aphasia all of 2 days duration. There was no associated painful neck stiffness. She did not have convulsion, loss of consciousness or vomiting.

On examination, she was drowsy but rousable. Her Glasgow Coma Scale (GCS) Score was 13/15. She had expressive aphasia, right facioparesis and right hemiparesis. Her vital signs were stable. There was no sign of deep vein thrombosis in both lower limbs. All routine biochemical and haematological investigations were within normal limits. MRI and MRV Brain could not be done because patient had a fixed metallic denture. CT of the brain revealed a well-defined area of left temporo-parietal hyperdensity with perilesional oedema and small dots of left temporal and occipital haemorrhage and slight features suggestive of cerebral venous sinus thrombosis as shown in figure 2.

She received anticoagulation, clexane 60 mg bid and then warfarin 3 mg od, IV dexamethasone 4mg tid and had physiotherapy. Her headache subsided drastically and she improved remarkably over a few days after admission. She was subsequently discharged on warfarin to be followed up in both the neurology and haematology clinics.

Case 3

Patient was a 57 year old Saudi male with history of post-traumatic epilepsy following road traffic injuries. He was maintained on Levetiracetam and some antipsychotic medications for his psychotic symptoms according to the relatives which could not be ascertained. He was brought to the emergency department of our facility on account of repeated episodes of generalised convulsions without recovery of consciousness.

He had several attacks before presentation and he was said to have hit his head against the ground when he fell down during one of the episodes. There was no fever, no painful neck stiffness but he had right side body weakness. There were no symptoms to suggest raised intracranial pressure.

On examination, he was unconscious, afebrile. Main findings were in the neurological examination, he was unconscious with GCS score of 6-7/15, had spastic quadriplegia, right sided facioparesis and anisocoria with left pupil measuring 0.3 cm with no light reaction and the right pupil measuring 0.2 cm with good light reaction.

The cardiovascular examination revealed a pulse rate of 102/min, BP- 146/70 mmHG and normal first and second heart sounds. Chest examination was essentially normal with a SPO2 of 94%

Random blood sugar was 96 mg/dl. CT brain done at presentation revealed a left temporo-parietal linear fracture of the skull, left temporo-parietal acute subdural haematoma, left hemispheric cerebral infarction and subarachnoid haemorrhage with a midline shift greater than 5mm. Patient was subsequently wheeled to the operating room by the neurosurgical team where he had a decompressive craniotomy and was shifted to the ICU after the neurosurgical procedure where he was intubated and placed on mechanical ventilation.

Four days after the surgery, patient had a MRI brain and MRV brain which revealed a left sinus thrombosis as illustrated in figure3. Patient received IV 20% mannitol 200mls od, Levetiracetam 500mg bid, frusemide 20mg od via NG Tube, IV Ceftriaxone 1g bid and Omeprazole 40 mg od and

NG tube for feeding and administration of oral medications. Patient did not recover from coma and subsequently died 4 days after admission.

Case 4

The patient was a 29 year old Indian female who presented to our facility with 3-day history of severe generalised throbbing headache which occasionally was unilateral affecting the left side. There was associated recurrent vomiting that started at the onset of the illness. The vomiting was non-projectile and the vomitus consisted of recently ingested food. There was no associated haematemesis. There was no fever or painful neck stiffness. There was no limb weakness, no speech abnormality and no visual loss.

The patient had no history of chronic illness such as diabetes mellitus, hypertension, Hemoglobinopathies. On examination, she was acutely ill-looking and anxious but not in any obvious distress. She was afebrile (temperature =36.5C) anicteric, acyanosed and not pale.

CNS: patient was fully conscious, alert and well-oriented. There were no signs of meningeal irritation, no obvious cranial nerve deficits and no pronator drift. She had bilateral papilloedema on fundoscopy.

Motor and sensory functions of the limbs were normal .Vital signs were normal. Pulse rate was 75/min, regular and normal volume, blood pressure was 100/75mmHg and heart sounds were normal first and second heart sounds only. Other systems were within normal limits.

Results of blood investigations yielded the following results. WBC=8.21 x 10⁹/mm³, Haemoglobin concentration was 12.07 but there was thrombocytopenia with a platelet count of 36,000/mm³. Erythrocyte sedimentation rate was 15mm/Hr. Serum electrolytes. Na=134, K=3.78, Urea=3.70 creatinine =77 and Calcium =2.06. CT brain was unremarkable.

Patient developed generalised tonic-clonic convulsion during the course of admission and MRV brain revealed left transverse sinus, left sigmoid sinus and left jugular veins absent normal flow signals in keeping with cerebral venous sinus thrombosis as shown in figure 4. There was a dilemma on whether to start therapeutic dose of clexane in view of the presence of severe thrombocytopenia in this patient. A decision was reached among the managing team members to rather start patient on unfractionated heparin which could be controlled by an antidote if intracranial bleeding occurs. Patient was also commenced on tab Levetiracetam (Keppra) to control seizures.

Patient was subsequently referred to a higher centre where interventional procedure such as mechanical thrombectomy could be performed.

Case 5

Patient was a 22 year old Saudi female with no significant past medical history who was referred from a peripheral hospital to our facility on account of severe generalised headache, recurrent vomiting and left sided body weakness of one week duration as well as recurrent episodes of generalised tonic clonic seizures of one day duration. There was no associated fever, no painful neck stiffness and no antecedent history of trauma to the head or neck region. There was also no past medical history of epilepsy or any neurological illness.

Of significant note, patient had received the second dose of covid-19 vaccination (Pfizer vaccine) 3 days before the onset of symptoms..On examination, she was an acutely-ill looking anxious young woman in painful distress. She was fully conscious, afebrile (temperature was 37.1C),not pale, acyanosed and anicteric.

Neurological examination revealed a fully conscious young woman (GCS score was 15/15) with no signs of meningeal irritation or pupillary abnormalities or cranial nerve palsies but had a mild left hemiparesis. Vital signs were stable. Heart rate was 72 beats/min, BP was 110/61mmHG and SPO2

was 100% at room air. Venous blood gases were within normal limits. Complete Blood Count revealed a WBC count of $13,400/\text{mm}^3$, haemoglobin concentration of 10g/dl and a platelet count of $58,000/\text{mm}^3$ (thrombocytopenia). Coagulation profile was normal with an INR of 1.1. Thyroid functions tests were normal and hepatitis C and D serology were both negative.

An initial plain CT brain showed a resolving right hemorrhagic infarct. MRA of the brain showed normal flow pattern in both carotid arteries, vertebra-basilar systems and the circle of Willis. There was no evidence of aneurysms, arterial occlusions or AV-malformations.

However, a subsequent MRV of the brain revealed a subacute dural sinus thrombosis involving the superior sagittal sinus, right transverse sinus with early subacute right temporal lobe hemorrhagic venous infarction as shown in figure 5. A diagnosis of post covid-19 cerebral venous sinus thrombosis was subsequently made. Patient was commenced on intravenous fluids (normal saline), Apixaban 5mg bid because of the thrombocytopenia and levetiracetam 500mg bid.

She was also commenced on physiotherapy and patient's clinical condition improved drastically. The headache subsided remarkably, vomiting and seizures stopped.

Patient was subsequently discharged on oral warfarin 3mg od to be followed up in both the haematology and neurology clinics.

Patients' demographics and clinical characteristics are illustrated in table 1

DISCUSSION

Cerebral venous sinus thrombosis (CVST) as shown in this case series constitutes a serious neurological disorder which cuts across racial, gender and age divides and is potentially reversible

with prompt diagnosis and medical care (9). CVST commonly affects individuals below the age of 45 years but can affect any age group (10). Four of the affected patients in our case series of five were below the age of 45 years. There is a female predilection with women being affected three times more than men (11, 12). This was clearly evident in our study where four of the affected individuals were females.

Predisposing factors can be identified in about 80% of cases (13). There are numerous causes of CVST. These include infections such as meningitis which may be bacterial, viral, fungal or parasitic in origin, otitis media .Other causes include malignancies (meningioma, carcinoid, leukaemia, lymphoma),red cell and platelet disorders (polycythaemia, sickle cell disease and thrombocytaemia),inflammatory disorders eg Behcet disease and connective tissue disease such as systemic lupus erythromatosus, are the most frequent. Additional causes include pregnancy and **puerperium**, oral contraceptive pills, coagulopathies, head injury and severe dehydration (11, 14, 15, 16 ,17).

A risk factor or more could be found in patients with CVST (7). In our series of five patients, the first patient was a young woman with history of hypothyroidism, previous miscarriages in her obstetrics history, the second was in the **puerperium**, the third patient had history of post-traumatic epilepsy with recurrent seizure attacks who had sustained a fall and subsequently developed a subdural haematoma. The fourth patient had received covid-19 vaccination (Astra-Zeneca product) a few days before the onset of her symptoms and additionally had severe thrombocytopenia. The fifth patient also received covid-19 vaccination (the second dose of Pfizer vaccine) ten days before the onset of symptoms. **A new syndrome of vaccine-induced immune thrombotic thrombocytopenia (VITT) has emerged as a rare side-effect of vaccination against COVID-19(18).**

There have been several reports of progressive thrombosis particularly cerebral venous sinus thrombosis despite the presence of thrombocytopenia following Covid-19 vaccination. A specific

pattern of the coagulation screen reveals low fibrinogen and very raised D-Dimer levels above the level expected of VTE. Antibodies to platelet factor 4(PF4) have also been detected causing some similarities with heparin induced thrombocytopenia(HIT) but the absence of patients prior exposure to heparin appears to be a confounding factor(18,19).

The clinical presentation of CVST varies with the location and extent of sinuses involved. The diagnosis of this condition is often difficult and can lead to a delay in the treatment (10). In fact, the median delay from presentation to diagnosis is often 7 days (10), therefore the physician must have a high index of clinical suspicion when patients have any of the of the above risk factors and some non-specific neurological symptoms.

The most common signs of CVST are headache, papilloedema, focal motor or sensory deficits and seizures. Our first patient had headache, neck pain, generalised seizures. The second patient also had headache, aphasia, papilloedema and right hemiparesis, the third patient was brought in coma with spastic quadriplegia, anisocoria and status epilepticus, the fourth patient had severe headache, recurrent vomiting, and bilateral papilloedema and generalised convulsions while the last patient had headache, vomiting, blurring of vision, left-sided weakness and generalised seizures. The most common denominators among our patients' symptoms were headache, vomiting, blurring of vision and seizures

Venous drainage of the brain involves blood flow through the cerebral veins into the dural sinuses that then drain into the jugular veins .CVST occurs following the formation of a thrombus in the cerebral venous/dural system due to possibly an hypercoagulable state. The underlying mechanism of CVST involves two mechanisms (16). The first includes localised oedema and venous infarction due to cerebral vein occlusion. The second mechanism constitutes the development of raised intracranial pressure due to occlusion of one of the cerebral venous sinuses, since CSF absorbed by the arachnoid villa drains into the superior sagittal sinus (16).According to the International Study on

Cerebral vein and Dural sinus thrombosis, the most commonly affected sites are the transverse sinus followed by the superior sagittal sinus (20). Other less common sites are the cortical vein, jugular vein and internal cerebral vein. In most cases, thrombosis occurs in more than one sinus (20). This fact was clearly corroborated in our study where the transverse sinus was affected in four of the cases.

Management of CVST is focused on timely diagnosis and treatment. Treatment is predominantly anticoagulation to prevent propagation of the thrombus and reduce the likelihood of complications such as pulmonary embolus.

Poor prognostic factors include large parenchymal lesions, age greater than 37 years, Glasgow Coma Scale (GCS) less than 9/15, seizures, posterior fossa lesions, intracranial haemorrhages (21). All these criteria were evident in the only mortality recorded in our series. These patients are more likely to deteriorate and would need management in acute settings.

Both the American Heart Association and American Heart Association (AHA/ASA) and European Federation of Neurological Societies (EFNS) guidelines recommend that patient should be anticoagulated even in the presence of haemorrhage(22).

If anticoagulation is contra-indicated, or in cases of CVST not responding to anticoagulants, endovascular thrombolysis or mechanical thrombectomy might be an option (23). Although evidence to support this approach is currently not strong enough. Steroids are not recommended are linked to a poorer prognosis in CVST even in the presence of underlying parenchymal lesions, unless indicated by underlying conditions such as meningitis or malignancy(24).

Antiepileptic drugs must not be given routinely as prophylaxis but should be administered if seizure occurs (10). Three patients in our series had generalised seizures which were controlled with Intravenous Phenytoin and oral AEDs such as Depakine and Levatiracetam.

Following the immediate management of CVST, long-term vitamin K antagonists such as warfarin, with a target international normalised ratio (INR) of 2-3 should be used(10) .The duration of anticoagulation depends on the aetiology. The AHA/ASA guidelines recommend anticoagulation for 3-6 months in provoked CVST, 6-12 in unprovoked CVST and potentially life-long in recurrent CVST, VTE following CVST or CVST associated with severe thrombophilias (10).

Conclusions: CVST is a rare cause of stroke in young adults and should be considered in the differential diagnosis of recent of headache, papilloedema, focal neurologic deficits, and seizure as seen in this case series. The risk factors and clinical features are myriad and diverse, thus a high index of clinical suspicion is very imperative. Covid-19 vaccination appears to be a novel risk factor which needs further evaluation and study. Anticoagulation with heparin is the mainstay of treatment, and prognosis is generally good if detected early and appropriate treatment is instituted promptly.

Competing interests: Authors have declared that no competing interests exist. The products used for this research are commonly and predominantly use products in our area of research and country. There is absolutely no conflict of interest between the authors and producers of the products because we do not intend to use these products as an avenue for any litigation but for the advancement of knowledge. Also, the research was not funded by the producing company rather it was funded by personal efforts of the authors.

Ethical approval: This was obtained from the ethics and review committee of the University of Bisha, Saudi Arabia as part of a larger stroke study in Bisha Saudi Arabia

Consent Disclaimer:

As per international standard or university standard, patient's consent has been collected and preserved by the authors.

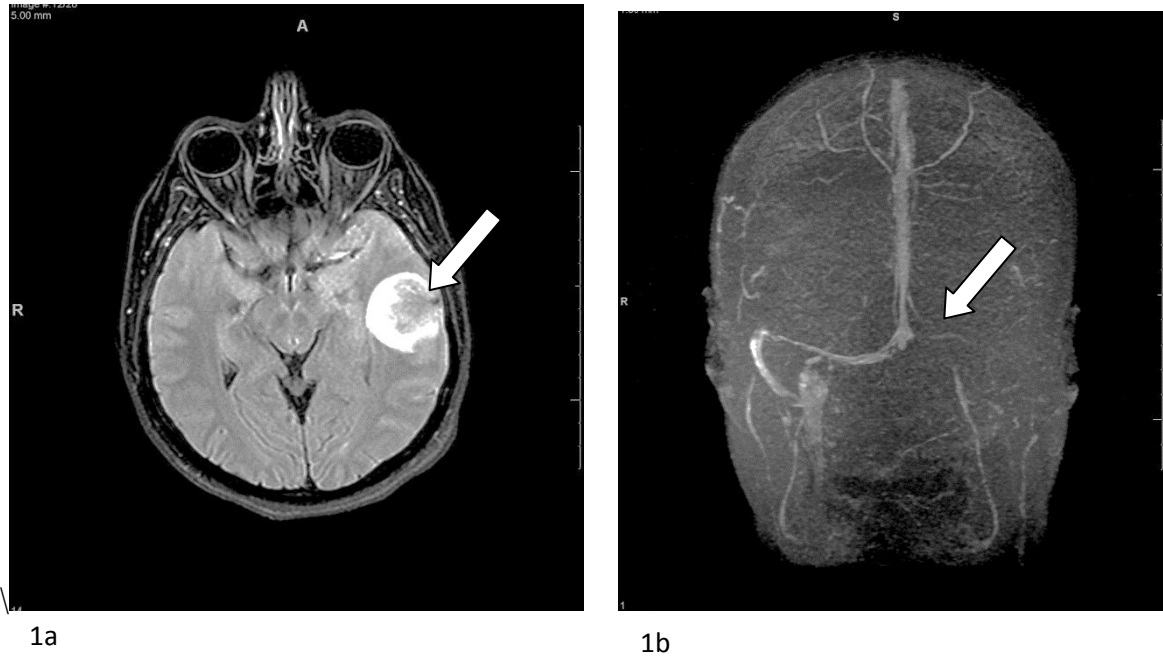
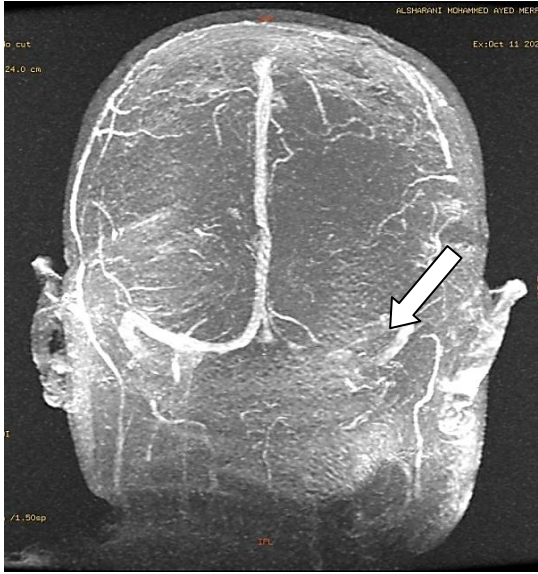


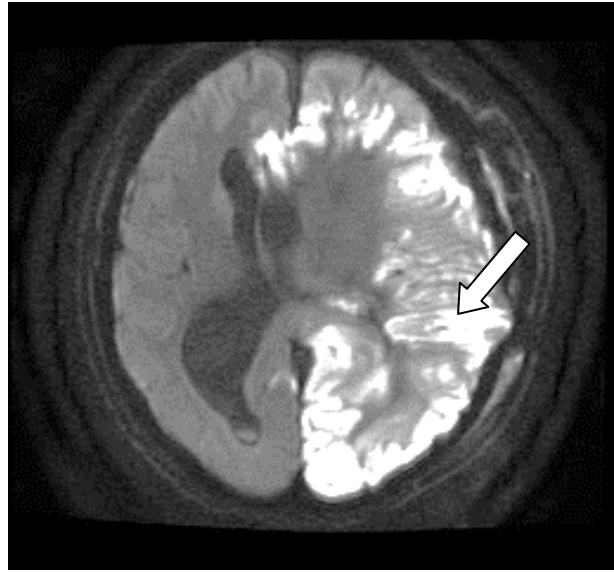
Figure 1.MRV Brain of the patient showing left temporal lobe cerebral haemorrhage (1a) and left transverse sinus, left sigmoid sinus and left jugular veins absent normal flow signals in keeping with cerebral venous sinus thrombosis (1b) .

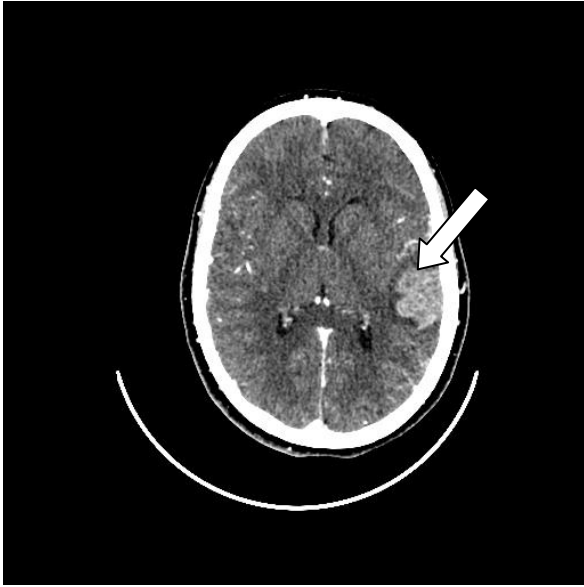

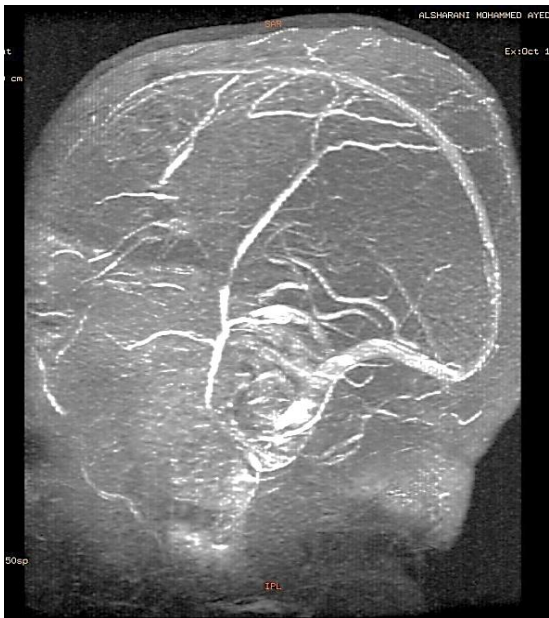Figure 2: CT Brain of patient 2 showing a well-defined area of left temporo-parietal hyperdensity with perilesional oedema with small dots of left temporal and occipital heamorrhage.



3a

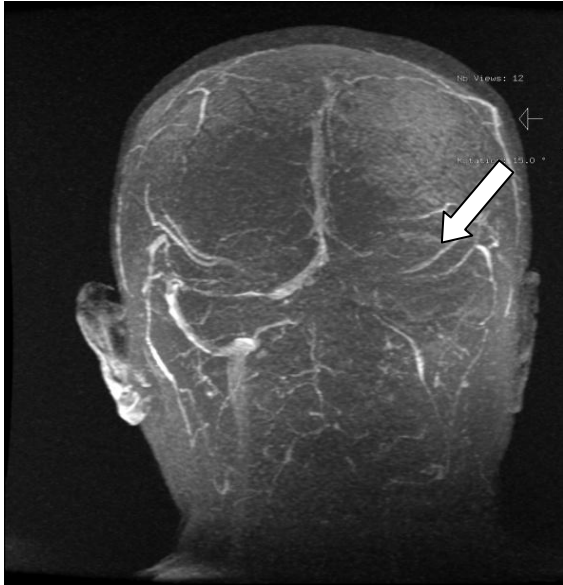


3b

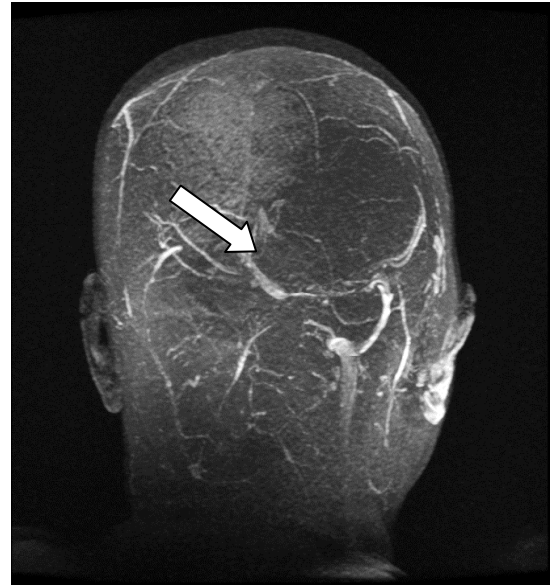


3c

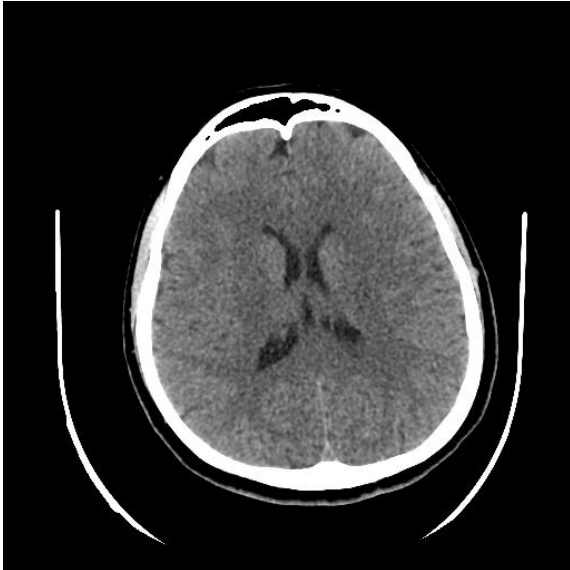Figure 3: Showing the MRV Brain of patient 3 showing a left cerebral sinus thrombosis (3a & 3c) and left temporo-parietal acute subdural haematoma (3b), left hemispheric cerebral infarction and subarachnoid haemorrhage with a midline shift greater than 5mm (3b).



4a

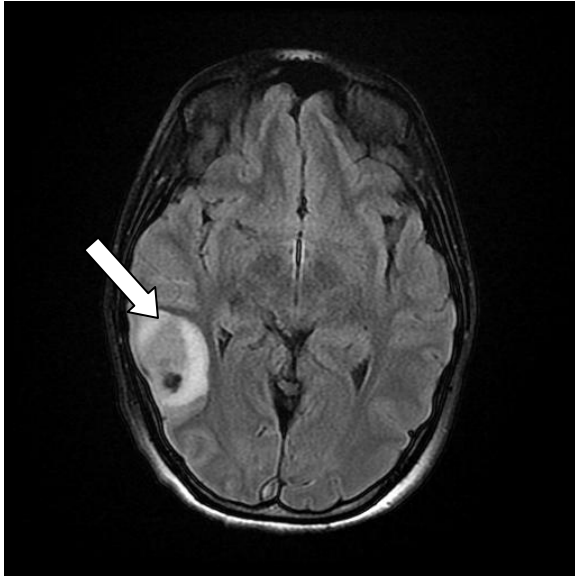


4b

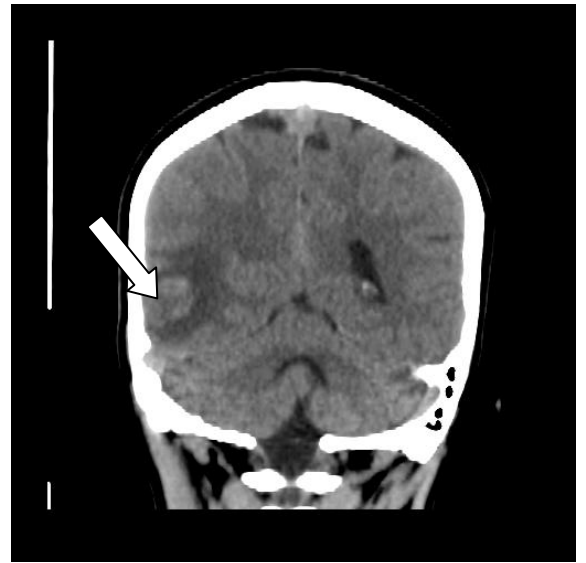

4c

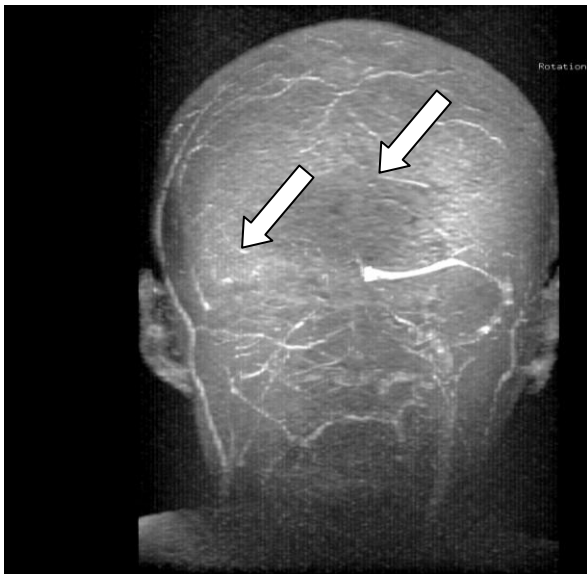
Figure 4: .MRV Brain of the patient showing left transverse sinus, left sigmoid sinus and left jugular veins absent normal flow signals in keeping with cerebral venous sinus thrombosis (4a & 4b)



5a



5b



5c

Figure 5: MRI Brain revealed an early subacute right temporal lobe hemorrhagic venous infarction (5a) while the MRV of the brain revealed a subacute dural sinus thrombosis involving the superior sagittal sinus, right transverse sinus (5b, 5c) with

Table 1: Patients demographics and characteristics and outcome

	Patient 1	Patient 2	Patient 3	Patient 4	Patient 5
Gender	Female	Female	Male	Female	Female
Age	41 years	24 years	57 years	29 years	22 years
Risk factors	Hypothyroidism, Fetal miscarriages	Puerperium	Post-traumatic epilepsy & Subdural haematoma	Post-19 Covid Vaccination(Astra-Zeneca) & thrombocytopenia	Post-Covid -19 vaccination and thrombocytopenia (Pfizer vaccine)
Clinical features	Headache, Neck pain and seizures	Headache, Right facioparesis, right hemiparesis, papilloedema and seizures	Status epilepticus, coma, anisocoria and right hemiparesis	Headache, recurrent vomiting, Papilloedema, Seizures	Headache, recurrent vomiting, Papilloedema, Seizures
Neuroimaging findings	absent normal flow signals in left transverse sinus, left sigmoid sinus and left jugular in	. CT brain - revealed a left temporo-parietal linear fracture of the skull, left temporo-parietal acute subdural haematoma , left	left temporo-parietal hyperdensity with perilesional oedema with small dots of left temporal	Left transverse sinus, left sigmoid sinus and left jugular veins absent normal flow signals in keeping with cerebral venous	MRA of the brain showed normal flow pattern in both carotid arteries, vertebral basilar systems and the circle of Willis. There was no evidence of aneurysms, arterial

	keeping with cerebral venous sinus thrombosis with consequent left temporal lobe cerebral haemorrhage as shown in figure	hemispheric cerebral infarction and subarachnoid haemorrhage with a midline shift greater than 5mm MRI brain and MRV which revealed a left sinus thrombosis	and occipital heamorrhage .	sinus thrombosis	occlusions or AV-malformations. However , a subsequent MRV of the brain revealed a subacute dural sinus thrombosis involving the superior sagittal sinus, right transverse sinus with early subacute right temporal lobe heamorrhagic venous infarction.
Managem ent	Clexane, warfarin phenytoin	Clexane, warfarin antiepileptic drugs	Intubation and mechanical ventilation with sedation, decompressive craniotomy, clexane, antibiotics , AEDS	Unfractionated heparin, antiepileptic drugs	Apixaban, levatiracetam
Outcome	Discharged	Discharged	Died	Referred	Discharged

References

1. Coutinho JM,Zuurbier SM,Aramideh M,Stam J.The incidence of cerebral venous thrombosis: a cross-sevntional study.Stroke 2012;43:3375-3377
2. Bousser M-G,Ferro JM.Cerebral venous thrombosis.An update.Lancet Neurol2007;6:1
3. Daif A, Awada A, Al-Rajeh S,Abduljabbar,AlTahan AR,Obeid T,Malibary T.Cerebral venous thrombosis in adults.A study cases from Saudi Arabia.Stroke 1995;26(7):1193-1195
4. Alghatani HA, Abdu AP, Shani AM,Hassan AE, Madkour M, Al-Ghamdi SM, Malhotra RM, Al-Khatani AM.Cerebral venous sinus thrombosis in Saudi Arabia.Neurosciences.2011.16(4)329-334.
5. Bousset MG, Barnett HJM. Cerebral venous thrombosis. In Barnett HJM, Mohr JP, Stein BM, Yatsu FM. Stroke Pathophysiology, Diagnosis and Management.2nd edition. New York, NY. Churchill Livingstone.1992
6. Bousser MG,Chiras J, Sauron B,Castaigne P.Cerebral venous thrombosis: A review of 38 cases.Stroke.1985;16:199-213.
7. Sebire G,Tabarki B,Saunders DE.Cerebral venous thrombosis in children: risk factors,presentation,diagnosis and outcome.Brain 2005;128:477-489.
8. Barnes C,Newall F,Furmedge J.Cerebral venous thrombosis in children. J . Peaditr.Child Health.2004;40:53-55.
9. Leach JL,Fortuna RB,Jones BV, *et al.* Imaging of cerebral venous thrombosis: current techniques, spectrum of findings and dianostic pitfalls.Radiographics2006;26 (suppl 1): S19-S41,Discussion S42-S43.
10. Saponisk G, Barinagarrementania F, Brown RD Jr, Bushnell CD, Cuchiarra B,et al. Diagnosis and management of cerebral venous thrombosis: a statement for health care

professionals from the American Heart Association/American Stroke Association. *Stroke* 2011;42:1158-1192.

11. Filippidis A, Kapsalaki E, Patramani G, Fountas KN. Cerebral venous sinus thrombosis. Review of the demographics, pathophysiology, current diagnosis, and treatment. *Neurosurg Focus* 2009;27:E3
12. Okunola P, Ofovwe GE, Abiodun MT, Azunna CP. Superior sagittal sinus thrombosis complicating typhoid fever in a teenager. *Case Rep. Paediatr.* 2012;20:1203
13. Bousser MG, Russell RR. *Cerebral venous thrombosis*. London. WB Saunders:1977
14. Bentley JN, Figueroa RE, & Vender JR. From presentation to follow up: Diagnosis and treatment of cerebral venous thrombosis. *Neurosurgical focus* 27:E4
15. Devasagayam S, Wyatt B, Leyden J, Kleining T. Cerebral venous thrombosis incidence is higher than previously thought: a retrospective population-based study. *Stroke* 2016;47:2180-2182.
16. Stam J. Thrombosis of the cerebral veins and sinuses. *New England Journal of Medicine*. 2005;352:1791-1798.
17. De Bruijn SF, Stam J, Koopman MM and others. Case-control study of cerebral venous thrombosis in oral contraceptive users and in carriers of hereditary prothrombotic conditions. The Cerebral Venous Sinus Thrombosis Study Group. *BMJ*. 1998;316:589-592.
18. Perry RJ, Tamborska A, Singh B, et al. Cerebral venous thrombosis after vaccination against COVID-19 in the UK: a multicentre cohort study. *Lancet*. 2021;398(10306):1147-1156.
19. See I, Su JR, Lale A. US case reports of cerebral venous sinus thrombosis with thrombocytopenia after Ad26.COV2.S vaccination, March 2 to April 21, 2021. *JAMA*. 2021;325:2448-2456.

20. Ferro JM, Canhao P, Stam J, Barinagarrementeria F, for the ISCVT investigators: Prognosis of cerebral vein and dural sinus thrombosis—results of International Study on Cerebral Vein and Dural Sinus Thrombosis (ISCVT). *Stroke* 2004;35:664-670.
21. Canhao P, Ferro JM, Lindgren AG *et al.* Causes and predictors of death in cerebral venous thrombosis. *Stroke* 2005;36:1720-1725.
22. Coutinho J, de Bruijn SF, Develer G, Stam J. Anticoagulation for cerebral venous sinus thrombosis. *Cochrane Database Syst. Rev.* 2011: CD002005.
23. Stam J, Majoie CBLM, van Delden OM, van Lienden KP, Reekers JP. Endovascular Thrombectomy & Thrombolysis for severe cerebral sinus thrombosis. *Stroke* 2008;39:1487-1490.
24. Canhao P, Corteseao A, Cabral M *et al.* Are steroids useful to treat cerebral venous thrombosis? *Stroke* 2008;39:105-110.