

Arrhythmogenic Right Ventricular Cardiomyopathy/ Dysplasia in Adults: A Case Report with Literature Review

Case Report

ABSTRACT

Arrhythmogenic right ventricular cardiomyopathy/ dysplasia (ARVC/D) is a cardiomyopathy of genetic origin, caused by abnormalities of desmosomes, characterized on the physiopathological level by a fibro-adipose infiltration replacing the myocardium of the right ventricle and the clinical level by an electrical instability leading to ventricular arrhythmias. ARVC/D peaks in frequency between the ages of 30 and 50. Diagnostic criteria have been established to retain the diagnosis of ARVC/D. Imaging, especially magnetic resonance imaging (MRI), plays a vital role in this diagnosis. We report the observation of a 48-year-old man, a former smoker, with a family history of the sudden death of a sister during a bicycle race and who has been complaining for several years of palpitations. Clinical presentation, electrical signs, cardiac ultrasound, and imaging findings lead to the diagnosis of ARVC/D. According to this observation, the authors describe the authors review the literature on this rare entity and discuss the different therapeutic approaches.

Keywords: *Arrhythmogenic dysplasia of the right ventricle/ genetics; ventricular tachycardia; electrocardiogram; magnetic resonance imaging.*

1. INTRODUCTION

During the last decades of progress in cardiology, many newly declared diseases have been described. One of these recently recognized conditions was arrhythmogenic right ventricular cardiomyopathy/dysplasia (ARVC/D), first described in 1978 by Franck et al. [1]. The clinical spectrum of this condition was described by Marcus et al. in 1982 [2]. The typical prevalence is between 1/2000 and 1/5000 patients. ARVC/D peaks in frequency between the ages of 30 and 50. Despite its low prevalence, it is said that 5-20% of sudden deaths in young people are due to ARVC/D. Patients present with different symptoms, especially after puberty and before age 50. In addition, family history is present in 30-70% of cases due to autosomal dominant inheritance.

ARVC/D is a cardiomyopathy of genetic origin, caused by abnormalities of the desmosomes,

characterized on the physiopathological level by a fibro-adipose infiltration replacing the myocardium of the right ventricle and on the clinical level by an electrical instability leading to ventricular arrhythmias [3]. Diagnostic criteria have been established to retain the diagnosis of ARVC/D. Imaging and especially MRI plays a vital role in this diagnosis.

2. CASE PRESENTATION

We report the observation of a 48-year-old man, a former smoker, with a family history of the sudden death of a sister at the age of 26 during a bicycle race, complaining for several years of palpitations.

These are angina-like palpitations of sudden onset and end, occurring with minimal effort and at rest, well-tolerated functionally, and associated with progressively worsening stage II dyspnea becoming stage IV with orthopnea. The patient

does not report any notion of vertigo, syncope, or faintness. The physical examination notes a normotensive patient (BP at 115/85 mm Hg) with a heart rate of 130 beats/min. Cardiac auscultation finds a systolic murmur rated 3/6th at the pulmonary focus. Pulmonary auscultation is unremarkable. The resting electrocardiogram (ECG) highlights the appearance of an incomplete right bundle branch block with the presence of the epsilon wave (Fig. 1). A 24-hour Holter ECG is performed, highlighting episodes of non-sustained VT.

All these elements plead in favor of a ventricular tachycardia whose origin would be right ventricular.

Transthoracic cardiac echocardiography shows a dilated right ventricle (RV) with significantly impaired systolic function, globally hypokinetic with the presence of aneurysm foci at the level of the apex (Fig. 2). It is not hypertrophied but is the seat of many trabeculations. The surface shortening fraction of the RV is estimated at 25%. The left ventricle is structurally normal.

Cardiac MRI reveals dilation of the right ventricle, with very extensive intramyocardial fibrosis at the level of the free wall of the RV (Fig. 3, Fig. 4). It is the site of foci of aneurysms in the subtricuspid (Fig. 5), at the level of the pulmonary infundibulum, the tip of the RV, as well as foci of bulging of the anterior and lateral wall of the RV. The left ventricle is non-dilated, with moderately impaired systolic function (LVEF 45%).

Coronary angiography shows a coronary network free of stenosis.

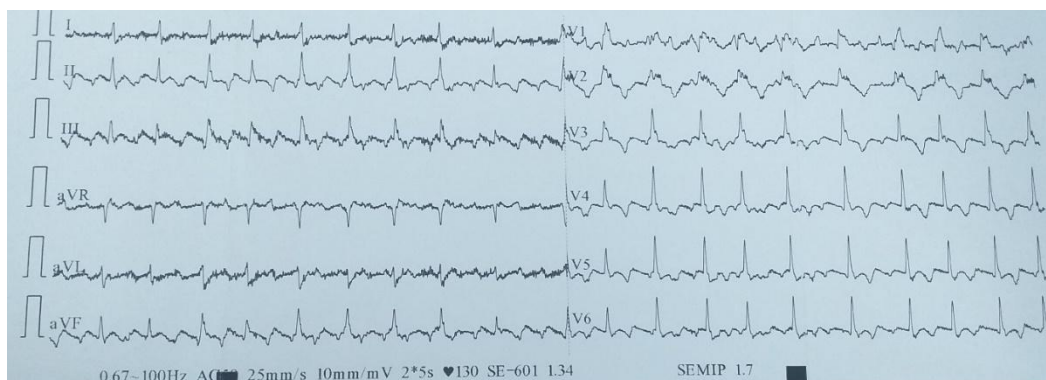
The diagnosis of ARVC/D is retained. The patient is put on amiodarone, beta-blockers, an ACE inhibitor, loop diuretics, and potassium-sparing agents. Given the family history of sudden death, the patient was fitted with a single-chamber implantable cardioverter-defibrillator without incident (Fig. 6). A genetic investigation was carried out without discovering minor or significant signs of ARVC/D in the collaterals. After one year of follow-up, no rhythmic event was detected.

3. DISCUSSION

In 1994, the World Health Organization (WHO) classified ARVC/D as non-ischemic cardiomyopathy [4].

It is more common in men than in women (ratio 3/1). It is a significant cause of sudden death in young athletes, representing less than 10% of sudden death in people under 65 [5].

The clinical picture generally appears between the second and fourth decades of life. Patients may report palpitations secondary to ventricular extrasystoles, ventricular tachycardia, signs of heart failure, syncope, and even sudden death. ARVC/D is often underdiagnosed [6].



Please replace all figures with in clear view

Fig. 1. ECG abnormalities in favor of DAVD. Epsilon waves (red arrow); Microvoltage witness to an advanced DAVD; Inversion of the T wave beyond V2

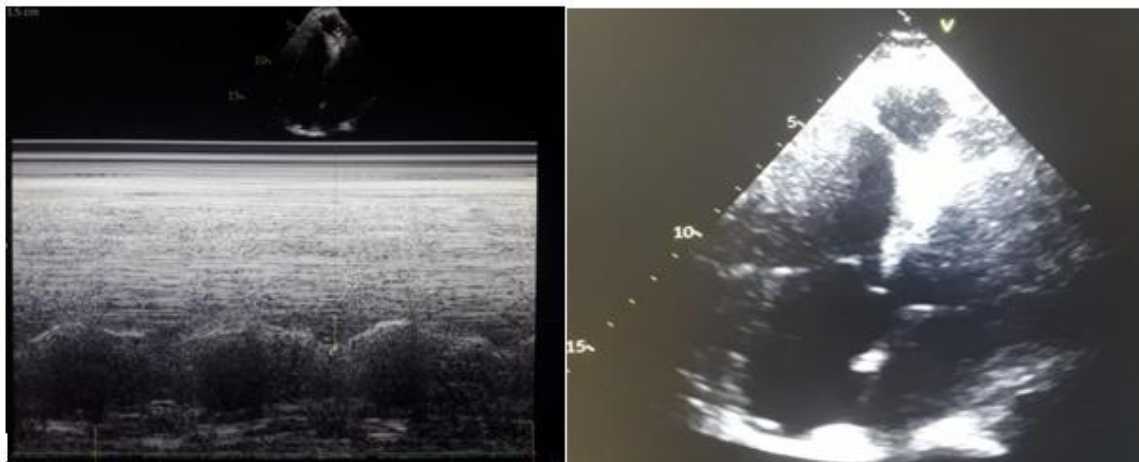


Fig. 2. TTE- Apical four chamber window. Anevrysm of the apex (red arrow); Right ventricular impaired systolic function: Tricuspid annular plane systolic excursion (TAPSE) =15 mm (blue arrow)

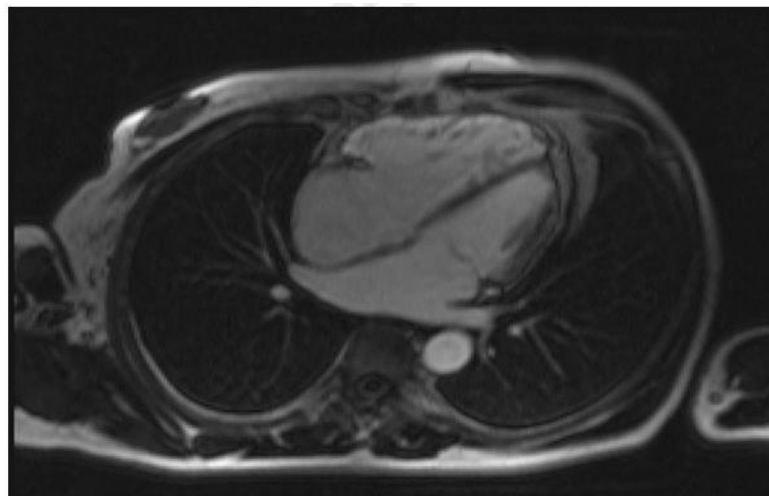


Fig. 3. Cine sequence in Steady State Free Precession (SSFP), 4-cavity incidence, post injection of contrast product (PDC). RV free wall hypersignal related to fatty infiltration (red arrow)

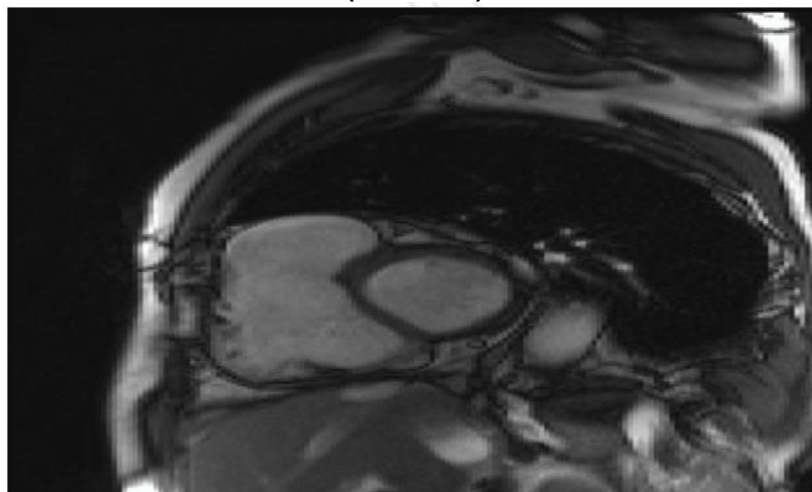


Fig. 4. Late enhancement sequence, 4-cavity incidence, contrast enhancement of the RV side of the SIV and of the free wall of the RV related to the fibrosis (red arrow)

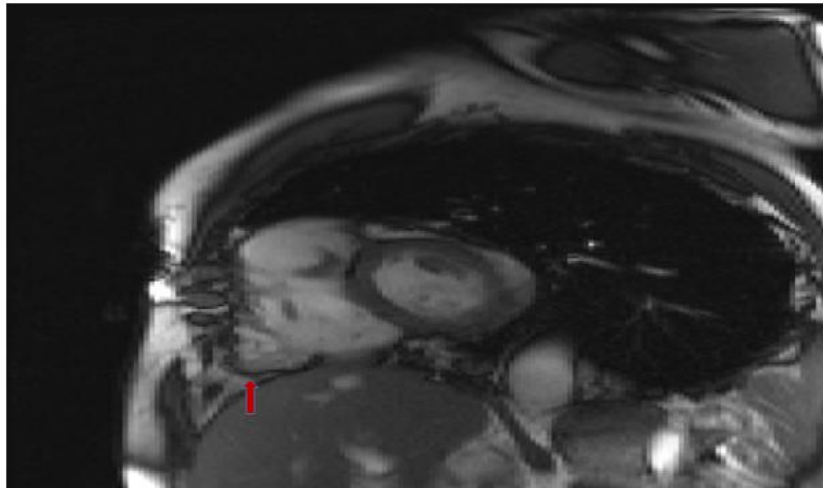


Fig. 5. SSFP cine sequence, short axis incidence, presence of an aneurysm in the paratricuspid region (red arrow)

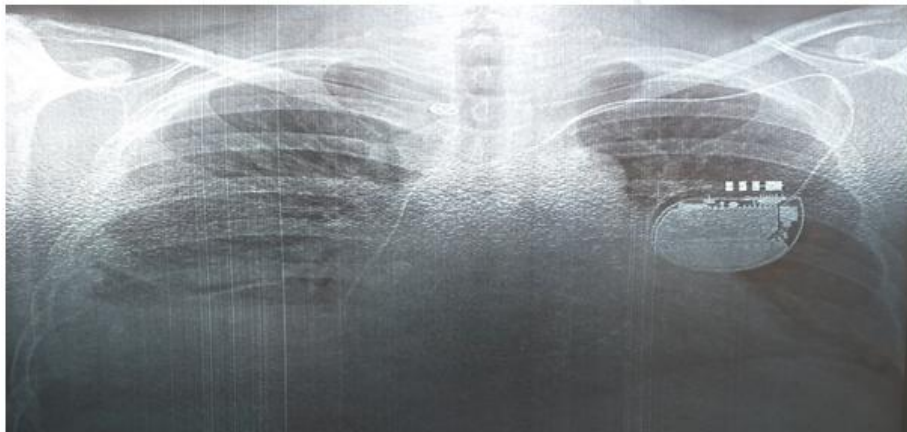

Fig. 6. Single-chamber implantable cardioverter defibrillator (red arrow)

The transmission of the disease is almost always autosomal dominant, which means a 50% risk of transmission to each first-degree relative. In sporadic cases, corresponding to a syndromic form with cardiac, cutaneous (palmoplantar hyperkeratosis), and appendages (woolly hair) involvement, it is a recessive transmission (Naxos or Carvajal syndrome) [7].

The diagnosis of ARVC/D is based on a range of arguments. The diagnostic criteria for AVDD were specified in 1994 by the International Task Force of Cardiomyopathies and updated in 2010. A scoring system was established, with major (2 points) and minor (1 point) criteria, considering ECG, para-clinical, personal, and family parameters. The diagnosis is deemed specific to the presence of a score ≥ 4 , as probable if the

score is 2 of 3, and as possible if the score is 2. Nevertheless, these diagnostic criteria have limitations due to the phenotypic heterogeneity of the ARVC/D and incomplete penetrance. The diagnosis can be as problematic in the forms of beginners or rough, even though there may be a rhythmic risk [8]. Electrocardiogram abnormalities are found in more than 90% of patients with ARVC/D. About 40% of patients may have a normal ECG, but all will show abnormalities over six years, and repolarization disorders are common. Delayed terminal activation and fragmented QRS are also prevalent. Low amplitude and QRS fragmentation are independent risk factors for adverse events. The prevalence of epsilon was up to 30%, being one of the major criteria for the diagnosis of ARVC/D, but it has a low specificity

[6,9]. Diagnosis of this clinical entity has been made easier thanks, in particular, to advances in imaging. It is commonly established that ultrasound, coupled with cardiac MRI, improves sensitivity and increases it from 75 to 85%. RV angioscintigraphy, little practiced under our skies, remains a reference examination for the search for small foci of dysplasia, undetectable on MRI. It should be noted that the polymorphism of this disease and the relative initial latency does not generally allow an early diagnosis, rarely made before the age of 20, and sometimes even at autopsy in the aftermath of a death. Sudden, in athletic adults or not. On the other hand, the discovery of this disease beyond 60 is relatively rare.

The treatment of ARVC/D is based on the antiarrhythmic component. The efficacy of these treatments is comparable, and the data in the literature argue in favor of the absence of a net reduction in mortality compared to the defibrillator [10]. The extension of dysplasia to the left ventricle and the occurrence of resuscitated sudden death or in a first-degree relative is poor prognosis criteria, and each constitutes a legitimate indication for the implantation of an implantable automatic defibrillator [11,12]. Radiofrequency Ablation may be attempted in some with the same VT form that is not controllable by medical treatment alone or that causes multiple defibrillation shocks that may cause premature exhaustion of the defibrillator [13,14]. The appearance of signs of congestive heart failure is considered an evolutionary turning point for this disease. Apart from the usual treatment of heart failure, which is based on ACE inhibitors, beta-blockers, loop diuretics, and potassium-sparing agents, the only effective treatment would be heart transplantation [15]. In the meantime, a defibrillator can be implanted.

Finally, the genetic investigation is an integral part of overall medical care, the aim of which is to detect the first signs of the disease and to reduce the risk of sudden death linked to rhythmic complications, which currently remains close to 2%/ year without treatment and 0.7%/year with antiarrhythmic treatment. In the future, gene therapy could provide a radical solution for treating diseased desmosomes and could, by restoring normal cellular homeostasis, regress or stabilize the disease [16,17].

4. CONCLUSION

Due to scientific and technological advances, ARVC/D has become a more manageable entity

to diagnose and treat. The Task Force criteria, updated in 2010, increase diagnostic sensitivity. The treatment of ARVC/D has been revolutionized by defibrillator technology. On the other hand, acting directly on the ultra-structural anomaly, which would be the ideal curative treatment, requires even more effort to prevent this disease's occurrence, stabilize it, and prevent its complications.

CONSENT

As per international standard or university standard, patients' written consent has been collected and preserved by the author(s).

ETHICAL APPROVAL

As per international standard or university standard written ethical approval has been collected and preserved by the author(s).

COMPETING INTERESTS

Authors have declared that no competing interests exist.

REFERENCES

1. Franck R, Fontaine G, Vedel J, Mialet G, Sol C, Guiraudon G, et al. Electrocardiologie de quatre cas de dysplasie arythmogène ventriculaire droite. *Arch Mal Cœur* 1978;71:963-72.
2. Marcus FI, Fontaine GH, Guiraudon G, Franck R, Laurence JL, Malergue S, et al. Dysplasie ventriculaire droite. *Circulation* 1982;65:384-98.
3. Marcus FI, Fontaine GH, Guiraudon G, et al. Right ventricular dysplasia: a report of 24 adult cases. *Circulation*, 1982;65:384-398.
4. Te Riele AS, Hauer RN. Arrhythmogenic right ventricular dysplasia/ cardiomyopathy: clinical challenges in a changing disease spectrum. *Trends Cardiovasc Med*. 2015;25(3):191-8.
5. Asimaki A, Kleber AG, Saffitz JE. Pathogenesis of arrhythmogenic cardiomyopathy. *Can J Cardiol*. 2015;31(11):1313-24. DOI:10.1016/j.cjca.2015.04.012.
6. Corrado D, Wichter T, Link MS, Hauer RN, Marchlinski FE, Anastasaki A, et al. Treatment of arrhythmogenic Right Ventricular Cardiomyopathy Dysplasia: An International Task Force Consensus Statement. *Circulation*. 2015;132(5):441-53.

- DOI:10.1161/CIRCULATIONAHA.115.017944.
7. Basso C, Corrado D, Marcus FI, Nava A, Thiene G. Arrhythmogenic right ventricular cardiomyopathy. *Lancet* 2009;373:1289-300.
 8. Treatment of Arrhythmogenic Right Ventricular Cardiomyopathy/Dysplasia. An International Task Force Consensus Statement. *Circulation*. 2015;132(5):441–453.
 9. Mast TP, Teske AJ, vd Heijden JF, Groeneweg JA, Te Riele AS, Velthuis BK, et al. Left Ventricular Involvement in Arrhythmogenic Right Ventricular Dysplasia/Cardiomyopathy Assessed by Echocardiography Predicts Adverse Clinical Outcome. *J Am Soc Echocardiogr*. 2015;28(9):1103-13.e9. DOI:10.1016/j.echo.2015.04015.
 10. Marcus GM, Glidden DV, Polonsky B, Zareba W, Smith LM; Cannom DS, Estes NA 3rd, Marcus F, Scheinman MM, Multidisciplinary Study of Right Ventricular Dysplasia Investigators Efficacy of antiarrhythmic: A report from the North American ARVC Registry. *J Am Coll Cardiol*. 2009; 54(7):609-615.
 11. Corrado D, Leoni L, Link MS, Della Bella P, Gaita F, Curnis A, Salerno JU, et al. Implantable cardioverter-defibrillator therapy for prevention of sudden death in patients with arrhythmogenic right ventricular cardiomyopathy/ dysplasia. *Circulation*. 108:3084-3091.
 12. Bhonsale A, James CA, Tichnell C, Murray B, Gagarin D, Phillips B, et al. Incidence and predictors of implantable cardioverter-defibrillator therapy in patients with arrhythmogenic right ventricular cardiomyopathy undergoing implantable cardioverter-defibrillator implantation for primary prevention. *Am Coll Cardiol*. 2011;58(14):1485-96.
 13. Radiofrequency catheter ablation of ventricular tachycardia in arrhythmogenic right ventricular dysplasia/ cardiomyopathy using non-contact electroanatomical mapping: A single-center experience with follow-up to a median of 30 months. Nair M; Yaduvanshi A, Kataria V, Kumar MJ. *Interv Card Electrophysiol*. 2011;31(2):141-7. Epub 2011 Mar 25.
 14. Bai R, Biase L, Shivkumar K, Mohanty P, Tung R, Santangeli P, Saenz LC, et al. Ablation of ventricular arrhythmias in arrhythmogenic right ventricular dysplasia/ cardiomyopathy: arrhythmia-free survival after endo-epicardial substrate-based mapping and Ablation. *Circ Arrhythm Electrophysiol*. 2011;4(4):478-85.
 15. Arbelo E, Josephson ME. Ablation of ventricular arrhythmias in arrhythmogenic right ventricular dysplasia. *J Cardiovasc Electrophysiol* 21(4):473-486.
 16. Tedford RJ, James C, Judge DP, Tichnell C, Murray B, et al. Cardiac transplantation in arrhythmogenic right ventricular dysplasia/ cardiomyopathy. *J Am Coll Cardiol*. 2012;59(3):289-90.
 17. Capulzini L, Brugada P, Brugada J, Brugada R. Arrhythmia and right heart disease: From genetic basis to clinical practice. *Rev Esp Cardiol*. 2010;63(8):963-83.