

ACUTE MYOCARDITIS AFTER COVID-19 INFECTION IN A YOUNG PATIENT: A CASE REPORT

ABSTRACT:

A 23 years-old male patient with a recent history of flu symptoms presented to the emergency department for acute chest pain. The electrocardiogram (ECG) found diffuse ST elevation in anterior territory. Transthoracic Echocardiography (TTE) showed left ventricular systolic dysfunction with changes in segmental contractions. Coronary angiography revealed normal coronary arteries. Due to the pandemic context, COVID-19 PCR test with serology was performed, it was positive. Cardiac Magnetic Resonance Imaging (MRI) confirmed acute myocarditis. The patient was discharged 7 days later with good clinical evolution.

Through this article, we learn to consider cardiac involvement of SARS-CoV19, even with poor respiratory symptomatology, and to insist on the importance of the cardiac evaluation even for young patients with a mild Covid-19 infection.

KEYWORDS:

Covid-19, Myocarditis, Coronavirus infections, Echocardiography.

INTRODUCTION:

Coronavirus disease 2019 (COVID-19) was first reported in China in December 2019 and is caused by the SARS-CoV-2 virus (severe acute respiratory syndrome coronavirus 2). In March 2020, it was declared as worldwide pandemic. (1, 2) Clinical presentation is large, going from asymptomatic to severely sick patients, with fever, cough, myalgia, and/or fatigue, as most common symptoms. (3)

Cases of cardiac involvement by the COVID-19, developing with acute myocarditis have also been described, mostly in serious and severe cases, (4, 5) but still underdiagnosed in young population having mild COVID-19 infections.

We present the case of an acute myocarditis related to a mild COVID-19 infection in a young patient.

CASE REPORT:

A 23 year-old male, without any previous medical or surgical history, presented to the emergency department for an acute chest pain spreading to the neck and both arms, fever, fatigue and weakness. A family history was not contributory. There was no history of recent intake of any drug. He reported a history of recent flu-like symptoms fifteen days before, and was treated by a symptomatic treatment without clinical amelioration.

The physical examination found fever (38,6°C), SaO₂=98% hemodynamic stability (blood pressure = 116/75 mmHg, heart rate = 81 beats per minute), without signs of acute heart failure. ECG found regular sinus rhythm (81 bpm) with a diffuse ST-segment elevation in the anterior territory. (Figure 1)

Echocardiography revealed a left ventricular systolic dysfunction with a hypokinesia of the anterior, anteroseptal, anterolateral walls, with a left ventricular ejection fraction (LVEF) at 40%.

Myocardial injury markers showed elevated troponin (15431ng/ml).

Biochemical assessment (Table 1) revealed inflammatory reaction, with elevated C-reactive protein (CRP).

Coronary angiography was performed, being normal.

Cardiac MRI revealed the presence of late enhancement areas in 7 LV segments out of 17, confirming then, the diagnosis of an acute myocarditis. (Figure 2)

Immunological tests for autoimmune illnesses and other viral serological tests (including hepatitis B and C viruses, HIV, and Cytomegalovirus) were likewise negative (CMV). → (CMV).

By reverse transcription polymerase chain reaction (RT-PCR), the nasopharyngeal swab tested negative for COVID-19, but serology testing came back positive (for both Immunoglobulin G and M). The diagnosis of Covid-19 infection was considered.

The patient was managed hemodynamically and treated with steroids, with significant amelioration of clinical symptoms and progressively normal biochemical tests, after 3 weeks of therapy. A TTE control showed a significant amelioration of the LVEF to 55%, with a normal wall motion.

	At Admission	7 days later	Reference values
Troponin us	15431	9679	<30 ng/ml
CRP	61.7	31	<5mg/l
White cell count	9300	7831	4000-10000/ul
Lymphocytes count	1391	1702	1500-4000/ul
Hemoglobin	14.8		13-18g/dl
Plaquet count	261000		150000-400000/ul
Creatinin	8.7	7.3	7-12mg/l
CPK	504	377	<30UI/l

Table 1: Laboratory tests at the admission, and 7 days later.

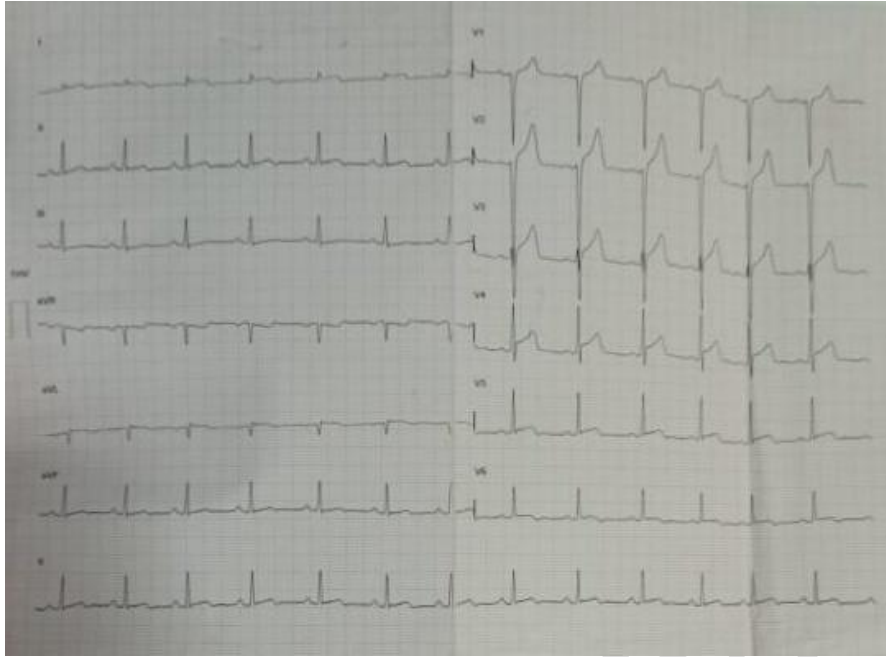


Figure 1 : ECG found diffuse ST-segment elevation in the anterior territory.

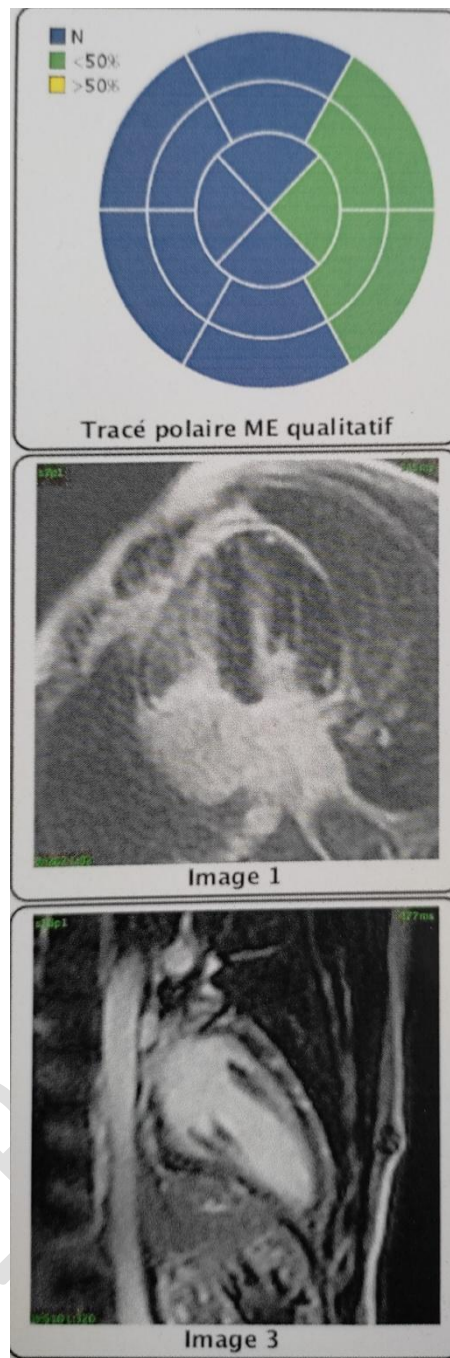


Figure 2 : MRI revealing the presence of late enhancement areas in 7 out of 17 LV segments confirming the diagnosis of an acute myocarditis.

DISCUSSION:

Myocarditis is defined as an inflammation affecting the heart, characterized by a myocardial injury and necrosis with, inflammatory infiltrates (ischemic cause non considered). Exact mechanisms and physiopathology of myocarditis related to COVID-19 are still not yet clearly understood. Most probably, it is the result of direct viral **infection to** the myocardium or

by the indirect toxicity **caused by** the systemic reaction, generating hypersensitivity reaction or vasculitis. (6)

The analysis of around 45,000 confirmed cases of COVID-19 in China found out cardiovascular involvement, such as myocardial injury (20%), arrhythmias (16%), myocarditis (10% of cases), and heart failure. **(7, 8)**

Other studies suggest that severe COVID 19 infections with cardiovascular complications are mostly observed around 10 to 15 days after the beginning of symptoms **(9)**, (which is convenient with our case). This explains also the negative COVID-19 PCR test.

A variety of cases of acute myocarditis were documented, ranging in severity from complete recovery during the first week of treatment (as in our case), to more serious cases recovering over several weeks, or to cardiogenic shock and death **(3, 10)**.

Increased troponin I was reported in almost all the cases COVID-19 related myocarditis (like in our case). Some studies suggested that the high troponin level was observed in severe cases much more than others. **(11)**

Inciardi and al. **(12)** and the majority of myocarditis related to COVID-19 cases, figured out left ventricular systolic dysfunction with changes in segmental contractions on the transthoracic echocardiography (TTE). This was reported also in our case.

Although MRI remains the gold standard diagnostic test to look for compatible signs with myocarditis, (non-ischemic late **enhancement pattern**, like in our case), and this, from a practical point of view, it is clearly difficult and burdensome to perform in COVID-19 patients with the associated risk of infection and contamination. Echocardiography may be helpful in assessing ventricular function. Interpreting BNP (or pro BNP), in this context, might be difficult to assess myocardial degradation. **(13)**

There is still no clear therapeutic consensus in the literature for myocarditis related to COVID-19. Following the first recorded cases, various treatments (steroids, intravenous human immunoglobulin, antiviral therapy, inotropic support, interferon alpha-1b, methylprednisone) were recommended, with essentially identical effects **(3, 10, 12)**.

In this pandemic, it's critical to consider the possibility of cardiac involvement, particularly in patients who have an unexplained increase in myocardial necrosis markers, a new dysfunction documented by Echocardiography, or a sudden deterioration of symptoms despite respiratory support measures, and in patients who have an unexplained increase in myocardial necrosis markers, a new dysfunction documented by Echocardiography, or who have an abrupt deterioration of symptoms despite respiratory support.

CONCLUSION:

Despite our patient's poor respiratory symptomatology, a significant heart issue was discovered. This highlights the risk of COVID-19-related cardiac involvement even in the absence of acute respiratory symptomatology, as well as the importance of a thorough cardiac assessment, particularly in young patients with a mild Covid-19 infection.

Ethical Approval:

As per international standard or university standard written ethical approval has been collected and preserved by the author(s).

Consent

As per international standard or university standard, patients' written consent has been collected and preserved by the author(s).

REFERENCES:

- 1- Cascella M, Rajnik M, Cuomo A, Dulebohn SC, Di Napoli R. Features, Evaluation and Treatment Coronavirus (COVID-19). 2020 Jul 4. StatPearls [Internet]. Treasure Island (FL): StatPearls Publishing; 2020 [cited 2020 Jul 20].
- 2- Ekinci A, Yücel Uçarkuş T, Okur A, Öztürk M, Doğan S. MRI of pneumonia in immunocompromised patients: comparison with CT. Diagn Interv Radiol. 2017;23(1):22-8.
- 3- J.H. Zeng, Y.X. Liu, J. Yuan, et al., First case of COVID-19 complicated with

fulminant myocarditis: a case report and insights, *Infection* 48 (2020) 773–777.

- 4- Hu H, Ma F, Wei X, Fang Y. Coronavirus fulminant myocarditis saved with glucocorticoid and human immunoglobulin. *Eur Heart J*. 2020 Mar 16: Volume 42, Issue 2, page 206.
- 5- Rente A, Uezato Junior D, Uezato KM. Coronavirus and the heart | A case report on the evolution of COVID-19 Associated with Cardiological Evolution. *Arq Bras Cardiol*. 2020;114(5):839-42.
- 6- Pagnoux C, Cohen P, Guillevin L. Vasculitides secondary to infections. *Clin Exp Rheumatol*. 2006;24(2 Suppl 41):S71-81. Review.
- 7- Wang D, Hu B, Hu C, Zhu F, Liu X, Zhang J, et al. Clinical characteristics of 138 hospitalized patients with 2019 novel coronavirus-infected pneumonia in Wuhan, China. *JAMA*. 2020;323(11):1061-9.
- 8- Shi S, Qin M, Shen B, Cai Y, Liu T, Yang F, et al. Association of cardiac injury with mortality in hospitalized patients with COVID-19 in Wuhan, China. *JAMA Cardiol*. 2020;5(7):802-10.
- 9- A. Magadum, R. Kishore, Cardiovascular manifestations of COVID-19 infection, *Cells*. 2020 Nov 19;9(11):2508. doi: 10.3390/cells9112508.
- 10- H. Hu, F. Ma, X. Wei, Y. Fang, Coronavirus fulminant myocarditis saved with glucocorticoid and human immunoglobulin, *Eur. Heart J*. (2020). Volume 42, Issue 2, page 206
- 11- F. Zhou, T. Yu, R. Du, G. Fan, Y. Liu, Z. Liu, et al., Clinical course and risk factors for mortality of adult inpatients with COVID-19 in Wuhan, China: a retrospective cohort study, *Lancet* (2020).
- 12- R.M. Inciardi, L. Lupi, G. Zacccone, L. Italia, M. Raffo, D. Tomasoni, et al., Cardiac involvement in a patient with coronavirus disease 2019 (COVID-19), *JAMA Cardiol* 5 (7) (2020) 819–824.

13-Zeng, J.H.; Liu, Y.; Yuan, J.; Wang, F.; Wu, W.; Li, J.; Wang, L.; Gao, H.; Wang, Y.; Dong, C.; Li, Y.; Xie, X.; Feng, C.; Liu, L. First Case of COVID-19 Infection with fulminant Myocarditis Complication: Case Report and Insights.

UNDER PEER REVIEW