

INFERIOR VENA CAVA TUMOR THROMBUS EXTENDING UP TO THE RIGHT ATRIUM

ABSTRACT:

Hepatocellular carcinoma (HCC) is one of the most common malignant tumors. Formed tumor thrombus (TT) may extend to the inferior vena cava (IVC) and even may extend up to the right atrium. Such a scenario is rare and poses a real surgical challenge. The prognosis for this condition is extremely poor, with a median survival time of several months. Furthermore, there is no established effective treatment for the condition. The management of patients with advanced HCC and a TT extending into the RA and IVC is extremely difficult and risky. We report an intrahepatic cholangiocarcinoma case with a tumor thrombus extending from the IVC to the RA, revealed by an acute pulmonary embolism assessing the clinical manifestations, pathophysiology, imaging diagnosis techniques and associated positive treatments for HCC with TT in IVC or RA.

KEYWORDS:

Pulmonary embolism, tumor thrombus, right atrium, inferior vena cava,

INTRODUCTION:

Hepatocellular carcinoma (HCC) is one of the most common malignant tumors. Tumor thrombus (TT) formation is seen in advanced-stages HCC (1). It is common and usually involves the hepatic or portal veins. The extension into the inferior vena cava (IVC) and subsequently into the right atrium (RA) is a very rare entity and predictive of extremely worse prognosis (2,3). The patients can present with no special clinical manifestations (4). To the best of our knowledge, there is currently no

worldwide consensus regarding the management of HCC with IVC/RA TTs. The reported treatment measures include surgery, radiotherapy, chemotherapy, radiotherapy combined with chemotherapy, intervention, (5,6).

We present the case of TT in the IVC extended to the RA and revealed by a pulmonary embolism in a patient with HCC.

CASE REPORT:

A 59-year-old man presented with a progressive onset of dyspnea over one month, abdominal distension, and a deterioration of general conditions. He reported a history of chronic alcoholism and smoking. He was followed in gastrology department for a heteronodular liver with suspected Hepatocellular Carcinoma. He also reported the notion of bed rest during this last month. At the time of his presentation, he was in a bad general condition. Physical examination found a subicteric patient, BP=110/62mmhg, HR=107bpm, SaO₂=96%, an abdominal distension with a non- tender hepatomegaly, and discrete lower limb edema. Electrocardiogram was normal.

Transthoracic Echocardiography showed a good biventricular function (EF=60%), with a right intraauricular “serpiginous” hyperechogenic mass measuring 31*30mm (**Figure 1**) extended to the inferior veina cava measuring 24mm (**Figure 2**).

Chest and abdominal Contrast-enhanced CT scan showed a right lower lobe and upper segmental pulmonary embolism, with a thrombus tumor extended from the IVC to the RA. (**Figure 3**).

The patient started anticoagulation. Gastrology team evaluated him and they determined he was not a candidate for surgery. He was discharged with a plan to receive palliative treatment as an outpatient, and unfortunately he passed three months after the diagnosis.

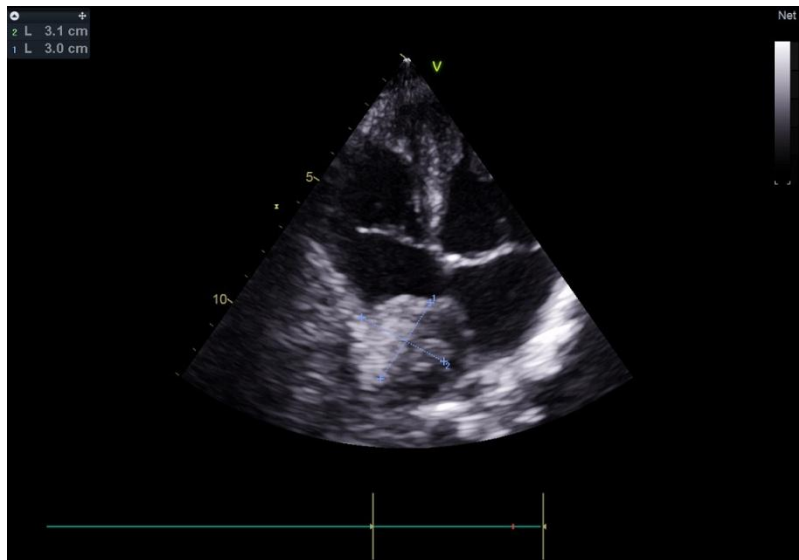

Figure 1: TTE showing a right intraauricular hyperechogenic mass measuring 31*30mm

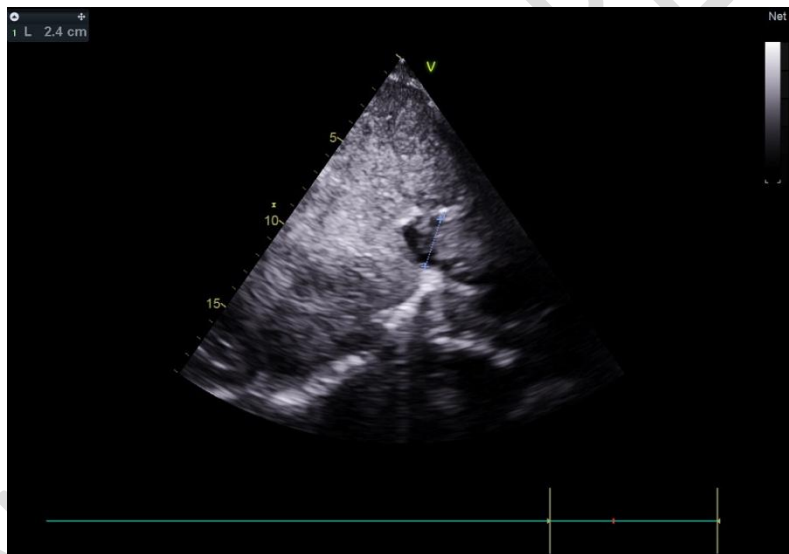

Figure 2: TTE showing the intra- Inferior Veina cava mass measuring 24mm

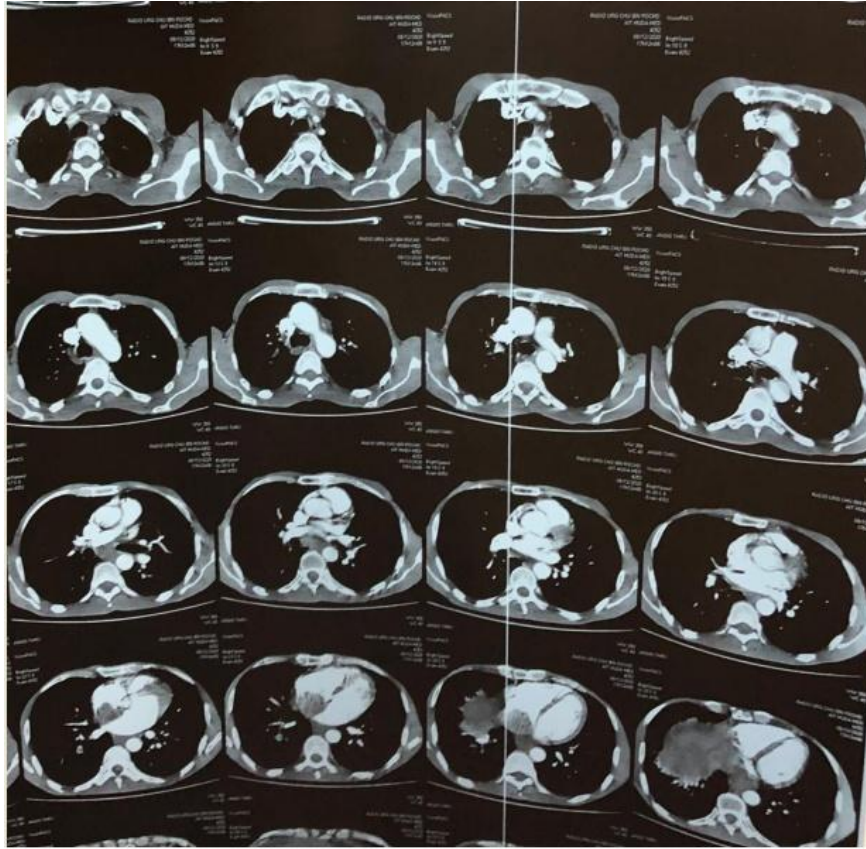


Figure 3: Chest and abdominal Contrast-enhanced CT scan showing a right lower lobe and upper segmental pulmonary embolism, with a thrombus tumor extended from the IVC to the RA.

DISCUSSION: (17)

Patients with a tumor thrombus (TT) in the IVC or RA and a hepatic tumor such as hepatocellular carcinoma have a high mortality risk. HCC is a very aggressive tumor with tendency to migrate through the vessels forming tumor thrombus involving the portal or hepatic vein (HV). The incidence of TT in the IVC and RA in cases of advanced HCC is up to 4.9%, with a median survival duration in untreated patients of 25 months (4, 7, 8). It is believed that due to the lack of specific clinical signs, it may have been under-diagnosed, and the incidence is now increasing with the availability of improved imaging studies. (18)

TT in the RA may be an isolated TT, but the IVC TT are more often observed to be extending into the RA. Anthony (12) found that almost 78% cases of TT in the RA originate from the

IVC, and almost 25% cases of TT in the RA are large enough to prolapse to the right ventricle and cause tricuspid stenosis or insufficiency.

Tumors in the right hepatic lobe usually invade the right HV and directly affect the IVC. The left hepatic lobe tumor first invades the left HV and the middle HV, then enters the IVC, and finally invades the RA (13).

TT is classified based on the anatomic location relative to the heart, which also determines the surgical approach when decided. Type I TT involves IVC below the diaphragm; type II TT involves IVC above the diaphragm but outside RA; and type III (intracardiac) TT is TT above the diaphragm that reaches the RA (like in our case). (14)

The clinical manifestations associated with the TT depend on the location, stability of the TT, and the level of blockage of the vein. Usually, incomplete blockage of the HV and IVC has no special clinical manifestation, while the complete obstruction may cause Budd-Chiari syndrome as well as acute right heart failure and pulmonary embolism (As in our case). (9). The patient can present with manifestations such as varicose veins of the esophagus, or the thoracic cavity and abdomen, pleural effusion, abdominal pain and distension and sometimes a palpable mass, mild fever lower extremity edema, tachycardia and dyspnea, syncope, repeated pneumonia and sudden death that might be caused by the detachment of the embolus (4,10). The risk for cardiopulmonary collapse is high and heart failure or sudden death is noted as the cause of death in 25% of the patients with HCC with intracavitary cardiac involvement (11).

IVC/RA TT may be diagnosed by Doppler ultrasound, CT scan, or MRI.

Electrocardiograms can show a complete right bundle branch block. (It was normal in our patient).

Cardiac and Abdominal Echography show a substantial echo mass in the HV and IVC, sometimes extending to the RA (like in our patient). Color Doppler ultrasound shows HV or IVC blood flow to be narrow or interrupted; HV and IVC masses show the same changes as intrahepatic lesions (hyperechoic enhancement in the arterial phase and hypoechoic enhancement in the portal phases). transesophageal Echography is **important** for making surgical decisions, as it is important to determine the location and classification of TT (15).

CT scans can demonstrate a low or iso density mass, which is equal to the density of the cardiac tissue. The vascular lumen is observed to be irregularly narrow and locally compressed or surrounded by the tumor. In general, patients with suspected TT in the HV or IVC must also undergo an injected CT scan to confirm the diagnosis and eliminate any misinterpretation. (Like in our case) **(16)**.

The study of TT in the IVC and RA with MRI was clearer and more performant compared the one the CT scan. It demonstrates the location and length of the TT, which provided the necessary basis for developing a surgical plan. It shows a T1 low signal block of TT in the HV and IVC cavity and a T2 high signal block. Furthermore, scanning with enhanced arterial phase showed mild-to moderate inhomogeneous abnormal enhancement of the block in the IVC, that with enhanced portal vein phase showed a decreased degree of block shadow enhancement, and the delayed phase showed slight enhancement. The intrahepatic lesions were generally consistent with those of TT in the IVC **(16)**.

(In our case, MRI was not performed).

All patients with TT extending from retrohepatic IVC and RA are considered treatable by surgery if the primary hepatic tumor can be resected. Patients with decompensated liver cirrhosis, advanced stage of the primary tumor, and distant metastases are not considered surgical candidates.. While Type I TT can be treated by radical hepatectomy and type II via abdominal approach and total hepatic vascular exclusion (THVE), once tumor extends fully into RA, cardiopulmonary bypass (extracorporeal circulation) is essential during surgery (like in our case) **(4, 7)**. Postoperative adjuvant chemotherapy is required given a high likelihood of recurrence following surgery. Radiotherapy may be used in some cases.

CONCLUSION:

Tumor thrombus formation is common in HCC. However, expansion to the right atrium is rare and indicates a worse prognosis. Doppler ultrasound, CT and MRI, and magnetic resonance angiography can be used to detect the size, location, length and degree of TT directly and clearly, which guide the selection of treatment modalities, assessment of the

degree of treatment difficulty and risks. If the patient is a good surgical candidate, surgery carries the best chances.

Consent Disclaimer:

As per international standard or university standard, patient's consent has been collected and preserved by the authors.

REFERENCES:

- 1- SEER Cancer Statistics Review, 1975-2016, National Cancer Institute (2019). Accessed: May 16, 2019.
- 2- Florman S, Weaver M, Primeaux P, et al: Aggressive resection of hepatocellular carcinoma with right atrial involvement. Am Surg. 2009, 75:1104-1108.
- 3- Lin HH, Hsieh CB, Chu HC, et al: Acute pulmonary embolism as the first manifestation of hepatocellular carcinoma complicated with tumor thrombi in the inferior vena cava: surgery or not? Dig Dis Sci. 2007, 52:1554-1557.
- 4- Sun JH, Zhang YL, Nie CH, Chen LM, He JD, Wang WL and Zheng SS: Long-term survival after chemoembolization of metastatic right atrial tumor thrombus as a presenting feature of hepatocellular carcinoma: A case study. Oncol Lett 3: 975-977, 2012.
- 5- Chun YH, Ahn SH, Park JY, Kim DY, Han KH, Chon CY, Byun SJ and Kim SU: Clinical characteristics and treatment outcomes of hepatocellular carcinoma with inferior vena cava/heart invasion. Anticancer Res 31: 4641-4646, 2011.
- 6- Sakamoto K and Nagano H: Outcomes of surgery for hepatocellular carcinoma with

- tumor thrombus in the inferior vena cava or right atrium. *Surg Today* 48: 819-824, 2018.
- 7- Lee I, Chung JW, Kim HC, Yin YH, So YH, Jeon UB, Jae HJ, Cho BH and Park JH: Extrahepatic collateral artery supply to the tumor thrombi of hepatocellular carcinoma invading inferior vena cava: The prevalence and determinant factors. *J Vasc Interv Radiol* 20: 22-29, 2009.
- 8- Okuda K: Hepatocellular carcinoma: Clinicopathological aspects. *J Gastroenterol Hepatol* 12: S314-S318, 1997.
- 9- Sun JH, Zhang YL, Nie CH, Chen LM, He JD, Wang WL and Zheng SS: Long-term survival after chemoembolization of metastatic right atrial tumor thrombus as a presenting feature of hepatocellular carcinoma: A case study. *Oncol Lett* 3: 975-977, 2012.
- 10- Kawakami M, Koda M, Mandai M, Hosho K, Murawaki Y, Oda W and Hayashi K: Isolated metastases of hepatocellular carcinoma in the right atrium: Case report and review of the literature. *Oncol Lett* 5: 1505-1508, 2013.
- 11- Sung AD, Cheng S, Moslehi J, Scully EP, Prior JM, Loscalzo J. Hepatocellular carcinoma with intracavitary cardiac involvement: a case report and review of the literature. *Am J Cardiol*. 2008;102:643-5.
- 12- Anthony PP: Primary carcinoma of the liver: A study of 282 cases in Ugandan Africans. *J Pathol* 110: 37-48, 1973.
- 13- Kojiro M, Nakahara H, Sugihara S, Murakami T, Nakashima T and Kawasaki H: Hepatocellular carcinoma with intra-atrial tumor growth. A clinicopathologic study of 18 autopsy cases. *Arch Pathol Lab Med* 108: 989-992, 1984.
- 14- Sakamoto K, Nagano H: Outcomes of surgery for hepatocellular carcinoma with tumor thrombus in the inferior vena cava or right atrium. *Surg Today*. 2018, 48:819-24.

15- Tse HF, Lau CP, Lau YK and Lai CL: Transesophageal echo- cardiography in the detection of inferior vena cava and cardiac metastasis in hepatocellular carcinoma. Clin Cardiol 19: 211-213,1996.

16- Cheng HY, Wang XY, Zhao GL and Chen D: Imaging findings and transcatheter arterial chemoembolization of hepatic malignancy with right atrial embolus in 46 patients. World J Gastroenterol 14: 3563-3568, 2008.

17- Ayman Z. Azzam and Kareem A. Azzam. Hepatocellular Carcinoma Migrating to the Right Atrium through the Inferior Vena Cava. Sultan Qaboos University medical journal 10.18295. squmj.2018.18.01.024

18- Wei Li†, Yang Wang†, Wenfeng Gao and Jiasheng Zheng HCC with tumor thrombus entering the right atrium and inferior vena cava treated by percutaneous ablation. BMC Surgery 10.1186/s12893-017-0217-y