

ISOLATED HETEROTOPIC PANCREAS IN A CHILD PRESENTING WITH JEJUNAL AND ILEAL INTUSSUSCEPTION: AN ATYPICAL MANIFESTATION

Abstract:

Background:

Heterotopic pancreas is most commonly found in the upper gastrointestinal tract, and is often asymptomatic and detected incidentally. Intussusception involving heterotopic pancreatic tissue is a rare condition, in which a portion of the bowel telescopes into an adjacent segment with intraluminal pancreatic tissue as the lead point. It is the most common cause of intestinal obstruction in children in the 6 months-6 years age group.

Case Presentation:

Here we describe a case of heterotopic pancreas presenting with intussusception. Isolated heterotopic pancreas acted as a lead point for intussusception in this child which is a rare occurrence. The child underwent **laparotomy and resection of the ischaemic bowel** and made a complete recovery post-operatively.

Conclusion:

To the best of our knowledge, very few cases with such a unique presentation have been reported to date. We emphasize the early recognition and treatment of this condition to ensure the best possible prognosis.

Keywords:

heterotopic, pancreas, intussusception, intestine

Introduction:

Heterotopic pancreas (also referred to as accessory pancreas, aberrant pancreas, pancreatic heterotopia, or pancreatic rest) is an uncommon developmental anomaly, in which pancreatic tissue is found on ectopic sites lacking anatomic and vascular continuity with the main body of the pancreas. Intussusception is defined as the telescoping of a segment of the gastrointestinal tract into an adjacent one. It is the most common cause of intestinal obstruction in children in the 6 months-6 years age group and is invariably idiopathic.

The presence of heterotopic pancreas (HP) is unusual but not rare with an estimated incidence of 0.2% of upper abdominal operations. Although it can occur throughout the gastrointestinal tract, the majority of cases involve the stomach, duodenum and jejunum, and ileum.

Cases of HP are predominantly asymptomatic and discovered incidentally. In this case, however, the ectopic pancreatic tissue acted as a lead point for intussusception, which resulted in the patient presenting initially with pain abdomen.

Case Report:

A 12-year-old boy presented to the surgical emergency department with acute onset pain abdomen. The child was crying and in distress. He pointed to the epigastric region when he was asked to localize the pain. His past medical history was unremarkable.

On examination, his vitals were stable. Abdominal examination revealed a sausage-shaped mass in the abdomen. Initial investigations included a complete blood count, erythrocyte sedimentation rate, renal and liver function tests, all of which were normal.

An abdominal ultrasound revealed a loop of abnormal bowel in the pelvis extending to the right iliac fossa. It was noted that the patient experienced marked tenderness from the ultrasound probe over the right iliac fossa. The bowel loop contained concentric rings of high and low echogenicity, which were highly suggestive of a small bowel intussusception. No proximal dilatation was noted. On this basis, the patient was initially managed conservatively with a pneumatic reduction. When conservative management failed, the patient was taken up for laparotomy.

During laparotomy, a long segment of ileal intussusception, measuring (80x45x50mm) was noted. Three small jejunal intussusceptions were also found. The jejunal intussusceptions were reduced. The bowel surrounding the ileal intussusception was found to be markedly ischemic. Thus the ileal intussusception was resected and a primary anastomosis was performed.

A thorough inspection was done to look for a Meckel's diverticulum, which was not found. However, a round polypoid mass measuring (20x20x5.5mm) was noted proximal to the intussusception (Fig 1). On histopathology, ectopic pancreatic tissue was seen in the small bowel (Fig 2).

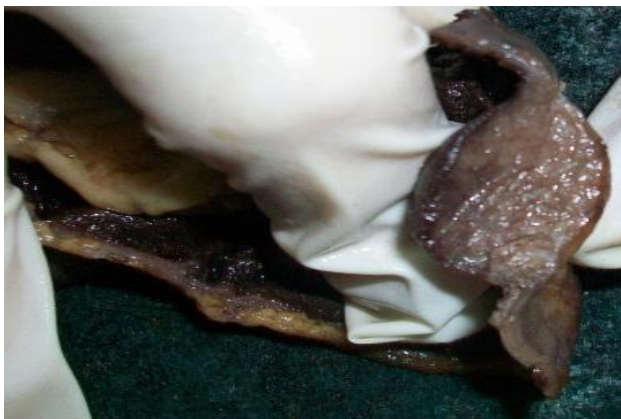

Fig 1. A round polypoid mass was noted proximal to the intussusception

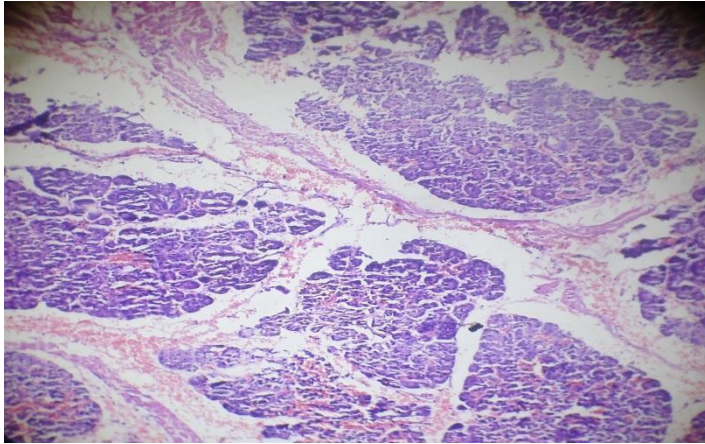


Fig 2. Heterotopic pancreatic tissue is seen on histopathology

The child was kept under observation postoperatively and was discharged. He was symptom-free on follow-up visits and made a complete recovery.

Discussion:

Intussusception is primarily a disease of children with only about 5% of cases occurring in adults [1]. Klob first described the histological appearance of heterotopic pancreas in 1859 [2]. The estimated occurrence of heterotopic pancreas is one per 500 upper abdominal operations and up to 5% of autopsy cases [3][4].

The embryological derivation of heterotopic pancreas is well described [5]. The pancreas is formed from several primitive endodermal evaginations of the primitive duodenal wall. The dorsal diverticulum becomes the body and tail and the ventral portion the head of the pancreas. If one or more of these evaginations remain within the wall of the bowel then these can be carried as longitudinal growth of the intestine continues, leading to ectopic tissue anywhere from the stomach (most common) to the jejunum or ileum (least common). In the latter, HP is usually associated with a Meckel's diverticulum.

Heterotopic pancreas is difficult to diagnose pre-operatively and is usually asymptomatic. If the ectopic pancreas acts as a nidus for bowel obstruction, it would present with vague abdominal pain, nausea, and vomiting [6]. Bowel obstruction occurring in association with gastrointestinal bleeding is even rarer and has been described in a case series in which all the patients presented with abdominal pain and melena [7]. In our case, the distressed child presented with acute onset abdominal pain.

Intussusception caused by HP is rare but has been described previously [3][13][14]. Most cases have been described in the upper gastrointestinal tract, namely the stomach, duodenum, and jejunum. Cases occurring in the ileum are very rare [8][9]. In our case, the child was found to have three jejunal intussusceptions and one ileal intussusception.

In adults, successful management of intussusception from any cause will invariably involve resection of the lead-point tissue and at times, segmental resection of the involved intestine, as was in this case [9]. Surgical resection is often recommended for large bowel intussusception in view of the higher rates of malignancy. This possibility should also be borne in mind in cases of small bowel intussusception despite a reported lower incidence.

Conclusion:

To summarize, heterotopic pancreas of the small bowel is rare, and it is usually associated with Meckel's diverticulum. Isolated heterotopic pancreas of the small bowel is very rare and is usually asymptomatic. In this case, the isolated heterotopic pancreas acted as a lead point for intussusception in the child, who presented acutely with abdominal pain.

After an extensive literature review, it was found that very few cases with such a unique presentation have been reported to date. Most of the cases of intussusception with a pathological lead point were reduced with a barium enema. In this case, the child was diagnosed preoperatively with abdominal ultrasound and was initially managed conservatively with pneumatic reduction. After conservative management was unsuccessful, the patient was taken for a laparotomy and the ischemic bowel was resected.

The child was symptom-free post-operatively and remained symptom-free at follow-up. We reiterate that early recognition and treatment of this condition are imperative to ensure the best possible prognosis.

It is important to palpate the bowel after manual reduction of the intussusception to look for submucosal heterotopic pancreas which may not be visible grossly, as was observed in this case [10]. Intussusception in the pediatric population is commonly associated with Meckel's diverticulum, which should also be looked for. If submucosal ectopic tissue is found, it is removed with a simple excision, which prevents recurrence and further sequelae [11]. The possibility of malignant disease should also be kept in mind while planning surgery and should be ruled out after a thorough workup.

Thus, heterotopic pancreas should be considered among the differentials for intussusception in the pediatric population. Early recognition and prompt treatment are vital to ensure the best possible prognosis [12].

List of abbreviations:

HP- Heterotopic Pancreas

Consent of patient:

Written informed consent was taken from the patient for the purpose of publishing this case

Consent of ethics:

Ethical approval is not required at our institution for publishing a case report in a medical journal

Conflict of Interest:

The authors declare that there was no conflict of interest regarding the publication of this case report

Financial support:

Sources of funding: None

References:

1. Intussusception in infants and adults. *Surg Gynecol Obstet* 1967; 124:99 -105. [PMID 6015799]
2. Pancreas accessorium. *Zeitschrift der Kaiserl. Königl. Gesellschaft der Aerzte zu Wien* 1859; 15:732
3. The clinical significance of heterotopic pancreas in the gastrointestinal tract. *Br J Surg* 1981; 68:384-7. [PMID 7237066]
4. Pancreatic heterotopia. Review of the literature and reports of 41 authenticated surgical cases, of which 25 were clinically significant. *Surg Gynecol Obstet* 1946; 82:527-42.
5. Aberrant pancreas in the gastric wall. *Radiology* 1963; 81:107-11. [PMID 14022897]
6. Monier A, Awad A, Szmigielski W, et al. Heterotopic pancreas: a rare cause of ileo-ileal intussusception. *Pol J Radiol*. 2014;79:349-351. Published 2014 Oct 4. doi:10.12659/PJR.890913
7. 14. Cao L, Wu W, Chen D, Hong J, Wu J, Zheng S. Ileo-ileal intussusception and gastrointestinal bleeding caused by incidental heterotopic pancreas: four case reports. *Ann Transl Med*. 2021;9(3):272. doi:10.21037/atm-20-2294
8. Hamada Y, Yonekura Y, Tanano A, et al. Isolated heterotopic pancreas causing intussusception. *Eur J Pediatr Surg*. 2000;10(3):197-200. doi:10.1055/s-2008-1072357
9. 13. Nagorney DM, Sarr MG, McIlrath DC. Surgical management of intussusception in the adult. *Ann Surg*. 1981;193(2):230-236. doi:10.1097/00000658-198102000-00019
10. Jacobz A, Nawaz A, Matta H, Al Salem A. Intussusception secondary to isolated heterotopic pancreas of the ileum: case report and review of the literature. *Ann Saudi Med*. 2002 May-Jul;22(3-4):213-5. doi: 10.5144/0256-4947.2002.213. [PMID: 17159398]
11. Samiee-Rad, F., Farajee, S. Heterotopic pancreas presentation as a fundal submucosal mass, a case report. *Eur Surg* 52, 43–47 (2020). <https://doi.org/10.1007/s10353-019-00618-y>
12. Tanaka K, Tsunoda T, Eto T, et al. Diagnosis and management of heterotopic pancreas. *International Surgery*. 1993 Jan-Mar;78(1):32-35. PMID: 8473080.

13. Isolated heterotopic pancreas causing intussusception. *Eur J Pediatr Surg* 2000;10:197-200.[PMID 10982052]

14. Nasser HA, Sleiman YA, Hassoun ZA, et al. Bowel obstruction secondary to an ectopic pancreas in the small bowels: About 2 cases. *Int J Surg Case Rep.* 2017;31:72-74.
doi:10.1016/j.ijscr.2017.01.019