

CASE REPORT

Terrible Triad of the Right Elbow Joint: A case report

ABSTRACT

Terrible triad of the elbow joint is a rare condition that usually follows a traumatic episode to the elbow joint. Classically the components of a terrible triad of the elbow involves posterior dislocation of the elbow joint ,coronoid process fracture and a radial head fracture and generally has poor outcomes .

This case report evaluates a 40 year old man who fell with the right arm extended with associated impaction to the right elbow joint. Clinical examination, X-rays and a three dimensional (3D) CT scan confirmed the diagnosis. He was subsequently counseled and worked up for surgery via Open reduction with K-wire fixation.

Key words –Terrible, triad, elbow joint.

1. INTRODUCTION

Terrible triad of the elbow joint usually follows acute traumatic episode and involves posterior elbow dislocation, coronoid process fracture and radial head fracture [1]. The mechanism of this type of elbow injury classically involves the arm extended and in supine position, valgus stress, axial loading to the ulnar joint and posterolateral rotational force impacted into the elbow joint [2]. Injuries to the Medial and Lateral collateral ligament can also occur with the latter being the most common [3]. Due to the complex nature of this injury it predisposes the elbow joint to unstable conditions and therefore surgical intervention has become the mainstay of definite treatment [4].

The surgical approach for the management of terrible triad of the elbow joint is to improve and maintain stability at the humeroulnar and humeroradial components of the elbow joint with the aim of increasing functional outcomes [5]. Unfortunately the complex nature of the injury has poor long term functional outcomes such as joint stiffness, pain, arthritis & recurring elbow dislocation [6]. This case report also reviews the functional outcome of the patient post-operatively following a terrible triad injury to the right elbow joint.

2. CASE PRESENTATION

A 40 year old business man who resides with his family in Ogun state in the south western region of Nigeria presented at the Orthopedic clinic on account of Right Elbow pain of 2 months duration. The event involved him playing football with his kids when he fell and landed on his extended right arm .The pain was sharp and radiated to his right shoulder and forearm and was also associated with progressive swelling with inability to flex and extend the elbow joint. There

was no history of loss of consciousness, nil bleeding from the site of impact. Following the incident he was taken to the closest hospital, had an x-ray done and subsequently managed conservatively with an above elbow back slab. He was discharged home four weeks after the back slab was removed. He returned to the same hospital, however, with complaints of recurrent pains, joint instability, and inability to bend or extend the right elbow joint, and was later referred to the Babcock University Teaching Hospital's (BUTH) orthopedic unit, Ilishan Remo, for professional care.

On examination at BUTH, swelling on the right elbow joint, tenderness on the lateral aspect of the right elbow joint, differential warmth was positive, limitation of joint movement at the elbow joint, there was no sensory deficit, power was 2/5 at the right wrist and radial pulse was palpable. A repeat X-ray and a Three dimensional (3D) CT scan [Figure 1 and 2] respectively was ordered for which confirmed the diagnosis. Following which he was subsequently worked up for surgery.

The lateral Kocher approach was used with the aim of fixing the radial fracture which was noticed to be healing with good callus formation as the patient presented 2 months post injury and the lateral collateral ligament was intact intra-operatively. An anterior medial approach was not made to repair the coronoid fracture as it only involved a small coronoid fragment. The elbow joint was reduced intra-operatively with the use of C-arm guidance as obvious anterior instability was noticed. The right olecranon was fixed by osteosynthesis and the ulnohumeral subluxation was seen and stabilized with Kirschner wire [Fig 3]. The right elbow was placed in an arm sling and after 1 week of hospital care he was discharged home. Four weeks later post operatively the Kirschner wires were removed and he was assessed for range of motion.

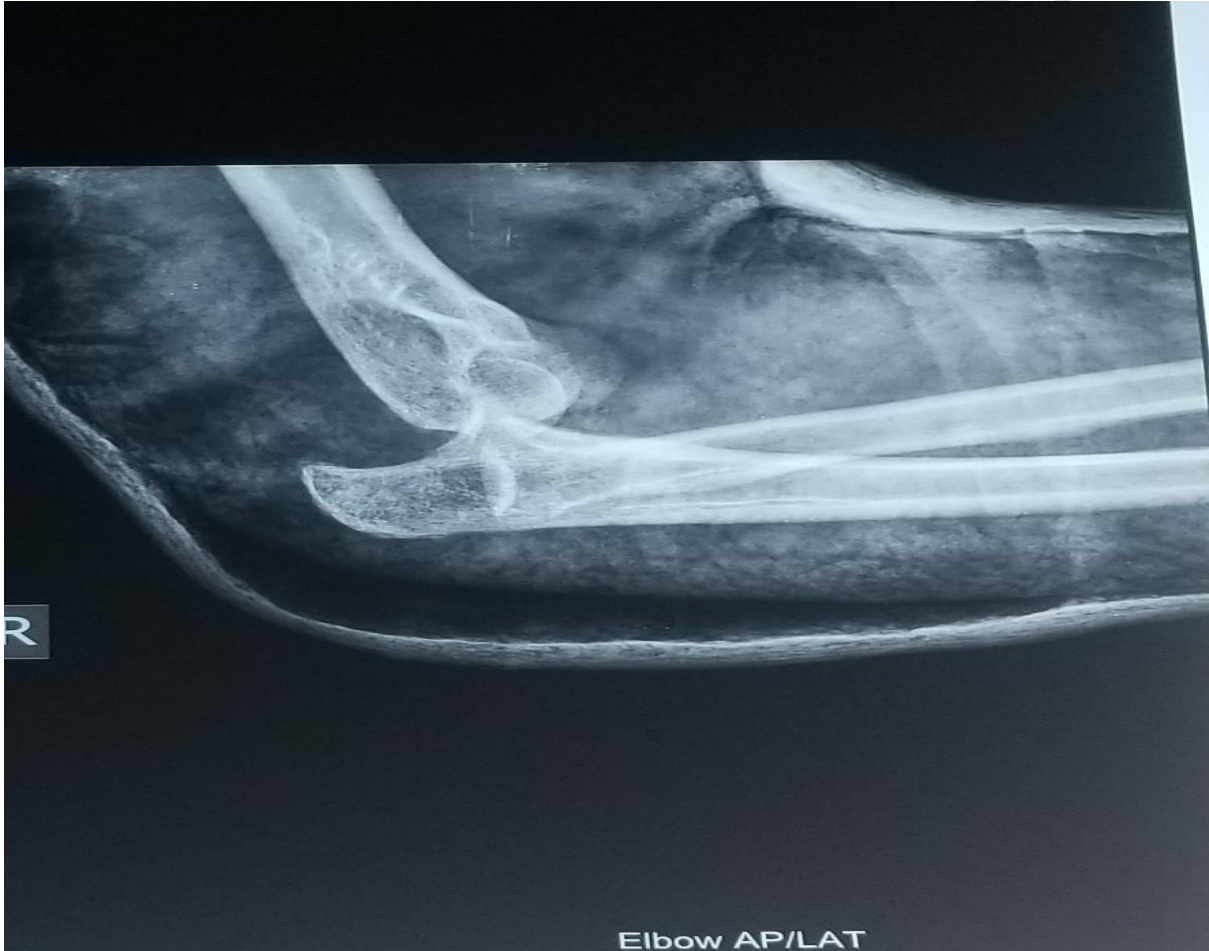

Fig 1: Anterior/Lateral view of the Right Elbow showing the dislocated elbow. The coronoid and olecranon processes are also visible.

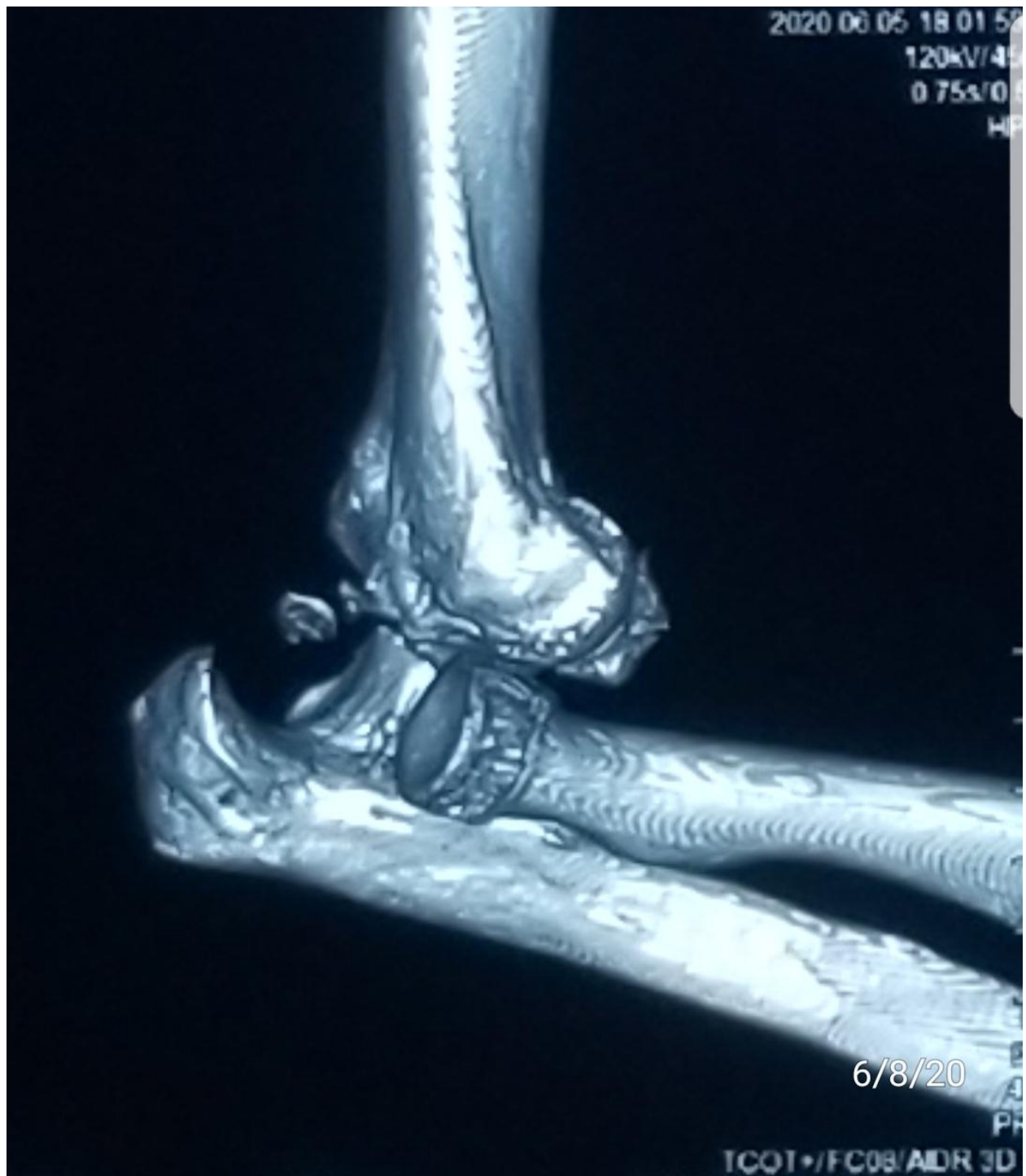

Fig 2. CT scan of Right Elbow showing the dislocated elbow

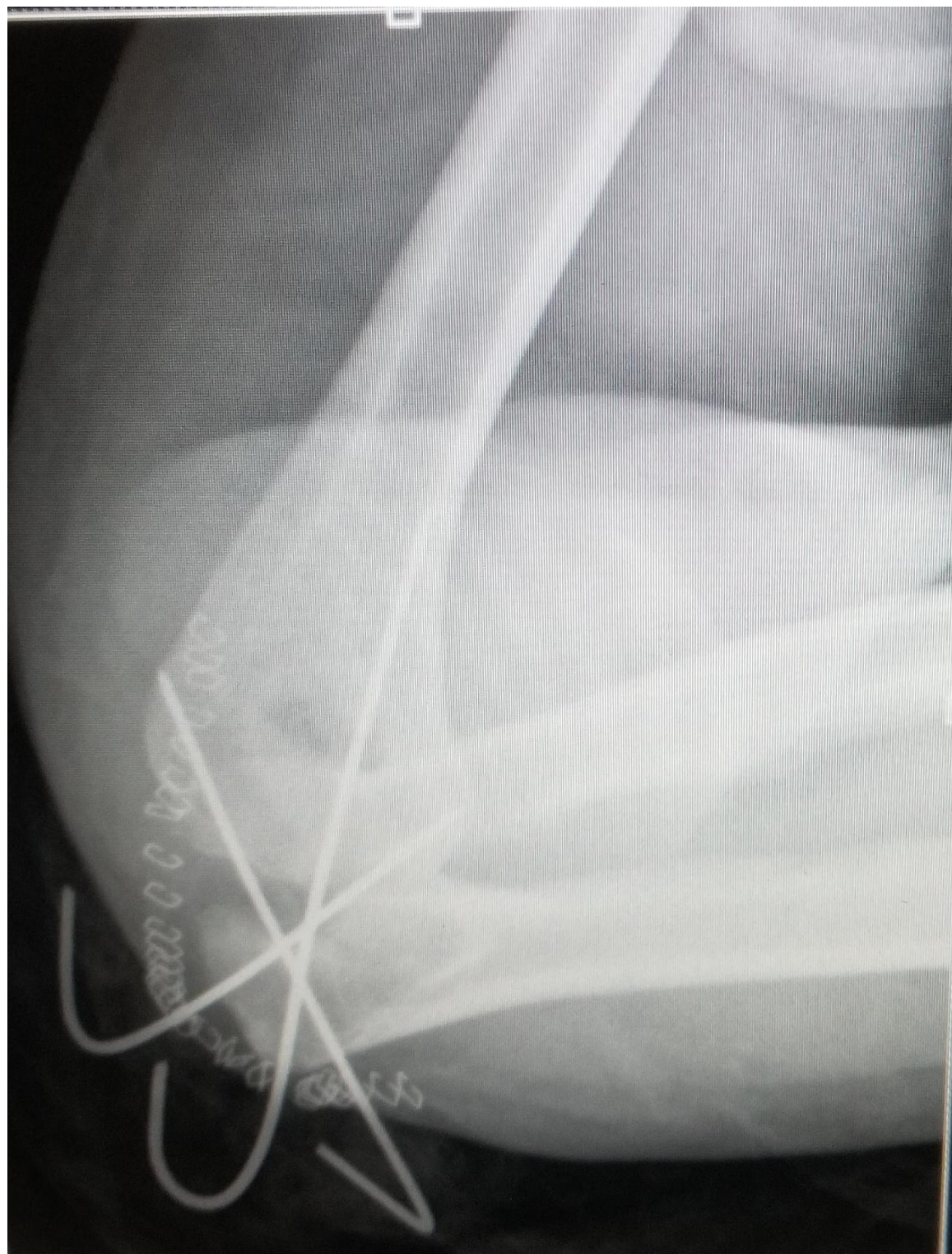


Fig 3: Right Elbow Olecranon fixed with Kirschner wire

3. DISCUSSION

Conservative management with immobilization for terrible triad injuries of the elbow has proved to be inadequate as it only predisposes the elbow to recurrent dislocation [7]. Fractures of the radial head are classified using Mason criteria based on the location of the fracture, degree of displacement and amount of comminution involved [8]. Coronoid process fractures are also classified according to the Regan and Morrey diagnostic criteria. [9], the patient had Mason type-IV and Morrey type -I radial and coronoid fractures respectively. The coronoid process accounts for a greater amount of the elbow joint stability and Morrey type -II and type -III fractures requires resection as they are the most difficult to treat [10]. Terrible triad injuries of the elbow are best managed surgically and involves repair of the coronoid process, radial head and lateral collateral ligament respectively [11]. However, the best approach for the surgical management of this condition remains equivocal [12]. Four weeks Post operatively the function of the elbow was assessed using the mayo elbow performance score [13]. Our patient had a Mayo elbow performance score of 65 at 6 weeks post operatively and could perform regular daily activities.

5. CONCLUSION

Terrible triad injury of the elbow accounts for instability of the elbow joint when it occurs and conservative management as it was initially done for this patient does not favor good prognosis. Regardless of the poor outcomes which is inherent to the injury itself the best form of treatment still remains surgical as it increases joint stability and good functional outcomes.

CONSENT

Informed consent was obtained from all individual participants included in the study.

ETHICAL APPROVAL

This study was conducted under the ethical principles of the Babcock University Research and Ethics Committee.

REFERENCES

1. Hotchkiss RN. Fractures and dislocations of the elbow. In: Rockwood CA, Green DP, Bucholz RW, Heckman JD, editors. Rockwood and Green's fractures in adults. 1, 4th edition. ISBN-10: 0397516029. Philadelphia: Lippincott-Raven; (1996). pp. 929-1024.
2. Mathew PK, Athwal GS, King GJ. Terrible triad injury of the elbow: current concepts. J Am Acad Orthop Surg. (2009); 17(3):137-51.
3. Andrew H, Crenshaw JR. Surgical techniques and approaches. In: Canale ST, Beaty J, editors. Campbell's operative orthopaedics. 12th ed. Philadelphia: Mosby. (2013). p. 106–9
4. Forthman C, Henket M, Ring DC. Elbow dislocation with intra-articular fracture: the results of operative treatment without repair of the medial collateral ligament. J Hand Surg Am. (2007);32(8):1200-9
5. Beingessner DM, Pollock JW, King GJW. Elbow fractures and dislocations. In: Court-Brown CM, Heckman JD, McQueen MM, Ricci W, Tornetta P 3rd, editors. Rockwood and Green's fractures in adults. 8th ed. Philadelphia: Williams & Wilkins; (2015). p. 1214–6.
6. Chemama B, Bonneville N, Peter O, Mansat P, Bonneville P. Terrible triad injury of the elbow: how to improve outcomes?. Orthop Traumatol Surg Res. (2010); 96(2):147-54.

7. Ring D, Jupiter JB, Zilberfarb J. Posterior dislocation of the elbow with fractures of the radial head and coronoid. *J Bone Joint Surg Am* (2002); 84:547–51
8. Mason ML. Some observations on fractures of the head of the radius with a review of one hundred cases. *Br J Surg* (1954); 42:123–32
9. Regan W, Morrey B. Fractures of the coronoid process of the ulna. *J Bone Joint Surg Am* (1989); 71:1348–54
10. Bousselmame N, Boussouga M, Bouabid S, Galuia F, Taobane H, Moulay I. Fractures of the coronoid process [in French]. *Chir Main* (2000);19:286–93.
11. Chen HW, Liu GD, Ou S, et al. Operative treatment of terrible triad of the elbow via posterolateral and anteromedial approaches. *PLoS One* (2015) 10: e0124821.
12. Papatheodorou LK, Rubright JH, Heim KA, et al. Terrible triad injuries of the elbow: does the coronoid always need to be fixed? *Clin Orthop Relat Res* (2014); 472: 2084–2091.
13. Morrey BF, An KN. Functional evaluation of the elbow. In: Morrey BF, editor. *The elbow and its disorders*. 3rd ed. Philadelphia: WB Saunders. (2000). p 82.