

Hemangioma of tongue with abrupt growth onset: A rare case report

Abstract

Hemangiomas of the oral cavity are uncommon but have a predilection for the tongue. Although many lingual hemangomas are superficial, some lesions may involve deep tongue or even the majority of the tongue. They are considered hamartomas rather than true neoplasms. Here we report a case of haemangioma of the anterior 2/3rd of the tongue involving both ventral and dorsal aspects, and ascertaining the diagnostic evaluation and emphasizing the role of color doppler ultrasonography and contrast enhanced magnetic resonance imaging in unrevealing the diagnostic dilemma of the lesion, and further helping in deciding the level of the management. This article presents a relatively rare and unusual case of haemangioma of tongue with abrupt onset of growth.

Introduction

Hemangioma is a common benign vascular neoplasm that closely resembles normal vessels. Oral cavity hemangiomas are relatively rare. Vascular lesions are classified as capillary, cavernous, venous and arteriovenous malformations depending on the predominant anomalous vascular channels.^(1,2) Alternatively malformations can be categorized as either high flow (arteriovenous) or low flow (capillary, cavernous, venous) vascular lesions.⁽³⁾ However low flow lesions can have mixed pathological features and manifest with similar patterns at magnetic resonance imaging, making differentiation impossible.⁽⁴⁾ Magnetic resonance imaging is useful for characterizing and determining the extent of vascular lesions. A combination of conventional MR imaging and Dynamic contrast enhanced MR angiography is especially useful in distinguishing between high- and low-flow lesions.⁽⁵⁾

Case Report

A 62yrs old male presented with swelling in the anterior two-third of the tongue, with stuttering of speech and swallowing difficulty for 25 days. The swelling was incidental in - onset , with rapid progression of growth and was associated with bluish discoloration. The patient had no fever and no pain. There was no personal history of previous diseases. The physical examinations showed no alterations, with all the vitals within the normal limits.

The Local intra-oral examination revealed the diffuse swelling noted involving the anterior 2/3rd aspect of the tongue, the surface appears granular with bluish discoloration and white patchy gelatinous geographical areas noted predominantly in ventral aspect of the tongue. The posterior 1/3rd of the tongue seemed to be healthy with normal morphology. On palpation the swelling was soft in consistency, non-tender, afebrile with no palpable thrills. There was no restriction in the range of movements.

Based on the basis of clinical features and physical examination the clinical diagnosis of hemangioma with differential diagnosis of vascular malformation, angiomyolipoma, angiosarcoma and Kaposi sarcoma were made. (Fig-1)

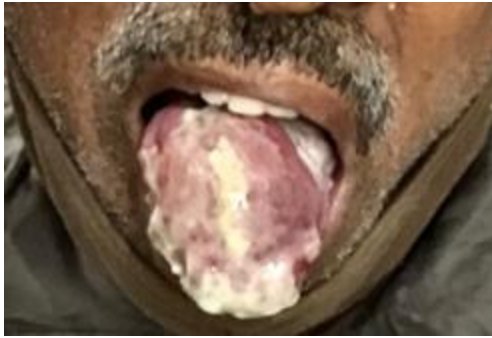

Fig 1: Image depicting the diffusely swollen tongue involving predominantly anterior 2/3rd, with bluish discolouration and gelatinous plaques noted along the ventral aspect.

The baseline routine investigations were normal. color doppler ultrasound revealed heterogeneously hypoechoic lesion involving anterior 2/3rd and extending across full thickness, with markedly increased vascularity showing arterial flow. The diagnosis of haemangioma with differential diagnosis of vascular malformation were taken into account and further contrast enhanced magnetic resonance imaging of neck upto skull base is advised to know the exact extension and involvement of the lesion to decide the level of management.(Fig-2)

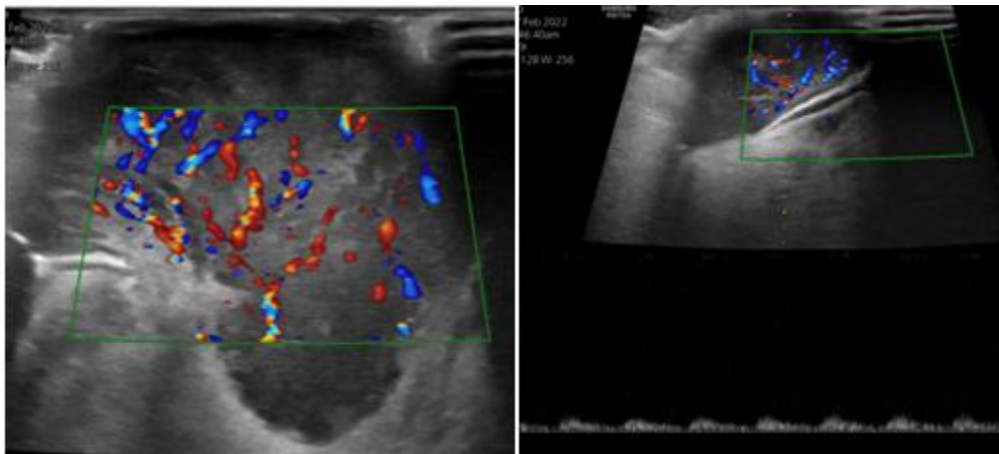


Fig 2 : Color Doppler ultrasonographic image of tongue depicting the heterogeneously hypoechoic intramuscular lesion involving diffusely, with marked increased vascularity and showing arterial biphasic flow.

CEMRI revealed well defined lesion involving anterior 2/3rd of the tongue. The lesion involves intrinsic muscles of the tongue and appears hypointense on T1WI, isointense on T2WI, and shows internal flow voids with avid homogenous post contrast enhancement with maintained fat planes with the surrounding structures. Thus the diagnosis of Haemangioma is

made on the basis of imaging features and further fine needle aspiration cytology confirmed the diagnosis. (Fig-3)

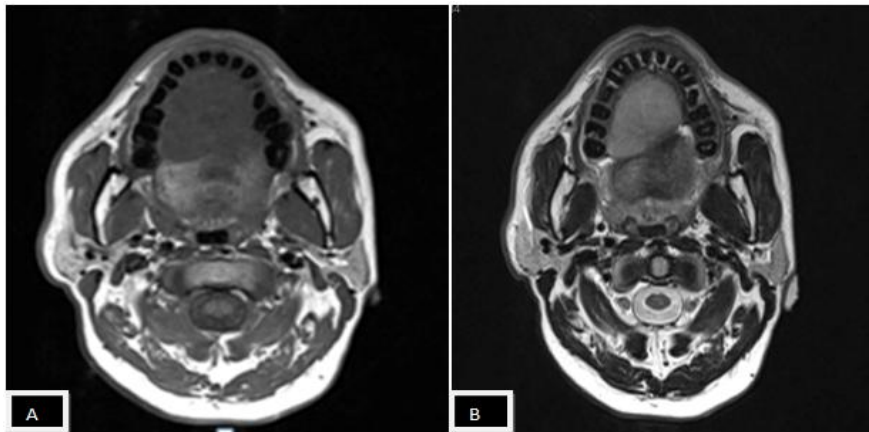


Fig 3a: Image depicting well defined lesion noted involving anterior 2/3rd of the tongue which is hypointense on T₁WI and iso-hyperintense on T₂WI.

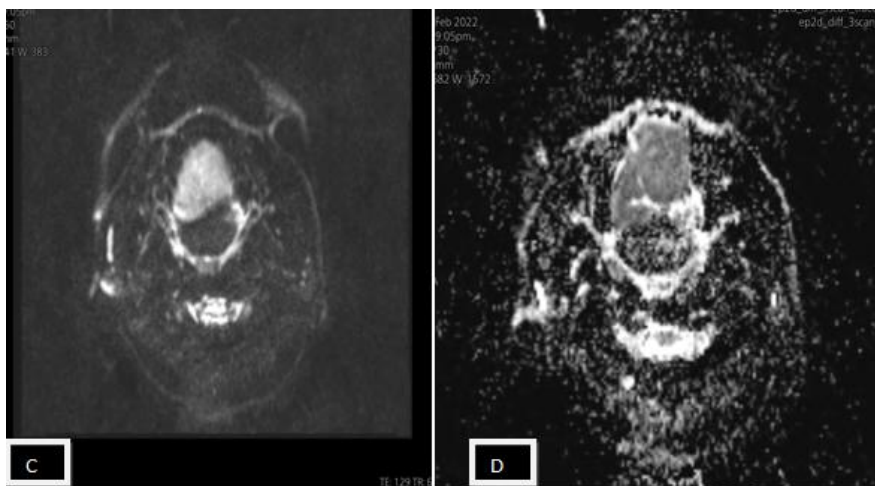


Fig 3b: The image depicting the presence of diffusion restriction in the lesion noted on DWI and ADC images.

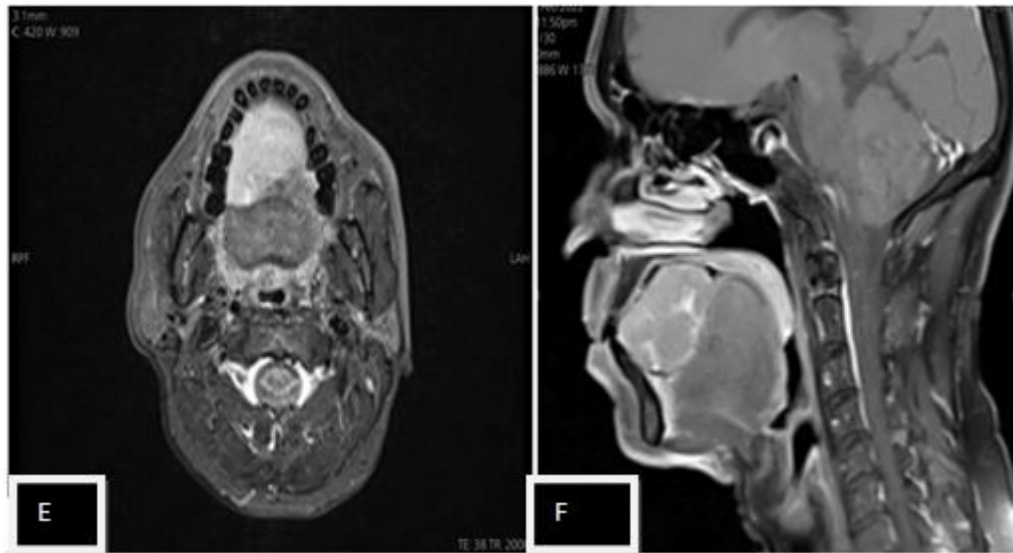


Fig 3c: Axial and sagittal postcontrast images shows the homogeneously avid post contrast enhancement of the lesion involving the anterior 2/3rd of the tongue.

Discussion

Hemangiomas are developmental vascular abnormalities characterized by proliferative growth phase and by very slow inevitable regression (involution phase), and about 60% to 70% of the lesions are found in head and neck region.⁽⁶⁾ The head and neck region is commonly affected especially the face, oral mucosa, lips, tongue and trunk.⁽⁷⁾ Although hemangioma is considered as one of the most common tumors of the head and neck, it is relatively rare in the oral cavity and uncommonly countered by the clinicians. The tongue haemangiomas can produce cosmetic deformity, bleeding, functional difficulties during mastication, deglutition as well as speaking. The main complication of tongue haemangiomas is recurrent haemorrhage.⁽⁸⁾ Imaging resources can be useful in both diagnostic differentiation and analysis of lesion features with regard to its size, extension and location, as well as for follow up of lesions treated under a systemic therapy. The differential diagnosis include lymphangioma, neurofibroma, pyogenic granuloma, chronic gingival hyperplasia, telangiectasia, angiosarcoma, squamous cell carcinoma, and other vascular appearing lesions.⁽⁹⁾ Generally, a biopsy is avoided due to high risk of bleeding. However a biopsy would be recommended if a malignant process is suspected.⁽¹⁰⁾ Management of the hemangioma depends on the variety of factors, and most true hemangioma require no intervention. However, 10-20% requires treatment because of the size, exact location, stages of growth or regeneration. There are many treatment modalities involving wait and watch policy for spontaneous involution, intralesional and systemic corticosteroids treatment, embolization, excision, electrolysis and thermocautery, immunomodulatory therapy with interferon alfa- 2a and laser photocoagulation. Currently, sclerotherapy is employed largely

because of its efficiency and ability to conserve the surrounding tissues. But the risk of thrombosis with embolization does remain.⁽¹¹⁾

Oral haemangiomas has over all favourable prognosis, as these lesions are benign, and only minority (10-20%) will require treatment.

Conclusion

Tongue hemangiomas are rare vascular benign neoplasm characterized frequently by slow and painless growth. The correct diagnosis is of utmost importance for treatment planning. Thus multimodality imaging including Color Doppler ultrasonography, Conventional MR imaging and Dynamic contrast MR angiography plays a pivotal role in unrevealing the diagnosis.

KEY WORDS: CEMRI Contrast enhanced magnetic resonance imaging, AVM Arterio-venous malformation. CD color doppler.

References

1. McCormick WF. The pathology of vascular ("arteriovenous") malformations. J Neurosurg 1966;24:807-816.
2. Weiss SW, Goldblum JR. Benign tumors and tumor-like lesions of blood vessels. In: Weiss SW, Goldblum JR, eds Enzinger and Weiss's soft tissue tumors, 4th edition. St Louis, Mo: Mosby, 2001: 837-890.
3. Donnelly LF, Adams DM, Bisset GS III. Vascular malformations and hemangiomas. AJR Am J Roentgenol 2000; 174:597-608.
4. Cohen JM, Weinreb JC, Redman HC. Arteriovenous malformations of the extremities. Radiology 1986; 158:475-479.
5. Van Rijswijk CS, Van der Linden E, van der Woude H, van Baalen JM, Bloem JL. Value of dynamic contrast MR imaging in diagnosis and classifying peripheral vascular malformations. AJR Am J Roentgenol 2002; 178:1181-1187.
6. Okoji VN, Alonge TO, Olusanya AA. Intra-tumoral ligation and the injection of sclerosant in the treatment of lingual cavernous haemangioma. Niger J Med 2011;20: 172-5.
7. Bonet- Coloma C, Minguez-Martinez I, Palma- Carrio C, Galan-Gil S, Penarroche-Diago M, Minguez-Sanz JM. Clinical Characteristics, treatment and outcomes of 28 oral hemangiomas in pediatric patients. Med Oral Patol Oral Cir Bucal 2011;16:e 19-22.
8. Kamala KA, Ashok L, Sujatha GP. Cavernous haemangioma of the tongue: A rare case report. (2014) contemporary clinical dentistry. 5 (1): 95-8.
9. Dilsiz A, Aydin T, Gursan N, capillary haemangioma as a rare benign tumor of the oral cavity: A case report. Cases J 2009;2:8622.
10. Gianfranco G, Eloisa F, Vito C, Raffaele G, Gianluca T, Umberto R. color- Doppler ultrasound in the diagnosis of vascular anomalies. N Amj Med Sci. 2014 Jan;6 (1):1-5.
11. Nguyen HP, Pickrell BB, Wright TS. Beta-blockers as therapy for infantile haemangiomas. Semin Plast Surg. 2014 May;28(2):87-90.