

# Use of Scheimpflug tomography and OCT tomography to examine corneal dimensional and anterior chamber depth before and after LASIK surgery

## ABSTRACT

**Aims:** To investigate the dimensions of the cornea on: the central thickness of the cornea (CCT), the thickness at the thinnest point of the cornea (TCT), the mean radius of curvature (Rm) and the depth of the anterior chamber (ACD) which are checked preoperatively and six months postoperatively after LASIK surgery.

**Methodology:** Our sample consisted of 40 eyes. Changes in corneal dimensions were monitored before and after LASIK surgery using scheimpflug tomography (Pentacam HR) and optical coherence tomography (OCT). The parameters measured were CCT, TCT, Rm and the ACD. The results between the two techniques were compared with the Bland-Altman method.

**Results:** During the analysis of the results, a statistically significant difference was observed between the two techniques in terms of the preoperative CCT as well as the TCT both preoperatively and postoperatively.

Scheimpflug tomography gives higher values of the CCT than OCT, up to thickness 530nm, while above this it seems that OCT overestimates the thickness of the cornea. Scheimpflug tomography at the TCT seems to give higher values than OCT tomography, up to thickness 520 nm, while above that it seems that OCT tomography overestimates TCT. We have similar results postoperatively for TCT. The two techniques agree on the ACD and the Rm rating.

**Conclusion:** How converging or different the two imaging devices are because it is important for both clinical practice and research may be a point of reference for starting a new research.

*Keywords: Scheimpflug tomography, OCT tomography, devices agreement, LASIK*

## 1. INTRODUCTION

The dimensions of the cornea such as its thickness and volume are very important parameters to prevent serious complications in LASIK surgery. In cases where safety limits are not observed during refractive surgery, the risk of postoperative complications increases due to the fact that, the large degeneration of the cornea affects its industrial stability, which leads to keratectasias. CCT measurements are also important in determining intraocular pressure (IOP) and evaluating corneal endothelial function in order to properly evaluate patients undergoing refractive surgery. Accurate mapping of the parameters of the corneal topography is necessary for the preoperative evaluation and monitoring of the eyes undergoing refractive surgery. Accuracy of corneal parameters is equally important for a possible future LASIK correction, the calculation of intraocular lens power and the early detection of postoperative keratectasia. [1, 2] Several advanced techniques have been developed for the evaluation of the anterior and posterior surface of the cornea such as Scheimpflug and OCT tomography. [3]

Scheimpflug tomography is a modern corneal imaging technology. It uses a rotating camera that focuses all parts of the cornea on one plane, creating a high-definition 3D photo. [4] This technique calculates CCT, TCT, Rm and ACD with great accuracy. It also provides us with reliable results for suspicious curvature points either due to dry eye, or due to subclinical keratoconus or due to corneal imprint from contact lenses. It can therefore provide data on the stability or evolution of any topographic disorder. [5]

On the other hand, OCT tomography is an established medical imaging technique that uses light to image high-resolution three-dimensional structures.

With OCT tomography it is possible to image all the tissues of the eye in real time, without the need for a tissue biopsy. OCT tomography has also been widely used in the evaluation of anterior chamber morphology. Specifically, it has been used during the preoperative examination and the postoperative follow-up of patients who have undergone LASIK for evaluation of the corneal flap. [6]

This study was performed to measure and evaluate the parameters CCT, TCT, Rm and ACD before and six months after LASIK surgery, to correct myopia with Allegretto Wave excimer laser (software version: 2.020/WaveLight AG, Erlangen, Germany), using Scheimpflug tomography and OCT tomography.

Several studies have been published in the literature [7-15] on the subject of evaluating the interchangeability of quantitative imaging of the anterior segment (and in particular, the thickness of the cornea), among the various optical methods. However, as far as we know, the present study is the only one that compares all the above parameters with the use of Scheimpflug tomography and OCT tomography before and after LASIK.

## 2. MATERIAL AND METHODS

The study included 20 young people (40 eyes, 11 men and 9 women, mean age  $(24.05 \pm 0.74)$ ). Patients underwent LASIK refractive surgery.

For the purposes of this work, two devices were used: the Scheimpflug tomography (OCULUS's Pentacam HR, Germany) and the OCT tomography (OCULUS Avanti Angiovue OCT, USA). With the specific devices, the parameters: CCT, TCT, Rm and ACD were measured and compared with each other. The depth of the anterior chamber was measured with both devices from the epithelium to the anterior surface of the lens.

Data collection was performed consistently by the same experienced device operator.

The study is according to the Helsinki Declaration.

### 2.1 Scheimpflug tomography

The Scheimpflug tomography records parts of the cornea and displays them on color maps. It takes about 2 seconds to create the full image of the front half.

In case of eye movement a second camera detects it and corrects it during the procedure.

The topography and thickness of the entire anterior and posterior surface of the cornea are calculated and plotted.

The illumination system of the device consists of a specially designed light source (custom designed blue LED-UV free, 475nm), the eye is scanned 100 times in 2 seconds and during the scan 138,000 points are measured on the surface.

Any measurements that are unreliable due to poor alignment, excessive eye movements, or any incomplete or invalid data were rejected. Scheimpflug tomography was obtained for each patient. A measurement was made for each eye separately before and six months after surgery. The accepted measurements were marked 'OK' in the Scheimpflug tomography.

### 2.2 OCT tomography

OCT tomography was performed for each patient for each eye separately before and six months after surgery. The measurements were made using an external lens for the anterior chamber.

During the imaging, the patient placed his head on the device, then was instructed to look at the internal focusing target.

The scan started when a cross-sectional image of the cornea was displayed focused on a computer screen.

The setting in OCT was at Total Corneal Power and the measurements that were accepted were marked 'GOOD'.

The depth of the anterior chamber was measured by the two devices from the epithelium to the anterior surface of the crystalline lens.

Regarding the LASIK operation, ofloxacin drops were instilled in both eyes, while povidone iodine solution was used for the disinfection of the eyelids and surrounding tissues. Proxymetacaine hydrochloride drops provided the required local anesthesia. Emmetropia was the refractive target in all cases. Alcon/WaveLight® FS200 femtosecond Laser was used for the creation of the flap. The hinge was created at the 12 o'clock position. The Allegretto Wave excimer laser (software version: 2.020/WaveLight AG, Erlangen, Germany) was used for the ablation in. After LASIK, the flap was repositioned with an irrigation cannula and the interface was irrigated. Proper alignment was ensured by gentle handling with a wet microsponge.

The comparison of the two techniques was performed with the Bland-Altman statistical analysis and a statistically significant difference was considered for  $p < 0.05$ .

### 3. RESULTS AND DISCUSSION

Detailed demographic parameters are presented in Table 1.

**Table 1. Patient Demographics**

Gender	Participants	Mean age $\pm$ standard deviation
Male	11	24,05 $\pm$ 0,7
Female	9	24,05 $\pm$ 0,7

Regarding the preoperative and postoperative comparisons for both devices, significant differences were detected in the majority of the measured parameters Table 2.

**Table 2. Preoperative and postoperative comparison of the parameters of the two devices**

	PRE-OP		POST-OP		P-value
	MEAN	SD	MEAN	SD	
PENTACA					
M HR					
ACD	3,29	0,27	3,22	0,26	0,002
CCT	534,25	24,6	455,07	35,27	<0.0001
TCT	529,75	25,93	451,01	35,35	<0.0001
RM	7,76	0,26	8,53	0,61	<0.0001
OCT					
ACD	3,25	0,26	3,19	0,25	<0.0001
CCT	522,73	33,48	452,38	43,65	<0.0001
TCT	518,63	29,96	440,53	40,67	<0.0001
RM	7,76	0,25	8,52	0,59	<0.0001

\*ACD: anterior chamber depth, CCT: central corneal thickness, Rm: Medium cornea radius, SD: standard deviation, TCT: thin central thickness

The comparison of the two devices preoperatively and postoperatively is shown in Table 3.

**Table 3. Preoperative and postoperative comparison of the mean difference of the parameters of the two devices**

Preoperative	Mean	p-value
DACD	0,035	0,10
DCCT	12	<b>0,01</b>

DTCT	11	<b>0,01</b>
DRM	-2,43E-14	1

Postoperative		
DACD	0,0323	0,182
DCCT	3	0,6
DTCT	10	<b>0,01</b>
DRM	0,00425	0.39

\*DACD : Differences of anterior chamber depth between pentacam HR and OCT, DCCT: Differences of central corneal power between pentacam HR and OCT, DRM: Differences of mean radius of the cornea between pentacam HR and OCT, DTCT: Differences of thinnest central thickness depth between pentacam HR and OCT

Preoperatively, a statistically significant difference was observed between two devices in CCT and TCT, while six months postoperatively, a statistically significant difference was observed only in TCT. No statistically significant difference was observed for the other parameters. Our results were confirmed by the Bland-Altman analysis (Fig. 1, Fig. 2, Fig. 3)

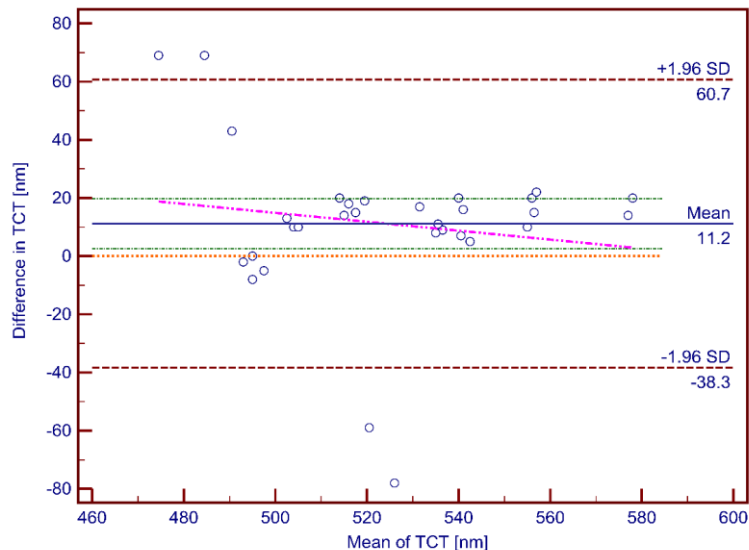
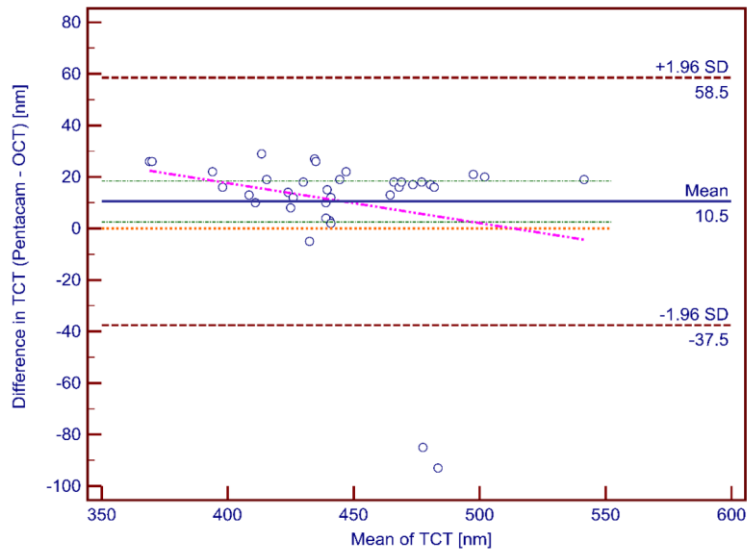
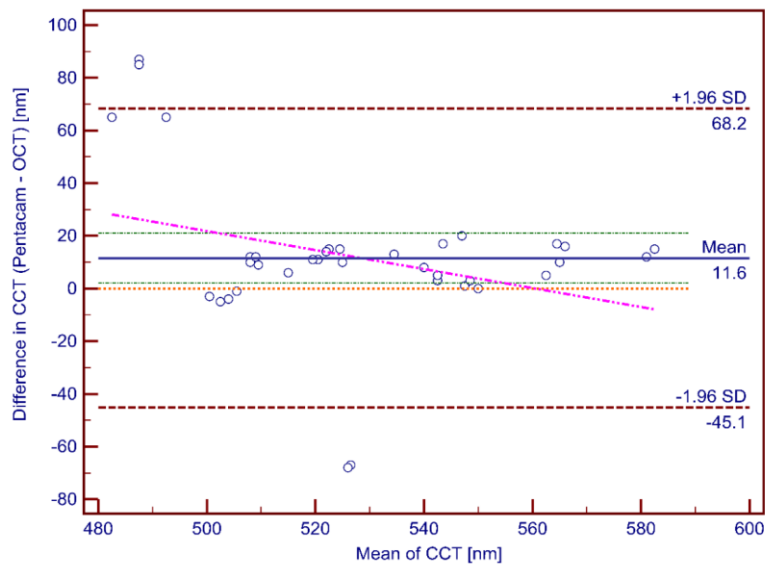


Fig. 1. Bland-Altman plot of TCT (preoperative)

**Comment [A1]:** What is being subtracted from what in figure 1



**Fig. 2. Bland-Altman plot of TCT (postoperative)**



**Fig. 3. Bland-Altman plot of CCT (preoperative)**

More specifically, as far as CCT, Scheimpflug tomography seems to give higher values preoperatively up to a corneal thickness of about 530 $\mu$ m, while above that it seems that OCT tomography overestimates CCT. Scheimpflug tomography seems to give higher values in TCT preoperatively than OCT tomography, up to a certain thickness (about 520nm), while above that it seems that OCT tomography overestimates TCT. Also the Scheimpflug tomography seems to give higher values to the TCT postoperatively than the OCT tomography, up to a certain thickness (about 450nm), while above that it seems that the OCT tomography overestimates the TCT.

It is noteworthy that the two devices agree on the ACD rating and the Rm rating.

#### 4. CONCLUSION

Despite the differences in the results recorded by the two techniques, both techniques should be considered when used to measure corneal thickness in preoperative screening, as not taking them into account may affect surgical planning.

How converging or different the two imaging devices are because it is important for both clinical practice and research may be a point of reference for starting a new research. Certainly further studies should be done with a larger sample.

Comment [A2]: This phrase is not clear

A limitation of this study was the application of statistical analysis in both eyes of some cases. The inclusion of bilateral cases was performed in order to increase the power of the study and to reduce the number of subjects that had to be recruited. The optimal way to address this issue is to use only one eye from each patient or to use advanced statistical analysis. However, this has not always been the case in all publications. Nevertheless previous studies published in the literature of LASIK patients, it was found that correlations were low in eyes having undergone refractive surgery, and that results were similar when using one or both eyes of the patients[16]. Another limitation is the small sample size.

#### CONSENT

All authors declare that written informed consent was obtained from the patient. A copy of the written consent is available for review by the Editorial office/Chief Editor/Editorial Board members of this journal.

#### ETHICAL APPROVAL

The study is according to the Helsinki Declaration.

#### REFERENCES

1. Byeong SK, Jeong MH, Joo YO, Mee KK, Won RW., Intraocular Lens Power Calculation after Refractive Surgery: A Comparative Analysis of Accuracy and Predictability. Korean J Ophthalmol. 2017 Dec; 31(6): 479–488. doi: 10.3341/kjo.2016.0078
2. Sorkin N., Kaiserman I, Domniz Y, Sela T, Munzer G, Varssano D. Risk Assessment for Corneal Ectasia following Photorefractive Keratectomy. Journal of Ophthalmology.2017. Volume 2017.Article ID 2434830. <https://doi.org/10.1155/2017/2434830>
3. Rio-Cristobal A, Martin R., Corneal assessment technologies: current status. Surv Ophthalmol. Nov-Dec 2014;59(6):599-614. doi: 10.1016/j.survophthal.2014.05.001.
4. Hashemi H. and Mehravaran S. Day to Day Clinically Relevant Corneal Elevation, Thickness, and Curvature Parameters Using the Orbscan II Scanning Slit Topographer and the Pentacam Scheimpflug Imaging Device. Middle East Afr J Ophthalmol. 2010 Jan-Mar; 17(1): 44–55. doi: 10.4103/0974-9233.61216.
5. Muñoz G., Albarrán-Diego C, Ferrer-Blasco T, García-Lázaro S, Cerviño-Expósito A., Long term comparison of corneal aberration changes after laser in situ keratomileusis: mechanical microkeratome versus femtosecond laser flap creation. J Cataract Refract Surg 2010;36:1934-44. doi: 10.1016/j.jcrs.2010.06.062.
6. Ventura BV, Moraes HV Jr., Newton K.-Junior, Santhiago MR., Role of Optical Coherence Tomography on Corneal Surface Laser Ablation, J Ophthalmol. 2012;2012:676740.doi: 10.1155/2012/676740.
7. Nolan W. Anterior segment imaging: ultrasound biomicroscopy and anterior segment optical coherence tomography. Curr Opin Ophthalmol.2008 Mar;19(2):115-21. doi:10.1097/ICU.0b013e3282f40bba.
8. Bechmann M , Thiel MJ, Neubauer AS, Ullrich S, Ludwig K, Kenyon KR et al., Central corneal thickness measurements with a retinal optical coherence tomography device versus standard ultrasonic pachymetry. Cornea. 2001 Jan;20(1):50-4.doi: 10.1097/00003226-200101000-00010.
9. Paul T, Lim M, Starr CE, Lloyd HO, Coleman DJ, Silverman RH., Central corneal thickness measured by the Orbscan II system, contact ultrasound pachymetry, and the Artemis 2 system. J Cataract Refract Surg. 2008 Nov;34(11):1906-12. doi: 10.1016/j.jcrs.2008.07.013.
10. Nam SM, Im CY, Lee HK, Kim EK, Kim Ti, Seo KY., Accuracy of RTVue optical coherence tomography, Pentacam, and ultrasonic pachymetry for the measurement of central corneal thickness. Ophthalmology. 2010 Nov;117(11):2096-103. doi: 10.1016/j.opht.2010.03.002.
11. Chen S, Huang J, Wen D, Chen W, Huang D, Wang Q., Measurement of central corneal thickness by high-resolution Scheimpflug imaging, Fourier-domain optical coherence tomography and ultrasound pachymetry. Acta Ophthalmol. 2012 Aug;90(5):449-55.doi: 10.1111/j.1755-3768.2010.01947.x.

12. Ishibazawa A, Igarashi S, Hanada K, Nagaoka T, Ishiko S, Ito H. et al., Central corneal thickness measurements with Fourier-domain optical coherence tomography versus ultrasonic pachymetry and rotating Scheimpflug camera. *Cornea*. 2011 Jun;30(6):615-9. doi: 10.1097/ICO.0b013e3181d00800.
13. Li H., Christopher Kai Shun Leung, Wong L, Lui Cheung CY, Pang CP, Weinreb RN. et al., Comparative study of central corneal thickness measurement with slit-lamp optical coherence tomography and Visante optical coherence tomography. *Ophthalmology*. 2008 May;115(5):796-801.e2. doi: 10.1016/j.ophtha.2007.07.006.
14. Amano S, Honda N, Amano Y, Yamagami S, Miyai T, Samejima T. et. al., Comparison of central corneal thickness measurements by rotating Scheimpflug camera, ultrasonic pachymetry, and scanning-slit corneal topography. *Ophthalmology*. 2006 Jun;113(6):937-41. doi: 10.1016/j.ophtha.2006.01.063.
15. Huang J, Pesudovs K, Yu A, Wright T, Wen D, Ming L. et al., A comprehensive comparison of central corneal thickness measurement. *Optom Vis Sci*. 2011 Aug;88(8):940-9. doi: 10.1097/OPX.0b013e31821ffe2c.
16. Gialelis TK, Kozobolis VP, Sideroudi H, Portaliou DM, Mouzaka AE, Stavrakas P, Mikropoulos D. et al., Contrast Sensitivity and Corneal Aberrations Analysis in Relation with Epithelial Thickness Changes at the Corneal Apex after Refractive Surgery. *J Surg* 6: 1437. DOI: 10.29011/2575-9760.001437