

CHORIOCARCINOMA: A REVIEW

Abstract:

Here in his article, we will come to know about choriocarcinoma which is a highly malignant tumor arising from chorionic epithelium. Among 3-5% of all patients with molar pregnancies develop choriocarcinoma. All the types of choriocarcinomas and their defining features are discussed below ~~in a view to you to for a better~~ understanding ~~of better~~ the basic pathogenesis, histology, and etiological factors involved. Patient may present with persistent ill health, irregular vaginal bleeding, continued amenorrhea, and when it is metastasized it forms lesions which presents in lung as cough, breathlessness, hemoptysis whereas in vagina as irregular and at times as brisk hemorrhage. It can also have lesions in cerebral region presenting as headache, convulsions, and paralysis. Signs include pallor of varying degree and ~~in all~~ the patient generally looks ill. Various investigations that are necessary to identify this disease are chest x-ray, pelvic sonography, diagnostic uterine curettage etc. ~~also Furthermore~~, excisional biopsy, the ratio of ~~hcg-hCG~~ levels, and CT scan, ~~ultrasonography, chest X ray~~ can also be done. There is also a staging we have talked about in the coming article ~~that is applicable~~ for gestational trophoblastic tumors. Management of the same has also been discussed below in view to treat the disease better and cure hefty number of patients. It can be preventive as well as curative. Here we have talked about treatment modality for low risk as well as high risk patients. ~~Also We have also discussed to add the additional~~ treatment for those who are resistant to the drugs used for low risk and high risk patients. Finally prophylactic chemotherapy and follow ups are given.

Keywords: Choriocarcinoma, Malignant, Management, Chorionic Epithelium.

Comment [D1]: Repeated investigations.

Introduction**CHORIOCARCINOMA**

Due to its rarity, ~~t~~The very first human tumour to be monitored by a tumour marker and curable by chemotherapy, choriocarcinoma (CH), raises a diagnostic challenge, ~~and~~ malignancy trying to define requirements in other malignancies, such as vessel intrusion, pleomorphism, mitoses, and even metastatic, are innate features of the standard, trophoblast. It is necessary to have a

clinicopathological relationship Finding abundant pleomorphic trophoblast after a typical full pregnancy usually always implies CH or a new pregnancy, whereas finding abundant pleomorphic trophoblast after a complete mole (CM) often indicates mole resolution with no chorionic Villi in the sample.

Comment [D2]: Please modify into more meaningful sentences.

It has a proclivity for vascular attack or ~~metastases~~ vascular metastases; however it is only treatable in most situations if it can be removed surgically. ~~CH and PSTT have nothing in common and perform in different ways, yet they can sometimes merge into one another.~~ The major analytic challenges include: first, distinguishing CH and PSTT from plentiful trophoblast, which is commonly seen near the beginning of pregnancy; second, distinguishing CH and PSTT from constant trophoblast; third, distinguishing CH with a mainly cytotrophoblastic constituent from PSTT. Because of its scarcity and the fact that criteria used to describe malignancy in other neoplasms, such as vessel attack, cellular pleomorphism, mitoses, and even metastases, are essential features of standard trophoblast, the difference between CH, PSTT, and trophoblastic metaplasia in non-gestational carcinoma tumour marker and cured by chemotherapy, presents unique investigative problems- (1). Because choriocarcinoma is a type of cancer, we must first understand ~~To understand~~ what gestational trophoblastic diseases (GTD) are; ~~we must first understand what they are~~ GTD are a different set of pregnancy-related evolutions. There are two types of GTD: benign and malignant. ~~Choriocarcinoma and hydatiform mole are the most common types, while ETT and PSTT are uncommon-~~ (2).

Comment [D3]: Please use full-forms when the abbreviations are used for the first time in the article.

Comment [D4]: Please reconstruct this part with simple meaningful sentences. Using too many information in a single sentence is not advisable, instead please break the sentences into simple ones.

Comment [D5]: Please mention full forms.

~~TROPHBLASTIC~~ TROPHOBLASTIC DISEASE AFTER A STANDARD ~~PEGNANCY~~ PREGNANCY IS EITHER CHORIOCARCINOMA OR PSTT, AND NOT A BENIGN ~~-OR~~ INVASIVE MOLE.

There can be benign ~~TBD~~ trophoblastic disease comprising of ~~-partial~~ hydatiform moles and complete hydatiform moles, or malignant ~~ones likehaving choriocarcinoma-choriocarcinoma,~~ hydatiform mole, ETT, and PSTT.

Angiogenic growth factors are abundant in choriocarcinomas. ~~The most common clinical signs include~~ cough ~~-cough,~~ irregular vaginal bleeding, enlarged uterus ~~uterus,~~ hemoptysis, headache and ~~vomiting~~ Alsovomiting. Also ~~There is a link between intraperitoneal haemorrhage and elevated hCG levels in the blood.~~ The important features of choriocarcinoma are:

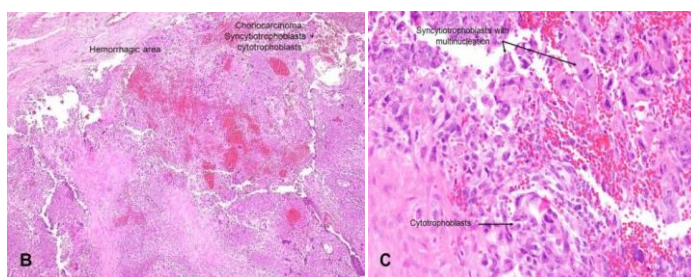
- It's really uncommon
- Symptoms may be present as a result of hematogenously spread metastatic lesions
- Significant increase in hCG levels in the blood
- Gross: a hemorrhagic nodule within the testicular parenchyma; if the tumour has regressed, it may merely be a remnant scarring focus

Comment [D6]: ? please confirm. References may be used.

ETIOLOGY: Choriocarcinoma is a cancer that develops when an aberrant trophoblastic population undergoes hyperplasia and anaplasia. ~~There are two types of choriocarcinoma: gestational choriocarcinoma and non-gestational choriocarcinoma-~~ (3).

PATHOPHYSIOLOGY- Although the exact pathophysiology of choriocarcinoma is unknown, investigations have demonstrated that cytotrophoblasts behave as stem cells and can convert into cancerous cells. Intermediate trophoblasts and syncytiotrophoblasts develop from the neoplastic cytotrophoblast. The cell combination closely matches that of a pre-villous blastocyst in development. In choriocarcinoma, upregulation of p53 and Transcription factors has been observed without the evidence of genetic change. Hypermethylation-induced upregulation or downregulation has indeed been related to the genes NECC1, related to vascular endothelial growth factor receptors. HLA-G is found in significant amounts in choriocarcinoma and is thought to alter the tumour microenvironment by inactivating the local immune system- (4).

Fig 1: HISTOPATHOLOGY-



- **Choriocarcinoma (classic)**

- o Cytotrophoblasts and syncytiotrophoblasts mixed together (picture B) & (image C)

Syncytiotrophoblasts develop a villous structure by wrapping or capping mononuclear cytotrophoblastic cells

- o Almost always linked to haemorrhages (do a search in this area)

Monophasic choriocarcinoma is a type of choriocarcinoma that has only one phase. Squamous-like characteristics; very infrequent, usually in metastatic areas

- trophoblastic tumour of the placenta

Very uncommon, made up of intermediated trophoblasts

(5)

Comment [D7]: Please construct meaningful sentences for better understanding.

Naked eye appearance: The lesion is of the nodular kind with a standard localization. the endometrium in its entirety The nodular kind can be found deep into the myometrium, with the endometrium above it intact. On uterine curettage, this frequently results in a false-negative diagnosis

Bilateral lutein cysts are found in about 30% of women with ovarian hypertrophy. These are caused by an overabundance of chorionic gonadotropin.

Aside from local spread, vascular degradation occurs early, allowing distant metastasis to occur quickly

CLINICAL FEATURES:-

A) Symptoms :- :Swelling in ~~stomach area~~ abdomen

: Bleeding per vaginum

: Infections causing vaginal discharge, pelvic

Cramps and ~~and~~ fever

: Amenorrhea

: Hyperemesis Gravidarum

: Abdominal mass

: Features of Hypothyroidism

: Respiratory symptoms

B) Signs :- : Ill looking patient

: Features of Shock, Pallor

: Features of thyrotoxicosis, enlarged thyroid

Gland

: Absent fetal heart sound

: Pelvic findings-

: Metastatic lesions

: Vesicles and bleedings seen

: Absent internal ballotement

: Palpable unilateral or

bilateral enlargement of ovary

Choriocarcinoma can ~~metastasize to~~metastasize to other organs especially lungs which can show these signs :-

: Dry cough

: Coughing of blood

: Chest pain

: Breathing difficulties

Standardized guidelines for the diagnosing ~~postmolar~~post molar GTN have been developed ~~created on as per~~ the recommendations of Braga et al;

I Choriocarcinoma histology

Human

chorionic gonadotropin (hCG) ~~persistence—molar~~persistence in molar pregnancy even after 6 months

II After about 21 days, various human chorionic gonadotropin levels reached a plateau

III After 14 days, human chorionic gonadotropin levels increased by 10% or higher for at least three values

Malignant trophoblastic cancer of the choriocarcinoma is the most common GTN discovered during microscopic histological analysis, and it is most commonly caused by Term births or sudden termination Choriocarcinoma, whereas on this side, is a type of lung cancer Choriocarcinoma, on the other hand, may present with no specific symptoms or signs, making an accurate diagnosis difficult and causing a delay in detection.— As a result, Gestational Trophoblastic Neoplasia should be carefully evaluated, and a ~~hcg~~hCG assessment must be undertaken by all the females during their reproductively active years, particularly those who have irregular uterine haemorrhage or other unexplained metastasized disease (6).

Comment [D8]: Full form

Comment [D9]: Rephrase into meaningful sentence

GTN risk Evaluation and Staging

Investigations : Pelvic assessment for lumps ~~or—unstandardized~~or unstandardized changes

: Test to check hCG levels

: Blood and Urine tests

~~Tests; Tests~~ to see if cancer is spreading to other body

: ~~Imaging's~~Imaging such as MRI, Ultrasound or x –ray

: CXR to exclude lung diseases

Comment [D10]: Full form

: Other supportive investigation

- CBC
- Blood group and Rh typing
- PIH investigations
- TSH levels

Comment [D11]: Full form

If we discuss about GTD ~~in as a~~ whole, this is the way management would ~~be proceeded~~ proceed.

Following a molar pregnancy, the majority of neoplasia are diagnoses ~~diagnosed~~ ~~dome~~ by continuous increase in hCG levels. While the symptoms of choriocarcinoma can be fairly variable, approximately 33% of these patients present with symptoms associated to distant tumours. However, responsible clinicians should look at malignant GTN in practically all patients with a metastatic tumour who are of reproductive age, because modest hCG test in serum or urine could save their lives. A medical ~~past~~ history, clinical evaluation, serum or urine hCG testing, chest radiograph, ultrasonography, ~~usg~~, and pelvic Doppler ~~usg~~ ultrasonography are all required for patients suspected with post-molar GTN. The repetitive ~~skimming~~ of the chest with CT cannot be employed for curative care of GTN patients. Ultrasonography and pelvic colour Doppler imaging are imaging procedures that can be used not only for general diagnosis but also in cases of prolonged GTN or molar pregnancy. Both the pulsatility index and the capacity of the uterus may provide self-governing medical prognostic data that can reveal methotrexate resistance mechanisms in malignancies.

Comment [D12]: Please use reference for statistical information

Comment [D13]: Rephrase or paraphrase this sentence

Comment [D14]: Rephrase or paraphrase this sentence

Comment [D15]: Please add reference

MRI- abdomen, brain, and pelvis, and also chest CT, are frequently employed in patients with drugs which are resistant or with recurrent disease. Furthermore, precise tumour localization may help to determine whether therapeutic excision is an option. However, using the FDG-PET imaging to locate relapsed or residual disease would be beneficial. MRI and CT scans may be used to assess the levels of human chorionic gonadotropin in cerebrospinal fluid in order to detect occult illnesses in the CNS (7)

STAGING-

The following choriocarcinoma staging system was devised by the WHO and the international federation of Gynecology and Obstetrics:

- Stage I: Disease limited to the uterus
- Stage II: Disease that extends beyond the uterus but is limited to genital structures
- Stage III: Disease that extends to the lungs
- Stage IV: The cancer has spread to other metastatic locations

Criteria--

Modified WHO Prognostic Scoring System as Adapted by FIGOb

Scores	0	1	2	4
Age	<40	≥40	–	–
Antecedent pregnancy	mole	abortion	Term	–
Interval months from index pregnancy	<4	4–6	7–12	>12
Pretreatment serum hCG (iu/l)	<103	103–104	104–105	>105
Largest tumor size (including uterus)	<3	3–4 cm	≥5 cm	–
Site of metastases	lung	spleen, kidney	gastrointestinal	liver, brain
Number of metastases	–	1–4	5–8	>8
Previous failed chemotherapy	–	–	single drug	≥2 drugs

GTN FIGO staging:

Stage Description

I GTDs are limited to the corpus of the uterus only

II GTDs can spread to the adnexa or vaginal region, but they are still restricted to the genital tissues

III GTDs that form in the lungs may affect the vaginal tract

IV The rest of the metastatic locations (8)

(6) Treatment-

Formatted: Font: Bold, Underline

Formatted: Font: Not Bold

Standard treatment options

Based on the kind and stage of the disease, conventional treatment options for GTD comprise chemotherapy, D&C, removal of uterus or with a combo of both. In generally, Dialation and curettage is used to save fertility and rule out molar pregnancy from the picture; although, to assure that the problem does not recur, rigorous post-treatment monitoring is required. When fertility retention is not a concern and there are no distant metastases, hysterectomy is a more typical therapy for more serious and especially notable cancers. Chemotherapy, whether as a solo or combined treatment, is successful for some types of GTD; however, it is not effective for a variety of diseases.

Comment [D16]: Full forms

Comment [D17]: Please add references regularly, ideally in every paragraphs

Low-risk GTN

Low and ~~high-risk~~ high-risk GTN illness can be classified based on the severity of the condition. In recent years, the treatment for low-risk GTN has remained relatively ~~unchanged~~ unchanged. ~~Dactinomycin~~ Dactinomycin and amethopterin are the most often used treatments for this group of illnesses. With or without the release of leucovorin, amethopterin is safe and has fewer negative ~~things~~ aspects. When the ~~human chorionic gonadotropin serum hormones~~ serum hCG levels have been ~~standardised~~ standardized, the amethopterin therapy would be carried out within consolidated treatment systems that might be effectively abided without causing side effects like spot baldness (9).

Other, less possible side effects include epithelial membrane irritation and alterations in renal and liver functions. Another unusual side effect is myelosuppression, which is the inhibition of the marrow. Dactinomycin is best administered as a daily intravenous infusion with a dosage of 0.5 mg. Dactinomycin has a greater short-term hazards than amethopterin. However, ~~dactinomycin's~~ the most prevalent side effects of Dactinomycin are myelosuppression and stomach ulcers.

Comment [D18]: Confirm proper dosage

However, myelosuppression, nausea, hair loss, and severe mucositis are some of the more typical side effects of dactinomycin. Dactinomycin, unlike amethopterin, does not have any possible long-term side effects (10).

Low risk persistent GTN

A rise in serum hormone of ~~hcg~~ hCG in far more than three successive values is the most sensitive sign of vulnerability to amethopterin in malignancy. The level of serum human chorionic hcg hormone where the prolonged condition develops, on the other hand, may aid in the choosing of rescuing treatment. Patients received treatment that contained amethopterin, etopophos, and dactinomycin if dactinomycin treatments fail or if they advanced amethopterin resistance with an hCG hormone level and done 100 IU/l. While individuals who are resistant to

Comment [D19]: Rephrase/paraphrase this part for better understanding

amethopterin may be managed regardless of level of resistance in some cases, this is not always the case. While patients who are immune to amethopterin may be handled deprived of regard for their hCG levels by merging chemotherapy with etopophos, amethopterin, and dactinomycin, in some situations, patients who are resilient with amethopterin may be handled without regard for their hCG levels by merging chemotherapy with etopophos and amethopterin, and dactinomycin (11)

Comment [D20]: Rephrase/paraphrase this part for better understanding

Despite the reality that these treatment plans may certify a faster treatment, ~~a huge patients~~ a huge number of patients will be exposed to more harmful medications, increasing the chance of cancer recurrence. In this case, the human chorionic gonadotropin threshold values for dactinomycin therapy in amethopterin-resistant patients can be augmented from 100 to 300 IU/l. Pulsed dactinomycin, on the other extreme, could be ~~utilised~~ utilized as a last-resort treatment for GTN patients who haven't progressed to amethopterin. Combined chemotherapy, on the other hand, has the potential to heal almost all patients at a faster rate (12)

High-risk GTN

Table 1: Treatment schedule		
Week one		Week two
Day one	Day two	Day one
I: Dactinomycin 0.5 mg iv bolus injection II: Etopophos 100 mg/m ² intravenous during half hour III: Amethopterin 300 mg/m ² intravenous during 12 h	I: Dactinomycin 0.5 mg intravenous bolus injection II: Etopophos 100 mg/m ² intravenous during half hour III: Oral leucovorin 15 mg for 12 hours over 2 days and 24 hours after amethopterin start	I: Leurocristine 1.4 mg per m ² iv bolus injection II: cytophosphane 600 mg per m ² iv during half hour

The probability of healing with this kind of regimen, as per reports, is around 90%. Etopophos, amethopterin, and dactinomycin have been used in the therapy, which was combined with vincristine. Cytophosphane is much more dangerous, causing reversible hair loss, bone marrow reduction, and severe mucous membrane infection in the ~~short-short-term~~ short-term. Nerve ~~damage~~

damaging disease ~~was~~ has been caused by their ~~o~~cristine. Moreover, the use of etopophos medicines opens up the risk of a small second tumour.

A fully functional chemotherapeutic agent ~~Medicines~~ like amethopterin, etopophos, and dactinomycin can be used to provide the best possible treatment for patients with greater GTN risks, which would have been effective in around 70% of cases. On the other side, each particular regimen is useful with treatment of both high and low risk GTN disorders appointment as remajors (13)

Comment [D21]: Rephrase or paraphrase this sentence

Management of Resistant GTN Patients

Among the most serious problems in GTN patients who are resistive to therapy is their ability to be cured even after routine care has failed. This objective could be achieved by removing resistant disease with a mixture of chemotherapy and surgery. The surgical procedure of hysterectomy is advised as a first approach when the remaining sickness site can indeed be detected using functional and anatomical imaging techniques

With the therapeutic adjuvant therapy of 2 types of etopophos, this regimen is by far the most suited, with the best recovery rate in comparison. Paclitaxel, alone and in combination with cisplatin, may, on either hand, be beneficial in resistant GTN patients. Moreover, although its effectiveness, the delivery of higher doses of chemotherapy to periphery blood stem cells in people has not been well investigated. On the other side, there are two reported cases of individuals who experienced assisted remission after receiving higher dosages of remedies:

Comment [D22]: Rephrase or paraphrase this sentence

A:) a treatment combining etopophos, cytophosphane, and melphalan

B:) a mixture of paraplatin, etopophos, and ifosfamide therapy (14)

Prophylactic chemotherapy

One element of GTD treatment which is still up for debate is either to start preventive chemotherapy in a subgroup of women who have hydatidiform mole are at high risk of tenacity but instead of tracking their hcg thresholds until they meet the criteria for declaring no evidence of disease or persistent GTD rather than tracking their hCG levels until they fulfill the requirement for announcing no evidence of disease or persistent GTD. The goal is to use a more moderate chemotherapy treatment to prevent the need for further rigorous treatment in a lesser group of women, improving the chance of full remission. In a number of non-randomized studies, the risk of recurrent/persistent sickness was significantly reduced (15)

Comment [D23]: Rephrase or paraphrase this part

Prophylaxis, Prophylactic chemotherapy was administered to 59% (19%) of the patients, while the remaining 216 people served as controls. In the 59 people who received preventative chemotherapy, no one had chronic GTD, while persistent GTD developed in 59% ~~percent~~ of the comparison group.

Comment [D24]: Please add reference to this part

Only three randomised trials were found in a recent Cochrane review, including the above-mentioned actinomycin study. The combined results of 7 studies showed a lower risk of GTD, but the 2 out of 3 studies were deemed low quality by the Cochrane authors (16)

Comment [D25]: Please add reference to this part

Second dilatation and curettage

~~2nd~~ Second uterine extraction appears to limit the symptoms linked to chronic illness and lessen the requirement for chemotherapy for certain institutions with considerable experience with GTD. 48 Sixty females who were diagnoses with prior GTN received a 2nd uterine curettage as part of the GOG 242 study, and 24 (40 percent) of them obtained full remission without the need for chemotherapy. There were no patient's were cured who had hCG level larger over 100,000 mIU/mL or a FIGO/WHO score greater than 4. (17-19).

Comment [D26]: Please simplify this part for better understanding.

Selective uterine surgery

~~Chemoresistant illness patients~~ Patients with chemo-resistant illness are frequently recommended to have a hysterectomy, although many of these women prefer to maintain their fertility. Women with PSTT who received fertility-saving treatment are highlighted in a research review. Six of the 11 women who underwent a laparotomy with uterine retention were successful, while the other five required a complete hysterectomy. As a result, while this therapy may be effective in approximately half of the cases, close monitoring of excision margin and disease progression is required. However, hCG monitoring is useless in the case of PSTT, and human placental DNA is a better predictor of disease incidence (17).

Follow-up GTN Patients after Treatment

If the hCG levels were not identified after three weekly spliced analyses and chemotherapy, numerical hCG levels in the plasma must be obtained for one year at monthly intervals for GTN patients in stages I and III, and for two years at periodic intervals for GTN patients in stage IV, exactly even before pregnancy period begins. The recurring risk for GTN patients is generally between 4 and 10% within the first year after taking the appropriate therapy. Actual medical assessments must be performed every three months when the hCG level is measured. Furthermore, radiographic imaging techniques should only be used in particular circumstances (18).

Formatted: Font: Bold

Comment [D27]: Please simplify this part for better understanding

Fertility control should be carried out primarily throughout treatment and for 1 or 2 years following completion of chemotherapy, mostly by the use of ~~of combined~~ in combination with oral contraceptive pills. In cases where amount of hCG is not measurable, the use of intrauterine contraceptive device may have negative consequences. In advanced gestations beyond 10 weeks, however, because to the likelihood of future GTD occurrences within the prospective subsequent pregnancy, a pelvic ultrasonography scan is recommended for fulfilling the development of standard ~~foetal~~ fetal development. Furthermore, 6 weeks following the procedure, an inspection of the HCG hormone level must be performed. Furthermore, 6 weeks afterward the completion of all subsequent gestations, and also hcg hormone levels should be checked. Certain related studies were reviewed (20-24).

Comment [D28]: Rephrase or paraphrase this part

After the abortion or ~~post~~ post-term disease should then be seen when a patient is having a past of molar pregnancy or gestational trophic neoplasia, has a fibroids bleeding, or displays evidence of metastatic sickness after a miscarriage or pregnancy. Utilizing pharmaceutical mixtures

Comment [D29]: Rephrase or paraphrase this part

containing etopophos has been associated to an elevated risk of hepatocellular carcinoma,carcinoma, include breast cancer, melanoma, CRC, blood and bone marrow cancer, as per a prior research-research.

Comment [D30]: Please add reference

Conclusion:

The prognoses for GTN malignancies after therapeutic ~~therapy-management~~ are critical, and the majority of ~~-existing~~ information in the area has ~~been-gained~~ importance during the last half-century, mostly by ~~seeing-observing~~ the natural and organic history of GTN malignancies. Patients with low and high risk GTN illness have survival rates of more than 95 percent and 80 percent, respectively. One of the most significant future difficulties in this area is the capacity to ~~optimiseoptimize the~~ treatment regimens for drug-resistant individuals. The advancement of anti-angiogenesis therapy, as well as molecular targeted cancer medications, could improve the therapeutic outlook for these patients.

References:

1. F.J. Paradinas, The differential diagnosis of choriocarcinoma and placental site tumour, *Current Diagnostic Pathology*, Volume 5, Issue 2, 1998, Pages 93-101, ISSN 0968-6053, [https://doi.org/10.1016/S0968-6053\(98\)80013-6](https://doi.org/10.1016/S0968-6053(98)80013-6). (<https://www.sciencedirect.com/science/article/pii/S0968605398800136>)
2. Hemberger M, Udayashankar R, Tesar P, et al. : ELF5-enforced transcriptional networks define an epigenetically regulated trophoblast stem cell compartment in the human placenta. *Hum Mol Genet.* 2010;19(12):2456–67. 10.1093/hmg/ddq128
3. Pijnenborg R, Robertson WB, Brosens I, et al. : Review article: trophoblast invasion and the establishment of haemochorial placentation in man and laboratory animals. *Placenta.* 1981;2(1):71–91. 10.1016/S0143-4004(81)80042-2
4. Early development of the human placenta. In: Benirschke K, Kaufmann P. *Pathology of the human placenta* New York: Springer-Verlag, 1990;13–21. 10.1007/978-1-4757-4193-3_2
5. Gude NM, Roberts CT, Kalionis B, et al. : Growth and function of the normal human placenta. *Thromb Res.* 2004;114(5–6):397–407. 10.1016/j.thromres.2004.06.038
6. Pijnenborg R, Vercruysse L, Hanssens M: The uterine spiral arteries in human pregnancy: facts and controversies. *Placenta.* 2006;27(9–10):939–58. 10.1016/j.placenta.2005.12.006
7. Moser G, Huppertz B: Implantation and extravillous trophoblast invasion: From rare archival specimens to modern biobanking. *Placenta.* 2017;56:19–26. 10.1016/j.placenta.2017.02.007
8. Eysbouts YK, Ottevanger PB, Massuger LFAG, et al. : Can the FIGO 2000 scoring system for gestational trophoblastic neoplasia be simplified? A new retrospective analysis from a nationwide dataset. *Ann Oncol.* 2017;28(8):1856–61. 10.1093/annonc/mdx211
9. Bruce S, Sorosky J: Gestational Trophoblastic Disease. Stat Pearls Publishing. 2017.

10. Shih IM: Gestational trophoblastic neoplasia--pathogenesis and potential therapeutic targets. *Lancet Oncol.* 2007;8(7):642–50. 10.1016/S1470-2045(07)70204-8
11. Vree M, van Trommel N, Kenter G, et al. : The influence of lung metastases on the clinical course of gestational trophoblastic neoplasia: a historical cohort study. *BJOG.* 2016;123(11):1839–45. 10.1111/1471-0528.13622.
12. Vargas R, Barroilhet LM, Esselen K, et al. : Subsequent pregnancy outcomes after complete and partial molar pregnancy, recurrent molar pregnancy, and gestational trophoblastic neoplasia: an update from the New England Trophoblastic Disease Center. *J Reprod Med.* 2014;59(5–6):188–94.
13. Garrett LA, Garner EI, Feltmate CM, et al. : Subsequent pregnancy outcomes in patients with molar pregnancy and persistent gestational trophoblastic neoplasia. *Obstet Gynecol Surv.* 2008;63(11):704–5. 10.1097/01.ogx.0000335639.50781.79
14. Nadhan R, Vaman JV, C N, et al. : Insights into dovetailing GTD and Cancers. *Crit Rev Oncol Hematol.* 2017;114:77–90. 10.1016/j.critrevonc.2017.04.001.
15. Altieri A, Franceschi S, Ferlay J, et al. : Epidemiology and aetiology of gestational trophoblastic diseases. *Lancet Oncol.* 2003;4(11):670–8. 10.1016/S1470-2045(03)01245-2.
16. Seckl MJ, Sebire NJ, Berkowitz RS: Gestational trophoblastic disease. *Lancet.* 2010;376(9742):717–29. 10.1016/S0140-6736(10)60280-2.
17. Trophoblastic disease: Scoring, standardization, and salvage. *Gynecol Oncol.* 2017;144(1):200–7. 10.1016/j.ygyno.2016.08.330.
18. Mello JB, Ramos Cirilo PD, Michelin OC, et al. : Genomic profile in gestational and non-gestationalchoriocarcinomas. *Placenta.* 2017;50:8–15. 10.1016/j.placenta.2016.12.009
19. Rodabaugh KJ, Bernstein MR, Goldstein DP, et al. : Natural history of post term choriocarcinoma. *J Reprod Med.* 1998;43(1):75–80.
20. Reitsma MB, Reitsma MB, Kendrick PJ, Ababneh E, Abbafati C, Abbasi-Kangevari M, et al. Spatial, temporal, and demographic patterns in prevalence of smoking tobacco use and attributable disease burden in 204 countries and territories, 1990-2019: a systematic analysis from the Global Burden of Disease Study 2019. *LANCET.* 2021 Jun 19;397(10292):2337–60.
21. Jessani S, Saleem S, Hoffman MK, Goudar SS, Derman RJ, Moore JL, et al. Association of haemoglobin levels in the first trimester and at 26-30 weeks with fetal and neonatal outcomes: a secondary analysis of the Global Network for Women's and Children's Health's ASPIRIN Trial. *BJOG-AN INTERNATIONAL JOURNAL OF OBSTETRICS AND GYNAECOLOGY.*
22. Abbafati, Cristiana, Kaja M. Abbas, Mohammad Abbasi, Mitra Abbasifard, Mohsen Abbasi-Kangevari, Hedayat Abbastabar, Foad Abd-Allah, et al. "Global Burden of 369 Diseases and Injuries in 204 Countries and Territories, 1990-2019: A Systematic Analysis for the Global Burden of Disease Study 2019." *LANCET* 396, no. 10258 (October 17, 2020): 1204–22.
23. Sahu, Preeti Rajendra, Kishor Madhukar Hiwale, and Sunita Jayant Vagha. "Transitional-Cell Carcinoma of the Endometrium: A Rare Case Report." *JOURNAL OF EVOLUTION OF MEDICAL AND DENTAL SCIENCES-JEMDS* 9, no. 36 (September 7, 2020): 2666–68. <https://doi.org/10.14260/jemds/2020/579>.

24. Toshniwal, Shikha M., Saunitra A. Inamdar, Himanshi D. Agarwal, and Sakshi R. Sharma. "Malignant Brenner Tumor- A Rare Case of Ovarian Carcinoma." MEDICAL SCIENCE 24, no. 105 (October 2020): 3550–54.

UNDER PEER REVIEW