

## **Case study**

### **Transient biventricular dysfunction following pericardiocentesis for cardiac tamponade**

#### **ABSTARCT :**

Pericardial decompression syndrome (PDS) is an infrequent, life-threatening complication following pericardial drainage for cardiac tamponade, either by needle pericardiocentesis or surgical pericardiostomy. It manifests with paradoxical hemodynamic deterioration and/or pulmonary edema, commonly associated with ventricular dysfunction.

PDS usually develops after initial clinical improvement following pericardiocentesis and is significantly underreported and may be overlooked in the clinical practice.

Although the precise mechanisms resulting in PDS are not well understood, this seems to be highly associated with patients who have some underlying ventricular dysfunction. Physicians performing pericardial drainage should be mindful of the risk factors associated with the procedure including the rare potential for the development of PDS.

**Keywords:** Pericardial Decompression Syndrome; Cardiac Tamponade; post-pericardial drainage low cardiac output syndrome; Paradoxical Hemodynamic Instability

#### **INTRODUCTION :**

Cardiac tamponade is a medical emergency that restricts the filling of the heart chambers and alters normal hemodynamic conditions, resulting in cardiogenic shock and hypotension occurs after rapid and or excessive deposition of fluid in the pericardial space.{ 1 }

Pericardial drainage, by either pericardiocentesis or pericardiotomy, is vital in making patients hemodynamically stable, but has been associated with numerous complications, including one very rare, underappreciated, and life-threatening complication known as pericardial decompression syndrome (PDS).{ 2 }

PDS usually occurs after clinical improvement following pericardiocentesis. It is largely unrecognized and may go unnoticed in daily practice.

#### **CASE REPORT :**

We report the case of a 38 year-old woman, with no past significant cardiovascular history. She has a history of metastatic breast cancer, who underwent mastectomy for Invasive Ductal Carcinoma SBR II triple negative, 6 months later, presented to the emergency department with progressively worsening dyspnea over the previous 2 weeks with lower chest discomfort.

Her physical examination was noticeable for jugular venous distension, hypotension (blood pressure of 80/50 mmHg), tachycardia (heart rate of 172 beats/min), and muffled heart sounds.

Her electrocardiogram showed sinus tachycardia with electrical alternance and diffuse low complex QRS voltage, and flat T waves (figure 1). The chest X-ray revealed an enlarged cardiac silhouette with a right pleural effusion. A transthoracic echocardiogram revealed a large pericardial effusion (53 mm

in the posterior wall, 31 mm in the anterior wall) with swinging heart. Global and regional contractility were preserved and left ventricle ejection fraction (LVEF) was preserved (figure 2-3-4)

An emergent pericardiocentesis was performed and 1,500 ml of sero-sanguinous fluid was removed. The pericardial draining catheter was left in place for one day. The pericardial fluid was exsudative. Cytologic examination of the pericardial fluid revealed malignant cells. A post pericardiocentesis TTE showed no residual pericardial effusion with LV systolic dysfunction. Her post- pericardiocentesis electrocardiogram showed normal sinus rhythm without electrical alternans. 8 hours after pericardiocentesis, patient became suddenly breathless with tachycardia, without chest pain. The TTE showed little pericardial effusion without hemodynamic compromise, but we noted a systolic dysfunction of both ventricles with LVEF 30 %.

No evidence of myocardial perforation was found. ECG showed a sinus tachycardia with diffuse low QRS voltage, negative T waves in anterior leads. Troponin was normal. Repeated renal workup did not reveal renal failure and liver testing showed an improvement in cytolysis. Immediate i.v therapy with dobutamine and furosemide 40mg per day were initiated with a steady clinical improvement. Eleven days after admission the patient was recovering well in the cardiology ward and expressed a subjective perception of good health. A follow-up echocardiogram showed a dramatic improvement in the contractility of both ventricles. Both ventricles had returned to a normal size and LVEF was 55%. Analgesics were only prescribed drugs, and the oncology team was ready to initiate chemotherapy for the breast cancer.

## **DISCUSSION :**

The presence of pericardial tamponade, drainage, whether performed transcutaneously or surgically, allows in the vast majority of cases an improvement in hemodynamics. Apart from the standard complications such as puncture of cardiac cavities, coronary artery injury, arrhythmia, pneumothorax, hemothorax, pneumopericardium or liver injury, this procedure may be accompanied by a paradoxical hemodynamic failure. This is a rare complication with an incidence of the disease is about 5 %, but it is severe with a mortality of about 16%. Mortality seems to be more important in the aftermath of surgical drainage 29%.{5}

The first description of this clinical syndrome dates back to 1983 Vandyke et al {7} in a patient of Caucasian origin with acute myeloid leukemia who benefited from a surgical drainage by pericardiocentesis of 500 ml of serosanguinous fluid, but it is only in 2010 that the term pericardial decompression syndrome was proposed.

Pericardial decompression syndrome also known as post-pericardial drainage low cardiac output syndrome is defined as a paradoxical worsening of hemodynamics and development of pulmonary edema after uneventful pericardial drainage in patients with cardiac tamponade. {3}

The clinical presentation is variable, ranging from acute pulmonary oedema without shock to right, left or bi-ventricular failure, and can occur up to hours after the procedure. The main risk factors for mortality are neoplastic damage to the pericardium, post-radical damage, pericardial calcifications, previous damage to myocardial function or the need for circulatory support, whether medical or mechanical.{8}

The pathophysiology is not fully understood at present, several hypotheses have been put forward (figure 5) :

- The first plausible hypothesis is paradoxical hemodynamic dysfunction based on a sudden increase in venous return following the lifting of the hemodynamic obstruction of the effusion, leading to an increase in afterload and dilation of the right ventricle which may lead to failure of the latter. The induced transmural pressure elevation of the right ventricle is further exacerbated by a negative intrapericardial pressure related to drainage. Indeed, the physiological pressure of the intrapericardial

**Comment [UdW1]:** It is best if this information appears in the Introduction.

space being almost zero, the latter becomes negative following the opening of this space and the implementation of the drainage. The dilation of the right ventricle also leads to a deviation of the interventricular septum towards the left and thus a decrease in cardiac output by virtue of the ventricular interdependence resulting in reduced volume and left ventricular output and results in decompensated left heart failure and/or pulmonary edema.{8}

-Other researchers, have specified that the dysregulation could be due to the drop in coronary flow due to the compression of the epicardial coronary arteries by pericardial fluid and that ischemic heart disease could be one of the contributing factors.{1}

- The last hypothesis suggests a neuro-vegetative origin with a sudden decrease in sympathetic activity after drainage, which may reveal a pre-existing ventricular dysfunction or lead to parasympathetic hyperactivity

Wolfe and Edelman reported that removal of sympathetic stimulus after pericardiocentesis might lead to unfolding of underlying left ventricular dysfunction that had not previously been revealed because of an exaggerated catecholamine state-producing. Moreover, Martins and colleagues demonstrated that although the administration of exogenous catecholamines enhanced coronary blood flow in patients with cardiac tamponade, there was no change in filling pressures and only a small increase in the cardiac index.{7}

They reasoned that because sympathetic nervous system activation was already taking place, elevated levels of endogenous catecholamines had no additional potential benefit. The removal of the stimulus that results in an enhanced sympathetic state may well lead to the revelation of left ventricular dysfunction that was previously balanced by high endogenous catecholamine levels.{ 11 }

Thus, sympathetic overdrive mechanism might play an important role in the etiology of PDS because left ventricular systolic function abnormalities may occur after pericardiocentesis intervention as described{6}

The presented case supports a diagnosis of PDS as clinical decompensation paradoxically followed decompression of cardiac tamponade. Since post-pericardiocentesis ventricular dysfunction is not a common finding in the clinic, we argue that transient myocardial dysfunction following pericardial Drainage is more susceptible to occur when a significant volume of pericardial fluid is being removed in a short period of time, inhibiting rapid regulation of coronary resistance and regulation of the autonomic nervous system.

In the absence of specific treatment, management is based primarily on early diagnosis and the introduction of supportive hemodynamic therapy. The introduction of vasopressor or inotropic therapy is often necessary, and the most severe cases may require external circulatory support.{7}

#### **CONCLUSION :**

Pericardial decompression syndrome is uncommon (incidence <5%) but severe with a mortality of up to 30%. Its pathophysiology is not well understood. During any pericardial drainage, whether surgical or medical, a prudent and slow drainage must be performed.{9}

#### **BIBLIOGRAPHIE**

{ 1 } Flores, V. M., Pascual Figal, D. A., Martínez, C. C., & Valdés-Chávarri, M. (2009). *Transient Left Ventricular Dysfunction Following Pericardiocentesis. An Unusual Complication to Bear in Mind. Revista Española de Cardiología (English Edition)*, 62(9), 1071–1072.

**Comment [UdW2]:** After a detailed discussion, a more abundant conclusion is to be expected. We suggest that the author review the results of the applied therapy and draw the conclusions derived from it. A numbered and argued conclusion will enhance the case study

{ 2 } Imazio, M. (2014). *Pericardial decompression syndrome: A rare but potentially fatal complication of pericardial drainage to be recognized and prevented. European Heart Journal: Acute Cardiovascular Care, 4(2), 121–123*

{3} Ligerio, C., Leta, R., & Bayes-Genis, A. (2005). *Transient biventricular dysfunction following pericardiocentesis. European Journal of Heart Failure, 8(1), 102–104.*

{4} Pradhan, R., Okabe, T., Yoshida, K., Angouras, D. C., DeCaro, M. V., & Marhefka, G. D. (2014). *Patient characteristics and predictors of mortality associated with pericardial decompression syndrome: a comprehensive analysis of published cases. European Heart Journal: Acute Cardiovascular Care, 4(2), 113–120.*

{5} Expert Analysis . Pericardial Decompression Syndrome - American College of Cardiology April 2020.

{6} Yougeesh Prabhakar, Amandeep Goyal, Nauman Khalid, Nitish Sharma, Raj Nayyar, David H Spodick, Lovely Chhabra. *World J Cardiol. 2019 Dec 26; 11(12): 282–291. Published online 2019 Dec 26.*

{7} Vandyke, W. H., Cure, J., Chakko, C. S., & Gheorghiad, M. (1983). *Pulmonary Edema after Pericardiocentesis for Cardiac Tamponade. New England Journal of Medicine, 309(10), 595–596.*

{8} Nicolas Ropraza, médecin diplômé; Thierry Bonjourb, médecin diplômé; Dr méd. Aurélien Roumyc ; Dr Ana Barrigon Benitezd; Dr méd. Marco Ruscae. *Un drainage péricardique qui tourne mal, le syndrome de décompression myocardique. SWISS MEDICAL FORUM – FORUM MÉDICAL SUISSE 2020;20(45–46):658–660*

{9} Chung, J., Ocken, L., Wolo, E., Herman, C. R., & Goldhammer, J. E. (2018). *Acute Right Ventricular Failure After Surgical Drainage of Pericardial Tamponade: A Case Report of Pericardial Decompression Syndrome and Review of the Literature. Journal of Cardiothoracic and Vascular Anesthesia.*

{10} Chakri Yarlagadda, MD, FACC, FSCAI, FASNC, CCDS Director of Cardiac Rehabilitation, St Elizabeth Youngstown Hospital; Radiation Safety Officer, Mercy Health Cardiology ,Pericardial Effusion and Cardiac Tamponade Requiring Pericardial Window in an Otherwise Healthy 30-year-old Patient With COVID-19

{11} Pradhan, R., Okabe, T., Yoshida, K., Angouras, D. C., DeCaro, M. V., & Marhefka, G. D. (2014). *Patient characteristics and predictors of mortality associated with pericardial decompression syndrome: a comprehensive analysis of published cases. European Heart Journal: Acute Cardiovascular Care, 4(2), 113–120.*

**Comment [UdW3]:** Bibliographic citation 4 do not appear in the text.

**Comment [UdW4]:** Bibliographic citation 10 do not appear in the text.

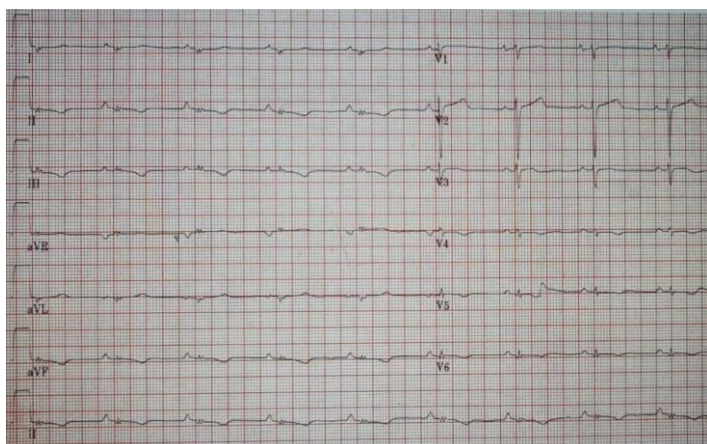


figure 1: Electrocardiogram showing low complex QRS voltage, and flat T waves

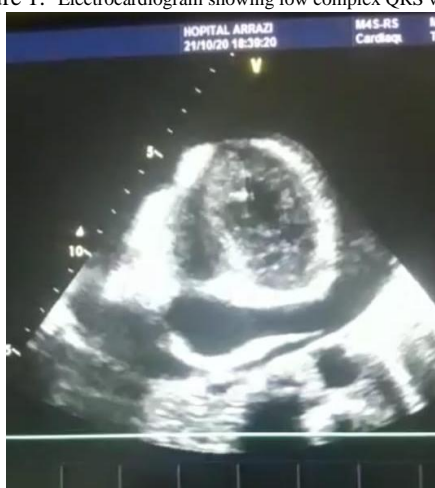

Figure 2

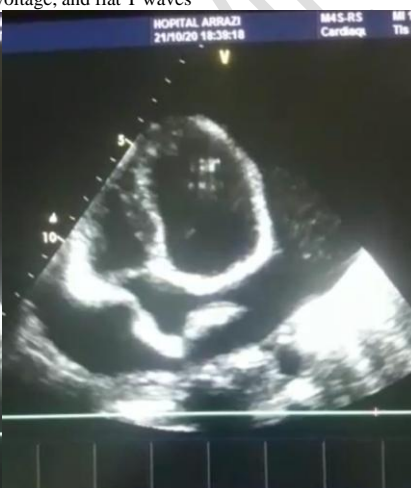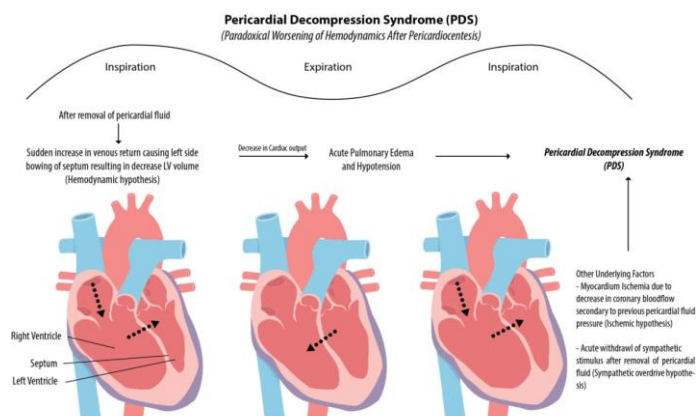


Figure 3

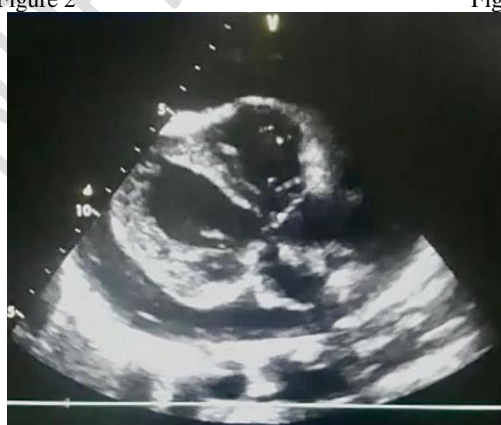

Figure 4

**Figure 2-3-4** :transthoracic echocardiogram demonstrates a large circumferential pericardial effusion with evidence of end diastolic right chamber compression



**Figure 5:** Schematic Illustration of the pathophysiology of PDS. {4}