



## Distal 3rd Diaphysial Fracture of Humerus Fixed with DCP Using Posterior Approach- The Assessment of the outcome

**Abstract: Objectives:** The effectiveness of open reduction and  fixation combined with or without autogenous bone grafting by posterior midline approach was assessed in the treatment of distal third diaphyseal humeral fractures. **Methods:** 33 patients (24 men, 9 women; mean age 37 years; range 20 to 60 years) were operated on for humeral nonunion, comminuted fractures or early failure of conservative treatments. The study was carried out at Dhaka Medical College Hospital, Dhaka from July 2005 to December 2006. **Results:** Union was achieved in all the patients after a mean of 17 weeks (range 14 to 26 weeks). Deep infection, nonunion, malunion, implant failure, or permanent nerve injury did not occur in any of the patients. Two patients had transient radial nerve palsy. Four patients developed superficial infections. All patients were relieved pain postoperatively. Functional outcome was excellent in all cases & good in 16 patients which constituted 87% satisfactory results. Functional results improved significantly postoperatively than the preoperative one ( $p < 0.001$ ). Shoulder range of motion was excellent in 20 patients. Elbow range of motion was excellent in 21 patients and moderate in 7 patients. **Conclusion:** Treatment with open reduction and DCP fixation by posterior approach combined with or without autogenous bone grafting is a safe and effective option in distal third humeral fractures, particularly in cases without infection or any bony or neurovascular defect.

### Introduction:

Distal humerus fractures are difficult to treat because they are so complicated. The shaft of the humerus is  often, accounting for 1–3% of all fractures [1, 2]. Humeral shaft and extra-articular supracondylar humerus fractures in adults comprise 10% of humeral shaft and 10% of distal humerus fractures [3]. Most of these are either simple spiral diaphyseal fractures or are complicated by extension into the articular surface.

Non-operative treatments such as hanging casts, functional braces, Velpeau dressing, coaptation splints, and abduction casts produce excellent results in humerus shaft fractures, which are unique among all long bone fractures [4,5]. The tolerance of malunion in the humerus contributes to good functional results in these fractures. All fractures, however, are not amenable to conservative treatment. Open fractures, segmental fractures, pathological fractures, fractures associated with vascular injuries, bilateral humerus fractures, polytrauma, radial nerve palsy after fracture manipulation, neurological loss after penetrating injuries, fractures with unacceptable alignment, and failure of conservative treatment are all indications for operative treatment of humeral shaft fractures [2]. Non-operative treatment necessitates a lengthy period of immobilization, which increases the patient's risk of shoulder joint stiffness and annoyance [6]. In addition, non-union after conservative treatment of these fractures occurs in up to 10% of patients, and management of this condition can be problematic [7,8].

There is a rising interest in using surgical methods to treat even mild humeral shaft fractures in order to minimize these complications and allow for earlier mobilization and return to work [9]. The use of a dynamic compression plate (DCP) or an interlocking intramedullary nail (ILN) is the most common operating approach (ILN). Among various modalities of surgical treatment, DCP and ILN, Compression Plate fixation remains the 'gold standard' according to Farragos, Schemitsch & Mckee [10]. Compression plating is a classical method [11]. In selected patients of the humeral shaft fractures, is preferred method because of its high success rate when used by simultaneous autogenous corticocancellous grafting. Though plating requires an extensive exposure with stripping of soft tissues from the bone, it permits excellent reduction and fixation and has the advantage that it does not interfere with elbow and shoulder function [12]. Open reduction and internal fixation of distal humeral shaft fracture provides good clinical result and should be carried out aiming for an early postoperative functional treatment [13]. Dynamic compression plate gives additional advantage of fixing the fragments putting the screw obliquely up to 45° if necessary due to its special design of holes. This ensures holding the comminuted fragments rigidly.

There is considerable interest in using the humeral intramedullary nail to treat this fracture as a result of recent technological developments and the success associated with nailing in other long bone fractures. The ILN method is less invasive, and the implant's biomechanics and load-sharing capabilities are improved. Fractures treated with ILN have a better likelihood of healing since there is no periosteal stripping and the reaming acts as an autograft. IM nail fixation was reported to achieve 100% union rate in the previous study [14]. The relative stability of the IM nail has been reported to have various advantages, including less soft tissue dissection and the capacity to deliver appropriate reduction. However, it has a number of disadvantages, including less perfect reduction with a higher risk of distraction, inability to remove interpositional nonunion tissue, increased risk of radial nerve injury due to inability to visualize the nerve, and technical difficulty passing the guide rod, which may injure the soft tissue around the shoulder joint.

### **Objective:**

The aim of this study was to assess the results of open reduction and DCP fixation with or without autogenous grafting by posterior approach in the treatment of fracture lower third of humeral diaphysis.

### **Materials and methods:**

**Study design:** This was an interventional study (quasi experimental type).

**Place of the study:** The study was carried out at Dhaka Medical College Hospital, Dhaka.

**Study period:** This study was conducted from July 2005 to December 2006.

**Study population:** Patients with clinical and radiological evidence of fracture distal third of humeral shaft who attended at the ID or emergency department of DMCH.

**Sample size:** Thirty-three patients with fracture of distal third humeral shaft were selected consecutively. Cases were diagnosed on clinical and radiological basis at the outpatient or emergency department of Dhaka Medical College & Hospital. Two patients were lost during follow up, before the measurement of final outcome. They were excluded from the final evaluation of the functional outcome. The remaining 31 were available for follow up for a period of 6 to 8 months.

**Inclusion criteria:**

- Adult patients of age between 18 years to 60 years of either sex.
- Closed Fracture located at the distal third of humeral diaphysis.

**Exclusion criteria:**

- Skeletally immature patients and the patients of age over 60 years.
- Open fractures.
- Pathological fractures
- Patients who were unable to cooperate the assessment of function because of head injuries or other causes (senility, neurotic).

**Data collection:** Data were collected with a pre-tested, structured questionnaire containing history, clinical & laboratory examination findings.

**Statistical analysis:** Data were processed and analyzed using computer software SPSS (statistical Package for Social Sciences) version 11.5. The test statistics used to analyze the data were descriptive statistics, Wilcoxon Signed Rank Test and one-tailed Z-test. The data presented on categorical scale were expressed as frequency and corresponding percentage, while the quantitative data were presented mean and standard deviation (SD) from the mean. Comparison between preoperative and postoperative data (according to Modified Constant and Murley scoring system) were done using Wilcoxon Signed Rank Test. Post operative final outcome was evaluated using Z-test. ANOVA statistics was used to compare the time interval among the types of cases. For all analyses level of significance was set at 0.05 and p-value < 0.05 was considered significant.

**Results:**

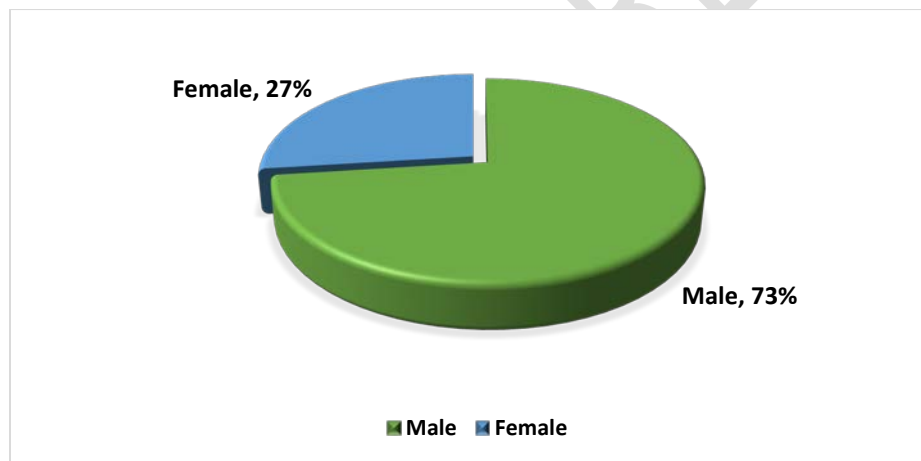
Out of 33 subjects one-third (33.3%) were below 30 years of age and 30.3% between 30-40 years of age constituting more than half (63.3%) of the subjects within 40 years of age. Of the rest subjects, 18.2% were in the age range of 40-50 years and another 18.2% were 50 or above 50

years of age. The mean age was ( $36.7 \pm 11.2$ ) years and the lowest and highest ages were 20 and 60 years respectively (Table 1).

**Table 1: Age distribution of the patients (n=33)**

Age (in years)	Frequency (n)	Percentage (%)
<30	11	33.3
30 to 40	10	30.3
40 to 50	6	18.2
$\geq 50$	6	18.2
Total	33	100

Among the 33 patients nearly three-quarter (73%) of the subjects were male and the rest were female (27%) giving a male-female ratio of 3:1 roughly.



**Figure 1 Gender distribution**

Table 2 shows that over 45% of the injuries resulted while walking on the street (pedestrian), 12.1% due to fall from height, another 12.1% were caused while on sports activities and 9.1% by motorcycle driving. Motorcar driving, assault and & accident at home each contained 6.1%. Only 1(3%) patient had machinery injury.

**Table 2: Distribution of the patients by cause of injury (n = 33)**

Cause of injury	Frequency (n)	Percentage (%)
Motor car driving	02	6.1
Motorcycle driving	03	9.1
Pedestrian	15	45.5
Fall from height	04	12.1

Assault	02	6.1
Machinery injuries	01	3.0
Accident at home	02	6.1
Sports activities	04	12.1

Table 3 compares the time interval between injury and operation among the three types of fracture cases. The time interval in non-united type of fracture was observed to be the highest ( $43.92 \pm 14.91$  weeks) compared to early failure of conservative treatment ( $1.82 \pm 0.41$  weeks) and comminuted fracture ( $2.33 \pm 1.12$  weeks). The groups were significantly heterogeneous in terms of time interval between injury and operation ( $p < 0.001$ ).

**Table 3: Comparison of time interval among the type of fractures (n = 33)**

Type of fracture	Frequency	Time interval (weeks)		p-value
		Mean	SD	
Early failure of conservative treatment	11	1.82	0.41	<0.001
Non-united	13	43.92	14.91	
Comminuted	9	2.33	1.12	

Table 4 shows the average hospital stay of the patients was 9.76 days with a SD of  $\pm 3.03$  days. The highest and lowest stays were 17 and 7 days respectively. Radiologically all the cases were found to be united and the mean time of presence of sign of union was  $17.06 \pm 2.01$  weeks and the minimum and maximum time needed for union were 12 and 24 weeks respectively. The mean follows up time of patients was  $24.58 \pm 3.56$  weeks and the lowest and highest time of follow up were 15 and 32 weeks respectively.

**Table 4: Post operative status (hospital stays and follow up) and time taken for union**

Variables	Mean $\pm$ SD	Range
Post operative stay (days)	$9.76 \pm 3.03$	7 to 17
Presence of sign of union (weeks)	$17.06 \pm 2.01$	12 to 24
Duration of follow up (weeks)	$24.5 \pm 3.56$	15 to 32

More than three-quarter (75.8%) of cases did not have any complication. Four patients (12.1%) developed infection and two patients (6.1%) had iatrogenic radial nerve palsy. One (3%)

exhibited loosening of the screw and one (3%) had to be transfused with blood because of profuse bleeding from the donor graft site

**Table 5: Distribution of patients by postoperative complications (n = 33)**

Postoperative complication	Frequency (n)	Percentage (%)
Iatrogenic radial nerve palsy	02	6.1
Infection	04	12.1
Loosening of the screw	01	3.0
Post operative blood transfusion	01	3.0
No complication	25	75.8

Table 6 shows the range of motion immediately before the last evaluation visit. The mean values and the range of different types of active and passive motions of shoulder and elbow were presented in the table.

**Table 6 Range of motion immediately before the last assessment visit (n=33)**

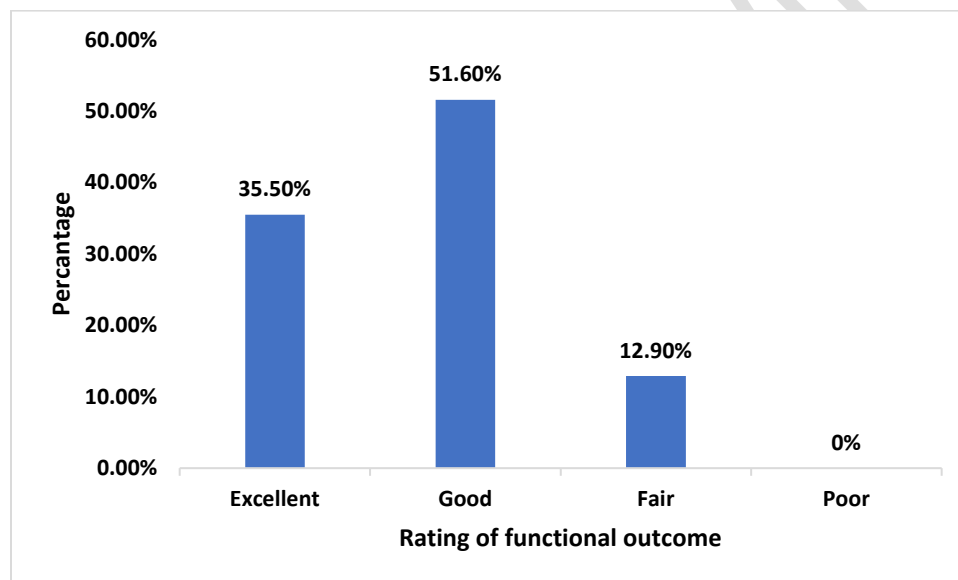
Range of motion	Mean $\pm$ SD	Range
<b>Shoulder</b>		
Flexion (active)	130+ 15	100 to 160
Flexion (passive)	136 $\pm$ 15	100 to 160
Extension (active)	38 $\pm$ 4	30 to 45
Extension (passive)	38 + 4	30 to 45
Abduction (active)	129 $\pm$ 11	110 to 150
Abduction (passive)	134 $\pm$ 12	110 to 150
<b>Elbow</b>		
Flexion (active)	116+10	100 to 130
Flexion (passive)	116110	100 to 130
Extension (active)	0 $\pm$ 0	0
Extension (passive)	0 $\pm$ 0	0

Table 7 evaluates the preoperative and postoperative total score (100) derived from combination of four parameters like pain (score 15), activities of daily living (score 20), power (score 25) and range of motion (score 40). The mean postoperative score improved significantly to 75.87  $\pm$  13.47 from the mean preoperative score of 8.16  $\pm$  7.23 ( $p < 0.001$ ).

**Table 7: Comparison between preoperative and postoperative functional outcome score (n=31)**

Variables	Mean $\pm$ SD	p-value*
Pre-operative	8.16 $\pm$ 7.23	<0.001
Post-operative	75.87 $\pm$ 13.47	

Figure 2 shows the **Rating** of postoperative functional outcome demonstrates that 11 (35.5%) patients had excellent outcome, 16 (51.6%) good, 4 (12.9%) fair and none had poor outcome



**Figure 2 Rating of postoperative functional outcome**

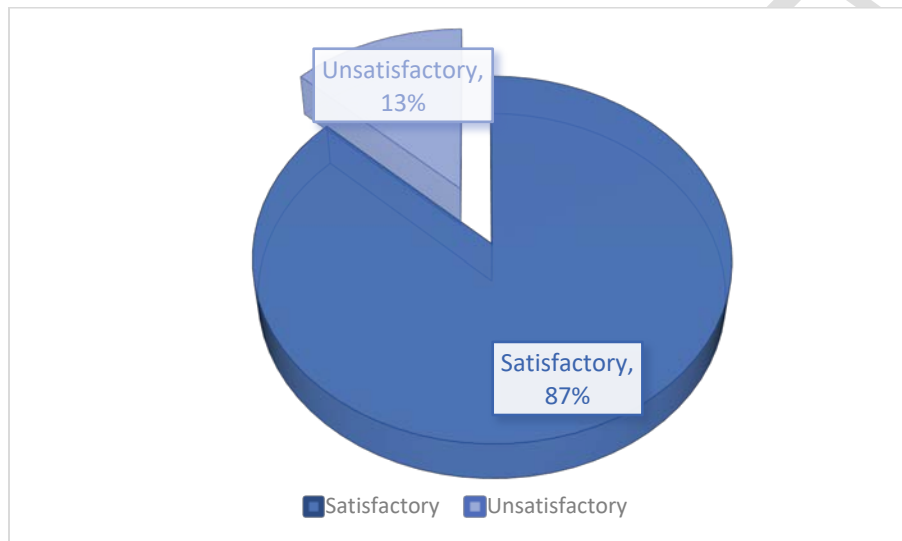
Shoulder motion test reveals that 20 (64.51 %) of the 31 subjects had excellent range of motion ( $< 10^\circ$  deficit) followed by 22.58 % (n= 7) moderate ( $10^\circ$ - $30^\circ$  deficit) and 12.90% poor outcome ( $> 30^\circ$  deficit). More than half (67.74 %) of the subjects had moderate, 22.58% had excellent and only 9.67% had poor functional outcome of elbow motion.

**Table 8: Distribution of patients by restriction in motion at final assessment (n = 31).**

Outcome	Range of motion	Frequency (n)	Percentage (%)
<b>Shoulder motion</b>			
Excellent	( $< 10^\circ$ deficit)	20	64.51
Moderate	( $10^\circ$ - $30^\circ$ deficit)	7	22.58

Poor	(> 30° deficit)	4	12.90
<b>Elbow motion</b>			
Excellent	(< 10° deficit)	21	67.74
Moderate	(10°-30° deficit)	7	22.58
Poor	(> 30° deficit)	3	9.67

Figure 5.6 shows that the majority of the subjects (87%) had satisfactory outcome (excellent and good) and the rest 13% had unsatisfactory outcome. Based on Z-approximation the outcome was considered significant ( $p < 0.001$ ).



**Figure 3 Final outcome**

## Discussion:

The humerus fracture is remarkable among long bone fractures in that it can tolerate reductions that are less than anatomical. Shortening of up to 3 cm, rotation of less than 30 degrees, and angulation of less than 20 degrees are all permissible [15]. Because of this, the majority of humerus fractures are still treated conservatively, with satisfactory functional outcomes. Inability to obtain satisfactory reduction is the most common reason for operational intervention, followed by concomitant vascular lesions, open fractures, radial nerve palsy, polytrauma patients, floating elbow, and pathological fractures [16]. Our series revealed a prevalence of fractures in young males, most typically in their third and fourth decades of life, as described by other similar investigations [17]. The most common cause of injury, particularly in younger patients, is a traffic accident. When operative treatment is indicated, plate fixation probably still remains the primary choice of most surgeons, producing satisfactory functional results and union rate [18].



Humeral shaft fractures are commonly associated with lesions of the radial nerve. The anatomical proximity and association of the bone and nerves in the humeral shaft explain the incidence of between eight and 12% [19,20]. Total documented primary radial nerve palsy in twelve of the 58 patients (20.7%). The best treatment for humeral shaft fractures complicated with radial nerve injury is highly controversial [21, 22]. While concomitant nerve injury has been used as an argument for the immediate surgical treatment of fractures in the past (using a posterior approach and visualizing the radial nerve) [23], recent investigations have shown no significant difference in radial nerve palsy recovery between initial operative and nonoperative management strategies [24, 25].

Epidemiological data of fractures, varies between communities as a result of differences in socioeconomic, cultural, degree of urbanization and other population characteristics [26]. Some authors have reported on trends and patterns of humeral fractures. A study conducted by, Chaudhary et al. [27], the incidence of humeral fractures was found to be 39 and 35 years for ILN and plating group respectively compared with those in the younger age group ( $p < 0.001$ ).

In our study of the 33 present study subjects, one-third (33.3%) were below 30 years of age and 30.3% between 30 - 40 years of age thus constituting more than half (63.3%) of the subjects within 40 years of age. The mean age was  $36.7 \pm 11.2$  years and the lowest and highest ages were 20 and 60 years respectively.

In relation to gender, analysis of this study showed that males had involvement of a nearly three-quarter (73%) of the subjects, giving a male-female ratio of roughly 3:1. while Modi and Pundkar reported 77% of males in a similar study [28]. Mohammad Shoaib Khan et al, in study operated 15 patients with bone grafting and DCP. Out of 15 patients 80% were male and 20% female. [29]. Males being the major working force of our society and are thus more consistently exposed to external environment which probably accounts for this predominance.

This study showed that over 45% of the of the injuries resulted while walking on the street (pedestrian) with a total of 60 % motor vehicle accident, 12.1% due to fall from height, another 12.1% were caused while on sports activities and 9.1% by motorcycle driving. Motorcar driving, assault and accident at home each was 6.1%. Only 1(3%) patient received machinery injury. a similar finding was observed in another study [30].

Long duration of hospital stay after surgery costs the patient both mentally and economically. Average hospital stay of the respondents was 9.76 days with a SD of 3.03 postoperatively. The lowest stay was 7 days and the highest was 17 days. A little longer stay was required for the patients having postoperative infection. Radiologically all of the cases of the present series were found to be united and the mean time of presence of bridging callus was  $17.06 \pm 2.01$  weeks and the minimum and maximum time needed for union were 12 and 24 weeks respectively. In the study of M.Walker et al observed that the union rates in the 92% to 96% range, time to union averaging around 12 weeks [31].

Aizaz Saleem Khan et al in study compared two groups of 30 patients each treated with intramedullary nail and DCP. In group A, transient radial nerve palsy was observed in 3 patients (10%) and mild wound infection in 2 (6%) [32]. In our study we observed more than three-

quarter (75.8%) of the patients did not have any complications in this series. Four patients (12.1%) developed superficial infection postoperatively and these were cross infections. They were given adequate antibiotics & care of the wounds and infection subsided before the patient left the hospital. Two (6.1%) patients had iatrogenic radial nerve palsy. These were neuropraxia and fully recovered within 2 months. One (3%) exhibited loosening of the lowermost screw and this continued all along the study period but didn't hamper the alignment. loosening of the plate or union. One (3%) patient had to be transfused 2 units of whole human blood because of profuse bleeding from the graft donor site which was controlled within 24 hours. There was no observation of any case of delayed healing & there was no necessity for re operation of any patient.

The most frequent problem encountered in antegrade humeral nailing has been its deleterious effect on shoulder function. Crates, et al. [33] reported 90% patients regaining full shoulder function. The present study also achieved the similar results. Shoulder motion tests revealed that 20 (64.51 %) of the 31 subjects had excellent range of motion ( $< 10^{\circ}$  deficit) followed by 22.58 % (n= 7) moderate ( $10^{\circ}$  -  $30^{\circ}$  deficit) and 12.90% poor outcome ( $> 30^{\circ}$  deficit). More than half (67.74 %) of the subjects had moderate, 22.58 % excellent and only 9.67 % poor functional outcome of elbow motion.

Ring, Perey and Jupiter [34] assed the functional outcome of the operative treatment of ununited fractures of the humeral diaphysis in 22 older patients. The average score according to the modified rating system of Constant and Murley increased from 9 points (range, 0-27 points) preoperatively to 72 points (range, 34-95 points) postoperatively at the time most recent follow up ( $p < 0.001$ ). It was performed in the series with 31 cases & follow up was continued for an average of  $24.58 \pm 3.56$  weeks. In this study the preoperative and postoperative total score (100) derived from combination of four parameters like pain (score 15), activities of daily living (score 20), power (score 25) and range of motion (score 40). The mean postoperative score improved significantly to  $75.87 \pm 13.47$  from the mean preoperative score of  $8.16 \pm 7.23$  ( $p < 0.001$ ) which was very consistent with the achievement of Ring, Percy and Jupiter [35].

According to the criteria by Jupiter the results were excellent in six (17.7%). good in 15 (44.1%), fair in nine (26.4%), and poor in four (11.8%) patients. In the current series, rating of postoperative functional outcome demonstrated that 35.5% (11 out of 31 respondents) had excellent outcome, over half (51.6%) good (n=16), 12.9% fair and none had poor outcome. Similar results were also reported in other studies [36]. In this study the majority of the subjects (87%) had satisfactory outcome (excellent and good) and the rest 13% had fair outcome. Based on Z-approximatlon the outcome was considered significant ( $p < 0.001$ ) which proved the procedure safe & effective.

## **Conclusion:**

The DCP via posterior approach was found to be a useful and trustworthy method for the management of distal third diaphyseal fractures of the humerus in this study. This is due to the fact that it has a faster union time and a lower risk of significant consequences like gross infection, radial nerve palsy, and implant failure. There appears to be a considerable variation in functional result between preoperative and postoperative. The lack of a big group of patients is one of the study's limitations. Certain technical aspects, such as proper debridement of avascular bone and fibrous, inflammatory, and synovial tissues from the nonunion site, drilling of sclerotic areas to encourage revascularization, using circumferential bone clamps as little as possible, and extreme caution to avoid devitalizing the bone and soft tissues, are all important.

## References:

1. Brinker MR, O'Connor DP (2004) The incidence of fractures and dislocations referred for orthopaedic services in a capitated population. *J Bone Joint Surg Am* 86:290–297.
2. Schemitsch EH, Bhandari M (2001) Fractures of the diaphyseal humerus. In: Browner BD, Jupiter JB, Levine AM, Trafton PG (eds) *Skeletal trauma*, 3rd edn. WB Saunders, Toronto, pp 1481–1511.
3. Ekholm R, Adami J, Tidermark J, Hansson K, Törnkvist H, Ponzer S (2006) Fractures of the shaft of the humerus. An epidemiological study of 401 fractures. *J Bone Joint Surg Br* 88(11):1469–1473. Doi. 10.1302/0301-620X.88B11.17634
4. Bohler L (1965) Conservative treatment of fresh closed fractures of humerus. *J Trauma* 5:464–468
5. Sarmiento A, Zagorski JB, Zych DO, Latta LL, Capps CA (2000) Functional bracing for the treatment of fractures of humeral diaphysis. *J Bone Joint Surg Am* 82:478–486
6. Rommens PM, Verbruggen J, Broos PL (1995) Retrograde locked nailing of humeral shaft fractures. A review of 39 patients. *J Bone Joint Surg Br* 77:84–89
7. Foulk DA, Szabo RM (1995) Diaphyseal humeral fractures; natural history and occurrence of nonunion. *Orthopaedics* 18:333–335
8. Jupiter JB, Vandec M (1998) Ununited humeral diaphysis. *J Shoulder Elbow Surg* 7:644–653
9. Heim D, Herkert F, Hess P, Regazzoni P (1993) Surgical treatment of humeral shaft fractures-the Basal experience. *J Trauma* 35:226–232
10. Farragos, AF, Schemitsch, EH & Mckee, MD 1999, 'Complications of intramedullary nailing for fractures of humeral shaft: a review', *J Orthop Trauma*, vol.13, pp.258-267.
11. Muller, ME, Allgower, M, Schneider, R & Willenegger, H 1991, *Manual of internal fixation: techniques recommended by the AO-ASIF group*, 3rd edn, Berlin. Springer-Verlag, pp. 427-52.

12. Chapman, JR., Henley, MB, Agel, J & Benca, PJ 2000, 'Randomized prospective study of humeral shaft fracture fixation: intramedullary nails versus plates', *J. Orthop Trauma*, vol. 14 , no.3, pp. 162-6.
13. Pereles, TR, Koval, KJ, Gallagher, M & Rosen, H 1997, 'Open reduction and internal fixation of the distal humerus: functional outcome in elderly', *J. Trauma*, vol. 43. no. 4. pp. 578-84. '
14. S. Bajaj, N. Rama Mohan, and C. Kumar, "Supracondylar Femoral Nail in the management of non-union of humeral shaft fractures," *Injury*, vol. 35, no. 5, pp. 523–527, 2004.
15. Papasoulis E, Drosos GI, Ververidis AN et al (2010) Functional bracing of humeral shaft fractures. A review of clinical studies. *Injury* 41:e21–e27
16. Hoang-Kim A, Goldhahn J, Hak DJ (2012) Humeral shaft fractures. In: Bhandhari M, Gandhi R, Petrisor BA, Swiontkowski M (eds) *Evidence-based orthopedics*, 1st edn. Willey, Hoboken
17. Tsai CH, Fong YC, Chen YH, Hsu CJ, Chang CH, Hsu HC (2009) The epidemiology of traumatic humeral shaft fractures in Taiwan. *Int Orthop* 33:463–467
18. Meekers, FS & Broos, PL 2002, 'Operative treatment of humeral shaft fractures. The Leuven experience', *Acta Orthop Belg* , vol. 68, PP. 462-70.
19. Shao YC, Harwood P, Grotz MR, Limb D, Giannoudis PV. Radial nerve palsy associated with fractures of the shaft of the humerus: a systematic review. *J Bone Joint Surg Br*. 2005;87(12):1647–52.
20. Bono CM, Grossman MG, Hochwald N, Tornetta P. Radial and axillary nerves. Anatomic considerations for humeral fixation. *Clin Orthop Relat Res*. 2000;373:259–64.
21. Rocchi M, Tarallo L, Mugnai R, Adani R. Humerus shaft fracture complicated by radial nerve palsy: is surgical exploration necessary? *Musculoskelet Surg*. 2016;100(Suppl 1):53–60.
22. Schacher B, Schnick U, Böttcher R, Casper D, Eisenschenk A, Ekkernkamp A. Paresen des N. radialis bei Humerusschaftfrakturen. *Obere Extremität*. 2015;10(3):137–43.
23. Packer JW, Foster RR, Garcia A, Grantham SA. The humeral fracture with radial nerve palsy: is exploration warranted? *Clin Orthop Relat Res*. 1972;88:34–8.
24. Liu GY, Zhang CY, Wu HW. Comparison of initial nonoperative and operative management of radial nerve palsy associated with acute humeral shaft fractures. *Orthopedics*. 2012;35(8):702–8.
25. Lotzien, S., Hoberg, C., Rausch, V. et al. Open reduction and internal fixation of humeral midshaft fractures: anterior versus posterior plate fixation. *BMC Musculoskelet Disord* 20, 527 (2019). <https://doi.org/10.1186/s12891-019-2888-2>
26. Cheng, JCY & Shen, WY 1991, 'Limb fracture pattern in 2,500 children under age 12', *J Hong Kong Med Assoc*, vol. 43, pp. 230-234.

27. Chaudhary P, Karn NK, Shrestha BP, Khanal GP, Paneru S, Kalawar RPS. Dynamic compression plate versus intramedullary interlocking nail for management of humeral shaft fractures. *NOAJ*. 2013; 3:10-13
28. Modi N, Pundkar GN. Comparative study of functional outcome of dynamic compression plating with intramedullary interlocking nailing in close fracture shaft of humerus in adults. *J Res Med Dent Sci*. 2015; 3(4):298-302
29. Khan MS, Sahibzada AH, Khan AM, Sultan S, Younas M, Khan AZ. Outcome of plating, bone grafting and shortening of non-union humeral diaphyseal fracture. *J Ayub Med Coll Abbottabad*. 2005;17(2):44-6.
30. Gonçalves FF, Dau L, Grassi CA, Palauro FR, Neto AA, Pereira PC. Evaluation of the surgical treatment of humeral shaft fractures and comparison between surgical fixation methods. *Revista Brasileira de Ortopedia (English Edition)*. 2018; 53(2):136-41
31. Walker M, Palumbo B, Badman B, Brooks J, Gelderen JV, Mighell M. Humeral shaft fractures: a review. *J shoulder and elbow surg* 2011; 20:833-44
32. Khan AS, Afzal W, Anwar A. Comparison of shoulder function, radial nerve palsy and infection after nailing versus plating in humeral shaft fractures. *J Coll Physicians Surg Pak*. 2010;20:253-7.
33. Crates J, Whittle AP. Antegrade interlocking Nailing of acute Humeral Shaft Fractures. *J Clinic Orthop.*, 1998; 350: 40-50.
34. Ring, D, Percy, BH & Jupiter, JB 1999, 'The functional outcome of operative treatment of uniminated fractures of the humeral diaphysis in older patients', *Journal of Bone & Joint Surgery*, vol. 81, no. A, pp. 177-190.
35. Ring, D, Jupiter, JB, Quintero, J, Sanders, RA, Marti, RK 2000. 'Atrophic uniminated diaphyseal fractures of the humerus with a bony defect: treatment by wave-plate osteosynthesis', *Journal of Bone & Joint Surgery [Br]*, vol. 82, pp. 867-71.
36. Cocco LF, Ejnisman B, Belangero PS, Cohen M, dos Reis FB. Quality of life after antegrade intramedullary nail fixation of humeral fractures: A survey in a selected cohort of Brazilian patients. *Patient safety in surgery*. 2018; 12(1):4.

UNDER PEER REVIEW