

NOVEL TECHNIQUE IN LATE STAGE AVASCULAR NECROSIS OF LUNATE: TENDON INTERPOSITION AND LIGAMENT RECONSTRUCTION WITH ECRL TENDON. – A CASE REPORT

ABSTRACT

AIM: TO EVALUATE CLINICAL AND FUNCTIONAL RESULTS OF EXTENSOR CARPI RADIALIS LONGUS TENDON BALL INTERPOSITION FOR TREATMENT OF LATE STAGE AVASCULAR NECROSIS OF LUNATE (KIENBOCK'S DISEASE).

MATERIAL AND METHOD: PATIENT WITH STAGE 4 KIENBOCK'S DISEASE WAS TREATED WITH EXCISION OF LUNATE AND ECRL TENDON INTERPOSITION TO FILL THE CAVITY OF THE EXCISED LUNATE BONE. TENDON WAS SPLIT. ONE HALF WAS LEFT IN SITU AND THE OTHER WAS USED TO FILL THE CAVITY BY PASSING IT TO THE SCAPHOID AND TRIQUETRUM. THIS ALSO HELPS TO MAINTAIN INTERCARPAL STABILITY. FUNCTIONS WERE ASSESSED USING GRIP STRENGTH, RANGE OF MOVEMENT OF WRIST, QUICK DASH AND VISUAL ANALOGUE SCORE. RADIOLOGICAL EXAMINATION WAS PERFORMED TO ASSESS CARPAL HEIGHT RATIO AND PROGRESSION OF ARTHRITIS.

RESULT: LONG AND BULKY ECRL TENDON ACTS AS A SPACER TO FILL THE EXCISED LUNATE. IT ALSO PROVIDES SCAPHO LUNATE AND LUNATE TRIQUETRAL LIGAMENT RECONSTRUCTION FOR INTER CARPAL STABILITY.

CONCLUSION: ECRL TENDON USED FOR INTERPOSITION WITH RECONSTRUCTION SEEMS TO BE AN EFFECTIVE TREATMENT MODALITY FOR LATE STAGE OF KIENBOCK'S DISEASE.

1. INTRODUCTION

Keinbock's disease is a painful idiopathic disorder of the wrist resulting from vascular compromise to carpal lunate bone. The disease usually results in avascular necrosis and later on fragmentation of the lunate, collapse with shortening of the carpus and arthritic changes in proximal carpal area.

Keinbock's disease is commonly seen between 20-40 years age group with female predominance (F:M::2:1). The diagnosis is made from characteristic change seen in lunate on radiograms of the wrist and the severity of the disease can be categorised by staging the degree of involvement (Stahl staging). In early stage of Keinbock's disease treatment is conservative and includes immobilization, analgesics, and/or anti-inflammatory medication. If symptoms are not relieved then based on degree of involvement, several surgical options exist like, revascularisation, radial shortening, ulnar lengthening, intercarpal arthrodesis, autogenous tendon replacement arthroplasty and silicone replacement arthroplasty.

Here we describe novel technique of lunate excision with autogenous ECRL tendon ball interposition with stabilization with same mimicking ligament.

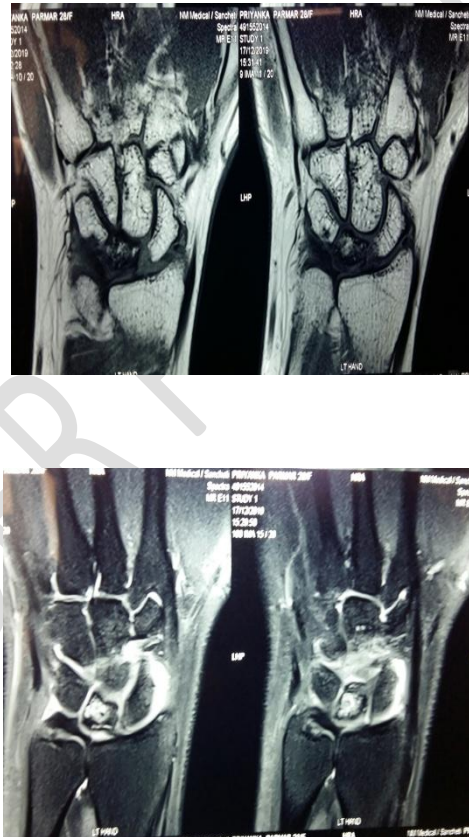

Image 1 : X-ray image

2. PRESENTATION OF CASE

A 28 year old female patient who presented with pain in her left wrist joint (dominant hand) since 8 months which was constant in nature, dull aching, non radiating and aggravated with movements like holding a bowl, combing hair and swiping floor. Patient had no history of trauma, fever, weight loss and loss of appetite. On examination – tenderness was present on watershed line of wrist joint.

On further examination, Range of movements in degree were as follow-

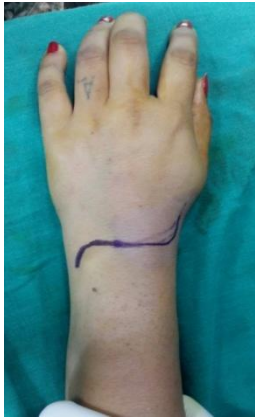Palmar flexion was 0-50 degree, Dorsiflexion was 0-40 degree, Ulnar deviation was 0-35 degree and Radial deviation was 0-10 degree.

Terminal palmar and dorsiflexion were painful. On admission VAS score was 9.

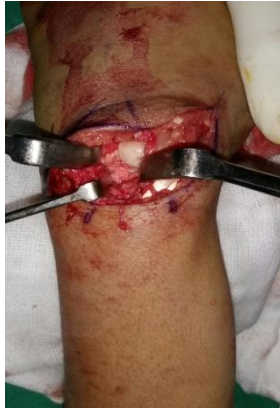TECHNIQUE:

After taking consent from patient, patient was taken to Operation theatre. Regional anaesthesia was given for left upper limb. Left upper limb was put on side arm support. Sterile painting and draping was done. Transverse incision made over dorsal aspect of wrist joint.

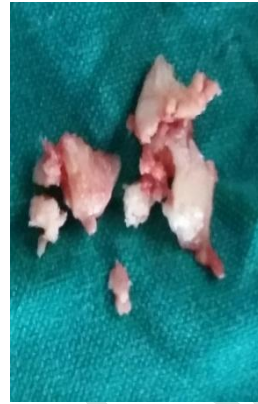- After superficial and deep dissection, wrist joint capsule opened in U-shaped and lunate was excised in piece meal.
- Extensor Carpi Radialis Longus tendon was identified in middle 1/3rd of forearm which was cut at musculotendinous junction and the tendon was harvested.
- After that tendon was split into two parts and the tendon strip was obtained.
- Then two holes of 2.7mm were drilled to the triquetrum and to the proximal scaphoid and the tendon strip obtained from ECRL tendon was passed through these holes.
- The coiled tendon was inserted into the cavity of excised lunate, and the tendon strip was sutured onto itself over the coiled tendon with prolene material.
- The remaining half of tendon was reinserted back to its original position.



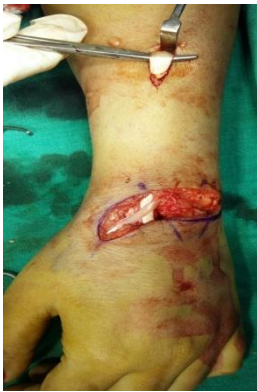Picture 1. Incision over dorsal aspect



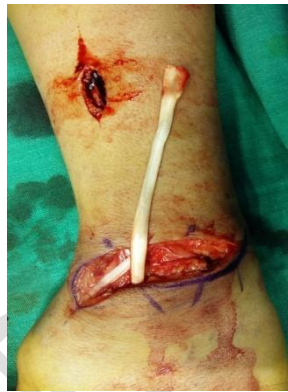Picture 2. Superficial and deep dissection



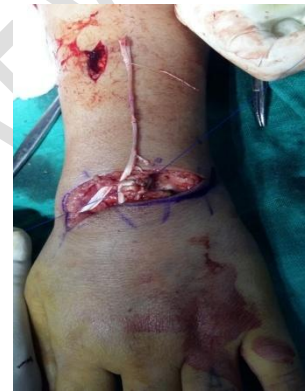Picture 3. Excised Lunate



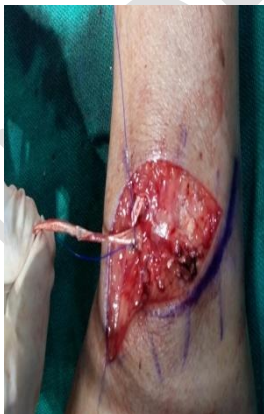Picture 4. ECRL Tendon exposed



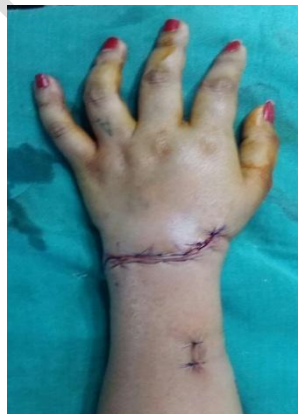Picture 5. Harvested ECRL Tendon



Picture 6. Tendon ball interposition



Picture 7. Tendon fixation



Picture 8. Closure

FOLLOW-UP:

Immediate post-op X-ray:

Immediate post operatively below elbow cast was given and suture removal was done after 1.5 months. Patients clinical function was assessed using grip strength, ROM of wrist and VAS score (visual analogue scale). On 12 months follow up - range of movements with functional activities pain free and VAS score improved from 9 to 1.

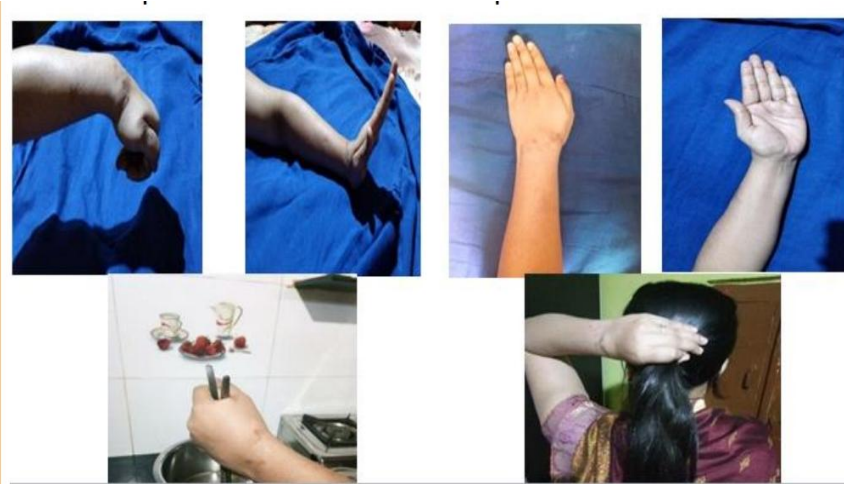


Figure 1 Range of movements recovery

DISCUSSION:

Definite treatment of Kienbock's disease with stages 3B and 4 can be done through such a surgical modality which would relieve the pain and maintain normal wrist function as much as possible. The ideal procedure for the treatment of Kienbock's disease should preserve biomechanics of the wrist as much as possible. To maintain grip strength, increased range of motions, and prevent carpal collapse, the space created after lunate excision has been filled with tendon, fascia and various materials such as steel, ivory, silicon and pyrocarbon.

In this study, for the treatment in the late stage of the disease, lunate was excised to relieve pain and autogenous material – ECRL tendon was used to fill the space. A strip obtained from the same tendon was passed through the scaphoid and the triquetrum to act as a ligament to prevent scaphoid rotation and to preserve proximal row integrity. ECRL tendon is preferred as it is longer and thicker than Palmaris longus, which would prevent further carpal collapse more effectively. The Extensor Carpi Radialis Tendon which lies in the same anatomic region and has similar morphological properties was not utilised, because of its centralising effect for the wrist. The function of the thumb had improved, and wrist motion and strength was not affected after sacrificing ECRL tendon. Also, use of autogenous material prevents chronic irritation findings that may be observed in silicon implant reconstruction.

CONCLUSION:

Use of ECRL tendon interposition for the excised space has minimum chances of carpal bone collapse and provides better wrist stability as compared to silicon prosthesis which has more chance of collapse and scaphoid rotation. This technique is cost effective as compared to other techniques.

ETHICAL APPROVAL: all experiments have been examined and approved by the appropriate ethics committee and have therefore been performed in accordance with the ethical standards laid down in the 1964 Declaration of Helsinki.

LIMITATION:

In order to study the complications of arthritic changes, proximal row carpal bone collapse, recurrence in symptoms found in Kienbock's disease, we need a larger sample number with frequent follow up visits.

REFERENCES:

- [1] K.H. Watson, J.Ryu, and A.Dibella, "An approach to kienbock's disease:triscaphe arthrodesis," Journal of hand surgery, vol.10, no.2, pp.179-187,1985.
- [2]P.J.King, W.A.Eglseder Jr., and H.O.House, "Extensor Carpi Radialis Longus tendinoplasty for thumb basal joint arthritis," American journal of Orthopaedics,vol.30,no.3,pp.213-219,2001.
- [3]A.H.Alexander, A.M.Turner, C.E.Alexander, and D.M. Lichtman, "Lunate silicone replacement arthroplasty in Kienbock's disease: a long term follow up," The journal of hand surgery,vol.15, pp. 401-407,1990.