

Original Research Article

THE CYTOLOGICAL ASPECT OF CLINICALLY CONCERNED SUPRACLAVICULAR LYMPHADENOPATHY- A PROSPECTIVE STUDY.

ABSTRACT

Aims: The purpose of the study was to find out the distribution of disease in supraclavicular lymphadenopathy in fine-needle aspiration cytology smears and to study cytomorphological findings in detail.

Study design: The present study was a prospective study done at a teaching hospital.

Place and Duration of Study: Department of Pathology, Dr. DY Patil medical college and research centre, DY Patil Vidyapeeth, Pune, Maharashtra, India, and the study was done between September 2019 to August 2021.

Methodology: Fine needle aspiration cytology (FNAC) was performed on 50 cases of supraclavicular lymphadenopathy with aseptic precautions and after taking written consent. **Results:** A total of 50 aspirates were studied. The male to female ratio was 2:3. The age of the patients ranges from 9yr to 81yrs. The maximum number of cases were found in the old age group (>60yrs) and on the right side. Diagnosis based on FNAC findings were categorized as metastatic deposits (34% cases), tubercular

lymphadenitis (16% cases), reactive lymphadenitis (14% cases), granulomatous lymphadenitis (14% cases), acute suppurative lymphadenitis (12% cases), necrotizing lymphadenitis (8% cases) and one NHL (2% case).

Squamous cell carcinoma (14% cases) was the commonest in metastatic lesions followed by adenocarcinoma (10% cases). Common primary sites were the breast, lung, and gall bladder for adenocarcinoma, whereas the esophagus and tongue for squamous cell carcinoma.

Conclusion: Supraclavicular nodes are well known for metastasis but non-malignant etiologies like tuberculosis are frequently found in developing countries. Enlarged supraclavicular nodes suggest some underlying pathology and chances of malignancy increase with the age of the patient. FNAC can be used as a first-line investigation for diagnosis because of its simplicity, cost-effectiveness, and efficacy to rule out metastasis.

Keywords: Supraclavicular lymphadenopathy, FNAC, Metastatic supraclavicular lymph nodes, Tubercular supraclavicular nodes.

1. INTRODUCTION

Lymphadenopathy is one of the commonest presenting symptoms of all age groups attending the outpatient department. In general practice < 1 % of patients with palpable lymphadenopathy have a malignant process [1].

The involvement of cervical lymph nodes is more common than in other lymph nodes groups in various diseases. FNAC is used as the first line of investigation in lymphadenopathy [2-5].

Supraclavicular nodes are also known as "Sentinel Node" because of their affinity for metastasis. Left supraclavicular nodes are also known as Virchow's nodes and are known for gastric malignancies metastasis. Clinically appreciable Virchow's node is called the Troisier sign [6].

Metastatic malignancies were found to be a major cause of supraclavicular lymphadenopathy in many studies. But benign causes like tuberculosis were also found in major proportions in developing countries. Metastatic squamous cell carcinoma with primary in the oral cavity is most often seen [7].

In supraclavicular nodes, diagnostic sensitivity (80%) of FNAC was lower than in other cervical lymph nodes (91.3%) [8].

The purpose of the study was to find out the distribution of disease in supraclavicular lymphadenopathy in fine-needle aspiration cytology smears and to study cytomorphological findings in detail.

2. MATERIAL AND METHODS / EXPERIMENTAL DETAILS / METHODOLOGY

| Age (in years) | Female n (%) | Male n (%) | Total n (%) |
|----------------|-----------------|---------------|----------------|
|----------------|-----------------|---------------|----------------|

September 2019 to August 2021.

The present study is a prospective study. This study was carried out in the Department of Pathology at a teaching medical hospital from

INCLUSION CRITERIA: All cases of clinically or radiologically diagnosed supraclavicular lymphadenopathy. Adequate smears were included only.

EXCLUSION CRITERIA: Diagnosed cases of Supraclavicular lymphadenopathy previously on FNAC or histopathology. Detailed clinical history including radiological findings was noted from the case file and a short clinical examination was done. After explaining the procedure in their language, written consent was taken for FNA from the patient.

With all aseptic precautions, FNA was done with a 22- or 23-gauge needle using a 10ml disposable syringe. The 4 to 6 passes were given. The needle is withdrawn, and the material was then smeared onto the glass slides. In cases in which material does not come those patients were subjected to repeat aspiration. The smears of the aspirated material were air-dried, stained, and reported based on their microscopical findings.

Smears were routinely stained with Leishman's Stain and Hematoxylin-Eosin Stain. ZN stain was used in clinically suspected cases of Tubercular lymphadenitis & in FNAC Smears which showed epithelioid cells granuloma or caseous necrosis. Special stains like GMS were used as required. Detailed cytomorphological features were studied and correlated with clinical findings. FNA diagnoses based on cytomorphological features were categorized as reactive lymphadenitis, suppurative lymphadenitis, necrotizing lymphadenitis, granulomatous lymphadenitis, tubercular lymphadenitis, non-Hodgkin lymphoma, and metastatic deposits.

3. RESULTS

Table 1: Age and Sex wise distribution of cases.

| | | | |
|---------------|-----------------|-----------------|------------------|
| 1-10 | 0 (0 %) | 0 (0%) | 0 (0%) |
| 11-20 | 7 (14%) | 2 (4%) | 9 (18%) |
| 21-30 | 4 (8%) | 3 (6%) | 7 (14%) |
| 31-40 | 6 (12%) | 3 (6%) | 9 (18%) |
| 41-50 | 5 (10%) | 1 (2%) | 6 (12%) |
| 51-60 | 3 (6%) | 3 (6%) | 6 (12%) |
| >60 | 5 (10%) | 8 (16%) | 13 (26%) |
| TOTAL | 30 (60%) | 20 (40%) | 50 (100%) |

A total of 50 cases of supraclavicular lymphadenopathy were subjected to FNA. Out of 50 cases, 20 cases were male, and 30 cases were female.

The right supraclavicular lymph node was more frequently involved (52% cases) than the left supraclavicular node (46% cases). Bilateral involvement was seen in 2% of cases. Non-malignant etiology was found in 32 cases and malignant etiology in 18 cases.

In 20% of cases size of the lymph node was <1cm, in 40% of cases 1-2 cm and 40% of cases the size was more than 2 cm, The smallest lymph node measured 0.5 cm, and the largest measuring 5cm in the largest dimension.

Table 2A: Distribution of cases based on FNAC diagnosis

| FNAC DIAGNOSIS | NUMBER OF CASES=50 | % OF CASES |
|---------------------------------|--------------------|------------|
| REACTIVE LYMPHADENITIS | 7 | 14 |
| ACUTE SUPPURATIVE LYMPHADENITIS | 6 | 12 |
| GRANULOMATOUS LYMPHADENITIS | 7 | 14 |
| TUBERCULAR LYMPHADENITIS | 8 | 16 |
| NECROTISING LYMPHADENITIS | 4 | 8 |
| METASTATIC DEPOSITS | 17 | 34 |
| LYMPHOMA (NHL) | 1 | 2 |
| TOTAL | 50 | 100 |

Table 2A summarizes the FNAC diagnosis of cases in which metastatic deposits

were the commonest diagnosis, followed by tubercular lymphadenitis (Figure 1B), reactive lymphadenitis (Figure 1A), granulomatous lymphadenitis, acute suppurative lymphadenitis (Figure 1D), necrotizing lymphadenitis (Figure 1C), and one case of NHL (Fig 3A&B).

Table 2B– FNAC diagnosis according to Age-Sex-

| Age (years) | Acute suppurative Lymphadenitis | | Reactive Lymphadenitis | | Granulomatous Lymphadenitis | | Tubercular Lymphadenitis | | Necrotizing Lymphadenitis | | Metastatic deposits | | NHL |
|-------------|---------------------------------|---|------------------------|---|-----------------------------|---|--------------------------|---|---------------------------|---|---------------------|---|-----|
| | M | F | M | F | M | F | M | F | M | F | M | F | |
| 0-10 | 0 | 0 | 0 | 0 | 0 | 0 | 0 | 0 | 0 | 0 | 0 | 0 | 0 |
| 11-20 | 1 | 2 | 1 | 0 | 0 | 1 | 0 | 2 | 0 | 1 | 0 | 1 | 0 |
| 21-30 | 0 | 1 | 1 | 1 | 1 | 0 | 1 | 2 | 0 | 0 | 0 | 0 | 0 |
| 31-40 | 1 | 1 | 0 | 0 | 0 | 2 | 1 | 1 | 0 | 1 | 1 | 1 | 0 |
| 41-50 | 0 | 0 | 0 | 1 | 0 | 1 | 0 | 1 | 1 | 1 | 1 | 1 | 0 |
| 51-60 | 0 | 0 | 2 | 1 | 0 | 0 | 0 | 0 | 0 | 0 | 1 | 2 | 0 |
| >60 | 0 | 0 | 0 | 0 | 0 | 2 | 0 | 0 | 0 | 0 | 5 | 4 | 1 |
| Total | 06 | | 07 | | 07 | | 08 | | 04 | | 17 | | 01 |

Table 2 shows FNA diagnosis in various sex and age groups.

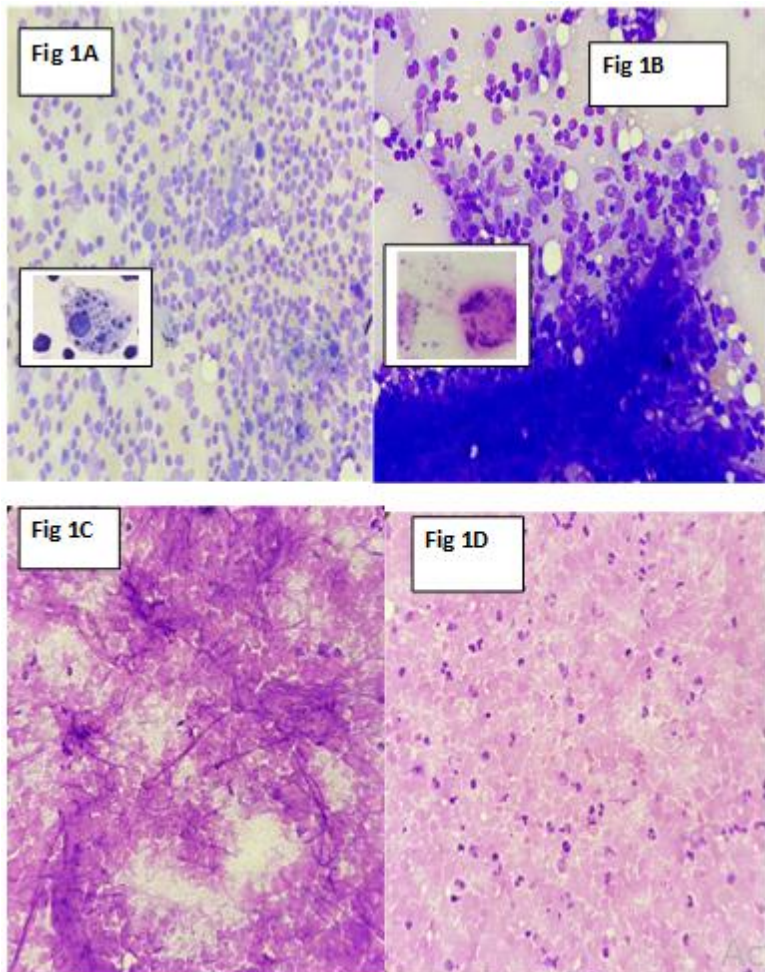
Acute suppurative lymphadenitis, Necrotizing lymphadenitis, and tuberculosis are more common in females. Tuberculosis is more common in the 11-30 years of age group. Metastatic deposits show the same male to female ratio but most commonly found in more than 60 year of age.

Table 3 – Supraclavicular lymph node malignancies with laterality and primary sites.

| FNAC DIAGNOSIS | Primary Site | Left | Right | Bilateral | Total |
|---------------------------------|--------------|------|-------|-----------|-------|
| Adenocarcinoma | Unknown | 0 | 1 | 0 | 1 |
| | Breast | 1 | 1 | 0 | 2 |
| | Lung | 0 | 1 | 0 | 1 |
| | Gall bladder | 1 | 0 | 0 | 1 |
| Squamous Cell Carcinoma | Unknown | 2 | 3 | 0 | 5 |
| | Oesophagus | 0 | 1 | 0 | 1 |
| | Tongue | 0 | 1 | 0 | 1 |
| Poorly differentiated carcinoma | Unknown | 3 | 1 | 0 | 4 |
| Round cell tumor | Unknown | 0 | 1 | 0 | 1 |
| NHL | | 0 | 0 | 1 | 1 |
| Total | | 7 | 10 | 1 | 18 |

Table 3 shows squamous cell carcinoma (Figure 2A) was the commonest in metastatic lesions followed by adenocarcinoma (Figure 2B), poorly differentiated carcinoma (Figure 2C), and round cell tumor (Figure 2D). In primary malignancy, a single case of NHL (Figure 3A&B) was also found.

It was found that metastatic involvement was more on the right side (10 cases) than the left side (7 cases). Common primary sites were breast, lung, gall bladder for adenocarcinoma, whereas esophagus and tongue for squamous cell carcinoma. In the remaining cases, the primary was unknown. The right-side involvement was more than the left side.



Legends of figures 1--

Figure.1A-Shows a polymorphous population of lymphocytes in reactive lymphadenitis, inset shows tangible body macrophage, Leishman stain, x400.

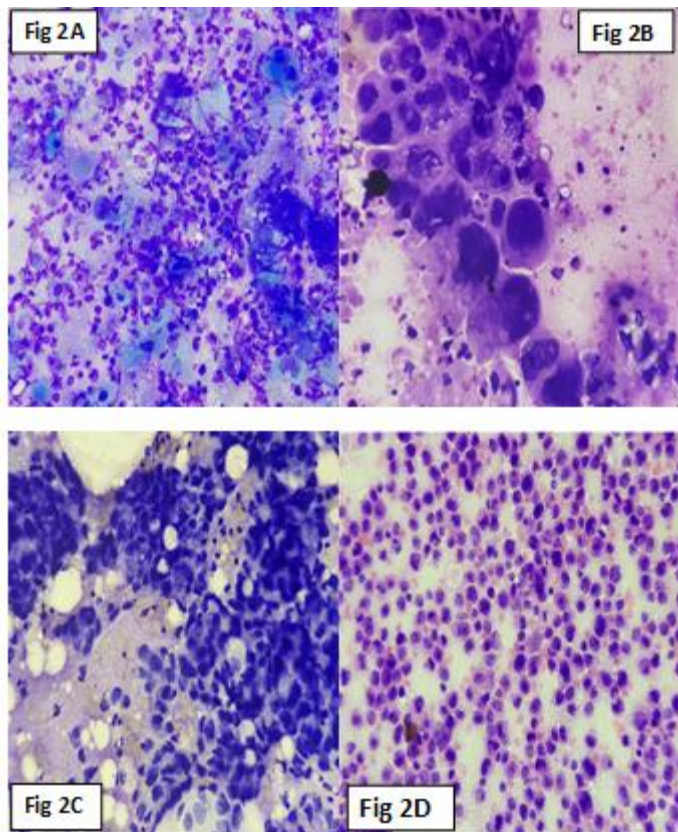
Figure 1B- Granulomatous lymphadenitis (Tuberculosis)- showing epithelioid granuloma with caseous necrosis.

Langhan's type giant cell in inset Leishman stain, x400.

Figure 1C- Showing necrotizing lymphadenitis, Leishman stain, x400.

Figure 1D- Shows suppurative lymphadenitis showing neutrophils with cell debris, H&E stain, X400.

UNDER PEER REVIEW



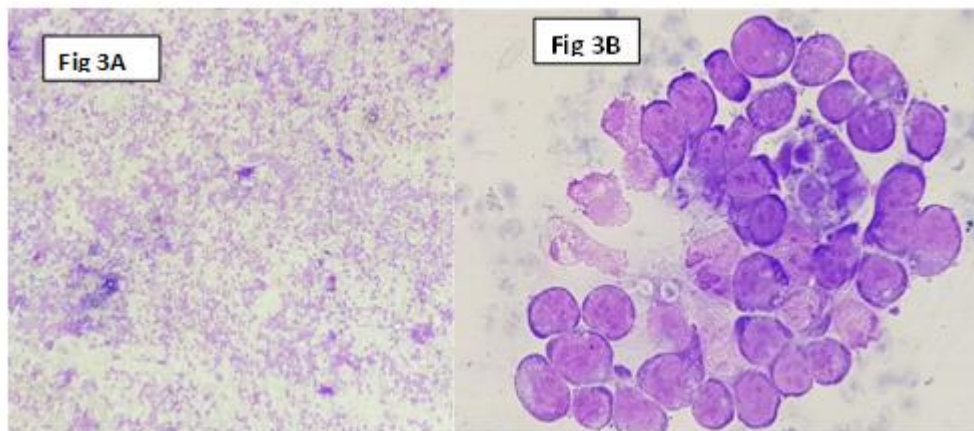
Legends of figures 2--

Figure 2A- Metastatic deposit of squamous cell carcinoma, shows pleomorphic hyperchromatic nuclei with atypia and keratinization, Leishman stain, x400.

Figure 2B- Metastatic deposit of adenocarcinoma showing large cells with increase N: C ratio, hyperchromatic nuclei, cytoplasmic vacuolization, and prominent nucleoli, Leishman stain, x400.

Figure 2C – Metastatic deposits of poorly differentiated carcinoma, showing marked nuclear pleomorphism, hyperchromasia in the lymphoid background, Leishman stain, x400.

Figure-2D- Metastatic round cell tumor, showing round cells with increased N: C ratio and hyperchromatic nucleus, pleomorphic nuclei with atypia, scant pale blue.H&E stain, x400.



Legends of figures 3—

Figure 3A-Shows monomorphous population of large lymphoid cells in non-Hodgkin lymphoma, Leishman, x100.

Figure 3B-Shows large lymphoid cells with increased N: C ratio and prominent nucleoli in non-Hodgkin lymphoma, Leishman, x400.

DISCUSSION

Enlarged supraclavicular nodes are generally palpable and are known for metastatic deposits either in a known case of malignancy or it can present as a primary complaint of underlying unknown malignancy.

Supraclavicular lymphadenopathy is always a concern for clinicians and pathologists. Although these lymph nodes were known for metastatic malignancies, benign or treatable causes are not uncommon findings.

FNAC is an important tool for diagnosing a case of lymphadenopathy as it is a cost-effective and simple procedure without any major complication as seen in the surgical biopsy. Diagnosis is rapid as compared to biopsy and multiple nodes from different anatomical sites can be sampled simultaneously, which is a great advantage in many cases [2,9].

The importance of FNAC in supraclavicular lymphadenopathy was already shown in several studies [9,10].

In this study of 50 cases of supraclavicular lymphadenopathy, we found M: F ratio was 2:3 and the mean age of presentation was 46 years. The maximum number of cases were found in the age group of more than 60 years of age. These findings are comparable with Sumit et al [7].

Right-sided lymph nodes were more involved than left-sided nodes in the present study. This finding shows concordance with Adhikari et al and Sujata et al. Malignant lesions were more common in larger lymph nodes as compared to small non-palpable nodes as shown in other studies (16% cases with size more than 2cm in greatest diameter) [9,12].

In the present study, benign aetiologies collectively dominated over malignancy. In 50 cases, 32 (64 %) were of benign nature, and 18 (36 %) were of malignancies. Similar results were found in the study conducted by Sujata et al in which benign lesions (55.6% of cases) were more common than malignant lesions (44.4 % of cases).

Another study by Adhikari et al showed 49.6 % of cases were of malignancies [9,12]. As supraclavicular lymph nodes are known for metastatic malignancy and always concerning for pathologists as well as clinicians.

The finding of 64 % of benign causes is somewhat more as expected in supraclavicular lymphadenopathy.

Collectively necrotic, suppurative, granulomatous, and tubercular lymphadenitis was considered benign.

Although some tumors can cause necrosis or degenerative changes like squamous cell carcinoma and can be missed on cytology in the absence of atypical cells. Tuberculosis cannot be ignored in these cases even with a negative ZN stain in developing countries, and cases should be investigated further based on clinical findings.

TB-PCR/CBNAAT (cartridge-based nucleic acid amplification test) can be done in clinically suspected cases of tuberculosis. Tubercular lymphadenitis was the second most common finding (16% of cases) in this study and was confirmed by ZN stain and culture. Similar findings were seen in a study conducted by Gupta N et al [11].

TB was more prevalent in the 20 years to 40 years of age group with female predominance and these findings were concordant with the previous studies like Kumar H et al, Adhikari et al and Chandanwale SS et al [5,12,17].

Metastatic malignancies (17/50, i.e.,34%) were the most common cause of supraclavicular lymphadenopathy in the present study which is in concordance with other studies like Sumit et al and Gupta N. et al [7,11].

Metastatic malignancies were more common after 60 years of age (52.9% of cases) with male predominance and these findings were concordant with the study conducted by Mitra et al and Laishram et al [7,14].

Among the metastatic malignancies squamous cell carcinoma was the most common metastatic lesion, (41.1%) followed by metastatic adenocarcinoma, (29.7%) which corroborates well with the study done by Mitra et al and Adhikari et al [7,12].

In this study, right-sided supraclavicular lymph node involvement was more (10 cases, 58.8 %) as compared to the left side (7 cases, 41.1 %) in metastatic malignancies. 5 out of 7 cases of squamous cell carcinoma, 3 out of 5 cases of adenocarcinoma, 1 out of 4 cases of poorly differentiated carcinoma, and 1 case of round cell tumor showed right-sided supraclavicular lymph node involvement. 2 out of 7 cases of squamous cell carcinoma, 2 out of 5 cases of adenocarcinoma and 3 poorly differentiated carcinoma showed left side supraclavicular involvement. Right side involvement was more in the case of Squamous cell carcinoma in our study and this finding showed concordance with the study conducted by Carson et al [13].

Common primary sites were the tongue, lung, breast, stomach, and esophagus which metastasizes to supraclavicular nodes. The primary origin of malignancies metastasizing to supraclavicular nodes in our study was well corroborated with the study conducted by Gupta et al., Adhikari R et al. and Van et al [2,12,16].

A single case of metastatic round cell tumor of unknown primary was found with right supraclavicular lymphadenopathy in a 60-year-old male patient. On further radiological and histopathology examination it was diagnosed as small cell carcinoma lung.

Lymphoid malignancies are far less common than metastatic malignancies in supraclavicular nodes as shown in several studies [9,12,14]. Supraclavicular nodes are the least common site of involvement in lymphoid malignancies with respect to other lymph nodes [15]. In this study, a single case of non-Hodgkin's lymphoma was diagnosed on FNAC and was further subclassified as DLBCL on histopathology examination of excised lymph nodes with the help of immunohistochemical staining and flow cytometry.

Out of 4 cases of necrotizing lymphadenitis diagnosed on FNAC, 2 cases were further diagnosed as Kikuchi Fujimoto disease on histopathological examination. Other 2 cases were diagnosed with Tubercular lymphadenopathy.

In acute suppurative lymphadenitis cases, aspirates were sent for culture and gram staining and they came positive for bacterial etiology in 5 out of 6 cases. The other 1 case turned out to be a positive culture of Tuberculosis.

In 7 cases of noncaseating granulomatous lymphadenitis, a fungal stain (Grocott gomori methenamine silver stain) was done, and all came negative for fungus. In 2 out of 7 cases diagnosis of tuberculosis was confirmed on lymph node biopsy. Further investigations can be done in clinically suspected cases of tuberculosis diagnosed as granulomatous lymphadenitis on FNAC.

5 out of 7 cases of reactive lymphadenitis showed clinical evidence of infection in the head and neck region. In the remaining 2 cases, follow-up and biopsy were suggested if needed clinically.

4. CONCLUSION

Enlarged supraclavicular nodes suggest some underlying pathology and chances of malignancy increase with the age of the patient. Fine needle aspiration cytology can be used as a first-line investigation due to its simplicity, cost-effectiveness, and rapid results. The extent of malignancy found in supraclavicular lymphadenopathy varies and it depends on at what level the patient is getting treatment, generally benign treatable causes don't come to tertiary centres, and malignancies are more frequently attended.

8.CONSENT (WHERE EVER APPLICABLE)

All authors declare that informed consent was taken for publication and accompanying images.

ETHICAL APPROVAL (WHERE EVER APPLICABLE)

Ethical approval was provided by Institutional Ethical committee with Ref. No.-LESC/282/2019.

REFERENCES

- 1). Kasper DL, Fauci AS, Hauser SL, Longo DL, Jameson JL, Loscalzo J. Harrison's principles of internal medicine,20/E (Vol 1 & Vol 2) (eBook). New York: The McGraw-Hill Companies, 2018, Page 411-13.
- 2) Gupta RK, Naran S, Lallu S, Fauck R. The diagnostic value of fine needle aspiration cytology (FNAC) in the assessment of palpable supraclavicular lymph nodes: a study of 218 cases. Cytopathology. 2003;14(4):201-7.

- 3) Gupta M, Singh K. Correlation of fine needle aspiration cytology lymph node with histopathological diagnosis. *Int J Res Med Sci.* 2016;4719-4723.
- 4) Hirachand S, Lakhey M, Akhter J, Thapa B. Evaluation of fine needle aspiration cytology of lymph nodes in Kathmandu Medical College, Teaching hospital. *J. Kathmandu Med. Coll.* 2009;7(26):139-42.
- 5) Kumar H, Pagaro P, Buch A, Chandanwale S, Gore C, Satav V. Role of fine needle aspiration cytology in assessment of cervical lymphadenopathy. *Med J DY Patil Vidyapeeth.* 2013;6(4):400.
- 6) Zdilla M, Aldawood A, Plata A, Vos J, Lambert H. Troisier sign and Virchow node: the anatomy and pathology of pulmonary adenocarcinoma metastasis to a supraclavicular lymph node. *Autopsy and Case Reports.* 2019;9(1).
- 7) Mitra S, Mitra P, Ray S. Fine needle aspiration cytology of supraclavicular lymph nodes: Our experience over a three-year period. *J. Cytol.* 2011;28(3):108.
- 8) Lee J. Usefulness and Limitations of Fine Needle Aspiration Cytology in Adult Cervical Lymph Node Enlargement Patients: An analysis of 342 cases. *Tuberc Respir Dis.* 2004; 56(1):18-28.
- 9) Kanetkar S. Supraclavicular lymphadenopathy: Cytopathological study of 3 years with Review of Literature. *J. med. sci. clin. res.* 2017;5(11).
- 10) Nasuti JF, Mehrotra R, Gupta PK. Diagnostic value of fine-needle aspiration in supraclavicular lymphadenopathy: a study of 106 patients and review of literature. *Diagn.Cytopathol.*2001; 25:351-5.
- 11) Gupta N, Rajwanshi A, Srinivasan R, Nijhawan R. Pathology of supraclavicular lymphadenopathy in Chandigarh, north India: an audit of 200 cases diagnosed by needle aspiration. *Cytopathology.* 2006 ;17(2):94-6.
- 12) Adhikari RC, Jha A, Sayami G, Srestha S, Sharma Sk. Fine needle aspiration cytology of palpable supraclavicular lymph nodes.*J. Pathol Nepal* 2011;1:8-12.
- 13) Carson HJ, Candel AG, Gattuso P, Castelli MJ. Fine-needle aspiration of supraclavicular lymph nodes. *Diagn. Cytopathol.* 1996;14(3):216-220.
- 14) Laishram RS, Devan R M, Laishram S, Sharma DC. Pattern of disease in palpable supraclavicular lymph node: A cytopathological perspective. *J Med Soc* 2012; 26:163-6
- 15) Laurent C, Do C, Gourraud PA, de Paiva GR, Valmary S, Brousset P. Prevalence of Common Non-Hodgkin Lymphomas and Subtypes of Hodgkin Lymphoma by Nodal Site of Involvement: A Systematic Retrospective Review of 938 Cases. *Medicine (Baltimore).* 2015 ;94(25):e987.

16) Van Overhagen H, Brakel K, Heijenbrok MW, van Kasteren JH, van de Moosdijk CN, Roldaan AC, van Gils AP, Hansen BE. Metastases in supraclavicular lymph nodes in lung cancer: assessment with palpation, US, and CT. Radiology. 2004; 232(1):75-80.

17) Chandanwale S, Buch A, Verma A, Shruti V, Kulkarni S, Satav V. Evaluation of granulomatous lymphadenitis on fine needle aspiration cytology- diagnostic dilemma. Int J Pharm Bio Sci. 2014;5(4):377-84

DEFINITIONS, ACRONYMS, ABBREVIATIONS

Not applicable