

Case study

Healing of a Large Periapical Cystic Lesion of Endodontic Origin Following Nonsurgical Retreatment and Low-level laser therapy: A case report

Abstract:

Long-term success of root canal treatment(RCT) is dependent on sufficient and appropriate cleaning and shaping of the root canal system along with 3 dimensional obturation. This article aims to report a non-surgical and orthograde endodontic retreatment of mandibular right central incisor with a large radicular cyst progression related to endodontic origin in a 51-year-old male. The signs (sinus tract) and symptoms ceased after treatment. Bone formation Complete healing of the periradicular lesion was observed at the two-year follow-up examination. The appropriate diagnosis of periradicular lesion and the treatment of root canal system allowed complete healing of large lesions without endodontic surgery.

Keywords: Cyst; Diode laser; endodontic therapy; intracanal irradiation; Nonsurgical; periapical lesion.

Introduction:

Microorganisms might colonize the pulp tissue after it loses its blood supply as a result of trauma, resulting in periradicular pathosis. Pulp exposures can lead to pulp necrosis and periradicular pathosis (1). Periradicular lesions are usually found during routine radiographic examinations or followed by patient's extreme pain sensation. The classification of periapical lesions into abscesses, granulomata and cysts is common knowledge . The incidence of cysts, granulomas and abscesses varies from 6- 55% , 9.3-87.1 % and 28.7-70.07% , respectively(2). According to clinical evidence, lesions that are larger in size, are most likely radicular cysts. Still, some of these large lesions may appear to be granulomas.

Persistent periapical radiolucency after endodontic treatments may decrease, remain unchanged, or increase over time. (3)Clinicians should consider factors including the quality of the RCT and the patient's symptoms before intervention. The decisions were made according to the probing depth, attached gingiva level, tooth mobility, pain, clinical signs, quality of canal filling, and periapical lesion size and location. In some situations, the patient may not want to receive intervention because of a lack of discomfort.

Non-surgical retreatment is usually the treatment of choice though occasionally periradicular surgery may be the treatment of choice, or even extraction may be necessary to allow the lesion to heal (4,5).Especially in cases of improper or defective filling of the canal system, the root canal and periapex should respond to orthograde treatment.(6) The choice of treatment approach

should be based upon the patient's clinical situation and preference, operator's experience and skill, the risk of complications, and the technical feasibility and cost.(4,7)

Laser was introduced to endodontics to improve the results acquired by traditional methods. Different wavelengths have been shown to be effective in reducing bacteria in the root canal system(8). Diode laser is an option for root canal disinfection acting through thermal effect. Diode lasers have gained importance in dentistry based on their affordability and small size.(9) Different studies reported that the use of diode laser for bacterial decontamination produced different success rates dependent on the amount of energy applied and dentin thickness.(8)

The following case report describes an orthograde endodontic retreatment of mandibular central incisor associated with a large cyst-like periradicular lesion.

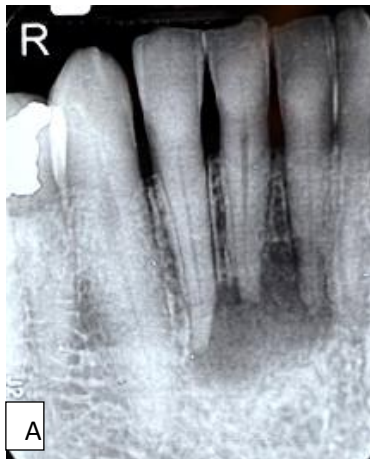Clinical Report

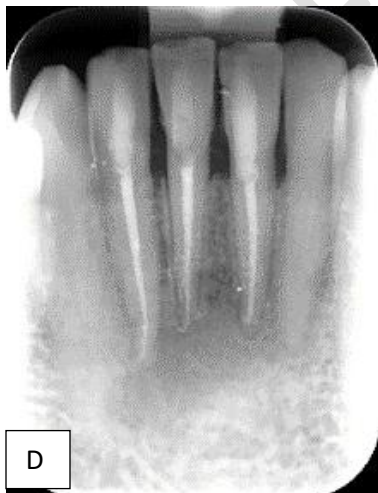
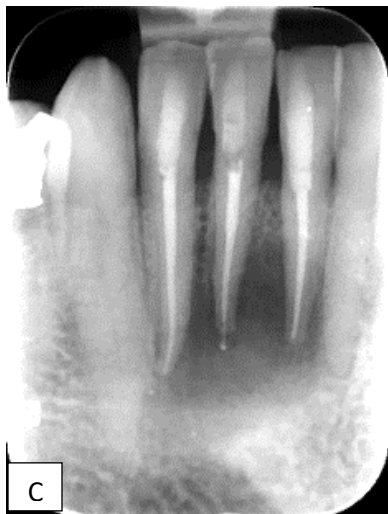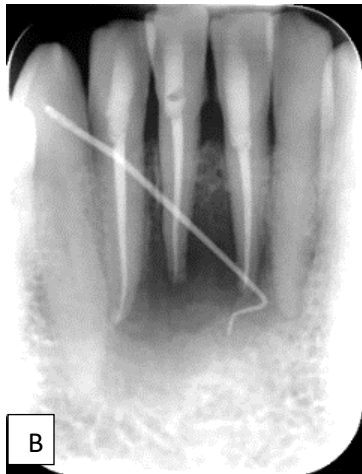
A 51-year-old man with no relevant medical history presented into private practice with the complaint of yellow discolored tooth #41 and pus drainage in the mandibular left anterior region since root canal treatment of teeth # 32 , 31 and 41 in 2019. He gave the history of trauma about 21 years ago and root canal treatment of teeth # 32 , 31 and 41 about 1 year ago.(Figure 1.A) The patient was unable to produce previous treatment records or recall all treatment details. Clinical examination revealed a sinus tract in labial vestibule. Extra-oral examination revealed no facial swelling nor palpable lymph nodes. Intra-oral examination showed no injury to soft tissues, no bleeding. Thermal and electrical pulp tests (EPT) (Analytic Technology, Redmond, WA, USA) were done, which elicited negative responses. Palpation produced purulent exudates .The teeth were non mobile. Radiographic evaluation demonstrated adequate RCT with a large unilocular radiolucent lesion measuring approximately the size of 16 mm × 12 mm associated with the teeth # 32,31 and 41. Gutta-percha cone was used to trace the path of sinus tract by periapical x-ray .(Figure 1.B)Taking into account the medical and dental history of the patient, provisional diagnosis of previously treated pulp with chronic apical abscess was made. The patient was offered three treatment choices – nonsurgical endodontic retreatment, periapical surgery, or extraction and prosthetic replacement. Nonsurgical endodontic retreatment of only tooth #41 was planned for the case. The patient was explained the treatment procedures to be performed, to which he agreed readily and signed the informed consent form. After administering local anesthesia (infiltration of 2% Lidocain with 1:80000 epinephrine, Darou Pakhsh, Iran) , endodontic access opening on the tooth #41 was done after rubber dam application. The old gutta percha removed (utilizing Gates Glidden drills, hand instrumentation with Hedstrom files and *Eukalyptol* gutta-percha solvent). Working length(WL) determined with Root-ZX electronic apex locator(J. Morita USA, Inc., Irvine, CA, USA)) and reconfirmed with the help of X-ray. There was no exudate from the canal. Biomechanical preparation of apical third was done up to ISO size #35 K-file(Dentsply Maillefer, Ballaigues, Switzerland), maintaining the apical patency. During the preparation, copious 5.25% sodium hypochlorite(NaOCl) solution using 30 G Max-i-Probe needle (Dentsply-Rinn, Elgin, IL, USA) was used as the intracanal irrigant which was activated with endoactivator(Dentsply Tulsa Dental Specialties, Tulsa, OK).The H- files were liberally coated with RC-Prep gel (Nikdarman,Iran)throughout instrumentation. The canal was enlarged by circumferential filling. After chemomechanical preparation and drying of root

canal system, a creamy mixture of calcium hydroxide (Golchadent, Tehran, Iran) and 2% chlorhexidine (gel) were placed in the canal with lentulo spiral (Dentsply Maillefer, Ballaigues, Switzerland) and retained for 10 days. Access cavity was sealed with a temporary filling material (Coltsol, Coltene, Altstätten, Switzerland). In the next visit, the sinus tract disappeared completely. The canal was cleaned with 2.25% NaOCl solution passively and final rinses of 17% EDTA (Nikdarman, Iran) were given followed by normal saline. Diode laser irradiation (output power of 2.5 W, continuous wave mode, 10-m s pulse duration, and 10-m s pulse interval.) is performed as a final step for decontaminating the root canal system before obturation. The canal filled with NaOCl, an optical fiber with 200 μm diameter of 940-nm diode laser (Epic 10 Diode Laser; Biolase Inc., USA) and 1mm shorter than the WL is placed inside the canal, starting irradiation with circular movement in the apical-coronal direction. The root canal was then dried with sterile paper points and obturated with gutta-percha (Dentsply Maillefer, Ballaigues, Switzerland) and AH plus sealer (Dentsply, De Trey, Konstanz, Germany) using a lateral compaction technique. Access cavity was sealed with composite resin (G-aenial Gradia). (Figure 1.C)

The patient was given seven sessions of low level laser therapy (LLLT) (940 nm, 50 mW, continuous emission; Epic 10 Diode Laser, Biolase Inc.). Transcutaneous irradiation was performed around the apices of involved teeth at four points equidistant from each other around the periapical lesion for 9 s delivering a total of 16 J/cm^2 in each session. Application was repeated every 48 h for 15 days.

On 3 month (Figure 1.D) and two- year (Figure 1.E) recalls, the patient had no sign and symptom; parallel periapical radiographic evaluation demonstrated proper integrity of the periodontal tissues, the absence of the radiolucent area and formation of trabecular bone. Clinical exam revealed no sensitivity to percussion and palpation.





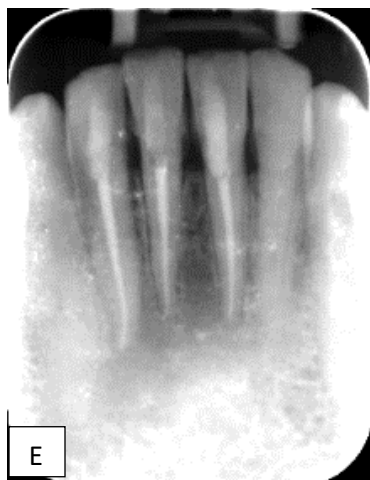


Figure 1.Periapical radiography demonstrating:

- A) Initial radiograph findings when the patient first visited in 2018. Left incisor probably responsible for the cyst-like lesion
- B) Gutta-percha used for tracing the sinus tract
- C) Periapical radio-graph after root canal filling and permanent restoration
- D) Healing of the lesion 3 months after RCT and permanent restoration
- E) Complete healing of the lesion 2-year after RCT

Discussion:

This case illustrated a cyst-like periradicular lesion, most probably a radicular cyst. The exact diagnosis can be made by microscopic examination.(3)

Dentists should have thorough knowledge about the biological factors that lead to the failure of endodontic treatments. The persistence of intraradicular infection(s) is the prominent cause of such failures; therefore, retreatment of failed cases using standard protocols is of paramount importance before considering surgery.(4) The success rate of retreatment might approach almost two thirds of the cases (3,5). However, teeth having undergone proper RCT that exhibits persistent apical periodontitis should be approached differently from the initial endodontic therapy in teeth with apical periodontitis. Some principal factors that might give rise to the persistence of apical radiolucencies in endodontically treated teeth are persistent intraradicular infection(s) remaining in the complex apical part of the root canal, extraradicular infection(s)(10), foreign body reactions due to extruded obturating material or exogenous materials(4), endogenous cholesterol crystals, true cysts (3) and fibrous scar tissues. Of all these factors, microorganisms remaining in the root canal should be addressed by conventional

orthograde retreatment; however, extraradicular lesions due to the bacteria remaining in the complex root canal space, true cysts, and foreign bodies are managed by periapical surgical procedures.

As mentioned in previous studies, in the cases of periradicular radiolucent lesions, sufficient biomechanical cleaning of the root canal system is the most critical factor for healing. It has been demonstrated that in these cases, non-surgical root canal therapy should be the first line of treatment (2,5) and approximately 74% of 42 endodontically treated teeth in one study showed bony healing within their large periradicular lesions (2). While some studies have shown no difference between large and small lesions' healing ability(11).In this case it seems teeth # 31 and 32 treated mistakenly, because the only tooth# 41 had a yellow color change following the trauma.

Calcium hydroxide is the most appropriate intra-canal medicament for teeth with periapical lesions(12), as it removes microorganisms and promotes repair by controlling the inflammatory action, neutralizing osteoclasts acid products, inducing cellular differentiation and neutralization of exotoxins(13).In this case ,two visit retreatment was planned in order to heal the sinus tract and better canal disinfection. Calcium hydroxide mixed with 2% chlorhexidine gel was used because it has been shown that it had a better antimicrobial action as compared to 2% Chlorhexidine gel or Calcium hydroxide alone.

The chemomechanical method cannot completely eliminate the microorganisms in root canal system.(2) Due to the limitation in penetration depth of irrigant solutions such as NaOCl, bacteria remaining in accessory canals cannot be removed. In order to improve the success rate of the RCT procedure, other technologies were introduced.(2) Laser as a new technology has the potential to eradicate the bacteria from root canals through photothermal reactions. (8,9)

To accelerate periapical healing, LLLT was used in the above case. LLLT has been shown to accelerate the process of osseous healing by several mechanisms(14) such as increasing neovascularization, decreasing the inflammatory mediators, increasing cellular proliferation, upregulating bone morphogenic protein(BMP), and transforming growth factor beta(TGF- β), and thus increasing the differentiation of mesenchymal cells into osteoblasts. All these factors result in accelerated osteogenesis.(15)LLLT protocols for bone regeneration show a large variety in literature, most of them involving daily or alternate days application for 15–21 days. Repetitive sessions were used in this study in accordance with the protocol used in previous studies on bone regeneration(15, 16).

Permanent restoration within two weeks of RCT contributed to periradicular healing, as several studies have shown that an adequate coronal restoration-placed as soon as possible after RCT-plays an important role in the outcome of endodontic therapy(17). In this case immediate permanent coronal restoration was done.

Radiographic changes such as the increase in density of the lesion and trabecular regeneration, confirmed healing in addition to the absence of signs and symptoms.(18) However it is difficult to be sure of complete healing with conventional radiographic techniques.

COMPETING INTERESTS DISCLAIMER:

Authors have declared that no competing interests exist. The products used for this research are commonly and predominantly use products in our area of research and country. There is absolutely no conflict of interest between the authors and producers of the products because we do not intend to use these products as an avenue for any litigation but for the advancement of knowledge. Also, the research was not funded by the producing company rather it was funded by personal efforts of the authors.

References:

- 1- Singh KK, Kumar P, Das P, Marandi M, Panda S, Mahajan A, Kumar D. Association of specific microorganisms with endodontic signs and symptoms. A comparative study. J Family Med Prim Care. 2020 Aug 25;9(8):3965-3969.
- 2- Karamifar K, Tondari A, Saghiri MA. Endodontic Periapical Lesion: An Overview on the Etiology, Diagnosis and Current Treatment Modalities. Eur Endod J. 2020 Jul 14;5(2):54-67.
- 3- García CC, Sempere FV, Diago MP, Bowen EM. The post-endodontic periapical lesion: histologic and etiopathogenic aspects. Med Oral Patol Oral Cir Bucal. 2007 Dec 1;12(8):E585-90.
- 4- Alghamdi F, Alhaddad AJ, Abuzinadah S. Healing of Periapical Lesions After Surgical Endodontic Retreatment: A Systematic Review. Cureus. 2020 Feb 7;12(2):e6916. doi: 10.7759/cureus.6916. PMID: 32190471; PMCID: PMC7061768.
- 5- Olcay K, Eyüboğlu TF, Özcan M. Clinical outcomes of non-surgical multiple-visit root canal retreatment: a retrospective cohort study. Odontology. 2019 Oct;107(4):536-545. doi: 10.1007/s10266-019-00426-6. Epub 2019 Apr 9. PMID: 30969392.
- 6- Del Fabbro M, Corbella S, Sequeira-Byron P, Tsesis I, Rosen E, Lolato A, Taschieri S. Endodontic procedures for retreatment of periapical lesions. Cochrane Database Syst Rev. 2016 Oct 19;10(10):CD005511.
- 7- Signor B, Blomberg LC, Kopper PMP, Augustin PAN, Rauber MV, Rodrigues GS, Scarparo RK. Root canal retreatment: a retrospective investigation using regression and

- data mining methods for the prediction of technical quality and periapical healing. *J Appl Oral Sci.* 2021 Apr 19;29:e20200799.
- 8- Saydjari Y, Kuypers T, Gutknecht N. Laser Application in Dentistry: Irradiation Effects of Nd:YAG 1064 nm and Diode 810 nm and 980 nm in Infected Root Canals-A Literature Overview. *Biomed Res Int.* 2016;2016:8421656.
 - 9- Morsy DA, Negm M, Diab A, Ahmed G. Postoperative pain and antibacterial effect of 980 nm diode laser versus conventional endodontic treatment in necrotic teeth with chronic periapical lesions: A randomized control trial. *F1000Res.* 2018 Nov 15;7:1795.
 - 10- Dioguardi M, Di Gioia G, Illuzzi G, Arena C, Caponio VCA, Caloro GA, Zhurakivska K, Adipietro I, Troiano G, Lo Muzio L. Inspection of the Microbiota in Endodontic Lesions. *Dent J (Basel).* 2019 May 1;7(2):47.
 - 11- von Arx T, Kissling- Jeger FB, Simone SFM. Tunnelierende zystische Läsion: Spontanheilung nach Aspiration und Wurzelkanalbehandlung [Through-and-through cystic lesion: spontaneous healing after needle aspiration and conventional root-canal therapy]. *Swiss Dent J.* 2020 Jan 13;130(1):31–35.
 - 12- Zare Jahromi M, Kalantar Motamedi MR. Effect of calcium hydroxide on inflammatory root resorption and ankylosis in replanted teeth compared with other intracanal materials: a review. *Restor Dent Endod.* 2019 Aug 1;44(3):e32.
 - 13- Ercan E, Dalli M, Duülgergil CT, Yaman F. Effect of intracanal medication with calcium hydroxide and 1% chlorhexidine in endodontic retreatment cases with periapical lesions: an in vivo study. *J Formos Med Assoc.* 2007 Mar;106(3):217-24.
 - 14- Chiniforush N, Pourhajibagher M, Shahabi S, Bahador A. Clinical approach of high technology techniques for control and elimination of endodontic microbiota. *J Lasers Med Sci.* 2015;6(4):139-150. doi:10.15171/jlms.2015.09.
 - 15- Fukuhara E, Goto T, Matayoshi T, Kobayashi S, Takahashi T. Optimal low-energy laser irradiation causes temporal G2/Marrest on rat calvarial osteoblasts. *Calcif Tissue Int* 2006;79:443-50.
 - 16- Matsumoto MA, Ferino RV, Monteleone GF, Ribeiro DA. Low-level laser therapy modulates cyclo-oxygenase-2 expression during bone repair in rats. *Lasers Med Sci* 2009;24:195-201.
 - 17- Gillen BM, Looney SW, Gu LS, Loushine BA, Weller RN, Loushine RJ, Pashley DH, Tay FR. Impact of the quality of coronal restoration versus the quality of root canal fillings on success of root canal treatment: a systematic review and meta-analysis. *J Endod.* 2011 Jul;37(7):895-902.
 - 18- Santos-Junior AO, De Castro Pinto L, Mateo-Castillo JF, Pinheiro CR. Success or failure of endodontic treatments: A retrospective study. *J Conserv Dent.* 2019 Mar-Apr;22(2):129-132. doi: 10.4103/JCD.JCD_507_18.

UNDER PEER REVIEW