

Case study

A CASE REPORT ON SPHENOIDAL SINUSITIS WITH BRAIN ABSCESS IN A 16 YEAR OLD

ABSTRACT:

Brain abscess due to pyogenic infection is rare and usually found in immune-compromised patients. Brain imaging and bacterial culture obtained from the infection site are used to diagnose a brain abscess. Surgical resection combined with a sufficient period of antibiotic treatment with bacteria-sensitive antibiotics is effective treatment methods.

PRESENTATION OF THE CASE: A 16-year-old boy was diagnosed with Sphenoidal Sinusitis.. The patient had a past medical history of dengue fever before 3 weeks and corona infection 4 months ago, and was then presented subsequently with manifestations of sphenoidal sinusitis as severe headache, vomiting and fever. He underwent bilateral Functional Endoscopy Sinus Surgery (FESS), sphenoidotomy, and also temporal craniotomy and evacuation of abscess.

CONCLUSION: The treatment of a brain abscess requires early detection, appropriate surgical intervention, and adequate duration of treatment with effective antibiotics.

KEYWORDS: Brain abscess, Sinusitis, Immunocompromised, Surgical treatment, Effective antibiotics

1. INTRODUCTION:

Sinusitis is described as an inflammation of the mucosal lining of one or more paranasal sinuses that can be divided into acute (90 days) and chronic (120 days) disease based on the length of clinical symptoms¹⁻⁴. Viral, bacteria or fungal infections as well as environmental irritants and allergies can induce acute sinusitis⁵.

Sphenoidal sinus lesions are uncommon, accounting for just 2 to 3% of all paranasal sinus lesions^{6,7}. Inflammatory disorders (acute, chronic bacterial and mycotic infections), mucocoeles, primary or secondary tumours (inverted papillomas, ossifying fibromas, pituitary adenomas) are examples of

differential diagnosis⁸. The most prevalent complaint is headache, which accounts for 80-100 percent of cases^{9,10}. Blurred vision, photophobia, progressive vision loss and diplopia owing to sixth nerve paralysis are all ocular symptoms that can occur in upto 22.5 percent of cases^{11,12}.

2. PRESENTATION OF CASE:

A 16 years old male patient approached to general medicine department. He had complaints of neck stiffness and was photophobic with worsening headache and intermittent vomiting for past 10 days. On admission the patient was conscious, oriented and febrile. His vitals such as oxygen saturation (SPO₂), pulse rate, respiratory rate were reported to be normal. He had past medical history of dengue fever before 3 weeks and COVID infection 4 months ago.

His blood group and rheumatoid factor (RH) type were found to be 'O' positive. His haematological report showed normal values of basophils, eosinophils, Mean Corpuscular Volume (MCV), Mean Corpuscular Hemoglobin (MCH), Mean Corpuscular Hemoglobin Concentration (MCHC), Platelet, Hemoglobin, Red cell Distribution Width (RDW), sodium, potassium whereas, his White Blood Cells (WBC) Count (20,300 cells/cu.mm), polymorph (88%) was elevated from normal. Based on clinical examination, the patient's Serum Glutamic Pyruvic Transaminase (SGPT) level and activated partial thromboplastin time were reported to be normal. His Prothrombin Time (PT) 16 seconds, international normalized ratio (INR) 1.39 and C-Reactive Protein (CRP) levels were slightly elevated from the normal value. His magnetic resonance imaging (MRI) brain report showed that sphenoidal sinusitis with skull base osteomyelitis and meningitis with extra axial extension showing adjacent cerebritis.

He was commenced with Intravenous Fluid (IV) ceftriaxone, vancomycin, doxycycline, acyclovir and transferred to High Dependency Unit (HDU) for further management. As his Cerebrospinal Fluid (CSF) analysis were suggestive of bacterial infection, acyclovir was discontinued. Moreover, doxycycline was also discontinued as his scrub typhus serology was negative. He underwent Bilateral Functional Endoscopy Sinus Surgery (FESS) & sphenoidotomy.

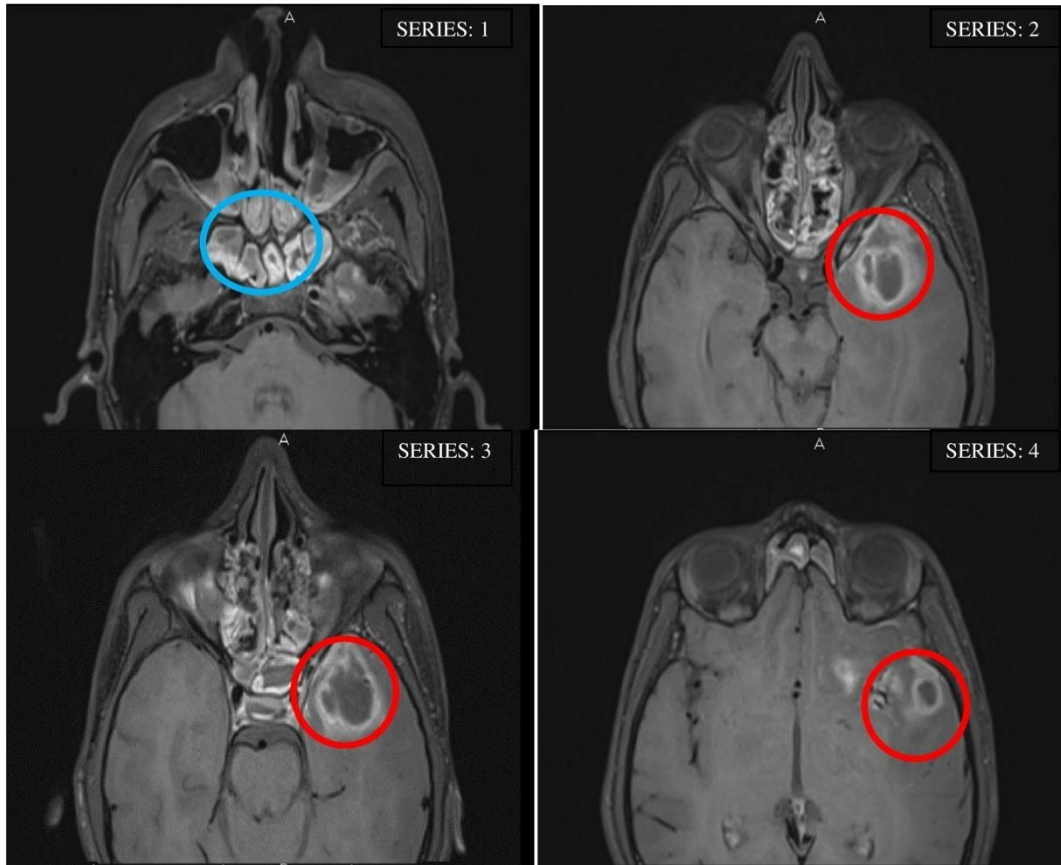


Figure 1: Frontal axis MRI showed left temporal ring enhanced cystitic lesions with edema (marked in red) and enhancement of Sphenoid sinus mucosa (marked in blue) in the patient

Since his MRI features were suggestive of fungal infection, voriconazole was given. He was then transferred to the ward, his head ache got better with regular analgesic. But after couple of days, he had persistent headache and generalized tonic clonic seizure, so from then he was on regular antiepileptic (Tab.levitiracetam) treatment. The MRI was repeated and it showed “features of left temporal ring enhanced cystic lesion with edema and enhancement of sphenoid sinus mucosa suggestive of abscess. He was treated with the following medications; T.Meropenam, T. Vancomycin, T.Voriconazole, T.levitiracetam, T.Mannitol, T.Paracetamol, T.Emeset, Fluticasone nasal spray, Polyethylene glycol 3350 and T.Fexofenadine hydrochloride. Later he pursued the treatment on another hospital. The patient underwent temporal craniotomy and evacuation of abscess and followed the current medication in hospital: analgesic, antibiotic and antiepileptics.

He was admitted in our hospital after the surgery for further treatment. His vitals were recorded and found to be normal. His computed tomography (CT) scan showed defects in the left frontotemporal

craniotomy, edema with air-pockets in the left temporal region and focal contusion in the left basifrontal lobe. He was treated with IV antibiotics and other supportive measures. Patient condition was improved and hence he was discharged with the following medications: T.Pantoprazole 40mg, T.levitiracetam 750mg, T.Diclofenac 75mg

3. DISCUSSION :

We presented a case of Sphenoidal sinusitis in a 16-year-old boy. The patient had a past medical history of dengue fever before 3 weeks and COVID infection 4 months ago, and was recently presented subsequently with manifestations of sphenoidal sinusitis. Recent studies have shown some most common presentation of sphenoidal sinusitis as headache and vomiting due to raised intracranial pressure. 50% cases of sphenoidal sinusitis reported having Seizures episodes¹³. The researchers reported incidence of brain abscesses as approximately 8% of intra-cranial masses in developing countries and 1–2% in the western countries¹⁴. Brain abscess is a rare disease in immunocompetent individuals. In adults, otitis media and paranasal sinusitis (frontal, ethmoidal, or sphenoidal sinuses) are the most common predisposing conditions for brain abscess formation. A brain abscess is an intraparenchymal collection of pus¹⁵. According to the World Health Organisation, most brain abscesses are polymicrobial, with the most common pathogens being gram positive (Streptococci and Staphylococci) and anaerobic bacteria¹⁶. The most common origin of microbial infection in children remains direct or indirect cranial infection arising from the middle ear, paranasal sinuses, or teeth¹⁵. Meningitis is the most common intracranial complication of sinusitis and often develops from a sphenoid source. Inflammation of the meninges (ie, pia or dura mater) leads to the clinical syndrome of headache, neck stiffness, and photophobia, often with nausea and vomiting¹⁷ and unusual behavior in the early stages of the disease alike the symptoms of the patient during admission. Complications of the inflammatory and infectious conditions of sphenoid sinusitis are the result of direct extension of disease to the surrounding tissues or a propagated thrombophlebitis through valveless veins, which connect the paranasal sinuses¹⁷. In a routine laboratory testing, white blood cell count greater than 11,000 per cu.mm is defined as Leukocytosis¹⁸. In this cases, due to reoccurrence of bacterial and viral infection weaken the immune system and increases the white blood count. The patient's imaging study result showed no sign of organism in gram stain cerebrospinal fluid (CSF). However, his CSF culture shows growth of Coagulase-negative staphylococci (CoNS) Concomitant. CoNS are a type of staph bacteria that commonly live on a person's skin. Physician typically considers CoNS bacteria harmless when it

remains outside the body. However, the bacteria can cause infections when present in large amounts, or when present in the bloodstream. Physicians often divide staph bacteria into coagulase-positive and coagulase-negative types. Coagulase is an enzyme needed to make blood clot. This enzyme is present in *Staphylococcus aureus* bacteria. Physician typically associates this type with causing more serious infections¹⁹. Earlier studies using conventional cultures demonstrated *Staph aureus*, coagulase-negative *Staph*, and gram-negative rods in Chronic Rhino Sinusitis patients²⁰. The CSF cell count was clear and colourless, with few count of CSF RBC and WBC count in the report. Normally, there are no RBCs in the cerebrospinal fluid, and there should be not more than five WBCs per cubic millimeter of CSF. If the CSF fluid contains RBCs, this may indicate bleeding or may be due to the possibility of traumatic tap (blood leaked into the fluid sample during collection)²¹. FESS (sinus surgery) is most successful in patients who have recurrent acute or chronic infective sinusitis. Patients are with the predominant symptoms of facial pain and nasal blockage usually respond well. The sense of smell often improves after this type of surgery. A CT scan before FESS is mandatory to identify the patient's ethmoid anatomy and its relationship to the skull base and orbit. CT scanning also allows the extent of the disease to be defined, as well as any underlying anatomic abnormalities that may predispose a patient to sinusitis²².

4. CONCLUSION:

The pyogenic brain abscess is a collection of pustular materials presenting as a mass-like lesion. A cerebral abscess usually occurs when bacteria or fungi make their way into the brain, either through your bloodstream or from an infected area in the head, such as your ears or sinuses. In the present case, craniotomy for abscess excision was a more effective method. Complete excision of the abscess capsule was an effective precaution against recurrence. It is necessary to choose antibiotic according to drug sensitivity tests result, and to ensure adequate duration of intravenous treatment until postoperative body temperature has remained within normal range level. It is also essential for the patient to continue oral antibiotics for at least 3 months after discharge.

CONSENT

As per international standard or university standard, patients' written consent has been Collected and preserved by the authors.

ETHICAL APPROVAL

As per international standard or university standard written ethical approval has been Collected and preserved by the authors.

COMPETING INTERESTS DISCLAIMER:

Authors have declared that no competing interests exist. The products used for this research are commonly and predominantly use products in our area of research and country. There is absolutely no conflict of interest between the authors and producers of the products because we do not intend to use these products as an avenue for any litigation but for the advancement of knowledge. Also, the research was not funded by the producing company rather it was funded by personal efforts of the authors.

REFERENCE:

1. American Academy of Pediatrics, Subcommittee on Management of Sinusitis and Committee on Quality Improvement. Clinical practice guideline: management of sinusitis. *Pediatrics*. 2001;108(3):798–808
2. Leung AKC, Kellner JD. Acute sinusitis in children: diagnosis and management. *J Pediatr Health Care*. 2004;18(2):72–76.
3. Leung AKC. Acute sinusitis. In: Leung AKC, ed. *Common Problems in Ambulatory Pediatrics: Specific Clinical Problems*, volume 1. New York: Nova Science Publishers, Inc., 2011:207–214
4. Zacharisen M, Casper R. Pediatric sinusitis. *Immunol Allergy Clin North Am*. 2005;25(2):313–332
5. Brook I. Acute sinusitis in children. *Pediatr Clin North Am*. 2013;60(2):409–424.

6. Cheung DK, Martin GF, Rees J. Surgical approach to sphenoid sinus. *J Otolaryngol* 1992;21:1-8.
7. Metson R, Gliklich RE. Endoscopic treatment of sphenoid 274 D. Giordano, D. Perano, S. Marchi, et al sinus disease: report of 39 cases. *Otolaryngol Head Neck Surg* 1996;114:736-744.
8. Elden LM, Reinders KK, Tom LWC. Management of isolated sphenoid sinus disease in children: A surgical perspective. *Int J Pediatr Otorhinolaryngol* 2011;75:1594-1598.
9. Castelnovo P, Pagella F, Semino F, et al. Endoscopic treatment of isolated sphenoid sinus lesions. *Eur Arch Otorhinolaryngol* 2005;262:142-147.
10. Marseglia GL, Pagella F, Licari A, et al. Acute isolated sphenoid sinusitis in children. *Int J Pediatr Otorhinolaryngol* 2006;70:2027-2031.
11. Kim SW, Kim IG, Kong DY, et al. Isolated sphenoid sinus diseases: report of 76 cases. *Acta Otolaryngol* 2008;128:455-459.
12. Nour YA, Al-Madani A, El-Daly A, Gaafar A. Isolated sphenoid sinus pathology: spectrum of diagnostic and treatment modalities. *Auris Nasus Larynx*. 2008 Dec 1;35(4):500-8..
13. Nauta HJ, Contreras FL, Weiner RL, Crofford MJ. Brain stem abscess managed with computed tomography-guided stereotactic aspiration. *Neurosurgery*. 1987 Mar 1;20(3):476-80.
14. Sharma BS, Gupta SK, Khosla VK. Current concepts in the management of pyogenic brain abscess. *Neurology India*. 2000 Apr 1;48(2):105.
15. Osenbach RK, Loftus CM. Diagnosis and management of brain abscess. *Neurosurgery clinics of North America*. 1992 Apr 1;3(2):403-20.
16. Chen M, Low DC, Low SY, Muzumdar D, Seow WT. Management of brain abscesses: where are we now?. *Child's Nervous System*. 2018 Oct;34(10):1871-80.
17. Goldman A. Complications of sphenoid sinusitis. *Operative Techniques in Otolaryngology-Head and Neck Surgery*. 2003 Sep 1;14(3):216-8.
18. Abramson N, Melton B. Leukocytosis: basics of clinical assessment. *American family physician*. 2000 Nov 1;62(9):2053-60.
19. Miyasar A. The Prevalence of Pathogenic Bacteria from Different Clinical Samples, Northern Part of Iraq. 2020

20. Nadel DM, Lanza DC, Kennedy DW. Endoscopically guided cultures in chronic sinusitis. American journal of rhinology. 1998 Jul;12(4):233-42.
21. Seehusen DA, Reeves MM, Fomin DA. Cerebrospinal fluid analysis. Am Fam Physician. 2003 Sep 15;68(6):1103-8.
22. Slack R, Bates G. Functional endoscopic sinus surgery. Am Fam Physician. 1998 Sep 1;58(3):707-18.a