

Original Research Article

OSTEOMETRIC MEASURES OF MANDIBLE ON ITS VARIOUS ASPECTS IN SOUTH INDIAN DRY SKULL

ABSTRACT

INTRODUCTION:

Mandible is the single bone articulated with cranium forming a temporomandibular joint and it contributes to the lower jaw containing teeth. The mandible is composed of the body and the ramus.

AIM:

Aim of this study is to find the distance between each parameter in different mandibles .

MATERIALS AND METHODS:

The present study has utilized 30 south indian dry skulls from the Anatomy Department of Anatomy, Saveetha Dental college. The following parameters are taken to measure by using vernier calipers. They are the maximum distance between the mandibular incisors, mandibular inter canine, mandibular 1st premolar, mandibular molar, mandibular coronoid process, mandibular condylar process, mandibular notch on either side. The results were analysed statistically by using t-test calculator in Graph pad.

RESULTS:

From the study it was observed that the mean distance between the mandibular incisors is 15.658 ± 1.642416 , mandibular inter canine 29.0025 ± 9.04636 , mandibular 1st premolar 40.746 ± 2.543341 , mandibular molar 62.076 ± 3.4988 , mandibular coronoid process 85.8735 ± 5.10615 , mandibular condylar process 103.013 ± 3.794 , mandibular notch on either side 88.368 ± 3.5832 (Table 1 & Figure 1-6).

CONCLUSION:

The present study thus concluded that the morphometric analysis of the mandible is of utmost importance in determining the gender, anatomical studies, clinical and anthropometric studies.

KEYWORDS :

INTRODUCTION:

Mandible is the strongest and largest bone of the face which forms the lower jaw. It is the only bone articulated with cranium forming the temporomandibular joint (1–3). The lower jaw contains teeth which includes incisors, canines, premolars and molars (4). The mandible is the bone that develops from the first pharyngeal arch, the meckel's cartilage is the primordia for the developing mandible(5,6). The mandible that possesses body, ramus, notch, coronoid and condylar process, alveolar sockets with teeth. Further it possesses mandibular foramen which transmits inferior alveolar nerves and vessels, mylohyoid groove in the inner surface of the mandible transmits mylohyoid nerves and vessels(7,8). The lines, ridges and rough areas of the mandible give attachment to muscles and ligaments(9,10). The sphenomandibular ligaments, stylomandibular ligaments and pterygomandibular raphe are attached to the mandible(11,12). The muscles of mastication such as masseter, temporalis, medial and lateral pterygoid are attached and suprahyoid groups of muscles such as mylohyoid, geniohyoid are attached to the mandible(13).

The horizontally curved portion of the mandible creates a lower jawline and rami is situated vertically with respect to the body, whereas the coronoid process give attachment to the the temporalis muscle as mentioned above and condylar process or head of the mandible articulates with mandibular fossa(14)(11,15–17). Thus the joint permits greater mobility for the process of mastication and speaking (18). The individual tooth present in the mandibular sockets has its own functions. They are incisors cutting the food, cut and tear by the canine, and it acts as a guide post to the rest of the teeth (19), (20).

Mandibular 1st premolar is the tooth located laterally from both the mandibular canines of the mouth but mesial form both mandibular second premolar its functions is similar to that of canines in regard to tearing being the principal action during mastication, commonly known as chewing (21,22). Mandibular molar is the tooth located distally from both the mandibular second premolar of the mouth but mesial form both mandibular second molars (23). The coronoid process of the mandible is thin, triangular, sharp projection, flattened from side to side and gives attachment to the tendon of the temporalis muscle(11,15,16). The shape of the

coronoid process may vary (23,24). The condylar process is rounded elevation of the mandible called head, compressed anteroposteriorly and elongated from side to side(25). Anteriorly it possesses a small depression called pterygoid fovea that provides insertion to the lateral pterygoid, main depressor of the temporomandibular joint (26,27). The coronoid and condylar processes are outpouching of the ramus of the mandible. The ramus is flattened from side to side having borders and surfaces provides attachments to muscles and ligaments, the superior border of the ramus forms the mandibular notch (28). From this the present study aimed to analyse the mandible from its various aspects by morphometrically(29).

MATERIALS AND METHODS :

The present study has utilized 30 south indian dry skulls adopted from the Department of anatomy from Saveetha Dental College and Hospitals. All the linear distances were measured by using a digital vernier caliper. The following parameters are studied on the mandible of south indian dry skull. They are maximum distance between the mandibular incisors, maximum distance between the mandibular inter canine, maximum distance between the mandibular 1st premolar, maximum distance between the mandibular molar, maximum distance between the mandibular coronoid process, maximum distance between the mandibular condylar process maximum distance between the mandibular notch. The obtained results were analysed and represented in graphs.

Statistical analysis:

The present study utilized a t-test calculator in Graph pad with 95% significance for statistical analysis. The analysis done between maximum distance of mandibular incisors and canine, mandibular 1st premolar and molar, mandibular coronoid process and condylar process.

RESULTS :

The present study was observed that the mean with standard deviation distance between the mandibular incisors is 15.658 ± 1.642416 , mandibular inter canine 29.0025 ± 9.04636 , mandibular 1st premolar 40.746 ± 2.543341 , mandibular molar 62.076 ± 3.4988 , mandibular coronoid process 85.8735 ± 5.10615 , mandibular condylar process 103.013 ± 3.794 , mandibular notch on either side 88.368 ± 3.5832 (Table 1 & Figure 1-6). But for statistical analysis, the study chose the following parameters. They are the difference observed between maximum incisors and canines, p value is < 0.0001 , difference observed between maximum distance of

mandibular 1st premolar distance and molar. The p value is 0.0001 and the maximum distance between right and left condylar and coronoid processes. The p value is 0.0001.

Table 1:

Parameters (mm)	Average	Standard deviation (\pm)
Maximum mandibular incisors distance	15.658	1.642416
Maximum mandibular inter canine distance	29.0025	9.04636
Maximum mandibular 1st premolar distance	40.746	2.543341
Maximum mandibular molar distance	62.076	3.4988
Maximum mandibular coronoid distance	85.8735	5.10615
Maximum mandibular condylar distance	103.013	3.794
Maximum inter notch distance	88.368	3.5832

Table 1 : Shows average and standard deviation of taken parameters in different mandibles.

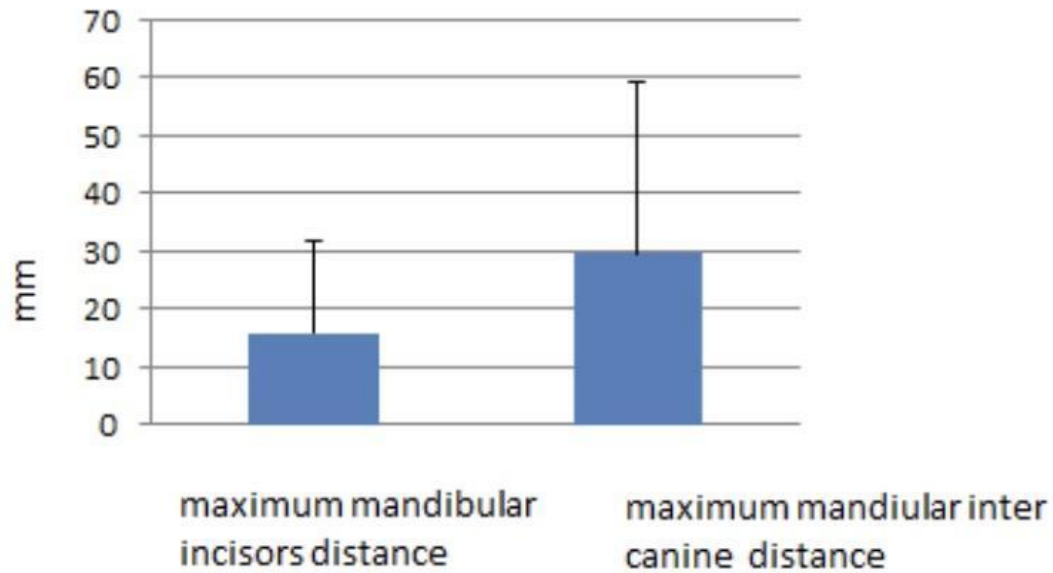


FIGURE 1: Bar graph depicts maximum mandibular incisors distance and maximum mandibular inter canine distance . X - axis represents maximum mandibular incisors distance and maximum mandibular inter canine distance. Y - axis represents measurements in mm . There was a significant difference observed between maximum incisors and canines, p value is < 0.0001 .

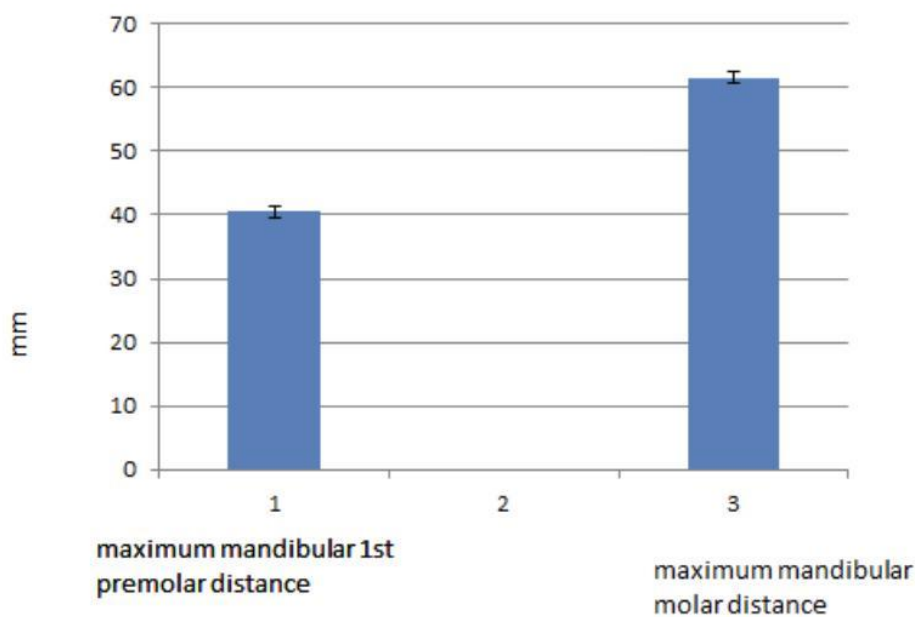


FIGURE 2: Bar graph depicts maximum mandibular 1st premolar distance and maximum mandibular molar distance. X - axis represents maximum mandibular 1st

premolar distance and maximum mandibular molar distance. Y - axis represents measurements in mm. It shows that maximum mandibular molar distance is greater than maximum mandibular 1st premolar. There was a significant difference observed between maximum distance of mandibular 1st premolar distance and molar. The p value is < 0.0001.

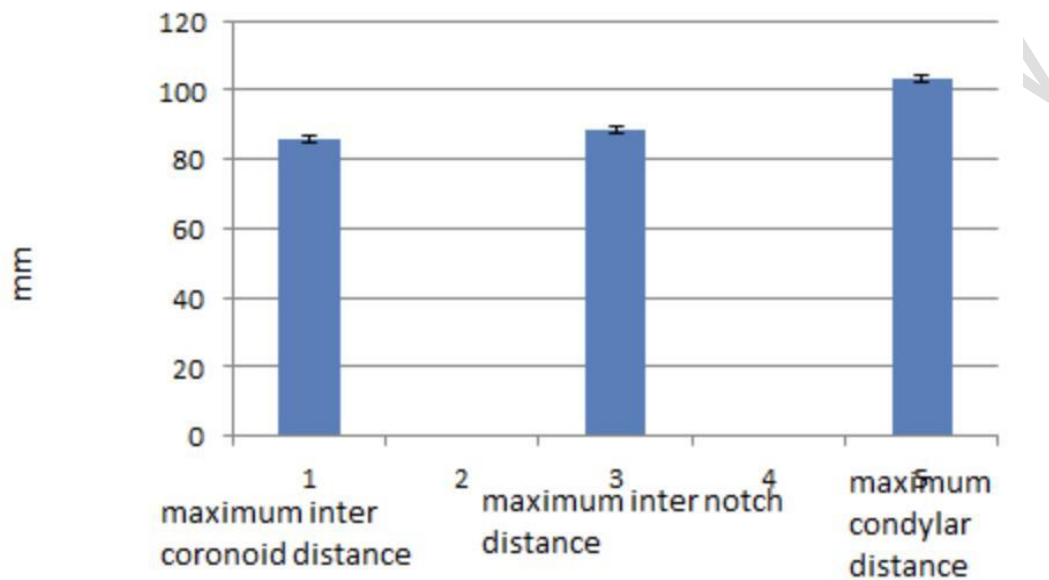


FIGURE 3: Bar graph depicts maximum inter coronoid distance and maximum inter notch distance and maximum condylar distance. X - axis represents maximum inter coronoid distance, maximum inter notch distance and maximum condylar distance. Y - axis represents measurements in mm. There was a significant difference observed between maximum distance between right and left condylar and coronoid processes. The p value is < 0.0001.



FIGURE 4: shows measuring maximum distance between canines.



FIGURE 5: shows measuring maximum distance between molars.

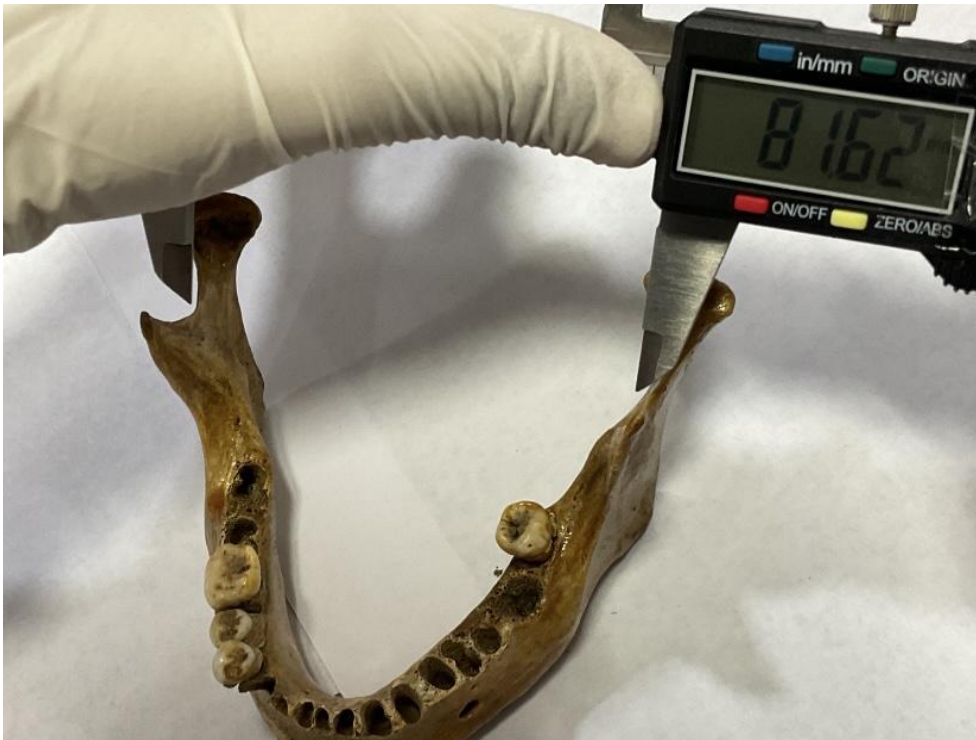

FIGURE 6: shows maximum distance between maximum intercondylar notch distance.

DISCUSSION :

Mandible is the important bone that contributes to the lower jaw with tooth sockets. It is developed from the first pharyngeal arch from its primordial meckel's cartilage. There are so many studies conducted by using mandibles world wide. Like morphometric analysis of condyles, coronoid process, ramus etc. From the study it was observed that the mean distance between the mandibular incisors is 15.658 ± 1.642416 , mandibular inter canine 29.0025 ± 9.04636 , mandibular 1st premolar 40.746 ± 2.543341 , mandibular molar 62.076 ± 3.4988 , mandibular coronoid process 85.8735 ± 5.10615 , mandibular condylar process 103.013 ± 3.794 , mandibular notch on either side 88.368 ± 3.5832 .

Similar to the present other study also analysed the mandible but there is no significant difference observed between right and left side of the mandible (30). But in the present study significant differences were observed between maximum incisors and canines (p value is < 0.0001), distance of mandibular 1st premolar distance and molar (p value is < 0.0001) and maximum distance of right and left condylar and coronoid processes (p value is < 0.0001).

The studies showing that this mandibular studies is used for to predict sex accurately (31). The mandibular measurements is not only helpful in anatomical studies, anthropometric, determining sex, etc. but also helpful in assessing facial index. In fact, the mandible also contributes a major

part i.e lower jaw. Similarly study was conducted to determine the facial height inclusive of mandible (32), mandibular measurements may be helpful in determining the sex (33). The limitations of the present study is small size and the study is further continued with larger sample size and interpreted with new findings.

CONCLUSION :

The mandible is the important skull bone and only movable bone, contributing for the lower facial skeleton. There are so many morphometric studies conducted with condyles, ramus, coronoid process, etc. Similarly the present study also conducted above mentioned parameters. These measurements are of utmost importance in anatomical, anthropometric and various clinical studies as well.

REFERENCES:

1. Priyadharsini JV, Vijayashree Priyadharsini J, Smiline Girija AS, Paramasivam A. In silico analysis of virulence genes in an emerging dental pathogen *A. baumannii* and related species [Internet]. Vol. 94, Archives of Oral Biology. 2018. p. 93–8. Available from: <http://dx.doi.org/10.1016/j.archoralbio.2018.07.001>
2. Uma Maheswari TN, Nivedhitha MS, Ramani P. Expression profile of salivary micro RNA-21 and 31 in oral potentially malignant disorders. Braz Oral Res. 2020 Feb 10;34:e002.
3. Gudipani RK, Alam MK, Patil SR, Karobari MI. Measurement of the Maximum Occlusal Bite Force and its Relation to the Caries Spectrum of First Permanent Molars in Early Permanent Dentition. J Clin Pediatr Dent. 2020 Dec 1;44(6):423–8.
4. Sumathy G, Sathyapriya B, Chandrakala B, Tamilsevi R. An Anatomical Study on Position of Mandibular Foramen in Dry Adult Human Mandibles [Internet]. Vol. 10, Indian Journal of Public Health Research & Development. 2019. p. 907. Available from: <http://dx.doi.org/10.37506/v10/i12/2019/ijphrd/192235>
5. Alharbi KS, Fuloria NK, Fuloria S, Rahman SB, Al-Malki WH, Javed Shaikh MA, et al. Nuclear factor-kappa B and its role in inflammatory lung disease. Chem Biol Interact. 2021 Aug 25;345:109568.
6. Marya A, Karobari MI, Selvaraj S, Adil AH, Assiry AA, Rabaan AA, et al. Risk Perception of SARS-CoV-2 Infection and Implementation of Various Protective Measures by Dentists Across Various Countries. Int J Environ Res Public Health [Internet]. 2021 May 29;18(11). Available from: <http://dx.doi.org/10.3390/ijerph18115848>
7. Sekar D, Lakshmanan G, Mani P, Biruntha M. Methylation-dependent circulating microRNA 510 in preeclampsia patients [Internet]. Vol. 42, Hypertension Research. 2019. p. 1647–8. Available from: <http://dx.doi.org/10.1038/s41440-019-0269-8>

8. Barma MD, Muthupandiyar I, Samuel SR, Amaechi BT. Inhibition of *Streptococcus mutans*, antioxidant property and cytotoxicity of novel nano-zinc oxide varnish. *Arch Oral Biol*. 2021 Jun;126:105132.
9. Pujari GRS, Subramanian V, Rao SR. Effects of *Celastrus paniculatus* Willd. and *Sida cordifolia* Linn. in Kainic Acid Induced Hippocampus Damage in Rats [Internet]. Vol. 53, *Indian Journal of Pharmaceutical Education and Research*. 2019. p. 537–44. Available from: <http://dx.doi.org/10.5530/ijper.53.3.86>
10. Rao SK, Kalai Priya A, Manjunath Kamath S, Karthick P, Renganathan B, Anuraj S, et al. Unequivocal evidence of enhanced room temperature sensing properties of clad modified Nd doped mullite Bi₂Fe₄O₉ in fiber optic gas sensor [Internet]. Vol. 838, *Journal of Alloys and Compounds*. 2020. p. 155603. Available from: <http://dx.doi.org/10.1016/j.jallcom.2020.155603>
11. Johnson J, Lakshmanan G, Biruntha M, Vidhyavathi RM, Kalimuthu K, Sekar D. Computational identification of MiRNA-7110 from pulmonary arterial hypertension (PAH) ESTs: a new microRNA that links diabetes and PAH [Internet]. Vol. 43, *Hypertension Research*. 2020. p. 360–2. Available from: <http://dx.doi.org/10.1038/s41440-019-0369-5>
12. Paramasivam A, Priyadharsini JV, Raghunandhakumar S, Elumalai P. A novel COVID-19 and its effects on cardiovascular disease. *Hypertens Res*. 2020 Jul;43(7):729–30.
13. Ravisankar R, Jayaprakash P, Eswaran P, Mohanraj K, Vinitha G, Pichumani M. Synthesis, growth, optical and third-order nonlinear optical properties of glycine sodium nitrate single crystal for photonic device applications [Internet]. Vol. 31, *Journal of Materials Science: Materials in Electronics*. 2020. p. 17320–31. Available from: <http://dx.doi.org/10.1007/s10854-020-04288-5>
14. Princeton B, Santhakumar P, Prathap L. Awareness on Preventive Measures taken by Health Care Professionals Attending COVID-19 Patients among Dental Students. *Eur J Dent*. 2020 Dec;14(S 01):S105–9.
15. Paulkumar K, Gnanajobitha G, Vanaja M, Rajeshkumar S, Malarkodi C, Pandian K, et al. Piper nigrum Leaf and Stem Assisted Green Synthesis of Silver Nanoparticles and Evaluation of Its Antibacterial Activity Against Agricultural Plant Pathogens [Internet]. Vol. 2014, *The Scientific World Journal*. 2014. p. 1–9. Available from: <http://dx.doi.org/10.1155/2014/829894>
16. Wu S, Rajeshkumar S, Madasamy M, Mahendran V. Green synthesis of copper nanoparticles using and its antioxidant and antibacterial activity against urinary tract infection pathogens. *Artif Cells Nanomed Biotechnol*. 2020 Dec;48(1):1153–8.
17. Vikneshan M, Saravanakumar R, Mangaiyarkarasi R, Rajeshkumar S, Samuel SR, Suganya M, et al. Algal biomass as a source for novel oral nano-antimicrobial agent. *Saudi J Biol Sci*. 2020 Dec;27(12):3753–8.
18. Veeramuthu M, Tutor, Department of Anatomy, Dhanalakshmi Srinivasan Medical College & Hospital, Varman R, Shalini, et al. MORPHOMETRIC ANALYSIS OF INFRAORBITAL FORAMEN AND INCIDENCE OF ACCESSORY FORAMEN AND ITS CLINICAL IMPLICATIONS IN DRY ADULT HUMAN SKULL [Internet]. Vol. 4,

International Journal of Anatomy and Research. 2016. p. 2993–3000. Available from: <http://dx.doi.org/10.16965/ijar.2016.391>

19. Fastlicht J. Crowding of mandibular incisors [Internet]. Vol. 58, American Journal of Orthodontics. 1970. p. 156–63. Available from: [http://dx.doi.org/10.1016/0002-9416\(70\)90069-2](http://dx.doi.org/10.1016/0002-9416(70)90069-2)
20. Verma SL, Sharma VP, Singh GP. Management of a transmigrated mandibular canine. J Orthod Sci. 2012 Jan;1(1):23–8.
21. Zhang M, Xie J, Wang Y-H, Feng Y. Mandibular first premolar with five root canals: a case report. BMC Oral Health. 2020 Sep 10;20(1):253.
22. Bhavikatti SK, Karobari MI, Zainuddin SLA, Marya A, Nadaf SJ, Sawant VJ, et al. Investigating the Antioxidant and Cytocompatibility of Linn Extract over Human Gingival Fibroblast Cells. Int J Environ Res Public Health [Internet]. 2021 Jul 4;18(13). Available from: <http://dx.doi.org/10.3390/ijerph18137162>
23. Ballullaya SV, Vemuri S, Kumar PR. Variable permanent mandibular first molar: Review of literature. J Conserv Dent. 2013 Mar;16(2):99–110.
24. Kale TP, Kotrashetti SM, Lingaraj JB, Aggarwal V. Mandibular Coronoid Fractures, How Rare? [Internet]. Vol. 16, The Journal of Contemporary Dental Practice. 2015. p. 222–6. Available from: <http://dx.doi.org/10.5005/jp-journals-10024-1665>
25. Rajkumar KV, Lakshmanan G, Sekar D. Identification of miR-802-5p and its involvement in type 2 diabetes mellitus. World J Diabetes. 2020 Dec 15;11(12):567–71.
26. Fonseca GDD, Da Fonseca GD. Experimental study on fractures of the mandibular condylar process (mandibular condylar process fractures) [Internet]. Vol. 3, International Journal of Oral Surgery. 1974. p. 89–101. Available from: [http://dx.doi.org/10.1016/s0300-9785\(74\)80040-2](http://dx.doi.org/10.1016/s0300-9785(74)80040-2)
27. Priyadharsini JV. In silico validation of the non-antibiotic drugs acetaminophen and ibuprofen as antibacterial agents against red complex pathogens [Internet]. Vol. 90, Journal of Periodontology. 2019. p. 1441–8. Available from: <http://dx.doi.org/10.1002/jper.18-0673>
28. Ishwarkumar S, Pillay P, De-Gama BZ, Satyapal KS. Osteometric and Radiological Study of the Mandibular Notch [Internet]. Vol. 37, International Journal of Morphology. 2019. p. 491–7. Available from: <http://dx.doi.org/10.4067/s0717-95022019000200491>
29. Logeshwari R, Rama Parvathy L. Generating logistic chaotic sequence using geometric pattern to decompose and recombine the pixel values [Internet]. Vol. 79, Multimedia Tools and Applications. 2020. p. 22375–88. Available from: <http://dx.doi.org/10.1007/s11042-020-08957-9>
30. Amin WM. Osteometric Assessment of Various Mandibular Morphological Traits for Sexual Dimorphism in Jordanians by Discriminant Function Analysis [Internet]. Vol. 36, International Journal of Morphology. 2018. p. 642–50. Available from: <http://dx.doi.org/10.4067/s0717-95022018000200642>

31. Adibi S, Paknahad M. Comparison of cone-beam computed tomography and osteometric examination in preoperative assessment of the proximity of the mandibular canal to the apices of the teeth. *Br J Oral Maxillofac Surg*. 2017 Apr;55(3):246–50.
32. Baral P, Lobo SW, Menezes RG, Kanchan T, Krishan K, Bhattacharya S, et al. An anthropometric study of facial height among four endogamous communities in the Sunsari district of Nepal. *Singapore Med J*. 2010 Mar;51(3):212–5.
33. Marinescu M, Panaitescu V, Rosu M. Sex determination in Romanian mandible using discriminant function analysis: Comparative results of a time-efficient method [Internet]. Vol. 21, *Romanian Journal of Legal Medicine*. 2013. p. 305–8. Available from: <http://dx.doi.org/10.4323/rjlm.2013.305>