

## **Case study**

### **TRANSIENT MYOCARDIAL ISCHEMIA IN A CASE POST INTRA-MUSCULAR ADRENALINE**

#### **Abstract**

**Background:** Anaphylaxis is a medical emergency and requires immediate medical attention. Kounis syndrome is myocardial infarction or injury occurring in the setting of anaphylaxis and can also be due to the effects of epinephrine. Adrenaline is a common drug in the management of anaphylaxis but the electrocardiographic consequences of its administration post an attack are seldomly seen. Vasospasm is generally the cause for myocardial injury in an acute setting following the administration of epinephrine.

**Case presentation:** A 21-year-old female developed sudden onset breathlessness and giddiness post vaccination with the Oxford – AstraZeneca COVID -19 vaccine. She was administered 0.5 ml adrenaline (1:1000) intramuscularly on the lateral aspect of the left thigh, following which she complained of chest tightness and palpitations. This was accompanied by hypotension and global ST segment depression on her Electrocardiogram. The second electrocardiogram, done after 30 minutes showed a relative resolution in ST segment depressions with sinus rhythm in the one done at 16:00 hours. Creatine Kinase- MB and Troponin I were within normal limits and the patient experienced symptomatic improvement with normalization of blood pressure post fluid challenge.

**Conclusion:** This case report highlights the case of a young female with no comorbidities who developed transient myocardial ischemia after administration of intramuscular adrenalin in therapeutic dose in view of an anaphylactic reaction. The probable action is alpha mediated coronary vasospasm. The potential adverse effects in an acute setting are hence outlined in this case report without discouraging its use given the potential benefits outweigh the risks.

**Keywords:** Anaphylaxis, Epinephrine, Myocardial infarction

#### **Background**

There are two possible reasons in a setting of Myocardial infarction one of which is epinephrine resulting in myocardial injury and the other is Kounis syndrome. 0.5ml of 1:1000 intramuscular adrenaline is recommended in the management of anaphylaxis [1,2]. Myocardial infarction has been reported in very few case reports [3]. Vasospasm secondary to epinephrine is the mechanism of myocardial injury. Coronary

angiographies done in these cases were found to be normal. [4] A young healthy female developed transient myocardial ischemia following administration of therapeutic dose of intramuscular adrenaline for an anaphylaxis.

### **Case presentation**

A 21-year-old Indian female developed giddiness and breathlessness following vaccination with oxford –AstraZeneca COVID -19 vaccine. On examination she had tachycardia, tachypnea, a bp of 100/70 mmHg, cold - clammy extremities and a wheeze on auscultation. She was treated with intravenous hydrocortisone 100 mg, intravenous chlorpheniramine 10 mg and 0.5 ml of intramuscular adrenaline (1:1000 solution) given in the left vastus lateralis. Within a few minutes of administration of adrenaline she developed chest tightness and palpitations. Her blood pressure dropped to 70 systolic with global ST segment depression in the ECG taken at 15:00 hours. She was then given a fluid challenge test with normal saline post that her blood pressure normalized. A Creatine Kinase – MB and Troponin I were sent which were found to be normal. In the Midst of these symptoms she also developed carpo pedal spasm, which was managed with Intravenous calcium gluconate given over 10 minutes. An ECG taken 30 minutes post administration of adrenaline which showed resolution of ST depression. The patient improved symptomatically and clinically with a pulse of 82/min, bp of 90/60, a respiratory rate of 22/minute and a clear chest on auscultation. An ecg was repeated at 16:00 hours which showed normal sinus rhythm. She was previously healthy, had no comorbidities with no food or drug allergy. There was no previous history of hospitalization for any cause or family history suggestive of hypertension, diabetes mellitus, ischemic heart diseases or premature deaths due to any cardiac condition. On further evaluation no structural anomaly or regional wall motion abnormality was detected on the 2 dimensional echocardiogram (ejection fraction =60%). Given the transient nature of the attack angiography was not done. Chest x-ray showed no obvious abnormality. Complete blood counts, liver and kidney function test were normal.

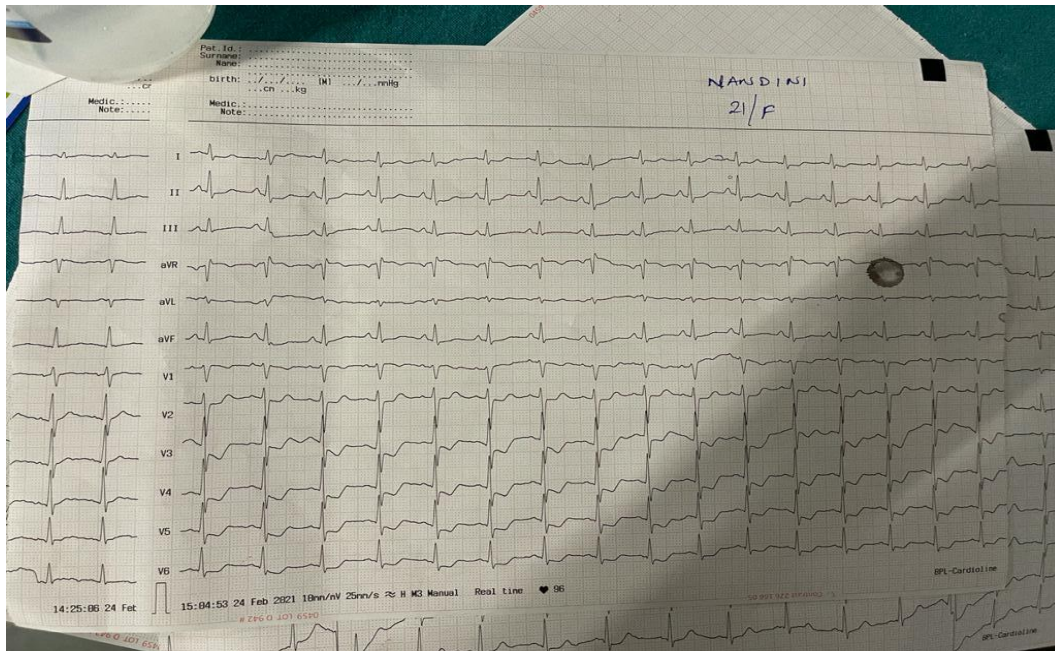


Figure 1: Global ST depression seen post intramuscular adrenaline

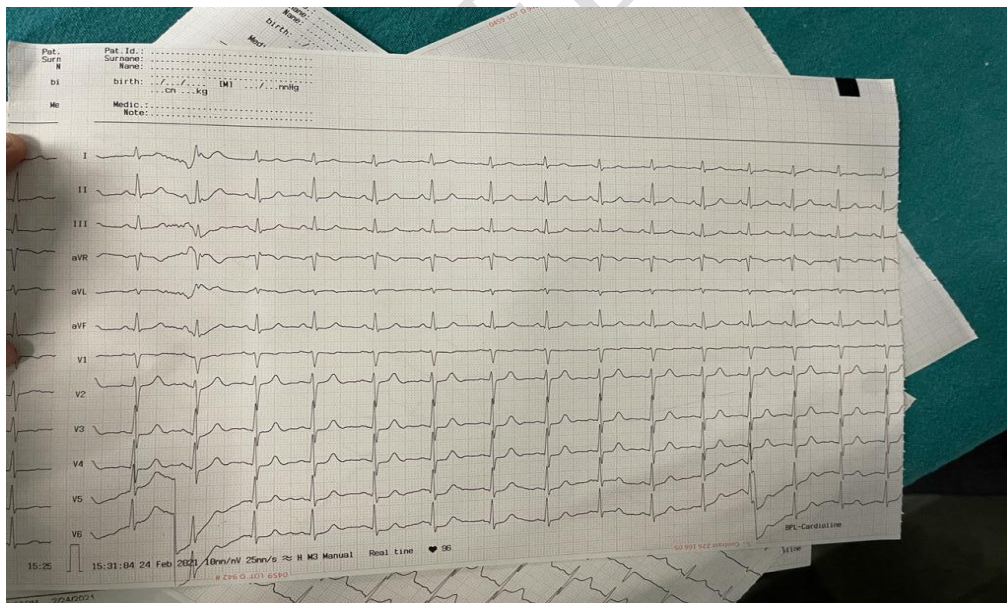


Figure 2: 30 minutes post intramuscular adrenaline – relative resolution in ST depression

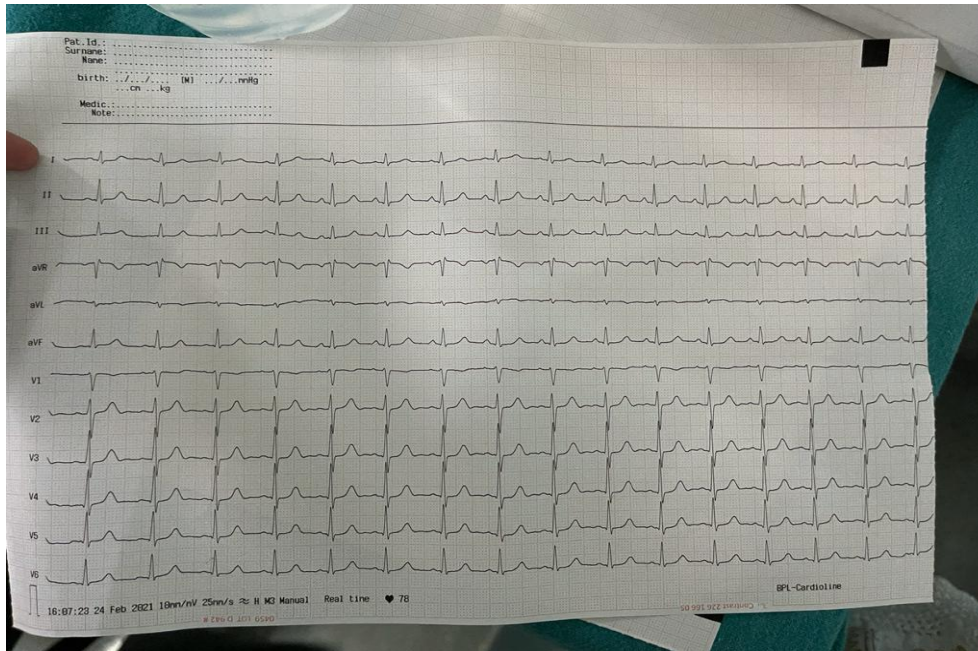


Figure 3: 60 minutes post intramuscular adrenaline- Normal Sinus Rhythm

### Discussion and conclusion

Myocardial infarction or injury in an anaphylactic reaction can be due to anaphylaxis i.e Kounis syndrome or due to adrenaline. Allergic angina or Kounis syndrome is an acute coronary syndrome. It occurs due to anaphylactic or anaphylactoid condition or mast cell activation [5]. A variety of cytokines, chemokines, neutral proteases (tryptase and chymase), arachdonic acid products, platelet activating factor and histamine are involved in it. These mediators cause coronary vasospasm and produce myocardial ischemia and infarction. There are 3 varaints of Kounis syndrome; Type I is when coronary vasospasm develops in those without any predisposing factors and is most likely as a result of microvascular angina or endothelial dysfunction. Type II have pre existing atheromatous plaques which undergo erosion or rupture due to allergic reaction and lead to an acute coronary event. The IIIrd variant includes coronary artery stent thrombosis secondary to allergic reaction [6]. A total of 5 cases have been reported where epinephrine has caused

myocardial infarction.[7 ] Out of these reports one was intramuscular use of epinephrine, another was after intravenous injection, two cases were following subcutaneous injection and one was where a subcutaneous epi pen auto injector was used.[8] adrenaline has high affinity for beta 1, beta 2, alpha 1 and alpha 2 receptors in cardiac and smooth muscles of the vascular wall [9] alpha 1 and 2 cause vasoconstriction of coronary vasculature while beta 1 and 2 lead to increased cardiac contractility and dilate coronary arteries. At low doses beta adrenergic effects are more predominant as compared to alpha [9].

Our patient developed transient myocardial ischemia following intramuscular injection which is regarded as a relatively safe route in comparison to intravenous [10]. This was demonstrated by Campbell and his colleagues on 573 patients studied by them.[11]. The risk of overdose with epinephrine was higher with intravenous route. Intravenous adrenaline is known to cause coronary vasospasm. [12]. Preexisting coronary artery disease, old age and beta blocker were some of the risk factors for epinephrine induced myocardial ischemia based on available evidence [13].

Adrenaline is a life saving medication in anaphylactic shock. Even though myocardial ischemia can occur on rare occasions with therapeutic doses of adrenalin its early use should not be averted. [14]. No contraindication exists for the use of adrenaline in the setting of life threatening anaphylaxis. [15]

This case report therefore highlights the case of a young female with no significant risk factors for coronary artery disease who developed transient myocardial ischemia post intramuscular adrenaline. Alpha 1 receptor mediated coronary vascular spasm is the most likely mechanism. The purpose of reporting this case is therefore to make one aware of the potential adverse effects of adrenaline and to keep the required measures at bay if and when they are required.

#### **COMPETING INTERESTS DISCLAIMER:**

Authors have declared that no competing interests exist. The products used for this research are commonly and predominantly use products in our area of research and country. There is absolutely no conflict of interest between the authors and producers of the products because we do not intend to use these products as an avenue for any litigation but for the advancement of knowledge. Also, the research was not funded by the producing company rather it was funded by personal efforts of the authors.



## References :

1. World allergy organization guidelines for the assessment and management of anaphylaxis. World Allergy Organization Journal. 2011;4(2):13.
2. Working group of the resuscitation council(UK); Emergency treatment of anaphylactic reactions,Guidelines for health care providers: 2008;77(2):157-69.
3. Shaver KJ, Adams C, Weiss SJ. Acute myocardial infarction after administration of low dose intravenous epinephrine for anaphylaxis. CJEM. 2006 Jul;8(4):289–94.
4. Cunnington C, McDonald JE, Singh RK;Epinephrine induced myocardial infarction in severe anaphylaxis:is non-selective beta blockade a contributory factor?: Am J Emerg Med 2013 Apr;31(4):759,e1-2. Epub 2013 Feb 4.
5. Kounis NG. Kounis syndrome (allergic angina and allergic myocardial infarction): a natural paradigm? Int J Cardiol. 2006;110:7–14.
6. Kounis NG. Coronary hypersensitivity disorder: the Kounis syndrome. Clin Ther. 2013;35(5):563–71.
7. Saff R, Naggas A, Flink JN. Myocardial infarction induced by coronary vasospasm after self-administration of epinephrine. Annals of allergy. 1993 May;70(5):396–8.
8. Thygesen K, Alpert JS, Jaffe AS, Simoons M. L et al. Third universal definition of myocardial infarction European Heart Journal. 2012;33:2551–67. doi: 10.1093/eurheartj/ehs184.
9. Overgaard CB. Dziaik. Inotropes and vasopressors:review of physiology and clinical use in cardiovascular disease. Circulation. 2008;2008(118):1047–56.
10. Wood JP, Traub SJ, Lipinski C. Safety of epinephrine for anaphylaxis in emergency setting. World J Emerg Med. 2013;4(4):245–51.
11. Campbell RL, Bellolio MF, Hess EP; Epinephrine in anaphylaxis:higher risk of cardiovascular complication and overdose after administration of intravenous

bolus epinephrine compared with intramuscular epinephrine;J Allergy Clin Immunol Pract ; 2015,vol.3 (1)76-80,doi10

12. Karch SB. Coronary artery spasm induced by intravenous epinephrine overdose. Am J Emerg Med. 1989;7:485–8.
13. McLean-Tooke APC, Bethune CA, Spickett GP. Adrenaline in the treatment of anaphylaxis: what is the evidence? BMJ. 2003 Dec 6;327(7427):1332–5.
14. Sampson HA, Mendelson L, Rosen JP. Fatal and near fatal anaphylactic reactions to food in children and adolescents. NEJM. 1992;327:380–4.
15. Simons KJ, Simons FE. Epinephrine and its use in anaphylaxis: current issues.
16. Curr Opin Allergy Clin Immunol. 2010;1;10(4):354-61.