

## **Original Research Article**

# **Role of Three-Dimensional Power Doppler Ultrasonography In Diagnosis Of Placenta Accreta Versus Two-Dimensional And Color Doppler Ultrasonography**

### **Abstract**

**Background:** Placenta accreta is a condition of abnormal placental implantation in which the placental tissue invades beyond the decidua basalis. It may invade into or even through the myometrium and adjacent organs, such as the urinary bladder. It is a major cause of obstetric hemorrhage and complication leading to significant maternal morbidity and mortality. The aim of this study is to compare the role of three-dimensional power Doppler ultrasonography in the antenatal diagnosis of placenta accreta .versus two-dimensional and color Doppler ultrasonography

**Methods:** A prospective comparative study design was conducted

This study was performed on 50 Pregnant females at the Department of Obstetrics and Gynecology, Tanta University Hospitals. The study was .conducted after approval of the Ethics Board Tanta University

:Inclusion criteria

Patients with placenta previa and previous one or more cesarian section at .gestational age from 28 weeks to 36weeks

The diagnosis of placenta previa confirmed using all diagnostic techniques (gray scale, color Doppler, and 3D power Doppler) and full availability of delivery information.

**Results:** abnormal placental lacunae was most frequently encountered in 2D gray scale ultrasound as it was noted in 12 (24.0%) patients, thinning or disruption of hyperechoic serosa-bladder interface was detected in 8 (16.0%) patients, loss of retroplacental sonolucent zone was detected in 7 (14.0%) patients, irregular retroplacental sonolucent zone was noted in 5 (10.0%) patients, while presence of focal exophytic masses invading the urinary bladder was the least encountered as it was noted in 4 (8.0 %) patients.

The 2D gray scale initially diagnose 52.0% of study participants as placenta accreta and 48.0% as had no placenta accreta.

**Conclusions:** There is no one imaging modality that provides the gold standard for diagnosing placental invasion. A high index of clinical suspicion is required for its detection in high risk patients. In contemporary obstetrical practice, this applies to patients with previous caesarean sections, and especially if there is a coexisting anterior low-lying placenta. A probable case of morbidly adherent placenta will benefit from preoperative multidisciplinary input and perioperative measures in preparation for an elective planned delivery

**Keywords** Three-Dimensional , Ultrasonography ,Placenta Accreta .

## Introduction:

Placenta accreta is a condition of abnormal placental implantation in which the placental tissue invades beyond the decidua basalis. It may invade into or even through the myometrium and adjacent organs, such as the urinary bladder. It is a major cause of obstetric hemorrhage and complication leading to significant maternal morbidity and mortality

(1)

The incidence of placenta accreta has increased with the rising number of cesarean deliveries. Current estimates indicate a 25% to 50% incidence of placenta accreta in patients with placenta previa and prior (3,2).cesarean delivery

In the past, this condition was often diagnosed at the time of delivery when massive and unexpected hemorrhage occurred. Hysterectomy, associated with significant physical and psychological consequences, was usually the only management option. As more obstetricians have become aware of this condition, early identification with antenatal imaging diagnostic technology has become possible. Antenatal diagnosis of placenta accreta can help to minimize the complication rate by enabling a surgeon to plan for the type of resources needed at the time of delivery which include obstetric anesthesia, appropriate surgical expertise, available blood products and cell saver technology, possibly interventional radiology for uterine artery (4).embolization, and postoperative intensive care

Antenatal diagnosis of placenta accreta based on characteristic finding in two-dimensional, color Doppler and three-dimensional ultrasonography, a normal placental attachment site is characterized by a hypoechoic boundary between the placenta and the bladder. The two-

dimensional ultrasonographic features suggestive of loss of retroplacental sonolucent zone. irregular retroplacental sonolucent zone, presence lacunae . color Doppler was used to scan all placenta to detect any newly formed vessel at serosa bladder border or presence of abnormal lacunae trans abdominal three dimensional Doppler ultrasonography features suggestive intraplacental hypervascularity, inseparable cotyledonal and intervillous circulations, and tortuous vascularity with chaotic branching (Chaotic branching) was defined as vessels growing in an irregular manner with tortuous courses varying calibers and complex vessel arrangement

The aim of this study is to compare the role of three-dimensional power Doppler ultrasonography in the antenatal diagnosis of placenta .accreta versus two-dimensional and color Doppler ultrasonography

## **Patients and Methods:**

A prospective comparative study design was conducted.

This study was performed on 50 Pregnant females at the Department of Obstetrics and Gynecology, Tanta University Hospitals. The study was conducted after approval of the Ethics Board Tanta University.

### **Inclusion criteria:**

- Patients with placenta previa and previous one or more cesarian section at gestational age from 28 weeks to 36weeks.
- The diagnosis of placenta previa confirmed using all diagnostic techniques (gray scale, color Doppler, and 3D power Doppler) and full availability of delivery information.

### **Exclusion criteria:**

- Haemodynamical unstable patient due to Sever vaginal bleeding.

### **3. Study Setting**

This study was conducted at Department of Obstetrics and Gynecology, Tanta University Hospitals.

Patients recruitment: the pregnant women who agreed and consented to participate in this study were collected from the outpatient clinics, during the period from September 2020 till July 2021.

#### **4. Sample size calculation and analysis**

Estimation of sample size is based on the following assumption: it is a two-arm comparison trial, relative risk 51%, two sided C.I. 95%. Accordingly, the sample size was set as 50 patients all of them will undergo to trans-abdominal and trans-vaginal ultrasound two dimensional and color Doppler and trans-abdominal and trans-vaginal three-dimensional powers Doppler.

**Investigational studies:** three-dimensional power Doppler ultrasonography, two dimensional gray scale ultrasonography and color Doppler ultrasonography for each patient, the whole placenta was scanned in a systematic fashion using both gray-scale ultrasound and color flow mapping. The placenta was imaged with a sufficient bladder volume to clearly visualize the serosa–bladder interface, and the angle of insonation was kept as low as possible.

On gray-scale ultrasound imaging, we considered the presence of at least one of the following characteristics to indicate placenta accreta (including its variants, placenta increta and placenta percreta):

- (1) complete loss of the retroplacental sonolucent zone.
- (2) irregular retroplacental sonolucent zone.
- (3) thinning or disruption of the hyperechoic uterine serosa–bladder interface.
- (4) the presence of focal exophytic masses invading the urinary bladder.
- (5) the presence of abnormal placental lacunae.<sup>(53)</sup>

Likewise, the diagnosis of placenta accreta was regarded as positive when any one of these color Doppler criteria was present:

- (1) diffuse or focal lacunar flow pattern

- (2) sonolucent vascular lakes with turbulent flow typified by high velocity (peak systolic velocity >15 cm/s) and low resistance waveform
- (3) hypervascularity of the uterine–bladder interface with abnormal blood vessels linking the placenta to the bladder
- (4) markedly dilated vessels over the peripheral sub placental.<sup>(54)</sup>

To analyze the angioarchitecture of the lower uterine segment and placenta, we carried out a 3D power Doppler examination targeted to this region. Three to five 3D volumes were obtained in automatic sweeps using a motorized curved-array transducer while the women held their breath.

In order to interpret the data consistently, the settings of power, pulse repetition frequency, gain and wall motion filter were maintained for all examinations at 100%, 0.9 kHz, –5.4 and low2, respectively.

Two views were successively evaluated: the lateral view was used to observe the intraplacental vasculature and serosa–bladder complex along the sagittal axis of the maternal pelvis, and the basal view illustrated the serosa–bladder interface in a 90° rotation of the lateral view (observing from the direction of the bladder). Since the abundant neovascularization of the uteroplacental region is a notable feature of placenta accreta, we further analyzed the patterns of placental vasculature in an attempt to differentiate between placenta previa totalis and placenta accreta. We made the diagnosis of placenta previa without accreta when the following 3D power Doppler criteria were demonstrated: (1) in the basal view, the vessels in the uterine serosa–bladder border were discretely arranged (2) in the lateral view, both cotyledonal (fetal villous) circulation and intervillous (maternal) circulation were essentially parallel to each other, and perpendicular to the decidual plate; (3) the cotyledonal and intervillous circulation were separately



distributed; and (4) the cotyledonal circulation was longer and more apparent than the intervillous circulation.<sup>(55)</sup>

Conversely, the diagnosis of placenta accreta and its variants was regarded as positive if at least one of the following 3D power Doppler criteria was illustrated: in the lateral view, (1) intraplacental hypervascularity, (2) inseparable cotyledonal and intervillous circulations, and (3) tortuous vascularity with chaotic branching. 'Chaotic branching' was defined as vessels growing in an irregular manner, with tortuous courses, varying calibers and complex vessel arrangement.<sup>(56)</sup>

Furthermore, the basal view revealed numerous coherent vessels involving the serosa–bladder interface.

All the pregnancies enrolled in this study were delivered by Cesarean section at tanta university hospital.

Definitive diagnosis of placenta accreta was made at delivery when the myometrium was seen to be invaded by the placenta, and in some cases the pathological examination of the removed uterus when supravaginal hysterectomy was mandatory showed the villi attached to the myometrium without intervening decidua (accreta), invading into myometrium(increscenta)or reaching the serosa (percreta)

## **6. Data Management and Statistical Analysis**

- The collected data were organized, tabulated and statistically analyzed using SPSS version 19 (Statistical Package for Social Studies) created by IBM, Illinois, Chicago, USA.
- For numerical values the range mean, median and standard deviations were calculated.

- For categorical variable, the number and percentage were calculated.
- ROC curve was also used to determine the diagnostic accuracy of different diagnostic methods of placenta accreta according to final diagnosis in the current study.
- The level of significant was adopted at  $p < 0.05$ .

UNDER PEER REVIEW

## Results

### I. Demographic characteristics of the studied participants.

**Table (1)** Demographic characteristics of the studied sample.

All patients (n= 50)		Mean & SD	Median	Range	IQR
Age		30.18 ± 5.082	29.50	20, 41	26.75, 34.00
Residence	Urban	38.0% (19)			
	Rural	62.0% (31)			
Occupation	Housewife	62.0% (31)			
	Worker	38.0% (19)			
Data is expressed as mean and standard deviation, median, range and interquartile range or as percentage and frequency.					

Table 2 shows that the age of our patients ranged from 20 to 41 years old, at the time of diagnosis with mean age 30.18 years, more than half (62.0%) of This study participants were from rural area, and most of them (62.0%) were housewives.

### II. Obstetric history of the studied participants

**Table (2)** Obstetric history of the studied sample.

All patients (n= 50)		Mean & SD	Median	Range	IQR
Gravidity		4.14 ± 0.756	4.00	3, 5	4.00, 5.00
Parity		2.30 ± 0.909	2.00	1, 4	2.00, 3.00
CS		2.44 ± 0.951	3.00	1, 4	2.00, 3.00
Abortion		0.70 ± 0.647	1.00	0, 2	0.00, 1.00
Data is expressed as mean and standard deviation, median, range and interquartile range.					

Table 3 shows that the mean number of gravidities of This study participants ( $4.14 \pm 0.756$ ), the mean number of parities was ( $2.30 \pm 0.909$ ), the mean number of CS was ( $2.44 \pm 0.951$ ), the mean number of abortions was ( $0.70 \pm 0.647$ ).

#### IV. 2D gray scale ultrasound

**Table (3)** Findings by 2D gray scale ultrasound in the current study.

All patients (n= 50)		Frequency	Percentage
Loss of retroplacental sonolucent zone		7	14.0%
Irregular retroplacental sonolucent zone		5	10.0%
Abnormal placental lacunae		12	24.0%
Thinning or disruption of hyperechoic serosa-bladder interface		8	16.0%
Presence of focal exophytic masses invading the urinary bladder		4	8.0%
Initial diagnosis by gray scale	<b>No placenta accreta</b>	24	48.0%
	<b>Placenta accreta</b>	26	52.0%
Data is expressed as percentage and frequency.			

Tables 5 shows that abnormal placental lacunae was most frequently encountered in 2D gray scale ultrasound as it was noted in 12 (24.0%) patients, thinning or disruption of hyperechoic serosa-bladder interface was detected in 8 (16.0 %) patients, loss of retroplacental sonolucent zone was detected in 7 (14.0 %) patients, irregular retroplacental sonolucent zone was noted in 5 (10.0%) patients, while presence of focal exophytic masses invading the urinary bladder was the least encountered as it was noted in 4 (8.0 %) patients.

The 2D gray scale initially diagnose 52.0% of study participants as placenta accreta and 48.0% as had no placenta accreta.

## V. 2D color doppler ultrasound

**Table (4)** Findings by 2D color doppler ultrasound in the current study.

All patients (n= 50)		Frequency	Percentage
Diffuse or focal lacunar flow pattern		12	24.0%
Sonolucent vascular lakes with turbulent flow		5	10.0%
Hypervascularity of the uterine–bladder interface		8	16.0%
Markedly dilated vessels over the peripheral sub placental region		4	8.0%
Initial diagnosis by 2D Color Doppler	No placenta accreta	27	54.0%
	Placenta accreta	23	46.0%
Data is expressed as percentage and frequency.			

Tables 6 shows that diffuse or focal lacunar flow pattern was most frequently encountered in 2D color doppler ultrasound as it was noted in 12 (24.0%) patients, hypervascularity of the uterine–bladder interface was noted in 8 (16.0 %) patients, sonolucent vascular lakes with turbulent flow was detected in 5 (10.0 %) patients, while markedly dilated vessels over the peripheral sub placental region was the least encountered as it was noted in 4 (8.0 %) patients.

The 2D color doppler initially diagnose 46.0% of study participants had placenta accreta and 54.0% as had no placenta accreta.

## VI. 3D Doppler ultrasound

**Table (5)** Findings by 3D Doppler ultrasound in the current study:

All patients (n= 50)		Frequency	Percentage
Intraplacental hypervascularity		16	32.0%
Inseparable cotyledonal and intervillous circulations		17	34.0%
Tortuous vascularity with chaotic branching		11	22.0%
Initial diagnosis by 3D Doppler	<b>No placenta accreta</b>	24	48.0%
	<b>Placenta accreta</b>	26	52.0%
Data is expressed as percentage and frequency.			

Tables 7 shows that Inseparable cotyledonal and intervillous circulations was most frequently encountered in 3D Doppler ultrasound as it was noted in 17 (34.0%) patients, Intraplacental hypervascularity was noted in 16 (32.0 %) patients, while Tortuous vascularity with chaotic branching was the least encountered as it was noted in 11 (22.0 %) patients.

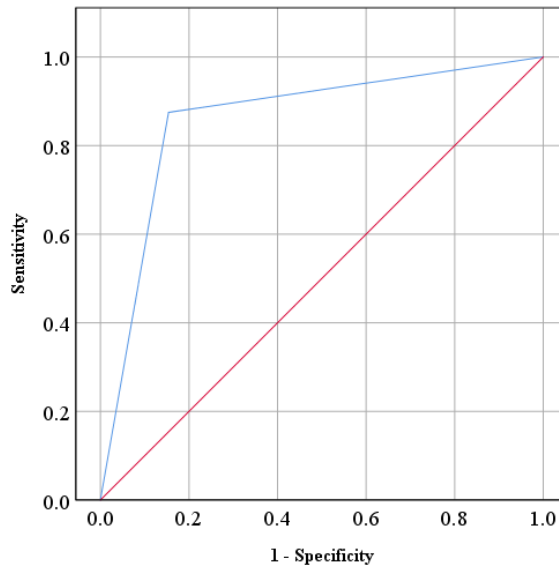
The 3D color doppler initially diagnose 52.0% of study participants had placenta accreta and 48.0% as had no placenta accreta.

**Table (6)** Diagnostic profile of different diagnostic methods of placenta accreta according to final diagnosis in the current study.

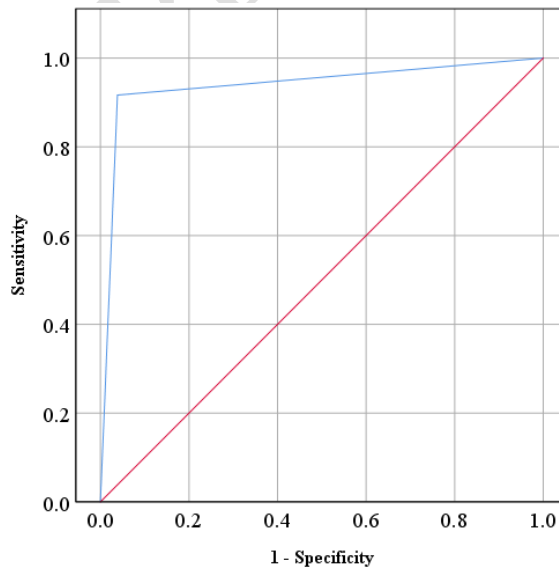
	Gray scale	2D color doppler	3D Doppler
AUC	0.861	0.939	0.921
95% CI of AUC	0.749, 0.972	0.861, 1	0.835, 1
p	<b>&lt; 0.001</b>	<b>&lt; 0.001</b>	<b>&lt; 0.001</b>
Sensitivity	87.5%	91.7%	95.8%
Specificity	84.6%	96.2%	88.5%
PPV	84.0%	95.7%	88.5%

## Results

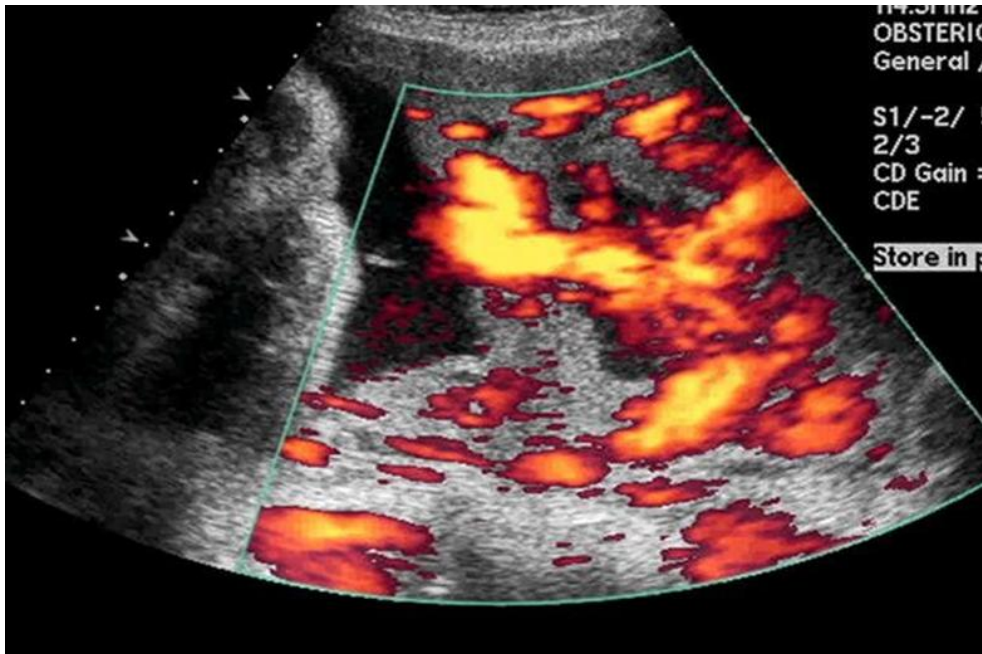
NPV	88.0%	92.6%	95.8%
Accuracy	86.0%	94.0%	92.0%
P is significant when $< 0.05$ .			



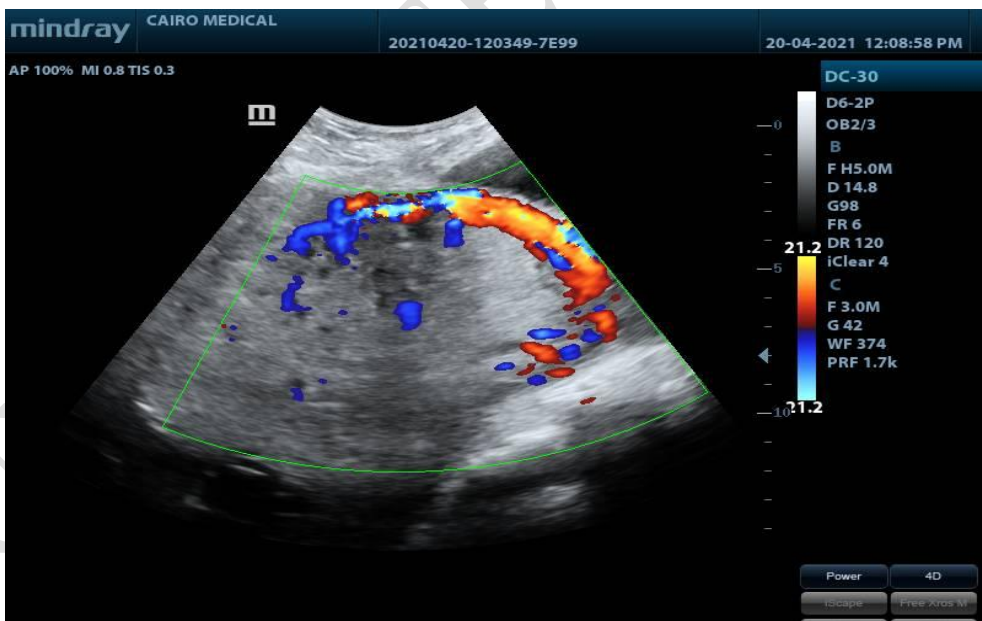
**Figure (1).** ROC curve of Gray scale according to final diagnosis in the current study.



**Figure (2).** ROC curve of 2D color doppler according to final diagnosis in the current study.

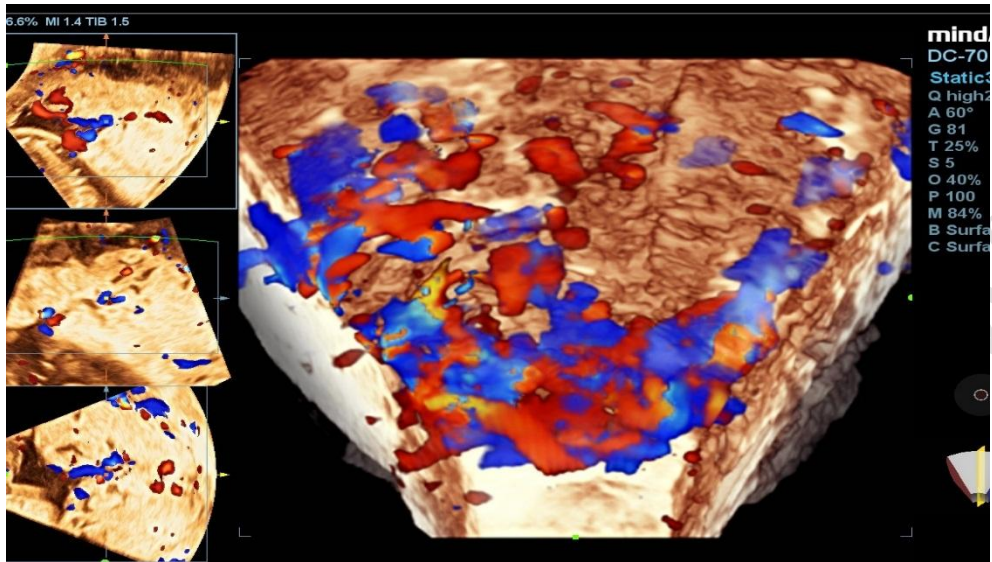


**Figure 3.** Placenta lacunae as seen with color Doppler.



**Figure4.** hypervascularity of the uterine-bladder interface.





**Figure 5.** Intraplacental hypervascularity on 3D doppl

UNDER PEER REVIEW

## **Discussion**

Placenta accreta encompasses various types of abnormal placentation in which chorionic villi attach directly to or invade the myometrium. PA is a significant cause of maternal morbidity and mortality and is now the most common reason for emergent postpartum hysterectomy.<sup>5</sup>

Early diagnosis can improve the perinatal prognosis by enabling preparations for a possible obstetric emergency to be made such as hysterectomy and massive transfusion.<sup>(59,60)</sup>

So, this study was carried out to compare the role of three-dimensional power Doppler ultrasonography in the antenatal diagnosis of placenta accreta with two-dimensional and color Doppler ultrasonography.

Our study results have revealed that, the age of our patients ranged from 20 to 41 years old, at the time of diagnosis with mean age 30.18 years, more than half (62.0%) of our study participants were from rural area, and most of them (62.0%) were housewives. Regarding our study participants obstetric history, the mean number of gravidities of our study participants was 4.14, the mean number of parities was 2.30, the mean number of CS was 2.44, the mean number of abortions was 0.70.

Andrew et al. and Silver et al.<sup>6</sup> reported that as Cesarean section rate has increased, there has been a concomitant increase in PA, their statistics illustrate the importance of the number of Cesarean sections as a risk factor for PA.

Also, Yang et al., and Shih et al.<sup>7-8)</sup> found that prior cesarean section and placenta previa are the two most important risk factors for developing placenta accreta and should elicit a detailed evaluation.

Moniem et al.<sup>9</sup> reported that previous cesarean delivery and parity are the two known risk factors for PA, and the incidence of PA is increased concomitantly with increased cesarean section rates

D'Antonio et al. concluded that the incidence of PA increased in the past decades as a consequence of increasing cesarean section rates.<sup>(10)</sup>

In contrast to Wright et al. who concluded that there was no significant relation among parity, number of previous cesarean deliveries, degree of placental invasion, and massive blood loss.<sup>(11)</sup>

In our study according to the final diagnosis by histopathology it was founded that 3D Doppler yielded the highest true false positive diagnoses 100.0%, followed by Gray-scale US (95.8%), then 2D Color Doppler (79.2%). The 3D power Doppler alone yielded the fewest false positive diagnoses (0 cases, vs. 5 cases by color Doppler criteria and 1 case by gray-scale).

In SHIH et al.<sup>(12)</sup> study, it was founded that 3D power Doppler alone yielded the fewest false positive diagnoses (19 cases, vs. 36 cases by gray-scale and 40 cases by color Doppler criteria). Most of the false-positive diagnoses that arose from gray-scale criteria were due to the 'irregularity or absence of retroplacental echolucent zone' and 'abnormal lacunae'. The 'absent or irregular retroplacental echolucency' in these non-accreta patients was probably due to a defective decidua with marked thinning of the myometrium. This may be due to a poor healing process after previous Cesarean delivery. The criteria of 'hypervascularity', 'abnormal lacunae' and 'coherent basal vessels' led to most of the false-positive diagnoses on color Doppler and 3D power Doppler imaging. Also, it was founded that 3D

Doppler yielded the highest true false positive diagnoses (90%) followed by 2D Color Doppler (72%) , then by Gray-scale US (67%).

In Shweel et al. <sup>(13)</sup> study, it was founded that regarding the final surgical and pathological reports included patients confirmed the diagnosis of placenta accreta in 11/28 (39.2%) patients. Color Doppler was correct in 10/15 (66.6%) patients, five false positive and one false negative. The low false negative was contributed to the fact that all placentas were anterior in position. On the other hand, a high false positive could be explained by the fact that 16 patients had more than one prior CS with the formation of bladder varices and neovascularized vessels mistaken as abnormal bladder–uterine serosa interface hypervascularity which was assumed to be placenta accreta. The false-negative one was obese and had a pregnancy with breech presentation, in this patient, the color Doppler imaging diagnostic errors were due to shadowing by fetal parts leading to false negative results.

In our study, gray scale, color Doppler, and 3D power Doppler were used to make an antenatal diagnosis of placenta accrete. Given the unique clinical management of placenta accreta, the PPV and NPV of these diagnostic measures are as important as the sensitivity and specificity.

Several authors have attempted to make an antenatal diagnosis of placenta accreta sonographically, Yang et al., Hong et al., Comstock et al., Elsayes et al., and Sumigama et al. <sup>(14-16)</sup> reported that conventional gray-scale ultrasonographic criteria for the diagnosis of adherent placenta can be useful in determining the patient's clinical outcome, as well as in preparing her for surgery.

In this study, the 2D gray scale initially diagnose 52.0% of study participants as placenta accreta and 48.0% as had no placenta accreta. It had

sensitivity 87.5 % to predict placenta accreta, specificity 84.6 %, positive predictive value 84.0 %, negative predictive value 88.0 %, accuracy 86.0 %

Warshak et al. found that 2D gray scale ultrasound accurately diagnosed PA with 77% sensitivity and ruled out PA with 96% specificity.

(17)

Haidar *et al.* <sup>(18)</sup> reported 2D gray scale ultrasound sensitivity of 82.6%, specificity of 88.9%, PPV of 85.5%, and NPV of 85%. Moniem *et al.* <sup>(89)</sup> reported sensitivity of 73.9%. Antonio *et al.* <sup>(90)</sup> reported sensitivity to detect placenta accrete was 77.43% and specificity was 95.02%. Cali *et al.* <sup>(91)</sup> reported sensitivity of 73% specificity of 86%, PPV 60%, and NPV 90%.

In this study, 2D color Doppler US initially diagnose 46.0% of study participants had placenta accreta and 54.0% as had no placenta accrete, it had sensitivity 91.7 % to predict placenta accreta, specificity 96.2 %, positive predictive value 95.7 %, negative predictive value 92.6 %, accuracy 94.0 %

Similar to our study, Shweel et al. <sup>(19)</sup> reported that color Doppler ultrasound has been suggested to aid in the diagnosis of placenta previa accrete because it highlights abnormal areas of hypervascularity with dilated blood vessels within the placental and uterine tissues. In his study, Color Doppler sonography showed sensitivity 90%, accuracy 78%, specificity 70%, positive predictive value 67%, and negative predictive value 92% for the diagnosis of placenta accreta.

Bonnie et al. <sup>(20)</sup> reported that color Doppler sonography showed (93% sensitivity; and 71% specificity).

In contrast to, Warshak et al. <sup>(21)</sup> who stated that color Doppler sonography had sensitivity of 77% and specificity of 96%. This can be

explained by the low false negative results in our study which may be contributed to the fact that all placentas were anterior in position. On the other hand, a high false positive could be explained by the fact that most of patients had more than one prior CS with the formation of bladder varices and neovascularized vessels mistaken as abnormal bladder-uterine serosa interface hypervascularity which was assumed to be placenta accreta.

Thia et al.<sup>22)</sup> Study reported that the sensitivity of 2D colour Doppler ultrasonography in diagnosing placenta previa accrete has ranged between 82% and 100%, and the specificity between 92% and 97%. Colour Doppler ultrasonography appears to be informative, as it is able to display the velocity and nature of the flow. High velocity and turbulent flow are always associated with placenta accreta. The placental vessels are usually large, and this can only be picked up by using colour Doppler.

However, Levine et al. reported that colour Doppler ultrasonography does not add any additional information that could already be obtained from grayscale ultrasonography.<sup>(23)</sup>

Recently, 3D ultrasound and 3D Power Doppler were introduced for the detection of PA. Using 3D power Doppler, the vascularization index, flow index (FI), and vascularization FI can be used for the detection of PA using the VOCAL method in the ROI.<sup>(24)</sup>

In this study, the 3D color doppler initially diagnose 52.0% of study participants had placenta accreta and 48.0% as had no placenta accreta. It had sensitivity 95.8% to predict placenta accreta, specificity 88.5%, positive predictive value 88.5%, negative predictive value 95.8%, accuracy 92.0%

Zhang *et al.* found that color Doppler had 77.3% sensitivity, 98.4% specificity, 85.0% PPV, and 97.4% in the diagnosis of placenta increta. Zhang *et al.* concluded that prenatal color Doppler ultrasound has a high sensitivity and specificity for the identification of placenta previa increta.<sup>(25)</sup>

Chou *et al.* found that color Doppler had 82.4% sensitivity, 96.8% specificity, 87.5% and 95.3% positive and NPVs, respectively.<sup>(26)</sup>

In our study, We looked at the comparison of sensitivity, specificity and accuracy of Gray scale US, 2D color Doppler sonography and 3D Doppler US in the diagnosis of placenta accreta, we found that 3D Doppler US was the most sensitive to predict placenta accreta, while 2D color doppler US was the most specific and accurate than gray scale US and 3D Doppler.

Chou et al. concluded that 3D ultrasound can be used as an adjunctive tool with 2D ultrasound to identify the extent of invasion in the cases of MAP.<sup>(27)</sup> Advantages of 3D ultrasound are (1) Multiplanes image display (sagittal, coronal and axial planes at the same time), (2) Viewing planes of vasculature can be manipulated to identify vessels invading bladder.<sup>(101)</sup>

In the study by Hesham *et al.*, the sensitivity of color Doppler sonography was 100%, 93.7% for 2D sonography.<sup>(28)</sup>

The results of Kamankesh et al. study showed that the use of a combination of gray scale and color Doppler sonographic findings in detecting placenta accreta in anterior placenta improves the diagnosis.<sup>(29)</sup>

The advantages of our study were that three modalities were used in the same group of patients with direct comparison of the sensitivity,



specificity and accuracy of Gray scale US, 2D color Doppler sonography and 3D Doppler US in them.

We acknowledge that there are some potential pitfalls in our study was the small sample size and the narrow zone of selection of patients with normal placental position and limited number of prior uterine surgery, so we tested the sensitivity and accuracy of the three modalities in the diagnosis of PA in low risk patients.<sup>30</sup>

It is important to remember that 3D power Doppler does have certain limitations including those that result from post-processing of the signal, such as the threshold and transparency settings, as well as those related to the relative weighting of the power Doppler and gray-scale signals when the data are displayed as a three-dimensionally rendered 'glass body image

## Conclusions:

There is no one imaging modality that provides the gold standard for diagnosing placental invasion. A high index of clinical suspicion is required for its detection in high risk patients. In contemporary obstetrical practice, this applies to patients with previous caesarean sections, and especially if there is a coexisting anterior low-lying placenta. A probable case of morbidly adherent placenta will benefit from preoperative multidisciplinary input and .perioperative measures in preparation for an elective planned delivery

3D Doppler US was the most sensitive to predict placenta accreta, while 2D color doppler US .was the most specific and accurate than gray scale US and 3D Doppler

The use of 3D power Doppler ultrasonography as a complementary diagnostic technique together with the 2D gray scale ultrasonography and 2D color Doppler ultrasonography helps to confirm or exclude the antenatal diagnosis of morbidly adherent placenta

## References:

1. Taylor DK, Leppert PCJDDTTS (2012): Treatment for uterine fibroids: searching for effective drug therapies. 9: e41-e9.
2. Ferri FF. Ferri's Clinical Advisor 2017 E-Book: 5 Books in 1: Elsevier Health Sciences; 2016.
3. Sabry M, Halder SK, Allah ASA, Roshdy E, Rajaratnam V, Al-Hendy AJIjowsh (2013): Serum vitamin D3 level inversely correlates with uterine fibroid volume in different ethnic groups: a cross-sectional observational study. 5: 93.

4. Vilos GA, Allaire C, Laberge P-Y, Leyland N, Vilos AG, Murji A, et al. (2015): The management of uterine leiomyomas. 37: 157-78.
5. Masciocchi C, Arrigoni F, Ferrari F, Giordano AV, Iafrate S, Capretti I, et al. (2017): Uterine fibroid therapy using interventional radiology mini-invasive treatments: current perspective. 34: 52.
6. Montenegro KR, Cruzat V, Carlessi R, Newsholme PJNrr (2019): Mechanisms of vitamin D action in skeletal muscle. 32: 192-204.
7. Corachán García A (2019): Understanding the effect of Vitamin D treatment on human uterine leiomyoma growth using in vitro and in vivo models.
8. Feng C, Meldrum S, Fiscella KJIJoG, Obstetrics (2010): Improved quality of life is partly explained by fewer symptoms after treatment of fibroids with mifepristone. 109: 121-4.
9. Sharan C, Halder SK, Thota C, Jaleel T, Nair S, Al-Hendy AJF, et al. (2011): Vitamin D inhibits proliferation of human uterine leiomyoma cells via catechol-O-methyltransferase. 95: 247-53.
10. Brakta S, Diamond JS, Al-Hendy A, Diamond MP, Halder SKJF, sterility (2015): Role of vitamin D in uterine fibroid biology. 104: 698-706.
11. Pérez-López FR, Ornat L, Ceausu I, Depypere H, Erel CT, Lambrinoudaki I, et al. (2014): EMAS position statement: management of uterine fibroids. 79: 106-16.
12. Bulun SEJNEJoM (2013): Uterine fibroids. 369: 1344-55.
13. Chowdhury S, Islam M, Shrestha S, Selim S EFFECT OF VITAMIN D SUPPLEMENTATION ON THE SIZE OF UTERINE FIBROIDS.
14. Henry HLJBp, endocrinology rC, metabolism (2011): Regulation of vitamin D metabolism. 25: 531-41.
15. Oskovi Kaplan ZA, Taşçi Y, Topçu HO, Erkaya SJGE (2018): 25-Hydroxy vitamin D levels in premenopausal Turkish women with uterine leiomyoma. 34: 261-4.

16. Hajhashemi M, Ansari M, Haghollahi F, Eslami BJCjoim (2019): The effect of vitamin D supplementation on the size of uterine leiomyoma in women with vitamin D deficiency. 10: 125.
17. Thomas MK, Lloyd-Jones DM, Thadhani RI, Shaw AC, Deraska DJ, Kitch BT, et al. (1998): Hypovitaminosis D in medical inpatients. 338: 777-83.
18. Haq A, Wimalawansa SJ, Pludowski P, Al Anouti FJTJosb, biology m (2018): Clinical practice guidelines for vitamin D in the United Arab Emirates. 175: 4-11.
19. Ciavattini A, Carpini GD, Serri M, Vignini A, Sabbatinelli J, Tozzi A, et al. (2016): Hypovitaminosis D and “small burden” uterine fibroids: Opportunity for a vitamin D supplementation. 95.
20. Ajmani SN, Sarbhai V, Singh S, Ajmani A, Pant LJIO, Gynaecology (2018): To establish the association of vitamin d levels with leiomyoma and its role as a risk factor for development of leiomyoma uterus. 8.
21. Yan L, Gu Y, Luan T, Miao M, Jiang L, Liu Y, et al. (2018): Associations between serum vitamin D and the risk of female reproductive tumors: A meta-analysis with trial sequential analysis. 97.
22. Zgaga L, Theodoratou E, Farrington SM, Agakov F, Tenesa A, Walker M, et al. (2011): Diet, environmental factors, and lifestyle underlie the high prevalence of vitamin D deficiency in healthy adults in Scotland, and supplementation reduces the proportion that are severely deficient. 141: 1535-42.
23. Sowah D, Fan X, Dennett L, Hagtvedt R, Straube SJBph (2017): Vitamin D levels and deficiency with different occupations: a systematic review. 17: 1-25.
24. Paffoni A, Somigliana E, Vigano' P, Benaglia L, Cardellicchio L, Pagliardini L, et al. (2013): Vitamin D status in women with uterine leiomyomas. 98: E1374-E8.

25. Mitro SD, Zota ARJRT (2015): Vitamin D and uterine leiomyoma among a sample of US women: Findings from NHANES, 2001–2006. 57: 81-6.
26. Baird DD, Dunson DB, Hill MC, Cousins D, Schectman JMJAjoo, gynecology (2003): High cumulative incidence of uterine leiomyoma in black and white women: ultrasound evidence. 188: 100-7.
27. Li S, Chen B, Sheng B, Wang J, Zhu XJJJoIMR (2020): The associations between serum vitamin D, calcium and uterine fibroids in Chinese women: a case-controlled study. 48: 0300060520923492.
28. Holick MFJNEJoM (2007): Vitamin D deficiency. 357: 266-81.
29. Baird DD, Hill MC, Schectman JM, Hollis BWJE (2013): Vitamin D and risk of uterine fibroids. 24: 447.
30. Ali M, Chaudhry ZT, Al-Hendy AJEoodd (2018): Successes and failures of uterine leiomyoma drug discovery. 13: 169-77.
31. Kumari S, Babu B, Singh SJIJSR (2019): Association of vitamin D, calcium and phosphate with uterine fibroid in premenopausal women of coastal Odisha. 8: 27-9.
32. Arjeh S, Darsareh F, Asl ZA, Kutenaei MAJCTicp (2020): Effect of oral consumption of vitamin D on uterine fibroids: a randomized clinical trial. 39: 101159.
33. Halder SK, Goodwin JS, Al-Hendy AJTJoCE, Metabolism (2011): 1, 25-Dihydroxyvitamin D3 reduces TGF- $\beta$ 3-induced fibrosis-related gene expression in human uterine leiomyoma cells. 96: E754-E62.
34. Halder SK, Sharan C, Al-Hendy AJBor (2012): 1, 25-dihydroxyvitamin D3 treatment shrinks uterine leiomyoma tumors in the Eker rat model. 86: 116, 1-10.
35. Halder SK, Osteen KG, Al-Hendy AJBor (2013): 1, 25-dihydroxyvitamin d3 reduces extracellular matrix-associated protein expression in human uterine fibroid cells. 89: 150, 1-13.

36. ElHusseini H, Elkafas H, Abdelaziz M, Halder S, Atabiekov I, Eziba N, et al. (2018): Diet-induced vitamin D deficiency triggers inflammation and DNA damage profile in murine myometrium. 10: 503.
37. Heaney RP, Davies KM, Chen TC, Holick MF, Barger-Lux MJJAjocn (2003): Human serum 25-hydroxycholecalciferol response to extended oral dosing with cholecalciferol. 77: 204-10.
38. Ali M, Laknaur A, Shaheen S, Sabri N, Al-Hendy AJF, Sterility (2017): Vitamin D synergizes the antiproliferative, apoptotic, antifibrotic and anti-inflammatory effects of ulipristal acetate against human uterine fibroids. 108: e66.