

Rhino-orbital-cerebral mucormycosis during pandemic of covid-19: a first case reported in Libya

Abstract-Mucormycosis is an unusual systemic infection caused by multicellular fungi. Despite, few reports have been documented world widely, incidences of mucormycosis are recently increasing due to several predisposing factors such as diabetes, COVID-19 pandemic, and over prescription of corticosteroids. The clinical symptoms of this disease are often unfamiliar and vague. Based on the published literatures, this is the first report that describes a case of clinical human mucormycosis during the COVID-19 pandemic in Libya. This report discusses also the risk factors and steps that can be applied to prevent occurrence of this disease. The patient is a 58-year-old Libyan female who presented with a history of COVID-19 infection, diabetes mellitus, hypertension, hypothyroidism, obesity, obstructive sleep apnea, and stable ischemic heart disease. She was complaining of loss of vision of the right eye, redness, and swelling all over the right face with scattered areas of blackish discoloration involving the inner third of the right eye and right face. Clinical examination showed bilateral basal and mid-lung fields fin crepitation, abdominal distension, severe chemosis, proptosis, restriction of all eye movement, anisocoria, upper lid ptosis and loss of corneal sensation of right

eye. CT-Scan of brain, para-nasal sinus, orbit revealed right periorbital cellulitis, right eye proptosis, right ethmoidal, maxillary, sphenoidal sinusitis, and right cavernous sinus thrombosis without bone erosion. The histopathological report showed numerous broad branching aseptate hyphae and spores with acute cellulitis indicating an invasive fungal infection (mucormycosis). Mucormycosis is a rare fatal disease. Physician awareness and early management may significantly reduce mucormycosis severity.

Keywords: *Mucomycosis, COVID-19, diabetes, hyphae, fungi, infection, ROCM.*

I. Introduction:

Since the onset of the COVID-19 pandemic, there have been several reported cases across the country at very high risk to mucormycosis among patients with COVID-19 (active cases, recovering or post-discharging) especially in those who are uncontrolled diabetic, immune-compromised or those who have received corticosteroids [1]. In few reports, the COVID-19 associated mucormycosis has been documented worldwide. A case series in Indian reported six cases of rhino-orbital-cerebral mucormycosis (ROCM) following COVID-19 infections. The mean duration between the diagnosis of COVID-19 and

the developing symptoms of mucormycosis was 15.6 ± 9.6 days [2-3].

Mucormycosis is a rare opportunistic fungal infection with high morbidity and mortality rates caused by the family of Mucorales (Mucor, Rhizopus or Absida) [4]. Destructive rhino-orbital-cerebral and pulmonary infections were the most common syndromes caused by these fungi [4]. Originally, these fungi were found in the soil and on decaying vegetation, as they live as saprophytic fungi. The fungi can become airborne due to their rapid growth and release of large numbers of spores.

Despite the habitual presence of the agents of mucormycosis in the environment and all humans may have been exposed to these fungi during daily activities, the mucormycosis is still a rare human infection in presence of an intact human immune system. In humans, mucormycosis infections occur almost in the presence of some underlying compromising condition [5].

In a reviewed report that included 101 COVID-19 patients with mucormycosis, it was found 80% of those patients had pre-existing diabetes mellitus, and 76% of them had received glucocorticoids for COVID-19 treatment. Mucormycosis in almost (90%) of these patients involved noses and sinuses with a mortality rate of 31%. As mucormycosis primarily targets the blood vessels (angioinvasive), tissue infarction is a hallmark of this infection [6].

The importance of this case report lies in the relatively few cases that have been reported across the world, to our knowledge, it is the first reported

case in Libya and to support the challenge in the diagnose and management of such cases during the Covid-19 pandemic.

II. Case report

A 58-year-old Libyan female presented to COVID-19 clinic at Misrata Medical Center (MMC) on 04th of August, 2021 with a history of fever, cough, shortness of breath, abdominal pain, general fatigability, and diarrhea. She had a previous history of long-standing type-2 diabetes mellitus, hypertension, hypothyroidism, obesity, obstructive sleep apnea, and stable ischemic heart disease. The patient was on insulin (30 IU-morning and 25 IU-evening), exforge (amlodipine 5mg/valsartan 80 mg/day), Levothyroxin (100 mcg/day), Aspirin 75 mg tablet daily, and fraxiparine 0.6 ml daily.

Based on the medical examination, the patient had normal blood pressure (130/80mmHg), heart rate of 89 beats/minute and fever (39 °C). The respiratory rate is 32/minute with 91% oxygen saturation on a non-rebreathing mask. The systemic medical examination revealed bilateral basal and mid-lung fields fin. Her initial laboratory investigations showed a significant increase in C-reactive protein (CRP 283 mg/dl), lymphopenia, and high random blood sugar (340mg/dl). Molecular study confirmed the diagnoses of COVID-19 infection. High resolution CT-Scan (HR-CT-Scan) of chest showed radiological criteria of severe COVID-19 infection.

She was then admitted to the isolation department. Four days later, the patient had rapid progression to critical COVID-19 infection and acute respiratory distress syndrome, she was connected to mechanical ventilation until the 16th of August. The patient was treated intravenously with antibiotics (tienam and ciprofloxacin), remdesivir, actemra, and dexamethasone (6 mg) in the period between the fourth to seventeenth of August.

On 14th of August, the patient started complaining of vision loss, drooping and swelling in the right eyelid with complete loss of sensation in that area and the new appearance of blackish lesions at the inner third of the right eyelid and nose. Ophthalmological observations were right upper eyelid complete ptosis, right ophthalmoplegia, anisocoria and right eye protosis. It was diagnosed as orbital cellulitis and 3rd cranial nerve palsy.

The patient was discharged from the isolation department on 17th of August 2021.

On 21st of August, she visited the medical outpatient department and her main complaints were persistence of right eye vision loss and worsening blackish discoloration of her inner 1/3 of right eye, periorbital swelling, redness involving nearly all the right side of her face. Laboratory investigations revealed a moderate elevation in WBC 16800 cell/ μ L, D-dimer 1.05 μ g/ml, random blood sugar 339 mg/dl and CRP 16 mg/l; while other investigations were normal (HB 11.8 gm/dl, platelets 281000 cell/ μ L, creatinine 0.5 mg/dl, urea 35 mg/dl, serum sodium 139.3 mmol/l, serum potassium 4.4 mmol/l, procalcitonin 0.256 ng/ml, normal arterial blood

gas). Therefore, The patient was admitted to the female medical ward at MMC for further medical evaluation.

Based on reviewing the literatures, the history and clinical examination of post-admission visit, we are able to deduce the ROCM was the most likely first provisional diagnosis. Treatment by amphotricine-B was started (antifungal agent) and at the same time, a brain CT-Scan study was requested and an incisional biopsy of skin of the right upper eyelid was taken for histopathological study. CT-Scan of para-nasal sinus, orbit and the brain revealed right periorbital cellulitis, right eye proptosis, right ethmoidal, maxillary and sphenoidal sinusitis, right cavernous sinus thrombosis.

The histopathological report showed acute cellulitis with invasive fungal infection (mucormycosis). Based on haematoxylin/eosin (H&E) and periodic acid-Schiff stains (PSA), it was noticed that there were numerous broad branching aseptate hyphae with spores which clearly supported the clinical finding of mucormycosis (Figure 1, 2 and 3).

Despite the initial significant improvement and good response to antifungal treatment (no more fever, subside of hemi-facial redness and swelling and a significant reduction in CRP levels), the patient had a sudden cardiac attack and had died a few days later.

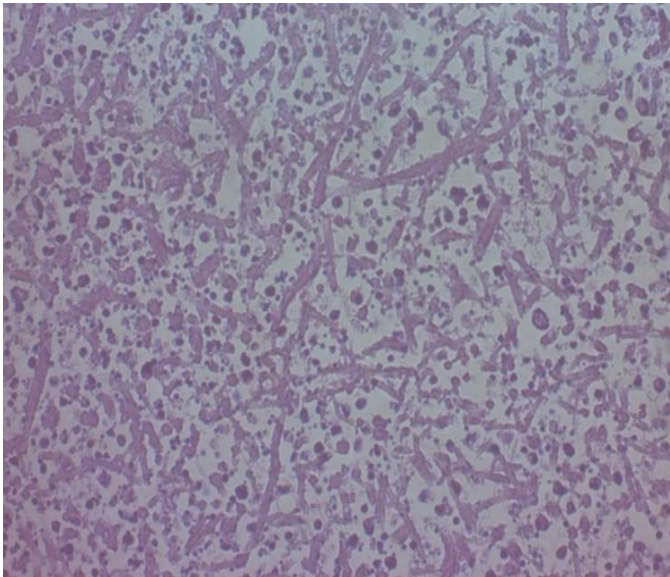


Figure 1: shows invasive fungal mucormycosis (H&E, 20X).

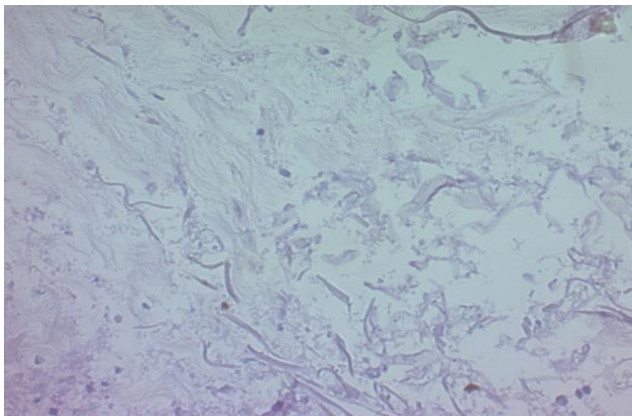


Figure 2: shows invasive fungal mucormycosis (H&E, 10X).

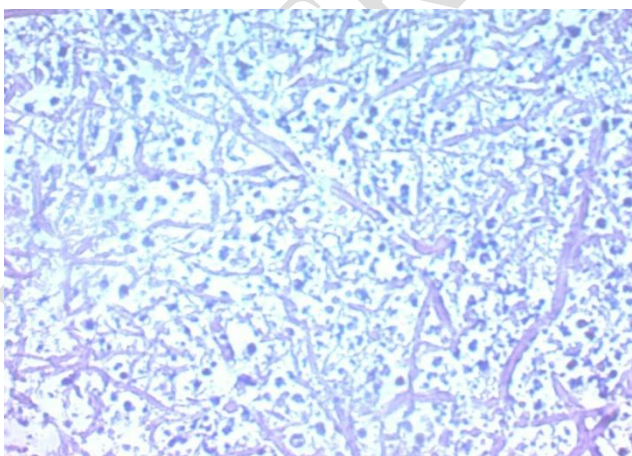


Figure 3: shows invasive fungal mucormycosis (PAS stain, 20X).

III. Discussion

The incidence of mucormycosis is difficult to be estimated since its risk varies widely in different populations. In addition, it is not a reportable disease. Many medical conditions are predisposing factors to mucormycosis, diabetic individuals have the highest risk to ROCM. Elevated serum free iron level in diabetic patients could be a trigger factor hence high serum iron (at an acidic pH) enhance the growth of *Rhizopus oryzae* [7-8].

Furthermore, in diabetic individuals, there are important alterations in both innate and adaptive immunity. These alterations in immune system may cause a significant reduction in phagocytosis, cytokine release, chemotaxis, and Natural killer cell activity with more pro-inflammatory macrophages. In presence of high blood sugar levels, this dysregulation of immune system response (delayed in IFN- γ response and expected exaggeration of inflammatory response), all together exacerbate the cytokine storm and increase COVID-19 severity. These remodeling in host response are considered as a major factor to predict disease severity and attenuate the antiviral response.

The endothelial inflammation and vasoconstriction in mucormycosis infection further put individuals with diabetes at a greater risk for endophthalmitis in several organs. Disease severity is not only predicted by viral load but also by the host response.

Risk factors to mucormycosis may include diabetes mellitus, particularly with ketoacidosis [4,9,10], treatment with glucocorticoids [11], hematologic malignancies [1,12,13],

transplantations [4,11,14,15]. Treatment with deferoxamine [6,16,17], iron overload [17], AIDS, trauma/burns [15,18,19] and malnutrition

Practical recommendations to prevent over surge in mucormycosis including a proper description of corticosteroids, tight control of diabetes, and early disease detection through increased clinical awareness. It is important to have a high index of suspicion for fungal co-infection in immune compromised patients infected by COVID-19. Furthermore, suspected patients should undergo immediate imaging studies with an emphasis on the requirement of surgical intervention. It is fundamental to insist on the retraction use of corticosteroids to avoid flaring up of the fungal infection.

Clinicians should be aware of the possible ROCM as a complication of COVID-19, especially in diabetic patients. Diabetes mellitus is an independent risk factor for ROCM. Prevention of COVID-19 associated mucormycosis needs to focus on aiming for better glycemic control in COVID-19 patients and monitoring the use of systemic corticosteroids in treating severe cases.

Outpatient use of systemic corticosteroids and other immune-modulating drugs for mild or moderate patients with COVID-19 should be avoided. Early diagnosis and treatment of mucormycosis using both antifungal therapy and surgical debridement are necessary to reduce mortality and prevent end-organ damage. For successful management of mucormycosis, a high index of clinical suspicion, low threshold for diagnosis in patients with risk factors,

neuroimaging and specific diagnostic tests with a coordinated effort from a multidisciplinary team including ophthalmology, otorhinolaryngology, infectious diseases, neurosurgery, critical care, microbiology, and pathology department are crucial. Simple tests like vision, pupil, ocular motility and sinus tenderness can be part of routine physical evaluation of a patient with COVID-19 hospitalized with moderate to a severe infection or diabetics with COVID-19 or those receiving systemic corticosteroids.

IV. Conclusion

Health providers should be aware of possible opportunistic systemic fungal infections in sub-group of patients who are at high risk such as COVID-19 diabetic patients treated by corticosteroids. Therefore, routine simple tests of sinus tenderness and rapid ophthalmological assessment may significantly improve the outcome of mucormycosis. As most uncontrolled diabetic patients have a weak immune system, the addition of corticosteroids could decrease immune system response to fungal and viral infections.

COMPETING INTERESTS DISCLAIMER:

Authors have declared that no competing interests exist. The products used for this research are commonly and predominantly use products in our area of research and country. There is absolutely no conflict of interest between the authors and producers of the products because we do not intend to use these products as an avenue for any litigation but for the advancement of knowledge. Also, the research was not funded by the producing company rather it was funded by personal efforts of the authors.

References

- [1] Kauffman CA, Malani AN. Zygomycosis: an emerging fungal infection with new options for management. *Curr Infect Dis Rep* 2007; 9:435.

- [2] Oliver A Cornely, Ana Alastruey-Izquierdo et al. Global guideline for the diagnosis and management of mucormycosis: an initiative of the European Confederation of Medical Mycology in cooperation with the Mycoses Study Group Education and Research Consortium. *Lancet Infect Dis* 2019; 19: e405–21.
- [3] Evidence based advisory in the times of COVID19. https://www.icmr.gov.in/pdf/covid/techdoc/Mucormycosis_ADVISORY_FROM_ICMR_In_COVID19_time.pdf accessed 26 May 2021
- [4] Roden MM, Zaoutis TE, Buchanan WL, et al. Epidemiology and outcome of zygomycosis: a review of 929 reported cases. *Clin Infect Dis* 2005; 41:634.
- [5] GALE GR, WELCH AM. Studies of opportunistic fungi. I. Inhibition of *Rhizopus oryzae* by human serum. *Am J Med Sci* 1961; 241:604.
- [6] Boelaert JR, Van Cutsem J, de Locht M, et al. Deferoxamine augments growth and pathogenicity of *Rhizopus*, while hydroxypyridinone chelators have no effect. *Kidney Int* 1994; 45:667.
- [7] Ibrahim AS, Spellberg B, Walsh TJ, Kontoyiannis DP. Pathogenesis of mucormycosis. *Clin Infect Dis* 2012; 54 Suppl 1:S16.
- [8] Artis WM, Fountain JA, Delcher HK, Jones HE. A mechanism of susceptibility to mucormycosis in diabetic ketoacidosis: transferrin and iron availability. *Diabetes* 1982; 31:1109.
- [9] McNulty JS. Rhinocerebral mucormycosis: predisposing factors. *Laryngoscope* 1982; 92:1140.
- [10] Farmakiotis D, Kontoyiannis DP. Mucormycoses. *Infect Dis Clin North Am* 2016; 30:143.
- [11] Kontoyiannis DP, Wessel VC, Bodey GP, Rolston KV. Zygomycosis in the 1990s in a tertiary-care cancer center. *Clin Infect Dis* 2000; 30:851.
- [12] Kontoyiannis DP, Lionakis MS, Lewis RE, et al. Zygomycosis in a tertiary-care cancer center in the era of *Aspergillus*-active antifungal therapy: a case-control observational study of 27 recent cases. *J Infect Dis* 2005; 191:1350.
- [13] Trifilio SM, Bennett CL, Yarnold PR, et al. Breakthrough zygomycosis after voriconazole administration among patients with hematologic malignancies who receive hematopoietic stem-cell transplants or intensive chemotherapy. *Bone Marrow Transplant* 2007; 39:425.
- [14] Lanternier F, Sun HY, Ribaud P, et al. Mucormycosis in organ and stem cell transplant recipients. *Clin Infect Dis* 2012; 54:1629.
- [15] Lanternier F, Dannaoui E, Morizot G, et al. A global analysis of mucormycosis in France: the RetroZygo Study (2005-2007). *Clin Infect Dis* 2012; 54 Suppl 1:S35.
- [16] Boelaert JR, Fenves AZ, Coburn JW. Deferoxamine therapy and mucormycosis in dialysis patients: report of an international registry. *Am J Kidney Dis* 1991; 18:660.
- [17] Maertens J, Demuyneck H, Verbeken EK, et al. Mucormycosis in allogeneic bone marrow transplant recipients: report of five cases and review of the role of iron overload in the pathogenesis. *Bone Marrow Transplant* 1999; 24:307.
- [18] Legrand M, Gits-Muselli M, Boutin L, et al. Detection of Circulating Mucorales DNA in Critically Ill Burn Patients: Preliminary Report of a Screening Strategy for Early Diagnosis and Treatment. *Clin Infect Dis* 2016; 63:1312.
- [19] Ling H, Yuan Z, Shen J, et al. Accuracy of matrix-assisted laser desorption ionization-time of flight mass spectrometry for identification of clinical pathogenic fungi: a meta-analysis. *J Clin Microbiol* 2014; 52:2573.