

Fusion Assessment in Stand Alone Oblique lumbar interbody fusion in Adult Degenerative Lumbar Scoliosis

Abstract

Background data: Lumbar spine degenerative disease is developed due to aging. Kirkandly Willis in 1983 hypothesized that theory 'the three-joint complex' as the primary cause usually causes the degeneration during the age progression and causes for the spine degenerative processes. Kirkandly also divided the degeneration diseases into three steps beginning from the malfunction of important structures including degeneration of the intervertebral disk and facet arthropathy into destabilization disease that results in segmental instability until re-stabilization that is caused mainly by formation of osteophytes and stenosis of the canal.

Study Design: Prospective clinical case study

Objective: To assess the fusion rates in patients suffering from degenerative lumbar spine deformities after stand-alone OLIF.

Patients and Methods: Patients with ADS following specific inclusion criteria underwent SA OLIF. Pre-, and Post-operative clinical data; back and leg pain 'VAS score' and ODI, radiological data; spinopelvic parameters, segmental Cobb angle and anterior disc height, and intra-operative data; operative time, amount of blood loss, complications 'intra-operative or post-operative' and hospital stay were all analyzed and compared statistically.

Results: A total of 28 patients and 30 levels were operated by SA OLIF, with mean age 50.54 ± 6.05 included 14 males and 14 females. The mean operative time/min, blood loss/ml and hospital stay/day was 91.29 ± 14.23 , 195.54 ± 42.299 and 2.78 ± 0.875 respectively. The mean of Back Pain 'VAS', The mean of Leg Pain 'VAS' and ODI changed from pre-operatively 7.36 ± 0.98 , 6.36 ± 0.911 and 68.615 ± 8.72 to 4.07 ± 1.01 , 2.07 ± 0.9 and 20.23 ± 4.7 in 1-year respectively. In this study we had 92.9% fusion rates after 1-year. Operative complications occurred in 3 cases with segmental artery injury. Post-operative complications were 1 cage dislodgment immediately post-operative and 2 cases of cage subsidence after 1-year.

Conclusion: SA OLIF can result in high rates of fusion. There are multiple factors that determine the rate of fusion such as the quality of the vertebrae and endplate preservation during the preparation procedure.

Keywords: OLIF, scoliosis, degenerative lumbar diseases, spinopelvic, Cobb angle, deformity, fusion

Introduction

Lumbar spine degenerative disease is developed due to aging. Kirkandly Willis [1] in 1983 hypothesized that theory 'the three-joint complex' as the primary cause usually causes the degeneration during the age progression and causes for the spine degenerative processes. Kirkandly also divided the degeneration diseases into three steps beginning from the malfunction of important structures including degeneration of the intervertebral disk and facet arthropathy

into destabilization disease that results in segmental instability until re-stabilization that is caused mainly by formation of osteophytes and stenosis of the canal. [1]

Adult lumbar degenerative scoliosis has at its beginning in the same manner by broader definition of adult scoliosis which is a deformity in the coronal plane of the spine where Cobb angle of greater than 10 degrees measured. However, it is especially for those adults and who had a normal spine alignment before.[2,3] Its process is very similar to the process of degenerative disc diseases (DDD). Along to this process there is an important concept of disease progression of the imbalance in the spine axial load causing the adult degenerative scoliosis (ADS).[4] This pathology with no specific causes results from a multimodal process of degenerative lumbar diseases.[5]

Ralph Cloward was the first spine surgeon to implement the basic ideas of interbody fusion in 1940s.[6] Since then enhancements in the spine fusion methods have increased. The operations of interbody fusion targets to stabilize the spine and decompress the neural elements by restoring the height of the disk. Lumbar spine interbody fusion can certainly deal with a group of spine diseases like DDD, deformities and tumors. [7] Oblique lumbar interbody fusion (OLIF) is one of the spine fusion methods used. It was implemented to take over the side effects of the commonly used interbody fusions like anterior (ALIF), lateral (LLIF) or posterior (PLIF) interbody fusions.[8] OLIF can obtain spinal stability, improve sagittal or coronal alignment and indirectly free the neural structures with less disadvantages related to traditional transposas or retropsoas approaches. OLIF technique gives access to work from L1 to S1.[9]

This series aims for assessing the fusion of the SA OLIF in the correction of adult lumbar degenerative deformity.

Patients and Methods

This is a prospective study in between Suez Canal University hospitals, Neurosurgery department and Nottingham university hospitals, Center for spinal studies from January 2019 to January 2021. Inclusion criteria: I. Degenerative lumbar spine diseases associated with deformity in either sagittal or coronal plans including fresh or recurrent pathology, II. Age between 30-70 years of any sex, and III. Failure of adequate conservative therapy. Exclusion criteria: I. Osteoporosis 'T-score <-2.5" and II. Other pathologies 'Trauma, Tumor, metabolic diseases.

Preoperative evaluation

Clinical assessment of back and leg pain's Visual Analogue Score (VAS) score', full neurological examination, and Oswestry Disability Index (ODI), and II. Radiological evaluation included Full spine X-ray AP, Lateral and dynamic views 'flexion and extension' to measure lumbar cobb angle, sagittal vertical axis (SVA), pelvic tilt (PT), pelvic incidence (PI), sacral slope (SS), and pelvic incidence/ lumbar lordosis mismatch using Surgimap®, MRI lumbosacral spine and DXA.

Operative technique:

All patients underwent the OLIF procedures in left lateral decubitus position with ipsilateral hip flexion under general anesthesia on a radiolucent operating table. Stabilizing the patient by the operating table belt and additional taping is done. Jack knifing the table to distract the intracoastal space for widening the surgical field. Fluoroscopy guided leveling is obtained and marked on the skin over the center of the disc space in AP and Lat. Views. Starting by surgical sterilization and draping followed by oblique skin incision anterior to the disc space mark.

Incision is 4-10 cm according to the number of levels intended to be operated on followed by blunt dissection of the oblique abdominal muscles. After reaching the retroperitoneal space marked by the fat appearance below the internal oblique muscle, blunt dissection by Kelly Clamps until reaching the Quadratus lumborum and the Psoas muscles. Syn-Frame blades are inserted in a 4-blade fashion 2 lateral and 2 in cranio-caudal position. The operating field is between the Psoas muscle and the abdominal Aorta. Standard annulectomy and discectomy is initiated. A wide intervertebral space is important to acquire, consequently, discectomy is done in a wide space. The Contra-lateral annulus is carefully opened by a Cobb dissector and confirmed by fluoroscopy. Trials are inserted until reaching the desired intervertebral cage size, followed by insertion of the Cage “Spineway Kili cages®”. Hemostasis is done in case of any bleeding, followed by removal of the Syn-Frame blades and insertion of a suction drain. Fascial and skin closure in layers is the final step (Figure1).

Postoperative evaluation

Clinical assessment included back and leg pain VAS, ODI and full neurological examination after 6 months and 12 months. Radiological evaluation included spine Xray erect in AP and lateral view and MSCT of the lumbosacral spine. The following outcome parameters were recorded at each visit; segmental coronal Cobb angle, LL, coronal cobb angle, SVA, PT, PI, SS, LL, PI/LL mismatch, and fusion grade. II. According to CT scan, fusion grading was as following; grade 1: Bridging trabecular bone, grade 2: Continuous bony density, grade 3: Marginal Radiolucency, grade 4: Secondary signs of motion, grade 5: Hardware loosening and fatigue, and grade 6: Subsidence.[10]

Statistical analysis:

The SPSS (Statistical Package for the Social Sciences) 18.0 software package was used for the statistical analysis of the data. Chi-squared statistics were employed in the comparison of categorical measurements between groups, and independent t tests were employed for the comparison of numerical measurements between groups. The statistical significance level was taken as 0.05 in all tests.

Results

28 patients (14 males and 14 females) were recruited for this study after exclusion of who have lost during the follow up. All patients suffered from single level disc disease except two patients who had two level pathology (Figure 2,3 and 4). Demographic data, pre-operative clinical data (Back and leg pain VAS, ODI) and co-morbidities are shown in (Tables 1 and 2).

The mean operative time was 91.29 ± 14.23 min and the mean blood loss was 195.54 ± 42.499 ml. The mean back pain VAS decreased from 7.36 ± 0.99 preoperative to 5.64 ± 0.87 in 6-months and 4.07 ± 1.02 in 1 year follow up. The mean leg pain VAS decreased from 7.36 ± 0.99 preoperative to 5.9 ± 0.54 immediately post-operative, 4.01 ± 0.9 in 6-months and to 2.07 ± 0.9 in 1 year follow up. The mean ODI also decreased from 68.615 ± 8.72 preoperative to 41.38 ± 8.5 in 6-months and to 20.23 ± 4.7 in 1 year follow up (Tables 2 and 3).

Operative complications were reported in 4 cases. Three cases had vascular injuries to radicular ‘segmental’ arteries during blunt dissection over the vertebral bodies and managed by monopolar electrocautery without clinical sequel. One patient had one of his two cages anterior dislodgment post-operatively and this cage was removed, and the patient underwent posterior instrumentation

in the same setting (Figure 5). Two patients had cage subsidence and refused to have further surgery (Table 4).

Discussion

Since its first description in 1977, OLIF has been found effective and safe utilizing a natural corridor between psoas muscle and great vessels retroperitoneally in various studies.[11–13]. In this series, stand-alone OLIF has proven to be effective in managing cases of degenerative lumbar spine diseases. The Mean age for the patients were 50.54 ± 6.05 years, 50% were males and 50% were females, and the mean duration of the symptoms was 34.44 ± 16.68 months. Xi et al.[14] in a study comparing ALIF to OLIF on 127 patients with mean age of 63.73 ± 10.80 and 66 patients who underwent OLIF were 24 males and 42 were females. He et al. [15] in a study of SA OLIF versus combined OLIF with percutaneous fixation had 32 patients underwent SA OLIF, males were 31.3% and females were 68.7%. The mean age for the SA OLIF group was 59.8 ± 13.7 years.

In this study total number of OLIF was 30 levels, L2/L3 were 8, L3/L4 were 17 and L4/L5 were 5. Xi et al. in their comparative study between ALIF and OLIF showed that OLIF was done in 66 patients were 31 patients were operated from L4 to S1, 12 were operated from L3 to S1 and 23 were operated from L2 to S1. Xi et al.[14] Liu et al.[16] in a study of Modic changes with SA OLIF, had 78 patients underwent OLIF with 92 levels operated as following; L2/L3 were 6, L3/L4 were 28 and L4/L5 were 58.

Pre-operative clinical findings statistically improved at 6-months and 1-year follow-ups as following; back pain VAS changed from 7.36 ± 0.99 pre-operatively to 5.64 ± 0.870 at 6 months and 4.07 ± 1.01 at 1 year, leg pain VAS changed from 6.36 ± 0.91 pre-operatively to 4 ± 0.903 at 6 months and 2.07 ± 0.9 at 1 year and ODI changed from 68.615 ± 8.72 preoperative to 41.38 ± 8.5 at 6-months and to 20.23 ± 4.7 at 1 year. Anand et al. in a prospective study of 111 patients with ASD from January 2015 to January 2019 underwent OLIF L5, S1[17] showed statistically significant improvement in the clinical findings in their series. He et.al. in a retrospective cohort study of patients underwent OLIF or OLIF and posterior instrumentation between July 2014 and October 2017 showed a significant VAS and ODI improvement after 1 week and 3 months post-operatively in SA OLIF group.[15] Abbasi et al.[18] in a retrospective study of 37 cases with ADS operated with OLIF in 2017, reported improvement in the pain scale from 8.3 to 3.7 and ODI decreased from 53% to 32%. Zhang et.al., in a study between October 2016 to January 2017 of 45 OLIF levels, showed significant improvement in ODI and VAS as well.[19] Kanno et.al.[20] in a case report study in 2014 showed a successful improvement in his series of back pain and leg pain of 2 cases with spinal stenosis at levels L5/S1.

Hospital stay in this study was 2.78 ± 0.875 (2-5) days. Xi et al.[14] in their study had mean hospital stay for their patients 7.02 ± 2.65 days, the possible cause is that they use posterior instrumentation along with OLIF. Xi et al. Zhu et al. in their comparative study between SA OLIF and PLIF proved that SA OLIF was superior over PLIF in operative time, Intraoperative bleeding, bed rest postoperative and hospital stay as the mean operative time was 52.24 ± 6.24 min. for SA OLIF and 134.32 ± 15.84 min. for PLIF group, the mean intraoperative bleeding was 34.94 ± 4.05 ml for SA OLIF and 340.68 ± 15.84 ml for PLIF, the mean bed rest 2.47 ± 0.51 days for SA OLIF and 6.95 ± 0.91 days for PLIF and The mean hospital stay was 6 ± 1.12 days for SA OLIF and 13.10 ± 1.40 days for PLIF.

Published data on SA OLIF complications has ranged between 3.7% to 66.7%. 19,39. Zeng ZY et al. [25] in a review of 235 patients with OLIF between October 2014 to May 2017, had 22 cases of endplate damage and a higher prevalence of cage subsidence than the posterior instrumented group. The specific pathophysiology of endplate damage is still unknown, consequently, avoiding such complication needs more biomechanical studies of SA OLIF. Fang et al.,[26] in a finite element study between SA OLIF and posterior instrumentation with OLIF in 2020, found that in SA OLIF models had less limited range of motions than posterior instrumented group. In addition, they concluded that posterior instrumented group with OLIF had better outcomes in cage subsidence and SA OLIF has higher risk for endplate damage and cage subsidence. However, He et al., [27] in a study of the paraspinal muscle atrophy between SA OLIF and posterior instrumentation with OLIF found that SA OLIF had superior clinical outcomes at 1 week and 3 months over the other group and SA OLIF may not result in paraspinal muscle atrophy at 24 months post-operatively. SA OLIF provided 30.2% increase in dural sac cross-sectional area and 30% increase in foramen cross sectional area.[28] However, SA OLIF advantages over combined method disappeared by the 2-year follow up period. This may be due to that SA OLIF does not include muscular manipulation of the spine like the posterior instrumentation, and by the 2-year follow-up when muscle hematomas disappear, and healing is full both methods had equal results.²⁵

In this study we had 92.9% fusion rates after 1-year, 2 cases had cage subsidence (7.1%) after 1-year were found although clinically not troubled much but the radiological finding during follow-up detected them. Huo et al. [30] in a prospective study of 154 patients underwent OLIF in 2019, had 2.4% cage subsidence in his series and they studied the cases with subsidence and proved that their T-score on DEXA was < -1.0 , consequently, they found that patients with T-score < -1.0 are at higher risk of cage subsidence, they performed DEXA as a routine pre-operative evaluation for all patients undergoing SA OLIF. Abbasi et al.[18] had 100% fusion rate in his retrospective series. He et al. [15] had 15.6% cage subsidence in his series of SA OLIF compared with 7.3% in the OLIF combined with posterior instrumentation. Zeng et al.[19] reported 36.3% cage subsidence and he directed the cause to the endplate damage done during surgery. Lin et al.[31] reported 81.9% fusion rate in his series at 1-year follow-up. Kim et al. [32] reported 92.9% fusion rates at 1-year follow-up. Xi et al. [14] in a comparative study between ALIF and OLIF, they used posterior instrumentation in both groups had the fusion rates of OLIF group 76.3%. Liu et al.[33] in their retrospective study of the correlation between SA OLIF, Modic changes and risk of subsidence found that 34.8% of their patients had Modic changes at the 1- year follow up duration. In these 34.8% with Modic changes only 1 patient had cage subsidence, while the remaining patients with no Modic changes had 6 patients with subsidence. Limitations of this study are, first the small sample size that likely affected the statistical power, then the expensive cage used for OLIF technique and the short follow-up duration. Large sample size prospective and long-term case control studies are required to give a wide prospect about the efficacy and validity of OLIF.

Conclusion

SA OLIF can result in high rates of fusion. There are multiple factors that determine the rate of fusion such as the quality of the vertebrae and endplate preservation during the preparation procedure.

References

- [1] Yong-Hing K, Kirkaldy-Willis WH. The pathophysiology of degenerative disease of the lumbar spine. *Orthop Clin North Am* 1983;14:491–504.
- [2] Gupta MC. Degenerative scoliosis: options for surgical management. *Orthopedic Clinics* 2003;34:269–79.
- [3] Grubb SA, Lipscomb HJ, Coonrad RW. Degenerative adult onset scoliosis. *Spine (Phila Pa 1976)* 1988;13:241–5.
- [4] Bess S, Schwab F, Lafage V, Shaffrey CI, Ames CP. Classifications for adult spinal deformity and use of the Scoliosis Research Society–Schwab adult spinal deformity classification. *Neurosurgery Clinics* 2013;24:185–93.
- [5] Ailon T, Smith JS, Shaffrey CI, Lenke LG, Brodke D, Harrop JS, et al. Degenerative spinal deformity. *Neurosurgery* 2015;77:S75–91.
- [6] Cloward RB. The treatment of ruptured lumbar intervertebral discs by vertebral body fusion: I. Indications, operative technique, after care. *J Neurosurg* 1953;10:154–68.
- [7] Kaiser MG, Eck JC, Groff MW, Watters III WC, Dailey AT, Resnick DK, et al. Guideline update for the performance of fusion procedures for degenerative disease of the lumbar spine. Part 1: introduction and methodology. *Journal of Neurosurgery: Spine* 2014;21:2–6.
- [8] Mobbs RJ, Phan K, Malham G, Seex K, Rao PJ. Lumbar interbody fusion: techniques, indications and comparison of interbody fusion options including PLIF, TLIF, MI-TLIF, OLIF/ATP, LLIF and ALIF. *Journal of Spine Surgery* 2015;1:2.
- [9] Orita S, Inage K, Furuya T, Koda M, Aoki Y, Kubota G, et al. Oblique Lateral Interbody Fusion (OLIF): Indications and techniques. *Operative Techniques in Orthopaedics* 2017;27:223–30.
- [10] Bridwell KH, Lenke LG, McEnery KW, Baldus C, Blanke K. Anterior fresh frozen structural allografts in the thoracic and lumbar spine. Do they work if combined with posterior fusion and instrumentation in adult patients with kyphosis or anterior column defects? *Spine (Phila Pa 1976)* 1995;20:1410–8.
- [11] Mayer MH. A new microsurgical technique for minimally invasive anterior lumbar interbody fusion. *Spine (Phila Pa 1976)* 1997;22:691–9.
- [12] Faundez AA, Mehbod AA, Wu C, Wu W, Ploumis A, Transfeldt EE. Position of interbody spacer in transforaminal lumbar interbody fusion: effect on 3-dimensional stability and sagittal lumbar contour. *Clinical Spine Surgery* 2008;21:175–80.
- [13] Ohtori S, Mannoji C, Orita S, Yamauchi K, Eguchi Y, Ochiai N, et al. Mini-open anterior retroperitoneal lumbar interbody fusion: oblique lateral interbody fusion for degenerated lumbar spinal kyphoscoliosis. *Asian Spine J* 2015;9:565.
- [14] Xi Z, Chou D, Mummaneni P v, Ruan H, Eichler C, Chang C-C, et al. Anterior lumbar compared to oblique lumbar interbody approaches for multilevel fusions to the sacrum in adults with spinal deformity and degeneration. *Journal of Neurosurgery: Spine* 2020;33:461–70.
- [15] He W, He D, Sun Y, Xing Y, Wen J, Wang W, et al. Standalone oblique lateral interbody fusion vs. combined with percutaneous pedicle screw in spondylolisthesis. *BMC Musculoskelet Disord* 2020;21:1–9.

- [16] Liu J, Feng H. Oblique lateral interbody fusion (OLIF) with supplemental anterolateral screw and rod instrumentation: a preliminary clinical study. *World Neurosurg* 2020;134:e944–50.
- [17] Anand N, Alayan A, Agrawal A, Kahwaty S, Nomoto E, Khandehroo B. Analysis of spino-pelvic parameters and segmental lordosis with L5-S1 oblique lateral interbody fusion at the bottom of a long construct in circumferential minimally invasive surgical correction of adult spinal deformity. *World Neurosurg* 2019;130:e1077–83.
- [18] Abbasi H, Miller L, Abbasi A, Orandi V, Khaghany K. Minimally invasive scoliosis surgery with oblique lateral lumbar interbody fusion: single surgeon feasibility study. *Cureus* 2017;9.
- [19] Zhang C, Wang K, Jian F, Wu H. Efficacy of oblique lateral interbody fusion in treatment of degenerative lumbar disease. *World Neurosurg* 2019;124:e17–24.
- [20] Kanno K, Ohtori S, Orita S, Yamauchi K, Eguchi Y, Aoki Y, et al. Miniopen oblique lateral L5-s1 interbody fusion: a report of 2 cases. *Case Rep Orthop* 2014;2014.
- [21] Li JXJ, Phan K, Mobbs R. Oblique lumbar interbody fusion: technical aspects, operative outcomes, and complications. *World Neurosurg* 2017;98:113–23.
- [22] Fujibayashi S, Kawakami N, Asazuma T, Ito M, Mizutani J, Nagashima H, et al. Complications associated with lateral interbody fusion: nationwide survey of 2998 cases during the first 2 years of its use in Japan. *Spine (Phila Pa 1976)* 2017;42:1478–84.
- [23] Woods KRM, Billys JB, Hynes RA. Technical description of oblique lateral interbody fusion at L1–L5 (OLIF25) and at L5–S1 (OLIF51) and evaluation of complication and fusion rates. *The Spine Journal* 2017;17:545–53.
- [24] Quillo-Olvera J, Lin G-X, Jo H-J, Kim J-S. Complications on minimally invasive oblique lumbar interbody fusion at L2–L5 levels: a review of the literature and surgical strategies. *Ann Transl Med* 2018;6.
- [25] Zeng Z, Xu Z, He D, Zhao X, Ma W, Ni W, et al. Complications and prevention strategies of oblique lateral interbody fusion technique. *Orthop Surg* 2018;10:98–106.
- [26] Fang G, Lin Y, Wu J, Cui W, Zhang S, Guo L, et al. Biomechanical comparison of stand-alone and bilateral pedicle screw fixation for oblique lumbar interbody fusion surgery—a finite element analysis. *World Neurosurgery* 2020;141:e204–12.
- [27] He W, He D, Sun Y, Xing Y, Liu M, Wen J, et al. Quantitative analysis of paraspinal muscle atrophy after oblique lateral interbody fusion alone vs. combined with percutaneous pedicle screw fixation in patients with spondylolisthesis. *BMC Musculoskelet Disord* 2020;21:1–9.
- [28] Fujibayashi S, Hynes RA, Otsuki B, Kimura H, Takemoto M, Matsuda S. Effect of indirect neural decompression through oblique lateral interbody fusion for degenerative lumbar disease. *Spine (Phila Pa 1976)* 2015;40:E175–82.
- [29] Yang Y, Zhang L, Liu B, Pang M, Xie P, Chen Z, et al. Hidden and overall haemorrhage following minimally invasive and open transforaminal lumbar interbody fusion. *Journal of Orthopaedics and Traumatology* 2017;18:395–400.
- [30] Huo Y, Yang D, Ma L, Wang H, Ding W, Yang S. Oblique lumbar interbody fusion with stand-alone cages for the treatment of degenerative lumbar spondylolisthesis: A retrospective study with 1-year follow-up. *Pain Research and Management* 2020;2020.

- [31] Lin J-F, Iundusi R, Tarantino U, Moon M-S. Intravertebral plate and cage system via lateral trajectory for lumbar interbody fusion-a novel fixation device. *The Spine Journal* 2010;10:S86.
- [32] Jin-Sung K, Choi WS, Sung JH. 314; Minimally Invasive Oblique Lateral Interbody Fusion for L4-5: Clinical Outcomes and Perioperative Complications. *Neurosurgery* 2016;63:190–1.
- [33] Liu J, Ding W, Yang D, Wu H, Hao L, Hu Z, et al. Modic changes (MCs) associated with endplate sclerosis can prevent cage subsidence in oblique lumbar interbody fusion (OLIF) stand-alone. *World Neurosurg* 2020;138:e160–8.

Table 1. Demographic data, Clinical presentation, and Co-morbidities

Parameters		Results
Age/years		50.54±6.05 (38-60)
Sex		Male 50% Female 50%
Symptom's duration/months		34.44±16.68 (12-84)
Presentation	Back pain	67.85% (19 patients)
	Leg pain	57.14% (16 patients)
	Sensory deficit	17.8% (5 patients)
	Reflexes deficit	10.7% (3 patients)
	Motor deficit	3.5% (1 patient)
	Sphincter's deficit	3.5% (1 patient)
Comorbidities	HTN	42.8% (11 patients)
	DM	21.4% (6 patients)
	IHD	32.1% (9 patients)
	Obese	35.7% (10 patients)
	Smoking	28.5(8 patients)

Table 2. Clinical data between Pre-operative and 6-month follow-up

Item	Pre-operative	6-months follow-up	t	p value
VAS (Back)	7.36±0.98	5.64±0.870	10.115	<0.05*
VAS (Leg)	6.36±0.911	4±0.903	17.06	<0.05*
ODI%	68.615±8.72	41.38±8.5	12.24	<0.001*

Data are in mean ±SD

*Statistically significant <0.05 at 95 CI.

Table 3. Clinical data between 6-months and 1-year follow-up

Item	6-months follow-up	1-year follow-up	t	p value
VAS (Back)	5.64±0.870	4.07±1.01	12.563	<0.05*
VAS (Leg)	4±0.903	2.07±0.9	11.9	<0.05*
ODI%	41.38±8.5	20.23±4.7	11.9	<0.001*

Data are in mean ±SD

*Statistically significant <0.05 at 95 CI.

Table 4. Fusion grading according to MSCT of the lumbosacral spine[10]

Grade of fusion	6 months post-operative		1-year post-operative	
Grade I: Bridging trabecular bone	N=10	35.7%	N=17	60.7%
Grade II: Continuous bony density	N=15	53.6%	N=9	32.2%
Grade III: Marginal Radiolucency	N=2	7.1%	N=0	0%
Grade IV: 2ry signs of motion	N=0	0%	N=1	3.6%%
Grade V: Hardware Loosening and fatigue	N=1	3.6%	N=0	0%
Grade IV: Subsidence	N=1	3.6%	N=2	7.1%

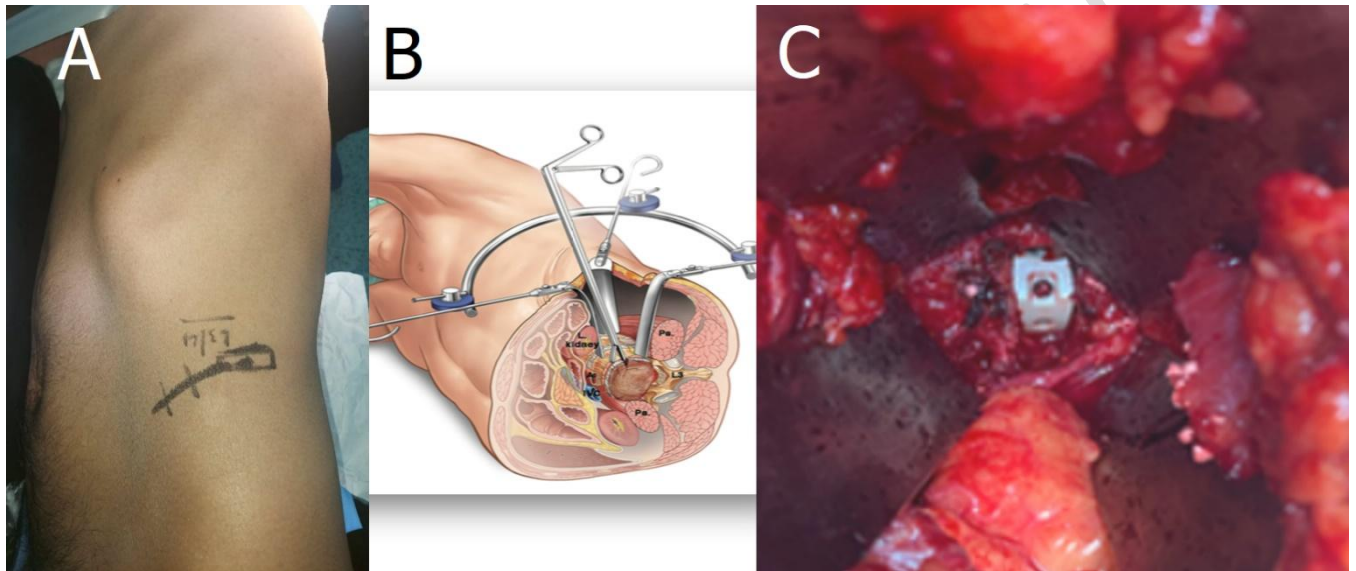


Figure 1. A. Skin incision marked from anterior axillary line to the left lateral side of the rectus muscles, and as shown cage mark is the disc space intended. B. OLIF approach “anterior to psoas”. [8] C. A closeup view for the Cage inside the intervertebral disc space

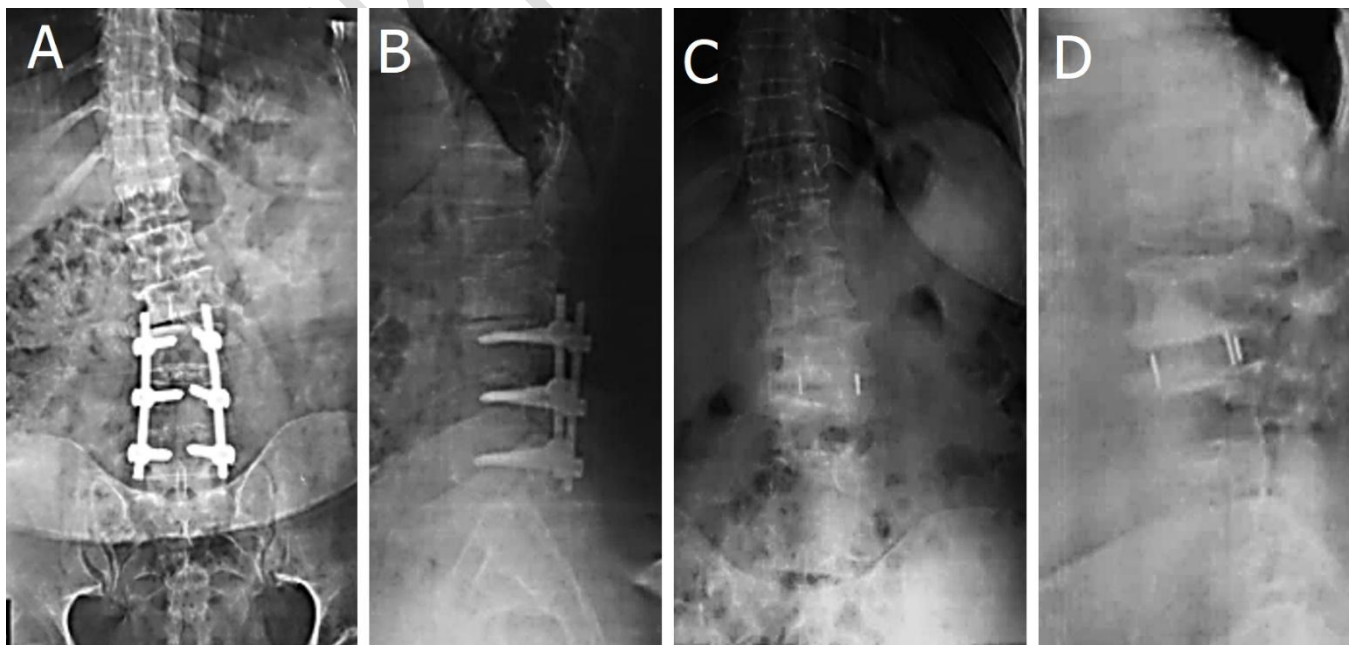


Figure 2. Case 1 a 45 years old female presented with back pain and right lower limb pain of 24 months duration. Back pain is increasing in intensity and aggravated by sitting, standing and relieved by analgesics. Right lower limb pain is found at rest and increased by walking. **A:** Pre-operative AP L/S X-ray Cobb angle was 15.5 degrees. **B:** Pre-operative Lat. L/S X-ray shows *SVA*: 13 mm, *PT*: 25 degrees, *PI*: 53 degrees, *SS*: 28 degrees, *LL*: 16 degrees, *PI/LL mismatch*: 37 and *anterior disc height*: 6.2 mm. **C:** AP L/S X-ray 1-year follow up *Cobb angle* 6 degrees, Sugrimap software A. *Cobb angle* in AP X-ray is 15.5 pre-operative. **B.** Post-operative follow up in 1-year period with *Cobb angle* 6. **D:** Lat. L/S X-ray 1-year follow up shows *SVA*: 8 mm, *SS*: 29 degrees, *PT*: 24 degrees, *LL* 21 degrees, *anterior disc height*: 8.1 mm and *PI/LL mismatch*: 32.

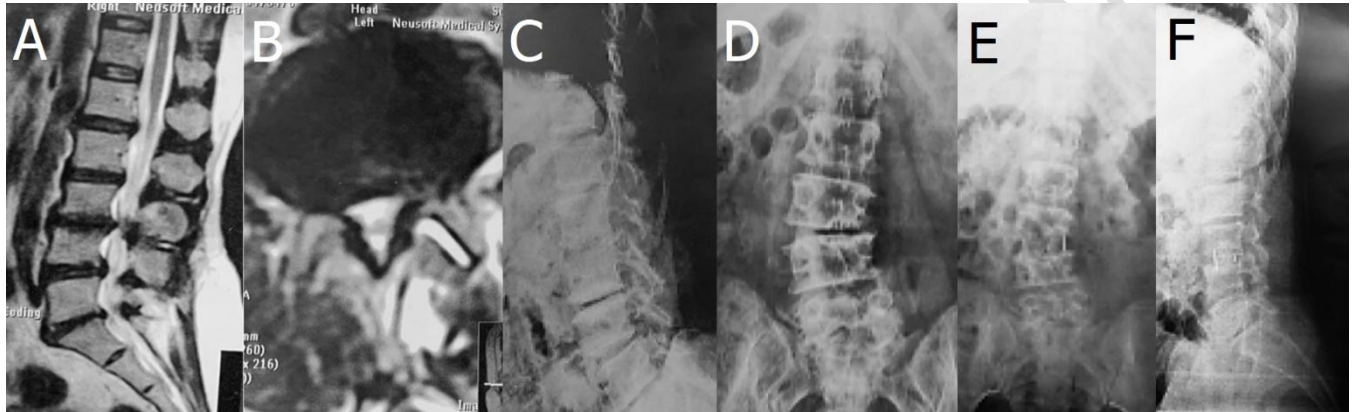


Figure 3. Case 2 **A.** MRI pre-operative T2W Axial cuts showing facet effusion and disc prolapse, **B.** MRI pre-operative T2W sagittal cuts showing canal stenosis at L3/L4 and decreased disc height. **C:** pre-operative lateral lumbar X-ray showing degenerated intervertebral disc L3/L4, *SVA*: 10 mm, *PT*: 27 degrees, *SS*: 33 degrees, *LL*: 18 degrees, *PI/LL mismatch*: 38 and *anterior disc height*: 5 mm. **D:** pre-operative AP lumbar X-ray shows *Cobb angle* of 28 degrees, **E:** demonstrates AP lumbar X-ray 1-year follow up with corrected *Cobb angle* to 7.3 degrees after stand-alone OLIF L3/L4 and **F:** demonstrates lateral lumbar X-ray 1-year follow up; *SVA*: 6 mm, *SS*: 35 degrees, *PT*: 25 degrees, *LL* 22 degrees, *anterior disc height*: 14 mm and *PI/LL mismatch*: 35.

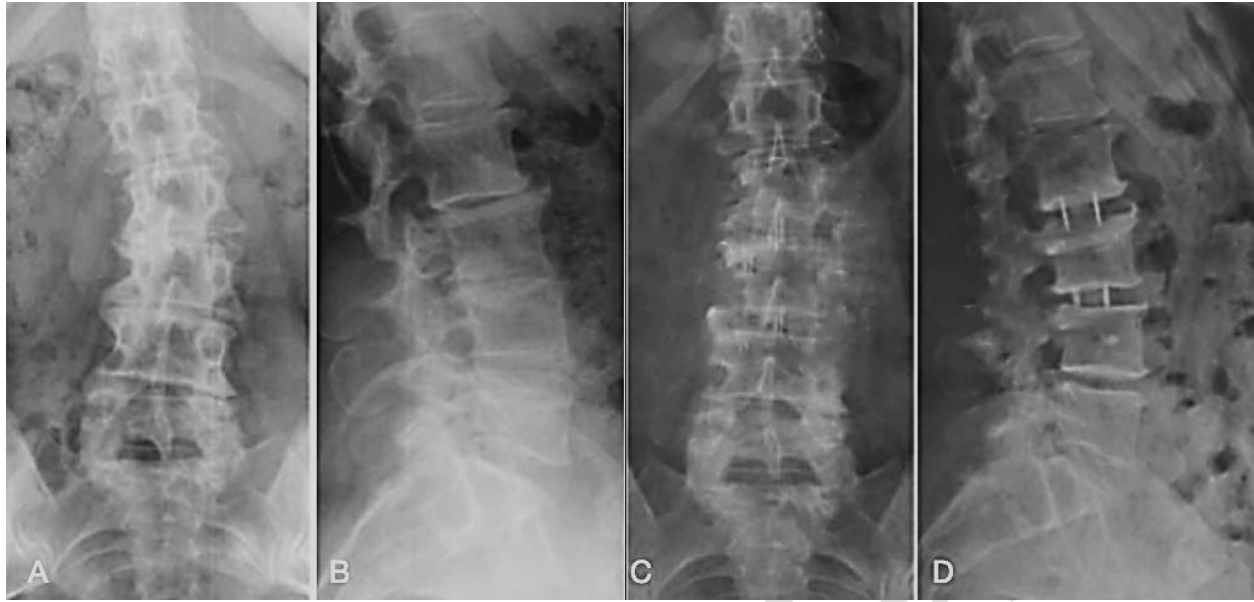

Figure 4. Case 3; 31 old male patient with degenerative scoliosis L2/L3 and L3/L4 complaining of back pain and leg pain of 12 months duration **A:** AP X-ray L/S spine denoting degenerative scoliosis *Cobb angle* 24 degrees, **B:** Lat. X-ray L/S spine with decreased disc spaces and straightening of lumbar spine, *SVA*: 10 mm, *PT*: 16 degrees, *SS*: 42 degrees, *LL*: 24 degrees, *PI/LL* mismatch: 27 and *anterior disc height*: 7.2 mm L2/3 and 8.3 mm L3/L4 **C:** AP L/S spine after OLIF levels L2/L3/L4 1-year follow up shows improved *Cobb angle* to 9 degrees, and **D:** Lateral X-ray L/S spine 1-year follow-up shows increased *anterior disc heights* 11.5 mm L2/L3, 12 mm L3/L4 on L2/L3 and L3/L4, *SVA*: 8 mm, *SS*: 43 degrees, *PT*: 14 degrees, *LL*: 35 degrees and *PI/LL*: mismatch: 18.

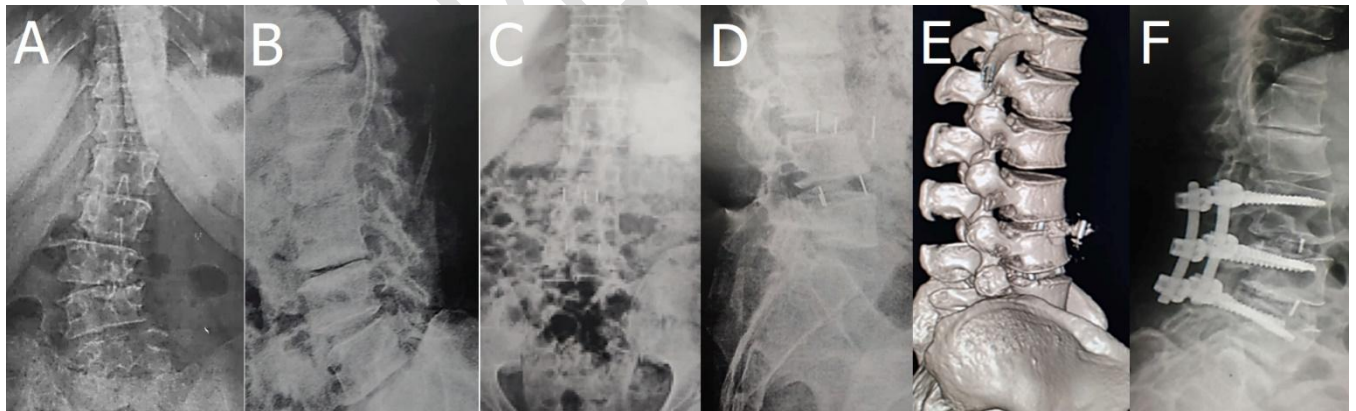


Figure 5. Case 4; a 31 year old male patient complaining of back pain and leg pain of 24 months duration **A:** AP X-ray L/S spine with Degenerative scoliosis L3/L4 and L4/L5 and *Cobb angle* was 21 degrees **B:** Lat. X-ray L/S spine with lumbar spine decreased lordosis and degenerative pattern in L3/L4 disc and *LL* was 10 **C:** AP X-ray L/S after first session shows improved *Cobb angle* to 4 degrees, **D:** Lat. X-ray L/S spine shows L3/L4 cage dislodgment and stable L4/L5 cage, **E:** CT 3D reconstruction, and **F:** Lat. X-ray L/S spine shows posterior instrumentation and cage re-application anteriorly.